

'Subarachnoid cyst' after evacuation of chronic subdural hematoma: Case report of an unusual postoperative morbidity

Low Y. Y. Sharon, NG Wai Hoe

Department of Neurosurgery, National Neuroscience Institute, Singapore

ABSTRACT

Burr-hole drainage of chronic subdural hematomas are routine operative procedures done by neurosurgical residents. Common postoperative complications include acute epidural and/or subdural bleeding, tension pneumocephalus, intracranial hematomas and ischemic cerebral infarction. We report an interesting post-operative complication of a 'subarachnoid cyst' after burr-hole evacuation of a chronic subdural hematoma. The authors hypothesize that the 'cyst' is likely secondary to the splitting of the adjacent neomembrane within its arachnoid-brain interface by iatrogenic irrigation of the subdural space. Over time, this 'cyst' develops into an area of gliosis which eventually causes long-term scar epilepsy in the patient. As far as we are aware, this is the first complication of such a 'subarachnoid cyst' post burr-hole drainage reported in the literature.

Key words: Burr-hole craniotomy, chronic subdural hematoma, subdural membrane

Introduction

Chronic subdural hematoma (CSDH) is one of the most common types of intracranial hemorrhage disease managed in most neurosurgical departments.^[1,2] Currently, CSDH has the best prognosis of all patients with intracranial hematoma.^[3] Common risk factors for CSDH include increased incidence of falls, especially in the elderly,^[4-6] excessive alcohol intake,^[7] increased use of anti-thrombotic medications and brain atrophy causing venous fragility.^[1]

The common post-operative complications reported in the literature include acute epidural hemorrhage, acute subdural hematoma, intracranial hematomas,^[8] tension pneumocephalus, ischemic cerebral infarction and one reported case of acute bleeding into the dural-outer membrane space.^[1] However, this is the first case of a 'subarachnoid cyst'

caused by iatrogenic irrigation of a CSDH, with resultant long-term scar epilepsy. Here, we present the case study, review the relevant literature and present our hypothesis for such an unusual postoperative complication.

Case History

A 50-year-old male was admitted for symptoms of persistent dizziness. Neurological examination did not demonstrate any obvious focal neurological deficit, and his systems review was otherwise unremarkable. However, a computed tomographic (CT) scan of his brain showed a right fronto-parieto-temporal acute-on-chronic subdural hematoma up to 2-cm thickness, with midline shift of 9 mm to the left [Figure 1].

The patient underwent a standard two burr-hole closed system drainage of the subdural hematoma by a first-year neurosurgical resident. Copious irrigation with Ringers Lactate solution was used to wash out the blood clots. The subdural hematoma was noted to be septated with some membranous material. Postoperatively, he was noted to have a new mild left-sided weakness. An urgent follow-up CT Brain was done. This demonstrated that the initial right-sided subdural hematoma was smaller and improvement in the midline shift. However, there was a new cerebrospinal fluid (CSF) attenuation collection measuring 3.1×2.7 cm in the right frontal lobe, which was reported to be likely communicating with the Sylvian fissure and remnant subdural hematoma [Figure 2].

Access this article online

Quick Response Code:



Website:

www.asianjns.org

DOI:

10.4103/1793-5482.144210

Address for correspondence:

Dr. Low Y. Y. Sharon, 11, Jalan Tan Tock Seng, National Neuroscience Institute, Singapore 308433. E-mail: sharon_yy_low@nni.com.sg

The patient's weakness gradually self-improved over the next 24 hours without any need for surgical intervention. Owing to his clinical improvement, decision was made for close monitoring with serial follow-up CT scans. However, 1 week postoperatively, the patient was witnessed to have an episode of left upper limb and facial jerking that self-aborted after a few minutes. A repeat CT brain did not show any new focal pathology. The impression was that of postoperative seizures. Antiepileptic medications were commenced for the patient. There were no more reported episodes of seizures after the medication reached therapeutic levels. The remainder of his inpatient stay was uneventful and he was discharged home stable.

Subsequent outpatient imaging showed resolution of the remnant CSDH, and the frontal lobe collection became a stable area of gliotic encephalomalacia [Figure 3]. There was an attempt by the clinical team to wean off the patient's antiepileptics after he was noted to be seizure-free for more than three months. However, this was unsuccessful and the patient re-presented to the hospital for focal left upper limb and facial jerking. Although there was no formal electroencephalography (EEG) performed for the patient, based on the patient's pattern of seizures and CT brain findings, he was likely to have developed postoperative focal scar epilepsy.

Discussion

The 'subdural space' for CSDH

In general, a subdural hematoma is said to be formed by the accumulation of blood products in the 'subdural space'. However in reality, a true subdural space does not exist at baseline in healthy individuals.^[9,10] Haines reports that at microscopic level, there is no evidence of an intervening space between the arachnoid barrier cell layer and the dural border cell layer that would correlate with what has been called the subdural space.^[10] When a tissue space is created in this general area of the meninges it is the result of tissue damage and represents, in most instances, a cleaving open of the dural border cell junctions are separated, and it is probable that cell membranes are damaged. It is suggested that the so-called 'subdural space' is not a potential space since the creation of a cleft in this area of the meninges is the result of tissue damage.^[10,11]

The relevance of 'neomembranes'

The actual pathogenesis of a chronic subdural hematoma and that of neomembranes have been controversial for more than a century. One of the theories is that when an acute hemorrhage originates above the arachnoid level, it dissects within the layer of the dural border cells which produce a so-called 'neomembrane' by their proliferation, becoming transfixed with collagen, elastic fibers and neo-microvascularization.^[12] These new macrocapillaries are generally leaky and exudations from them in the outer part of the neomembranes may play an important role in the lesion's enlargement.^[13]

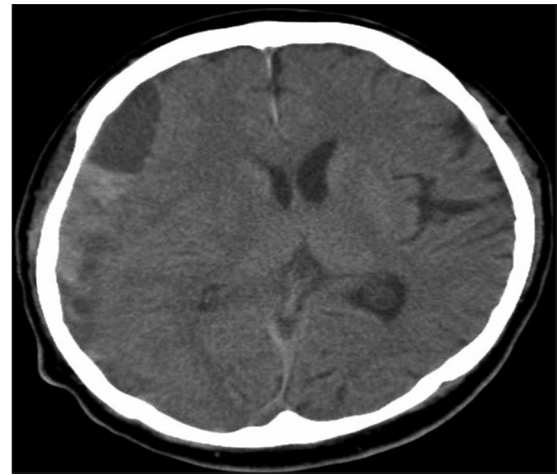


Figure 1: Axial noncontrast CT brain obtained preoperatively shows a right-sided acute-on-chronic SDH

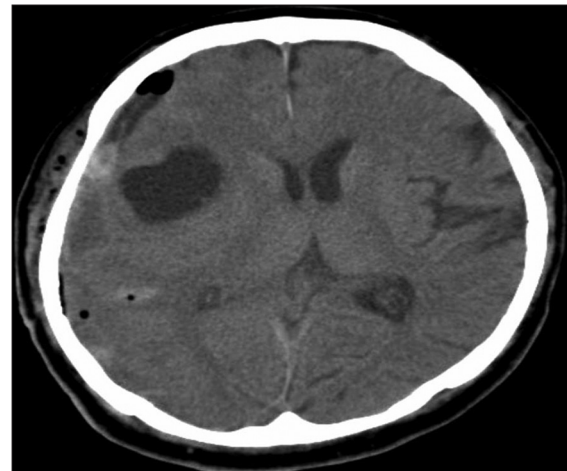


Figure 2: Axial noncontrast CT brain done postoperatively shows a 'subarachnoid cyst' in right frontal lobe likely communicating with the Sylvian fissure and remnant SDH

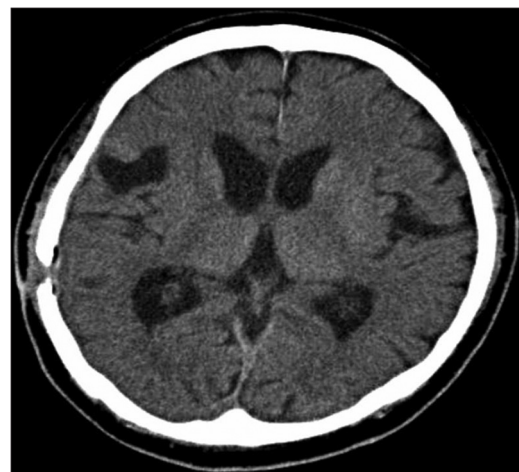

Figure 3: Axial noncontrast follow-up CT brain 6 months postoperatively shows complete resolution of initial right-sided CSDH and stable right frontoparietal gliosis

Friede and Schachenmayr's detailed study have demonstrated that these subdural neomembranes are tightly attached to the inner surface of the dura mater. Any cleavage within the dural border typically leaves the arachnoid barrier with its tight junctions and its basement membranes lamina intact. However, the side attached to the arachnoid is fragile with minimal continuity to the neomembrane. Thus, as the dura can be separated from the arachnoid without effort, there is an impression of a 'space' where is actually a lack of reinforcing tissue structure.^[12]

Microscopically, there is little mechanical coherence of the tissue because of its loose texture and due to the layering of cells in parallel sheets. A zone of extreme fragility between the proliferated dural border cells (the neomembrane) and its arachnoid border prevents fusion of the dura with the arachnoid by way of the neomembrane.^[12]

Another notable aspect of these neomembranes is their tendency to undergo repetitive multifocal bleeding. This is understood from the sprouting of capillaries into a tissue zone lacking in intercellular cohesion.^[12] In addition, Yamashima *et al.*'s study concludes that blood vessels of these neomembranes show a marked proliferation potential and a fragile nature.^[14] The ongoing interaction between the components of the outer membrane and the subdural fluid will thus, contribute to the growth of this neomembrane and may inevitably cause recurrent hemorrhage.^[15]

Overview of burr-hole drainage and common post-CSDH complications

Although the initial surgical management of CSDH remains controversial,^[2] multiple drainage surgical techniques have been well-described for the evacuation of chronic subdural hematomas.^[3,9] These techniques include twist drill craniostomy, burr-hole craniostomy and open craniotomy. For the majority of CSDH without extensive membranes, evacuation is possible via any of the above techniques.^[9] However, if significant thick and/or calcified membranes are present, craniotomy evacuation has been recommended as the technique of choice.^[4,16]

Majority of the intracerebral complications cited in the literature are usually postoperative intracerebral hematomas. Possible pathogenic mechanisms include hemorrhage into previously undetected areas of contusion, a sudden increase in cerebral blood flow combined with faulty autoregulation, and damage to parenchymal vessels secondary to intra- or postoperative shift of the intracranial contents possibly caused by rapid surgical decompression of the initial lesion.^[8,17] However, there is no previously reported postoperative subarachnoid cystic lesion as illustrated in our case report.

The overall incidence of post-CSDH seizures has been cited to vary from 2.3 to 17%.^[15,18] Furthermore, Ohno *et al.* quotes the

general risk of seizure post-burr-hole evacuation of hematoma is usually less than 5%.^[18] In Huang *et al.*'s study, patients with seizures after CSDH are noted to experience borderline longer duration of hospitalization and worse outcome after discharge compared to those without seizures.^[19] The known pathophysiological mechanisms include surgical techniques causing brain insults may provoke early seizures^[20] and late onset seizures can theoretically be due to gliosis from previous cortical injury.^[21]

Our hypothesis

In our case study, copious irrigation of the subdural space with Ringers Lactate was used during evacuation of the subdural hematoma via two burr holes. The intraoperative findings were that of membranous septations within the CSDH.

We postulate that the neomembranes, with on its friable arachnoid interface, created a partial one-way valve which enabled access between the subdural-subarachnoid space. Next, the accumulation of the irrigation fluid within this newly created spatial connection occurred. This can explain the communication of the 'subarachnoid cyst' with the Sylvian fissure and the cerebrospinal fluid reported in the CT scan. Another factor considered by the operating resident was the fact that irrigation into the burr holes was probably at a higher pressure in a bid to evacuate the subdural blood clots. This resulted in a further accumulation of isotonic wash inside the cranium, which was unable to flow out smoothly owing to partial obstruction caused by such neomembranes. Hence, the remnant irrigation fluid left behind is the most probable cause of the appearance of the 'cystic lesion'. Fortunately, the irrigation done during the course of the surgery was not forceful enough to cause significant bleeding when it made contact with the neomembranes. After all, based on the literature, a well-known cause of recurrent and new intracerebral hemorrhages is likely to occur from these neomembranes.

However, despite its eventual resolution the 'subarachnoid cyst' had caused substantial cortical injury that became gliotic. Based on the pattern of the patient's post-operative seizures, the area of gliosis was most likely a causative factor for long-term scar epilepsy.

Conclusions

Although burr-hole drainage of subdural hematomas is often routinely done by neurosurgeons, they should not be regarded as entirely benign entities. Upon reflection of this case, the relevance of controlled irrigation and watchful monitoring intraoperatively become more crystal clear, especially to the surgeon involved. As CSDH patients have the best outcomes amongst all who have intracranial hemorrhages, it becomes more important for resident neurosurgeons to be mindful when operating on them.

References

- Chen CL, Cheng JY, Chen LK. Acute bleeding into dural-outer membrane space after burr hole drainage for chronic subdural haemorrhage. *Brit J Neurosurg* 2005;19:366-7.
- Ducruet AF, Grobelny BT, Zacharia BE, Hickman ZL, DeRosa PL, Anderson K, *et al*. The surgical management of chronic subdural hematoma. *Neurosurg Rev* 2012;35:155-69; discussion 169. Epub 2011 Sep 10. DOI: 10.1007/s10143-011-0349-y.
- Friede RL, Schaechenmayr W. The origin of subdural neomembranes. *Am J Pathol* 1978;92: 69-78.
- D'Avella D, De Blasi F, Rotillo A, Pensabene V, Pandolfo N. Intracerebral hematoma following evacuation of chronic subdural hematomas. *J Neurosurg* 1986;65:710-2.
- Haines DE. On the question of a subdural space. *Anat Rec* 1991;230:3-21.
- Yamashima T, Yamamoto S, Friede RL. The role of endothelial gap junctions in the enlargement of chronic subdural hematomas. *J Neurosurg* 1983;59:298-303.
- Haines DE, Harkey HL, Ossama AM. The 'subdural' space: A new look at an outdated concept. *Neurosurgery* 1993;31:111-20.
- Lee JY, Ebel H, Ernestus RI, Klug N. Various surgical treatments of chronic subdural hematoma and outcome in 172 patients: Is membranectomy necessary? *Surg Neurol* 2004;61:523-8.
- Misra BK. Commentary: What is the best option for recurrent chronic subdural hematoma? *World Neurosurg* 2010;73:640-1.
- Ramachandran R, Hedge T. Chronic subdural hematomas—causes of morbidity and mortality. *Surg Neurol* 2007;67:367-73.
- McLachlan RS, Bolton CF, Coates RK, Barnett HJ. Gait disturbance in chronic subdural hematoma. *Can Med Assoc J* 1981;125:865-8.
- Kim JH, Kang DS, Kim JH, Kong MH, Song KY. Chronic subdural hematoma treated by small or large craniotomy with membranectomy as the initial treatment. *J Korean Neurosurg Soc* 2011;50:103-8.
- Rocchi G, Caroli E, Salvati M, Delfini R. Membranectomy in organized chronic subdural hematomas: Indications and technical notes. *Surg Neurol* 2007;67:374-80.
- Modesti LM, Hodge CJ, Barnwell ML. Intracerebral hematoma after evacuation of chronic extracerebral fluid collections. *Neurosurgery* 1982;10 (6 Pt 1):689-93.
- Luxon LM, Harrison MJ. Chronic subdural haematoma. *Q J Med* 1979;48:43-53.
- Killeffer JA, Killeffer FA, Schochet SS. The outer neomembrane of chronic subdural hematoma. *Neurosurg Clin N Am* 2000;11:407-12.
- Tokmak M, Iplikcioglu C, Bek S, Gokduman CA, Erdal M. The role of exudation in chronic subdural hematomas. *J Neurosurg* 2007;107:290-5.
- Ohno K, Maehara T, Ichimura K, Suzuki R, Hirakawa K, Monma S. Low incidence of seizures in patients with chronic subdural haematoma. *J Neurol Neurosurg Psychiatry* 1993;56:1231-3.
- Huang YH, Yang TM, Lin YJ, Tsai NW, Lin WC, Wang HC, *et al*. Risk factors and outcome of seizures after chronic subdural hematoma. *Neurocrit Care* 2011;14:253-9.
- Hirakawa K, Hashizume K, Fuchinque T, Takahashi H, Nomura K, Matsutani M, *et al*. Statistical analysis of chronic subdural hematoma in 309 adult cases. *Neurol Med Chir (Tokyo)* 1972;12:71-83.
- Markwalder TM, Reulen HJ. Influence of neo-membranous organization, cortical expansion and subdural pressure on the post-operative course of chronic subdural hematoma: An analysis of 201 cases. *Acta Neurochir (Wien)* 1986;79:100-6.

How to cite this article: Sharon LY, Wai Hoe NG. 'Subarachnoid cyst' after evacuation of chronic subdural hematoma: Case report of an unusual postoperative morbidity. *Asian J Neurosurg* 2016;11:316.
Source of Support: Nil, **Conflict of Interest:** None declared.