

Received: 2020.03.18

Accepted: 2020.08.18

Available online: 2020.09.02

Published: 2020.10.12

Widely Disseminated Cryptococcosis Manifesting in a Previously Undiagnosed Human Immunodeficiency Virus (HIV)-Positive 18-Year-Old

Authors' Contribution:

Study Design A
Data Collection B
Statistical Analysis C
Data Interpretation D
Manuscript Preparation E
Literature Search F
Funds Collection G

ABDEF 1 **John Howard**
ABDEF 1 **Thomas Z. Thompson**
DE 2 **Rodger D. MacArthur**
ABDEFG 1 **Amy M. Rojiani**
ABEF 1 **Joseph White**

1 Department of Pathology, Medical College of Georgia at Augusta University, Augusta, GA, U.S.A.

2 Department of Medicine (Infectious Diseases), Medical College of Georgia at Augusta University, Augusta, GA, U.S.A.

Corresponding Author: Joseph White, e-mail: JWhite3@augusta.edu

Conflict of interest: None declared

Patient: Male, 18-year-old
Final Diagnosis: Disseminated cryptococcosis in previously undiagnosed HIV
Symptoms: Diarrhea • lymphadenopathy
Medication: —
Clinical Procedure: —
Specialty: General and Internal Medicine • Pathology

Objective: Unusual clinical course

Background: After initial infection with HIV, loss of CD4+ T cells progresses along a predictable timeline. The clinical latency stage lasts an average of 10 years, until the CD4+ T cell count falls below 200 cells/uL or the patient develops an AIDS-defining opportunistic infection/cancer. This report describes an unusual opportunistic infection in a young patient with no prior clinical evidence of HIV infection.

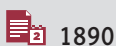
Case Report: An 18-year-old man presented with fever, abdominal pain, and dyspnea for the previous 2 weeks and was symptomatically treated for gastroenteritis. He presented 2 weeks later with extreme fatigue, and a CT scan revealed diffuse lymphadenopathy. He was transferred to a regional hospital, but upon arrival and prior to detailed investigative work-up, he developed cardiac arrest. Despite maximal resuscitative efforts, he died approximately 8 h after admission. At autopsy, diffuse lymphadenopathy, splenomegaly, and pulmonary congestion were noted. Disseminated cryptococcal infection involving almost every organ system was identified at autopsy. A postmortem HIV-1 antibody test was positive. The cause of death was severe immunodeficiency as a result of advanced HIV infection resulting in disseminated cryptococcal infection, with cerebral edema, herniation, and respiratory failure.

Conclusions: This patient's non-specific symptoms in conjunction with his rapid decline made arriving at a correct diagnosis challenging. Only during autopsy was the disseminated fungal infection discovered, leading to suspicion of HIV infection.

HIV autopsies are not uncommon, but the clinical history is usually known beforehand. This case report highlights the importance of considering HIV-related conditions in patients presenting with this array of symptoms, as well as to alert healthcare providers and staff to the need for increased biosafety precautions.

MeSH Keywords: Case Reports • Cryptococcosis • Diagnosis, Differential • HIV

Full-text PDF: <https://www.amjcaserep.com/abstract/index/idArt/924410>



1890



1



1



9



Background

In most cases, following primary infection with HIV, the loss of CD4+ T cells continues over a fairly predictable, extended period of time. The period during which the body's defenses attempt to bring the virus under control, at least to a more stable set point, is defined as the clinical latency stage, which lasts an average of 10 years, until the CD4+ T cell count falls below 200 cells/ μ L or the patient develops an AIDS-defining opportunistic infection/cancer. The patient described here had no clinical evidence of HIV infection or other manifestation of the disease. Because he remained asymptomatic before presentation, there was no indication of a need for HIV testing. His clinical presentation is highly unusual in that his initial non-specific gastrointestinal symptoms and fatigue did not in any way raise suspicion of HIV infection, and his subsequent diffuse lymphadenopathy was suspected to be lymphoma. The identification of disseminated cryptococcosis at autopsy in the absence of prior clinical evidence of HIV infection led to a postmortem diagnosis of AIDS. This case may have been acute retroviral syndrome; however, since the patient had no prior testing or evidence of HIV infection, it is impossible to confirm that diagnosis [1]. This case report presents important information by defining the very extensive dissemination of cryptococcosis and discussing the implications for differential diagnosis. Additionally, patient care and exposure at autopsy are important considerations in the absence of a prior HIV diagnosis.

Case Report

An 18-year-old African American man presented to the hospital with complaints of fever, nausea, dyspnea, and abdominal pain over the previous 2 weeks. He was subsequently symptomatically treated for gastroenteritis without additional work-up, and blood culture, stool analysis, and colonoscopy were not performed. This case occurred before the present COVID-19 pandemic. This was his first clinical episode and he otherwise appeared to be healthy, with no evidence of cachexia. He had no history of recent travel, prior surgery, or blood transfusion. There was no social history of sexual activity or preference. He returned 2 weeks later with extreme fatigue to the point of being unable to walk, at which point a CT of his chest, abdomen, and pelvis was ordered, which revealed diffuse lymphadenopathy. A lymphoma was suspected, and the patient was admitted for work-up (Day 1). A complete blood count (CBC) was also ordered, which demonstrated a leukocytosis (15 200 cells/ μ L) with an absolute and relative neutrophilia (90%).

Soon after admission, before the patient could undergo additional investigative studies including lymph node biopsy or complete pulmonary work-up, he rapidly declined and developed respiratory distress requiring intubation. He was transferred to

a regional medical center for a heightened level of care. Upon evening arrival, he exhibited altered mental status, prompting a chest X-ray that revealed bilateral hilar adenopathy and right lower-lobe predominant consolidations. Subsequent X-rays over the next several hours showed increasing levels of pulmonary edema. Another CBC was ordered, which showed a further increase in WBC (16 900 cells/ μ L), with 93% neutrophils (15 700 cells/ μ L) and 5% lymphocytes (850 cells/ μ L), as well as hemoglobin and hematocrit values of 11.5 gm/dL and 36.2%, respectively. A complete metabolic panel revealed elevated AST (147 IU/L) and ALT (62 IU/L), as well as extremely high CRP (6.40 mg/dL) and procalcitonin (5.33 ng/mL) levels. The following morning (Day 2), he had a sharp decline in hemodynamic status and had a cardiac arrest secondary to ventricular tachycardia. He received multiple rounds of advanced cardiac life support over the next 4 h, but died despite maximal resuscitation efforts.

An unrestricted autopsy was performed on this generally normal-appearing man, with no evidence of cachexia, no external wounds, rash, icterus, or other obvious pathology. Autopsy findings demonstrated diffuse lymphadenopathy observed in the mediastinal, retroperitoneal, mesenteric, and inguinal groups, splenomegaly, and pulmonary congestion. Histologic examination of submitted tissues revealed disseminated cryptococcal infection involving the spleen (Figure 1A), CNS (Figure 1B), left adrenal gland (Figure 1C), lungs (Figure 1D), bone marrow (Figure 1E), myocardium (Figure 1F), and thyroid (Figure 1G), as well as liver, kidneys, pancreas, gastrointestinal tract, and lymph nodes. Gomori methenamine silver (Figure 1H), mucicarmine (Figure 1I), and periodic acid-Schiff histochemical staining demonstrated morphology consistent with the diagnosis.

After identification of disseminated cryptococcal infection, human immunodeficiency virus (HIV)-1 antibody screening was performed, with confirmation of HIV-1 infection. The available clinical and family history did not suggest HIV infection within the immediate family. The cause of death was severe immunodeficiency as a result of advanced HIV infection resulting in diffuse fungal infection leading to sepsis, cerebral edema with herniation, and respiratory failure.

Discussion

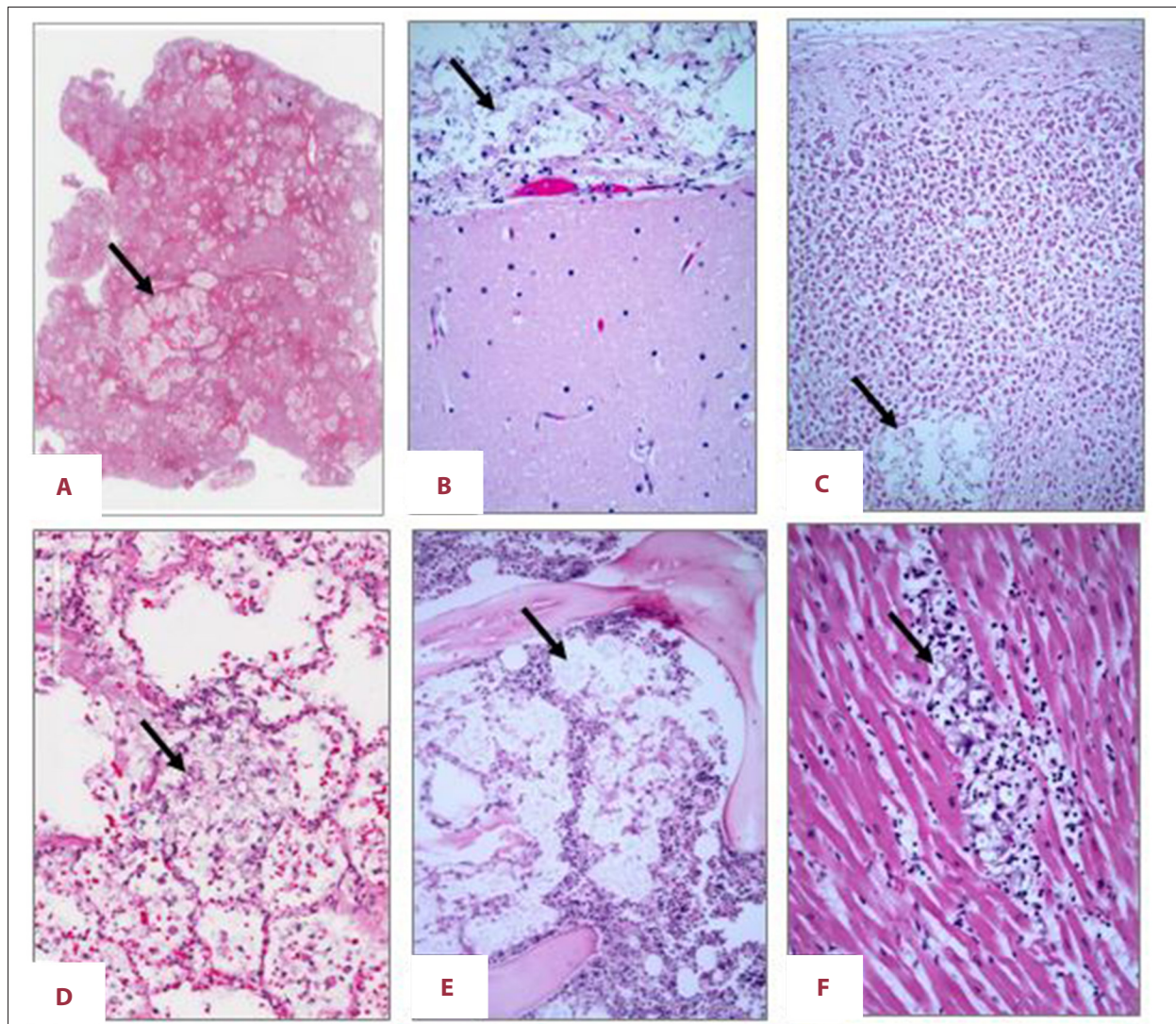
HIV is spread through contact with certain human body fluids, after which the virus invades and attacks the host's immune system. HIV infects host CD4+ T cells via interaction between an HIV envelope-bound protein called *env*, and host cell CD4, CCR5, and CXCR4 receptors [2]. The HIV protein *env* extends from the virion and consists of 2 glycoproteins, gp120 and gp41, which make up the cap and stem, respectively, of *env* [2]. Gp120 is required for binding to host CD4 receptors,

while gp41 plays a role in promoting fusion of the viral envelope and host cell plasma membrane after receptor binding [2]. The HIV virus then uses host cell machinery to reproduce, destroying these cells in the process. CD4⁺ T cells are a vital part of the human immune system; therefore, their destruction by the HIV virus weakens the body's overall immune capabilities. After initial seroconversion due to infection with HIV, progressive loss of CD4⁺ T cells follows a fairly predictable timeline. There is typically a clinical latency stage, followed by clinical evidence of AIDS. The clinical latency stage develops as the body's immune response is able to substantially, but not completely, lower the viral load. The clinical latency stage for patients who are not receiving treatment lasts an average of 10 years, until the CD4⁺ T cell count falls below 100-200 cells/ μ L. Infected individuals not receiving treatment eventually progress to the third stage of HIV infection, known as AIDS, when their CD4⁺ T counts drop below 200 cells/ μ L or they develop an AIDS-defining opportunistic infection/cancer.

The acute HIV infection stage, also known as acute retroviral syndrome (ARS), typically presents (in 50% or more of patients) with symptoms 2-4 weeks after seroconversion [1]. Symptoms during this stage can last from a few days to several weeks, and fall under 4 broad categories as defined by Braun et al. [3]: neurological, constitutional, gastrointestinal, and skin/mucosal (Table 1).

Typical ARS is defined as the presence of a fever plus at least 1 of the 17 most common symptoms associated with ARS, or, in the absence of fever, at least 2 of the 17 symptoms listed in Table 1 [3]. During the typical presentation of ARS, the CD4⁺ T cell count usually falls rapidly as the virus replicates and may be followed by acute infections or other manifestations.

In our patient, both of these possibilities remain viable options. However, because the patient presented to us at the autopsy stage, we are unable to confirm the precise pathogenesis.



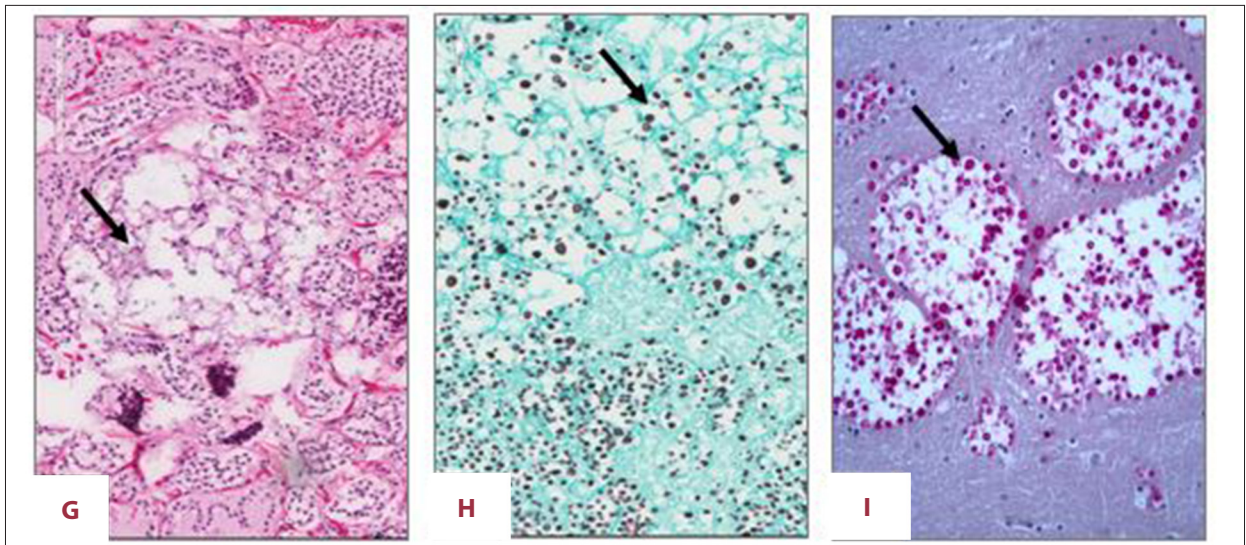


Figure 1. (A) Low-power view demonstrating the large number of foci of cryptococci in the spleen. H&E. Original magnification 20×. (B) Cryptococcal foci widely disseminated within the subarachnoid space. H&E. Original magnification 200×. (C) Occasional cryptococcal foci within the adrenal cortex. H&E. Original magnification 100×. (D) Widespread cryptococcal foci within the lungs. H&E. Original magnification 100×. (E) Cryptococcal foci seen in multiple sections of bone marrow. H&E. Original magnification 100×. (F) Rare cryptococcal foci were present in the myocardium. H&E. Original magnification 200×. (G) Cryptococcal foci were also seen in the thyroid gland. H&E. Original magnification 100×. (H) Gomori methenamine silver stain identifying cryptococci foci within the adrenal cortex. H&E. Original magnification 100×. (I) Mucicarmine stain identifying cryptococcal foci within the brain. Original magnification 200×.

Table 1. The most common symptoms present in patients with acute retroviral syndrome (adapted from Braun et al. [3]).

Neurological	Gastro-intestinal	Constitutional	Skin and Mucosal
1. Headache	1. Diarrhea	1. Fever/malaise	1. Rash
2. Severe neurological symptoms	2. Nausea	2. Weight loss	2. Pharyngitis
	3. Vomiting	3. Arthralgia	3. Genital ulcers
	4. Oral ulcers	4. Myalgia	4. Oral ulcers
		5. Night Sweats	
		6. Cough	
		7. Lymphadenopathy	

He was not previously known to be HIV-infected, and was unable to give any specific history to the health care providers. It is possible that the patient had latent HIV infection for many years prior, but was asymptomatic and not cachectic, and developed disseminated cryptococcosis when his immunocompromised status crossed a threshold level with a CD4⁺ T cell count of less than 100–200 per μL . On average, progression from initial presentation to a CD4⁺ T cell in this range takes about 10 years. However, higher HIV RNA levels are associated with faster decline in CD4⁺ T cell counts, such that our patient's decline could have occurred in less than 5 years. Many individuals in the USA become infected with HIV as early as age 13 years. Another possibility is that our patient could have been congenitally infected. While less likely, the possibility also remains that this represents the acute retroviral syndrome presenting 6 weeks or so after initial exposure to HIV.

According to the CDC, the most prevalent opportunistic infections for HIV-positive individuals living in the USA are candidiasis of the bronchi, trachea, esophagus, or lungs, coccidioidomycosis, extrapulmonary cryptococcosis, and cytomegalovirus [4]. Extrapulmonary cryptococcosis (EC) in immunocompromised hosts can affect any organ in the body, but it most commonly manifests as cryptococcal meningoencephalitis, with associated symptoms including fatigue, headache, altered mentation, stiff neck, and fever [5]. Other associated symptoms include skin rash, dyspnea, and cough, which are indicative of disseminated cryptococcal infection [6]. Our patient did not have any skin manifestations. The diffuse lymphadenopathy was not investigated because of the unstable condition of the patient and his subsequent cardiac arrest. However, at autopsy, the nodes were seen to be severely involved with cryptococcosis, with no evidence of lymphoma. The guidelines for treatment of

EC state that treatment should proceed in 3 stages: induction, consolidation, and maintenance. Induction begins with interval treatments of IV amphotericin B in conjunction with oral flucytosine for a minimum of 2 weeks [7]. After moderate clinical improvement, treatment can move to the consolidation stage, in which fluconazole (400–800 mg daily) is indicated for at least 8 weeks. Finally, the dosage of fluconazole can be decreased to a maintenance dose (200 mg/day), which should be taken for at least 1 year [5]. Despite advances in both HIV and cryptococcosis treatment, EC remains a major cause of mortality in HIV-positive individuals, with mortality rates for untreated individuals ranging from 22% to 96% at 10–12 weeks, and 100% for untreated cryptococcal meningoencephalitis [8,9]. Cryptococcal meningoencephalitis can result in death by causing cerebellar tonsillar herniation leading to cardiopulmonary collapse, as was seen in our patient.

Cryptococcal infection is most commonly due to *Cryptococcus neoformans* and *Cryptococcus gattii*. The most common site of infection is the lungs, with macroscopic, tan-to-white nodules that can demonstrate central necrosis. When dissemination occurs, the brain and skin are the most common secondary infection sites. Skin lesions can appear as Molluscum contagiosum-like raised, umbilicated papules or weeping, ulcerated lesions. Brain lesions are often cystic and periventricular. Microscopically, immunocompetent patients demonstrate granulomas with multinucleated giant cells containing the fungal organisms. These granulomas can become necrotizing, with surrounding histiocytes. In immunocompromised patients, inflammation is minimal, with expansion within alveolar spaces or production of cryptococcomas in other organs.

References:

1. Remien RH, Higgins JA, Correale J et al: Lack of understanding of acute HIV infection among newly-infected persons-implications for prevention and public health: The NIMH Multisite Acute HIV Infection Study: II. *AIDS Behav*, 2009; 13(6): 1046–53
2. Wilen CB, Tilton JC, Doms RW: HIV: Cell binding and entry. *Cold Spring Harb Perspect Med*, 2012; 2(8): a006866
3. Braun DL, Kouyos RD, Balmer B et al: Frequency and spectrum of unexpected clinical manifestations of primary HIV-1 infection. *Clin Infect Dis*, 2015; 61(6): 1013–21
4. Centers for Disease Control and Prevention: AIDS and Opportunistic Infections. 2019 August 6; <https://www.cdc.gov/hiv/basics/livingwithhiv/opportunisticinfections.html>
5. AIDSinfo USDoHaHS. Cryptococcosis – guidelines for the prevention and treatment of opportunistic infections in adults and adolescents with HIV 2019; <https://aidsinfo.nih.gov/guidelines/html/4/adult-and-adolescent-opportunistic-infection/333/cryptococcosis>
6. Murakawa GJ, Kerschmann R, Berger T: Cutaneous *Cryptococcus* infection and AIDS. Report of 12 cases and review of the literature. *Arch Dermatol*, 1996; 132(5): 545–48
7. Dammert P, Bustamante B, Ticona E et al: Treatment of cryptococcal meningitis in Peruvian AIDS patients using amphotericin B and fluconazole. *J Infect*, 2008; 57(3): 260–65
8. Mwaba P, Mwansa J, Chintu C et al: Clinical presentation, natural history, and cumulative death rates of 230 adults with primary cryptococcal meningitis in Zambian AIDS patients treated under local conditions. *Postgrad Med J*, 2001; 77(914): 769–73
9. Pasquier E, Kunda J, De Beaudrap P et al: Long-term mortality and disability in cryptococcal meningitis: A systematic literature review. *Clin Infect Dis*, 2018; 66(7): 1122–32

The fungal organisms are often variable in size, with a thick, refractile-appearing capsule.

Conclusions

We present the case of an 18-year-old man with no evident prior clinical disease presenting with symptoms of fever, nausea, dyspnea, and abdominal pain, which were followed 2 weeks later by diffuse lymphadenopathy. He died shortly thereafter and at autopsy showed disseminated cryptococcal infection and HIV positivity. The time from initial presentation to death was only 16 days. The patient's non-specific symptoms in conjunction with his rapid decline made arriving at a correct diagnosis challenging. Only during autopsy was the disseminated fungal infection discovered, leading to suspicion of HIV infection.

HIV autopsies are not uncommon, but the clinical history is often known beforehand. This case report highlights the importance of considering HIV-related conditions in patients presenting with the discussed array of symptoms. Early diagnosis can greatly improve patient outcomes and alert healthcare providers and staff to the need for increased biosafety precautions. Clinical suspicion of HIV infection should be high for individuals in at-risk groups, as the presentation can be highly variable or atypical.

Conflict of interest

None.