

The Role of Diagnostic Tests in Therapeutic Choices for Gastroesophageal Reflux Disease

E. Croce, S. Olmi, M. Golia, R. Russo

ABSTRACT

Gastroesophageal reflux disease has different clinical presentations that require different diagnostic and therapeutic approaches. This paper describes the appropriate use of diagnostic tests before and after treatment. Each diagnostic tool is examined from a practical point of view to determine the information it can provide and its possible pitfalls, and to comment on how it can influence therapeutic choices. Performing a preoperative diagnostic evaluation is especially stressed, so as not to select the wrong patient or the wrong procedure. Finally, failures of surgery are examined to understand their causes and to prevent them. The value of the most relevant examinations for diagnosing the causes of failures and choosing the appropriate solution are discussed.

Key Words: Gastroesophageal reflux disease (GERD), Esophageal pH monitoring, Esophageal manometry, Antireflux surgery, Laparoscopic fundoplication, Dysphagia.

INTRODUCTION

Everybody has gastroesophageal refluxes, especially after a meal, but they are not very frequent, they rarely last more than 5 minutes, rarely occur at night, the total duration does not exceed about 1 hour a day, and symptoms are absent or occasional. Gastroesophageal reflux disease (GERD) is a very common syndrome, but most patients have mild symptoms, do not seek medical attention, and medicate themselves with antacids when needed. Medical aid is sought when the clinical setting is more important. Of course, the boundaries between disease and "normality" are ill-defined.

Sliding hiatal hernias favor GERD, especially if large, but are not sufficient to provoke it: 80% of hiatal hernias are not associated with GERD, but at least 20% of patients affected with GERD do not have a hiatal hernia.

Only a minority of GERD patients have esophagitis, which occurs mainly if total acid exposure is long, refluxes occur at night and have a long duration due to low esophageal clearance.¹ Symptoms are usually worse if esophagitis is present, but one may have severe symptoms without esophagitis or esophagitis with no symptoms. Sometimes the first symptom is dysphagia caused by stenosis-complicating esophagitis. Patients exist whose symptoms are caused by refluxes that do not exceed upper normality values at pH monitoring. As a matter of fact, symptoms are caused either by pathological refluxes or by abnormal sensitivity of esophageal mucosa, or by both.

MATERIALS AND METHODS

From November 1991 to March 1999, 95 patients had a total fundoplication (Rossetti's procedure); 31 had a posterior 180° fundoplication (Toupet's procedure) because preoperative manometry showed disordered motility of the esophageal body (mean pressure lower than 30 mm of mercury, more than 30% disordered contractions, or both); 16 patients had an anterior 180° fundoplication (Dor's procedure); and 6 had a simple reconstruction of His' angle. These minor antireflux procedures were adopted to prevent GERD after Heller's operation (10 patients) or surgery for paraesophageal hernia (4

1st Department of General and Thoracic Surgery, Center of Laparoscopic and Minimally-Invasive Surgery, Fatebenefratelli and Oftalmico Hospital, Milan, Italy (all authors).

Address reprint request to: Stefano Olmi, MD, Piazza VI Febbraio 22, 20145 Milano, Italy. Telephone: 0039 - 02 - 63632430, Fax: 0039 - 02 - 63632460, E-mail: stefolmi@tin.it

© 2001 by JSLs, *Journal of the Society of Laparoendoscopic Surgeons*. Published by the Society of Laparoendoscopic Surgeons, Inc.

patients), or to correct a mild GERD (and normal HPZ at preoperative manometry) in patients who needed laparoscopic cholecystectomy (3 patients). The preoperative studies included esophago-gastric X-ray, endoscopy, 24 hours pH ambulatory monitoring, and manometry for avoided esophageal disorders. In our experience, the patients with Visick I-II equaled 97.3%.

THE DIAGNOSTIC FLOW CHART (Table 1)

Symptoms of GERD may be “typical” (but they are not specific to GERD), that is, heartburn and regurgitations, or atypical (ear, nose, or throat symptoms, asthma, non-cardiac thoracic pain).

In case of “typical symptoms,” it is commonly agreed that patients younger than 50, with a recent history of GERD and no “alarm symptoms” (dysphagia, loss of weight, hemorrhage, anemia) need no investigation before “ex-

iuvantibus” medication. Alarm symptoms should alert physicians to cancer or complications of esophagitis (ulcer, stenosis). All other patients need endoscopy, as do people who do not respond to medication. Atypical symptoms require endoscopy to be indicated for GERD, but if esophagitis is absent, a diagnosis needs manometry, too. Patients with typical symptoms and normal endoscopy do not need 24 hours pH ambulatory monitoring unless they receive no benefit from medication.

The “omeprazole test,” that is, proton pump inhibitors (PPI) given for 2-4 weeks, is a useful tool for reinforcing the GERD diagnosis. On the contrary, if symptoms are not relieved by PPI, esophagitis is absent, and no significant temporal relationship exists between symptoms and refluxes during pHmetry, even if total esophageal acid exposure is increased, GERD might not be responsible for symptoms. This is important because these patients are usually referred for antireflux surgery.²

Table 1.
Algorithm of GERD Diagnosis.

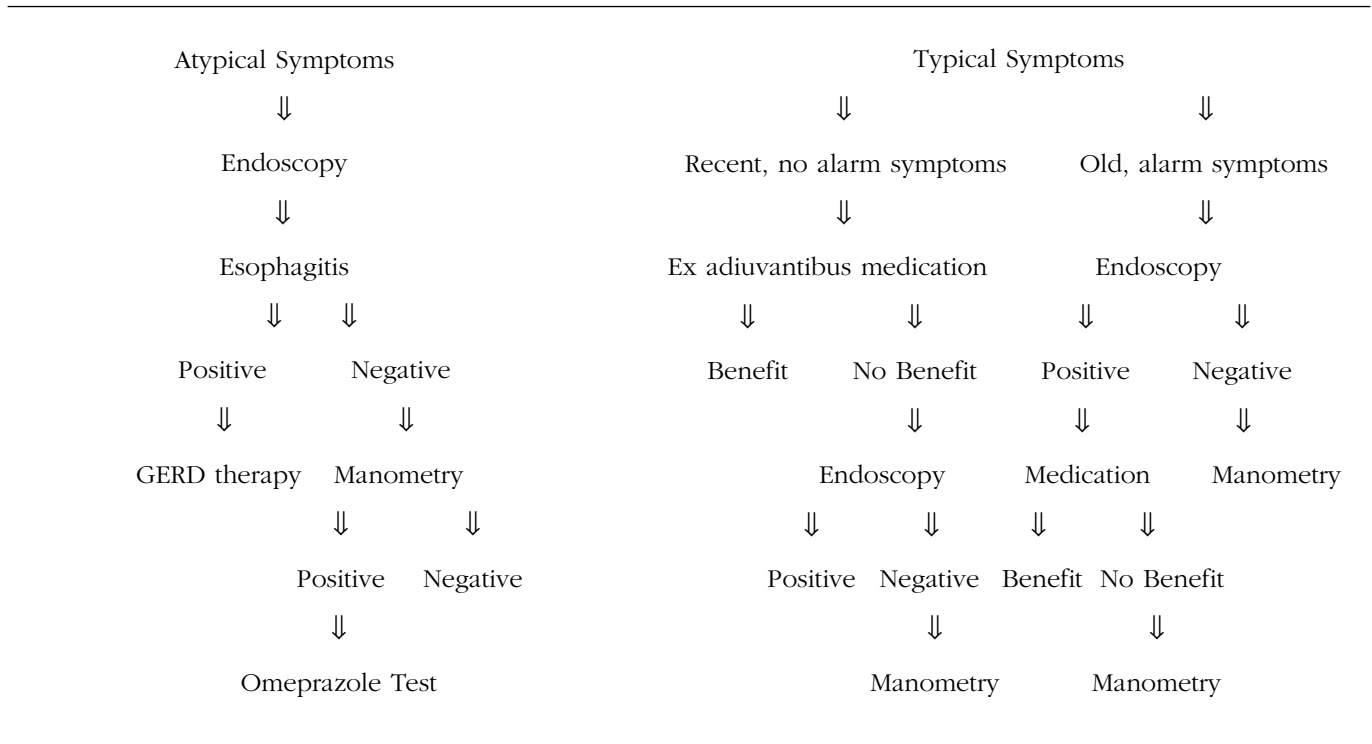


Table 2.

Relationship Between Esophagitis and Treatment.

Absent	Mild	Severe
⇓	⇓	⇓
minor drugs	PPI	PPI (surgery)
⇓	⇓	⇓
endoscopic control only if medication is ineffective		endoscopic control
⇓		⇓
occasional or intermittent treatment (long-term if symptoms recur immediately)		long term treatment with PPI

Table 3.

Treatment and Follow-up of Barrett's Esophagus.

High risk surgical patients: no control
 First histological control after three months of PPI
 No dysplasia: histology every two years
 Mild dysplasia: histology every year
 Moderate dysplasia: histology every six months
 Severe dysplasia: immediate control of dysplasia and esophagectomy if confirmed (endoscopic treatments for high risk patients)

ENDOSCOPY AND HISTOLOGY

Mucosal hyperemia should not be considered esophagitis: first grade inflammation has at least 1 erosion. If no mucosal breaks exist, histology is not useful for diagnosing esophagitis. Confluent erosions characterize second grade esophagitis; the third grade has circumferential erosions, and stenosis, ulcer, or columnar metaplasia are the stigmata of fourth grade inflammation.³

Histology is not needed if erosions are present, but it is necessary in case of ulcer or stenosis, to exclude malignancy, and when Barrett's esophagus is suspected. This clinical condition may not be confirmed or excluded by endoscopy alone.⁴ A histology examination also looks for dysplasia associated with Barrett's mucosa. Three months of proton pump inhibitor use is required to differentiate dysplasia from histological changes due to inflammation. Barrett's esophagus has 10% risk of malignant degeneration,⁵ but only if intestinal metaplasia is present. This is possible also when the gastric lining does not extend more than 3 centimeters above the esophago-gastric junction, as thought before. Even if only a small area of metaplasia is found above the cardia and intestinal metaplasia is present, we have an increased risk of cancer ("short Barrett"). Vital stainings may be useful for detecting metaplastic mucosa, dysplasia, and carcinoma.³

Endoscopy is important in choosing the appropriate treatment for different groups of GERD patients (**Table 2**).

Mild esophagitis is grade 1; severe is grade 2-3-4. All grades of esophagitis require use of proton pump inhibitors for at least 8-12 weeks, and ranitidine or prokinetics, or both of these may be tried for GERD without esophagitis, in association with life style changes, loss of body weight, and correction of other risk factors. Sometimes PPIs are required also for GERD without esophagitis, if minor drugs are ineffective. Endoscopic control is not necessary for all patients. If medication succeeds in controlling symptoms, no endoscopic control is needed in patients with no esophagitis or grade 1 esophagitis, because mucosal healing is the rule and the risk of complications is low. Endoscopic control is suggested if symptoms persist and also in cases of severe esophagitis even if symptoms have subsided, to check mucosal healing.

The most severe esophagitis may be treated with drugs, but surgery is often preferred, even if PPIs are probably as effective as surgery in controlling symptoms and healing esophagitis. In fact, esophageal protection depends on continuous regular lifelong compliance to drugs. Before PPIs were introduced, surgery proved to be more effective than anti-H2 therapy.⁶ Usually GERD is treated with medication, but the role of surgery has increased because minimally invasive procedures have proved to be as effective as open surgery,⁷ and pain and postoperative discomfort are minimal, recovery is fast, and hospitalization is very short. Great surgical expertise is required though. The following are the precise surgical indications: pharmacological treatment is ineffective; compliance to medication is unsatisfactory; continuous medication is needed in young people; regurgitations are

Table 4.

Indications for Long-Term pH-Monitoring.

TO DIAGNOSE GERD: atypical symptoms with negative endoscopy, typical symptoms resistant to medication

PREOPERATIVE

SURGICAL FAILURES

Table 5.

pH-Monitoring: Cutoff Points.

Total time < pH 4: 5%

Upright time < pH 4: 8%

Supine time < pH 4: 3%

Number of reflux episodes: 50

Number of reflux episodes > 5': 3

the main symptom; a large hiatal hernia provokes mechanical symptoms.

Continuous treatment is required if symptoms recur when medication is interrupted and in case of severe esophagitis. These last patients require PPIs. Long-term treatment with PPIs may cause atrophic chronic gastritis if *Helicobacter pylori* is not eradicated. If esophagitis is mild or absent, long-term treatment with anti-H2 must be tried before more powerful acid suppression is adopted. With any drug, the rule is to prescribe the smallest effective dose. Many patients whose symptoms relapse after a period of remission require intermittent therapy, and usually anti-H2 is sufficient. Most patients with occasional symptoms may be treated with antacids only when needed.

Endoscopy and histology are also important in deciding how to treat and control patients with Barrett's mucosa (Table 3).⁸

RADIOLOGY

An upper gastrointestinal (GI) series is recommended as the first-line examination in cases of dysphagia to differentiate organic from functional dysphagia. Small hiatal hernias are revealed by X-rays better than by endoscopy.

Rotational or mixed hernias too are better evaluated by X-rays and should be treated surgically to avoid their frequent and severe complications. An upper GI series is also recommended to any patient indicated for surgery in the following situations: a hiatal hernia that is not self-reducing in the standing position, in a patient with severe long-standing esophagitis, suggesting brachy-esophagus. It helps to differentiate GERD from other esophageal diseases, like achalasia.

pH MONITORING

Indications for 24-hour esophageal pH monitoring are summarized in Table 4. Table 5 shows upper limit values.² The most important parameters are total time and the number of episodes longer than 5 minutes. If 1 of them is abnormal, pH monitoring may be considered positive.⁹ Severe esophagitis is usually associated with severe reflux.

Twenty-four hours pH monitoring is also "positive" in case a statistically significant relationship between refluxes and symptoms is revealed. Some patients have normal values, but their symptoms occur during reflux episodes or within 2 minutes. We may say that they have an "acid hypersensitive esophagus."²

Twenty-four hours pH monitoring is highly specific (false-positives are rare) if the esophageal electrode is correctly positioned 5 centimeters above the high pressure zone (HPZ). Its sensitivity is only 70 to 80%, so a negative examination does not exclude GERD. False-negatives may be due to calibration, wrong electrode positioning, medication, or occasional normality during the examination. Sensitivity is even lower (60 to 70%) in the case of patients with negative endoscopy, that is, when the test would be more useful.²

MANOMETRY

Indications for esophageal manometry are summarized in Table 6. In case of functional dysphagia, this test differentiates nonspecific motor disorders associated with GERD from other esophageal motor disorders, aspecific or specific (achalasia, diffuse esophageal spasm, hypertensive lower esophageal sphincter).

Performance of preoperative manometry is necessary for deciding whether total fundoplication is possible. This procedure is more efficacious than 180° or 270° wraps, but requires efficient esophageal body motility. If disor-

Table 6.
Indications for Manometry.

FUNCTIONAL DYSPHAGIA
NONCARDIAC CHEST PAIN
GERD: preoperative
failures of antireflux surgery

Table 7.
Failures of Antireflux Surgery.

REFLUX: persistent or relapsing
SIDE EFFECTS: dysphagia, gas bloating, others
PERSISTENT SYMPTOMS UNRELATED TO GERD

dered contractions exceed 25% of the total, or their mean pressure is lower than 30 mm Hg, 360° fundoplication is contraindicated, because of the high risk of postoperative persistent dysphagia. An example of such esophageal body disorders is patients affected with scleroderma. These patients may have severe GERD needing surgery, but their severely disordered esophageal motility contraindicates a total fundoplication. Transient dysphagia is common after fundoplications, especially after a total one. Floppy and short 360° wraps have reduced postoperative dysphagia, as short vessel ligation in the opinion of some surgeons. In our experience, short vessel ligation is rarely necessary to obtain a floppy wrap, and postoperative dysphagia did not occur any more when we started selecting patients for total or partial wraps depending on their preoperative manometry. Intraoperative manometry is not necessary for calibrating the wrap in the experience of most surgeons.

GASTRIC SCINTIGRAPHY

Gastric emptying delay is frequently associated with GERD. In rare cases, it is due to a gastrointestinal obstruction, which needs to be removed thus correcting reflux, too. In the vast majority of cases, we find a functional delay in gastric emptying, which is usually ameliorated by antireflux surgery.¹⁰ It is important to differentiate these patients from those with delayed gastric emp-

tying and no GERD, because an antireflux procedure could worsen their symptoms due to postoperative inability to belch and vomit.

Gastric scintigraphy may be helpful for an accurate functional evaluation of patients, but it is poorly standardized, so that at the moment its practical value is not high.

DIAGNOSIS OF ANTIREFLUX FAILURES

Currently the gold-standard surgical treatment for GERD is laparoscopic fundoplication, either a 360° (Nissen, Rossetti) or a 180-270° posterior wrap (Toupet, Lindt).

Failures of antireflux surgery may be classified as in **Table 7**. The third group (“persistent symptoms unrelated to GERD”) includes patients whose symptoms were not due to reflux, so that they persist or worsen after antireflux surgery. In any case, the cause of failures is either a wrong indication (“wrong patient”), a wrong procedure even if well done (“wrong procedure”), or a wrong technique (the patient had a correct surgical indication, the right procedure was chosen, but a faulty technique was performed).

Persistent reflux is due to an inappropriate procedure or wrong technique. For example, reconstruction of His’ angle and the Dor’s procedure may not be sufficient to prevent pathological refluxes. Examples of wrong techniques are disruption of a fundoplication due to absorbable sutures, or sutures under tension, or its slipping because of inadequate esophageal mobilization. Early postoperative reflux is caused by a wrong technique; late reflux is usually due to unavoidable tissue modifications. Diagnosis of persistent or recurrent GERD is usually easy. An upper GI series may reveal upwards migration of the repair (which is usually asymptomatic, but may cause reflux or obstructive dysphagia). Endoscopy may show esophagitis or the absence of the wrap, which is normally evident with the scope in retroflexed position. Twenty-four hours pH monitoring reveals abnormal refluxes, and manometry may show a low value of the high pressure zone (pressure, or length, or both).

Dysphagia is the most important side effect, the “gas bloat syndrome” the most frequent. They are caused by a wrap that hampers esophageal emptying, or belching, or both, and vomiting. The first diagnostic test for postoperative persistent dysphagia (when the cause is not already clear to the surgeon who performed the proce-

dures just by recalling it) is radiology, which usually shows slow esophageal emptying and some degree of dilation, may reveal a slipped wrap, mediastinal herniation of the wrap, para-esophageal herniation,¹¹ or a wrap that was erroneously done with the anterior wall of gastric body rather than the fundus. Endoscopy usually does not add valuable information. Postoperative manometry may be important. It may show a high-pressure zone with abnormally high values (> 40 mm Hg, or > 3 cm, or both). Postoperative manometric values are always high compared with normal values, but they are reduced by 50% one year after the operation: that is why normal early postoperative values of the lower esophageal sphincter are 20 to 40 mm Hg. Abnormally high values are caused by a wrap that is too long, too tight, or both too long and too high, or by mediastinal migration of the wrap that may compress the esophagus above it. In 1 of our patients, manometry revealed a 5-cm long, 30 mm Hg HPZ (too long, not too tight).

Relaparoscopy showed that fundoplication was done with the gastric body. Manometry may also show normal values of the newly established high-pressure zone, but abnormal motility of the esophageal body, which was decompensated by a total fundoplication. Sometimes manometry reveals a specific esophageal motor disorder (achalasia for instance) that was not diagnosed preoperatively. This is 1 of the reasons why manometry should always be performed before antireflux surgery. A certain degree of incomplete relaxation of the newly created HPZ is common, and sometimes it causes dysphagia. De Meester¹² believes it is due to poor mobilization of the fundus. Finally, postoperative manometry may be normal. In these cases, it is not rare that also other tests did not show any abnormality so that only relaparoscopy reveals the cause of dysphagia: distortion due to creation of the wrap with the body rather than the gastric fundus, a tight hiatusplasty, or stenosis of the esophageal hiatus due to postoperative scarring, which Watson and Jamieson¹¹ described as a specific complication of laparoscopic fundoplication together with para-esophageal herniation.

Postoperative persistent dysphagia is usually treated by endoscopic dilation at first, independently from the cause. In case of failure, relaparoscopy is usually performed. The surgical options are the following: a) redo total wrap if it was too long or too tight (use a 60 French bougie for calibration), or it was done with the gastric

body; b) transformation of a total fundoplication to a posterior one (this can be easily done with an endo-GIA) in case of disordered esophageal body motility;¹³ c) transformation to a Heller-Dor's procedure in case of achalasia.^{13,14}

CONCLUSIONS

Gastroesophageal reflux is a very common disorder. Typical symptoms are heartburn, regurgitation and chest pain. Recently, it has been demonstrated that gastroesophageal reflux may generate or worsen extraesophageal symptoms such as asthma, chronic bronchitis, posterior laryngitis, and chronic cough. The diagnosis of gastroesophageal reflux is suggested by typical symptoms which improve under a therapy with proton pump inhibitors. pH monitoring over 24 hours is able to establish directly the diagnosis by measuring acid reflux into the esophagus. Manometry detects the two most common causes of gastroesophageal reflux: insufficiency of the lower esophageal sphincter or esophageal motility abnormalities. Gastroesophageal reflux can lead to reflux esophagitis, which is diagnosed endoscopically. An endoscopy should routinely be performed in case of dysphagia, anemia or loss of weight. A long-term sequela of gastroesophageal reflux is the development of Barrett's esophagus, a condition which has to be verified by endoscopy and biopsy. This premalignant lesion is defined by a metaplastic change from the normal squamous mucosa to a specialized intestinal epithelium characterized by goblet cells. Because dysplasia in these metaplastic areas can lead to esophageal adenocarcinoma, regular endoscopic surveillance with biopsies is recommended. Gastroesophageal reflux can significantly impair the quality of life and can cause complications that include the neoplastic progression from Barrett's esophagus to carcinoma. Therefore, appropriate diagnostic procedures and adequate therapy are required.

Prior to the advent of proton pump inhibitors, internists recommended antireflux surgery primarily for patients whose gastroesophageal reflux disease (GERD) failed to respond to medical therapy. Although many physicians still cling to the notion that antireflux surgery is a procedure best reserved for "medical failures," today this position is inappropriate. Modern medical treatments for GERD are extraordinarily effective in healing reflux esophagitis. It is uncommon to encounter patients with heartburn or esophagitis due to GERD who do not

respond to aggressive antisecretory therapy. Indeed, the very diagnosis of GERD must be questioned for patients whose esophageal signs and symptoms are unaffected by the administration of proton pump inhibitors in high dosages. In the large majority of these so-called refractory patients, protracted esophageal pH monitoring reveals good control of acid reflux by the proton pump inhibitors. This finding indicates that the persistent symptoms usually are not due to acid reflux, but to other problems such as functional bowel disorders. Medical treatment fails in such patients because the diagnosis is mistaken, not because the drugs fail to control acid reflux. Modern antireflux surgery also is highly effective for controlling acid reflux, but fundoplication will not be effective for relieving symptoms in patients whose symptoms are not reflux-induced. Therefore, many patients deemed failures of modern medical therapy would be surgical failures as well. Antireflux surgery is an excellent treatment option for patients with documented GERD who respond well to medical therapy, but who wish to avoid the expense, inconvenience, and the theoretical risks associated with lifelong medical treatment. Ironically, surgical therapy for GERD today is best reserved for patients who are medical successes.

References:

1. Janssens J, Vantrappen G, Peeters TL, Ghillebert G. How do 24 hours pH measurements distinguish the disease spectrum of reflux patients. *Gastroenterology*. 1995;88:1431.
2. Galmiche JP, Scarpignato C. Modern diagnosis of gastroesophageal reflux disease. *Hepatogastroenterology*. 1998;45:1308-1315.
3. Savary M, Miller G. The esophagus. In: Gassmann, Solothurn, eds. *Handbook and Atlas of Endoscopy*. 1977.
4. Gruppo Operativo per lo Studio delle Precancerose Esofagee (G.O.S.P.E.). ed, *L'Esofago di Barrett*. Milano, Segrate: Edizioni Ulisse; 1995.
5. Pera M, Cameron AJ, Trastek VF, Carpenter HA, Zinmeister AR. Increasing incidence of adenocarcinoma of the esophagus and esophagogastric junction. *Gastroenterology*. 1993;104:510-513.
6. Spechler SJ. Comparison of medical and surgical therapy for complicated gastroesophageal reflux disease in veterans. *New Engl J Med*. 1992;326:786-792.
7. Stein HJ, Feussner H, Siewert JR. Anti-reflux surgery: a current comparison of open and laparoscopic approaches. *Hepatogastroenterology*. 1998;45:1328-1338.
8. Baldi F, Crotta S, Penagini R. Linee guida per la gestione diagnostico-terapeutica dei pazienti con malattia da reflusso gastroesofageo. *Giorn Ital End Dig*. 1998;21: 53-60.
9. Vantrappen G. *Disordini della motilità gastrointestinale*. Cortina Int ed. Verona; 1995.
10. Maddern GJ, Jamieson GG. Fundoplication enhances gastric emptying. *Ann Surg*. 1985;210:296-299.
11. Watson DI, Jamieson GG, Devitt PG, Matthew G, Britten-Jones RE, Game PA, Williams RS. Changing strategies in the performance of laparoscopic Nissen fundoplication as a result of experience with 230 operations. *Surg Endosc*. 1995;9:961-966.
12. De Meester TR, Bonavina L, Albertucci M. Nissen fundoplication for gastroesophageal reflux disease. *Ann Surg*. 1986;204:9-20.
13. Croce E, Azzola M, Russo R, Golia M, Olmi S. Laparoscopic reoperation for gastro-esophageal reflux. *Hepatogastroenterology*. 1997;44: 912-917.
14. Croce E, Olmi S, Azzola M, Russo R. Trattamento laparoscopico della malattia da reflusso gastroesofageo: indicazioni, complicanze, insuccessi, reinterventi e risultati. *Osp Ital Chir*. 1998.