



# Ultrasound-Guided Suture Tape Augmentation and Stabilization of the Medial Collateral Ligament

Alan M. Hirahara, M.D., F.R.C.S.C., Gordon Mackay, M.D., F.R.C.S.(Orth), F.F.S.E.M.(UK), and Wyatt J. Andersen, A.T.C.

**Abstract:** Management of medial collateral ligament (MCL) injuries usually consists of time and conservative management; however, patients are typically immobilized and need extensive time to return to sport. Although the MCL has been shown to have the ability to heal given time, surgical management is still sometimes needed to provide stability to the knee. Operative techniques vary in methodology, but are typically highly invasive and technically demanding. In the event of multiligamentous or severe injuries, reinforcing the MCL with an ultrahigh-strength, 2-mm-wide suture tape allows for early functional rehabilitation, permitting the native MCL tissue to heal and avoiding late reconstructions. This technical report details an ultrasound-guided technique for the percutaneous suture tape augmentation and stabilization of the MCL with or without repair. Ultrasound allows for anatomic percutaneous placement of the sockets, as opposed to landmark palpation guidance that has proven to be unreliable. This is a simple, quick procedure that provides instant stability to the MCL with or without operating on the ligament itself, allowing patients to return to activity faster with the reduced risk of reinjury due to less muscle atrophy and loss of function.

**I**nitial management of medial collateral ligament (MCL) injury is typically conservative, requiring extensive time and immobilization to allow for healing. For patients needing to return to activity or sport quickly, this can be unacceptable. Surgical management is considered appropriate after failure of nonoperative care, but is typically highly invasive and technically

demanding. Operative techniques range from repairs to single or double bundle reconstructions using auto- or allografts of the semitendinosus, gracilis, tibialis anterior, and Achilles tendons.<sup>1-10</sup> Both courses of treatment have produced good results.<sup>11-13</sup>

A review of the literature demonstrates a need for a technically easy, minimally invasive surgery to establish stability of the MCL complex. As opposed to most operative procedures that use unreliable landmark palpation to guide anchor placement, this technique uses diagnostic ultrasound to establish the anatomy of the MCL. This Technical Note details an easy, reproducible method of providing instant stability to the MCL with or without repair by using an ultrahigh-strength suture tape augmentation and stabilization, the InternalBrace, to allow for natural healing of the torn tissue with early rehabilitation.

## Surgical Technique

### Patient Setup

The patient is brought to the operating room and placed supine under general anesthesia. A diagnostic arthroscopy can be performed initially if internal derangement is suspected. The knee is brought to 30° flexion and placed in neutral rotation. Instability testing and ultrasound evaluation are performed to evaluate the MCL.

Private Practice (A.M.H., W.J.A.), Sacramento, California, U.S.A.; and School of Sport, University of Stirling (G.M.), Dunblane, Scotland.

The authors report the following potential conflicts of interest or sources of funding: A.M.H. receives consultancy fees from Arthrex, Naples, FL, and Clarius Mobile Health; is a medical advisor for Clarius; has grants/grants pending from Arthrex, Naples, FL (research support); receives royalties from Arthrex, Naples, FL; has stock/stock options in Clarius Mobile Health; and is a medical advisor for Clarius Mobile Health. G.M. is a consultant for teaching for Arthrex; has patent (planned, pending or issued) on InternalBrace; and has royalty agreement with Arthrex, but only relates to InternalBrace kits not the individual components as described in this technique note. Full ICMJE author disclosure forms are available for this article online, as [supplementary material](#).

Received July 8, 2017; accepted August 18, 2017.

Address correspondence to Alan M. Hirahara, M.D., F.R.C.S.C., Private Practice, 2801 K St., 330, Sacramento, CA 95816, U.S.A. E-mail: [ahirahara@sacortho.net](mailto:ahirahara@sacortho.net)

© 2017 by the Arthroscopy Association of North America. Published by Elsevier. This is an open access article under the CC BY-NC-ND license (<http://creativecommons.org/licenses/by-nc-nd/4.0/>).

2212-6287/17846

<https://doi.org/10.1016/j.eats.2017.08.069>

**Table 1.** Pearls/Pitfalls

Pearls	Pitfalls
Use ultrasound to identify the anatomic location of the prospective femoral and tibial anchor sites	Inability to correctly identify anatomy may result in improper anchor placement
Use a spinal needle to mark the location of the tibial socket while passing FiberTape	Must use FiberTape as opposed to FiberWire sutures
Create a plane between 2 incisions with a 90° hemostat	
Use the looped end of the FiberWire suture to pass FiberTape	

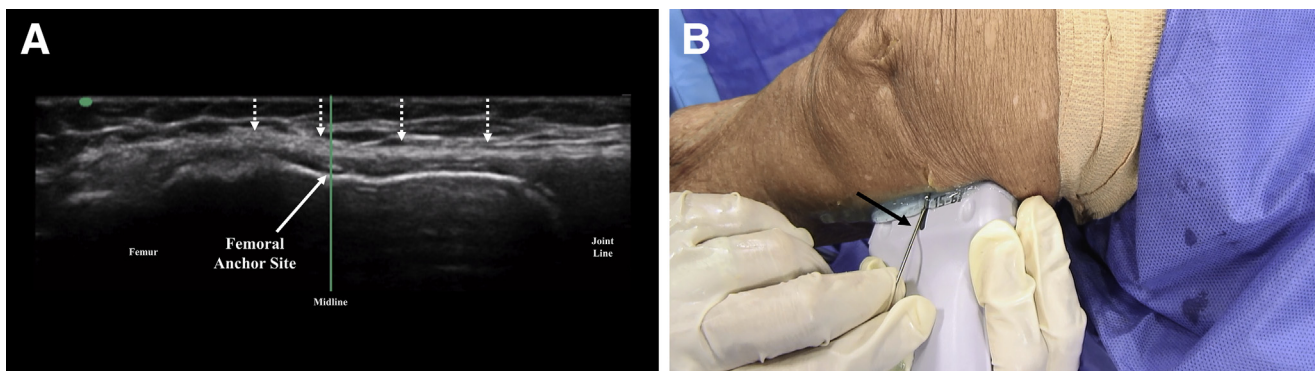
### Femoral Anchor Placement

Diagnostic ultrasound (FUJIFILM SonoSite, Bothell, WA) is used to identify the anatomic locations of the femoral and tibial attachments of the MCL (Video 1). At the tibial aspect, both the superficial and deep aspects of the MCL should be identified. When the femoral attachment site has been found, it should be centered on the midline of the ultrasound transducer (Table 1). A spinal needle is inserted out-of-plane at the center point under the transducer (Fig 1). A small, percutaneous incision is made at the base of the spinal needle down to the bone. A drill sleeve is exchanged for the spinal needle to act as a guide for drilling of the socket (Fig 2). A socket is drilled using a 4.5-mm drill bit. A FiberTape (Arthrex, Naples, FL) is preload to a 4.75-mm BioComposite Vented SwiveLock (Arthrex). The anchor is placed and fixed into the drilled socket (Fig 3). A Kelly clamp is used to ensure that the anchor is flush with the bone (Fig 4). The FiberWire eyelet sutures can be removed from the anchor, while the FiberTape (Arthrex) remains unless repair at the femoral attachment is planned; then the FiberWire is retained.

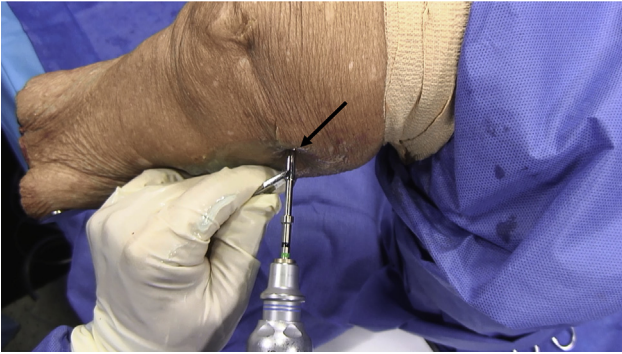
### Tibial Anchor Placement

Once the femoral anchor is placed, diagnostic ultrasound is used to identify the tibial attachment. The

insertion is centered on the ultrasound transducer, and a spinal needle is introduced out-of-plane to the desired fixation point (Fig 5). A percutaneous incision is made at the site of the spinal needle. A drill sleeve replaces the spinal needle, and the socket is created, using a 4.5-mm drill bit. A spinal needle is then placed into the socket to act as a marker for its location (Fig 6). A 90° hemostat is used to establish a plane between the femoral and tibial incisions. The looped end of a FiberWire suture is passed through the tibial incision to the femoral site with the aid of the hemostat (Fig 7). The free end of the FiberTape is passed through the FiberWire loop, and passed through to the tibial site. The FiberTape is attached to a second 4.75-mm BioComposite Vented SwiveLock (Fig 8). The leg is verified to be at 30° of flexion and neutral rotation. The spinal needle is removed, and the anchor is placed and fixed into the tibial socket. Full range of motion (ROM) and isometry can be verified before fully inserting the anchor. Once again, a Kelly clamp is used to ensure that the anchor is fully seated to the bone. The anchor can be measured at the laser line. At this point, the FiberWire eyelet sutures can be removed from the incisions, unless repair at the tibial attachment is desired, in which case the FiberWire would be retained. The remaining FiberTape is cut (Fig 9). This completes the suture tape augmentation and stabilization



**Fig 1.** (A) With the patient placed in a supine position, the right knee at 30° flexion, and at neutral rotation, the medial collateral ligament (MCL) (dashed arrows) and the prospective site of the femoral anchor (solid arrow) are identified on ultrasound. (NOTE. The green line is the midline function on the ultrasound machine. The green dot corresponds to the orientation of the ultrasound transducer.) (B) With the patient placed in a supine position, the right knee at 30° flexion, and at neutral rotation, the spinal needle (solid black arrow) is seen being placed at the femoral attachment of the MCL from an exterior view, corresponding with the ultrasound view. The spinal needle acts as a guide for anatomic socket placement and eventual anchor fixation.



**Fig 2.** With the patient placed in a supine position, the right knee at 30° flexion, and at neutral rotation, the femoral socket is seen being drilled (solid black arrow) from an exterior view.

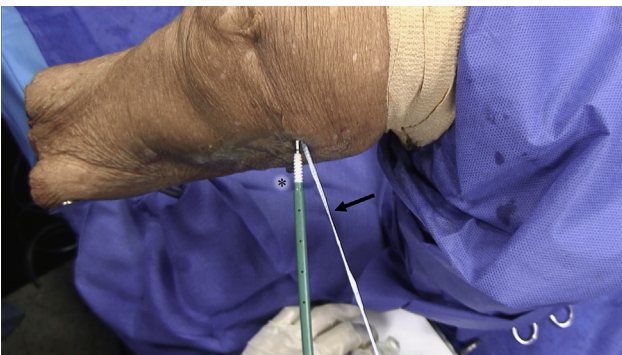
(InternalBrace, Arthrex) of the MCL. Diagnostic ultrasound can be used to confirm the location of the anchors and the presence of the InternalBrace construct.

### Repair of the MCL

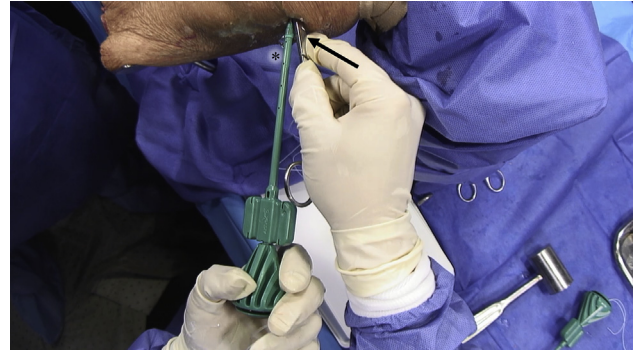Using diagnostic ultrasound to identify the location of the tear of the MCL from either the femoral or tibial attachment, the MCL tear can be repaired at the same time as the stabilization construct. The same technique described above can be used with the FiberWire eyelet suture retained in the SwiveLock anchor at the corresponding side of the tear location (i.e., femoral or tibial side). This suture is then attached to the torn end of the ligament using a Scorpion Suture Passer (Arthrex) and tied down to the anchor. This completes the repair of the MCL.

### Rehabilitation

Rehabilitation following MCL suture tape augmentation and stabilization has changed considerably from



**Fig 3.** With the patient placed in a supine position, the right knee at 30° flexion, and at neutral rotation, a BioComposite Vented SwiveLock (asterisk) can be seen being fixed into the femoral socket from an exterior view. The FiberTape (solid black arrow) attached to the BioComposite Vented SwiveLock will be passed to the tibial site.



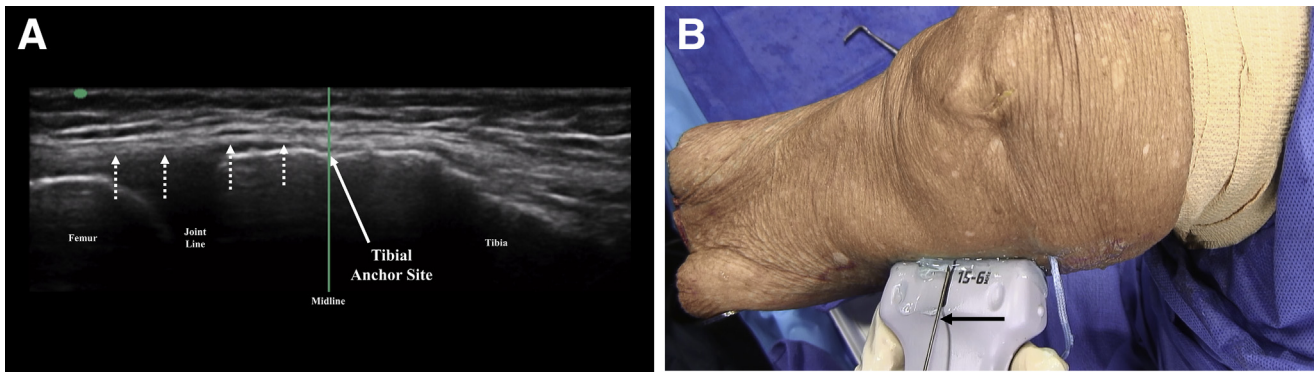
**Fig 4.** With the patient placed in a supine position, the right knee at 30° flexion, and at neutral rotation, the BioComposite Vented SwiveLock (asterisk) and a Kelly clamp (solid black arrow) can be seen from an exterior view. The Kelly clamp is used to ensure that the anchor is fully seated to the bone.

traditional operative MCL protocols. Because of the augmentation and stabilization, we can begin rehabilitation earlier with a focus on passive ROM. There is no longer a need for a knee immobilizer or crutches. The procedure allows for early weight bearing as tolerated and up to 90° of knee flexion within the first 4 to 7 days with full passive ROM by 4 weeks. Crutches are not needed if gait mechanics are adequate. Early physical therapy consists of passive and active ROM as well as closed chain strengthening in the pain-free range. Therapy plays a critical role in proper mechanics and graded supervised activities helping to decrease fear avoidance behaviors seen in knee surgeries. During the strengthening phase, loading is progressive, but deep knee squats are avoided to allow the MCL to heal. Over the next 1 to 3 months, the patient progresses to full strength, lifting, and normal daily activities, but lateral movements are limited as the construct matures and integrates. Return to sports and heavy lifting activities are achieved by 3 to 4 months. Once the patient has met all of the strength, ROM, and functional outcome measures, no brace will be required for return to sport.

### Discussion

The InternalBrace is an ultrahigh-strength suture tape augmentation and stabilization to the MCL that is designed to provide instant medial stability to the knee. Lubowitz et al.<sup>6</sup> have described an open repair technique of the MCL and posteromedial corner with an InternalBrace noting its potential ability to protect patients from secondary injury and to act as a secondary stabilizer. This technique is described with and without repair of the MCL and can be employed in conjunction with reconstructions to allow for healing. The suture tape augmentation and stabilization is appropriate not only for the MCL, but for other ligamentous and tendinous procedures as well.<sup>14-18</sup> Although most methods addressing the MCL are performed as an





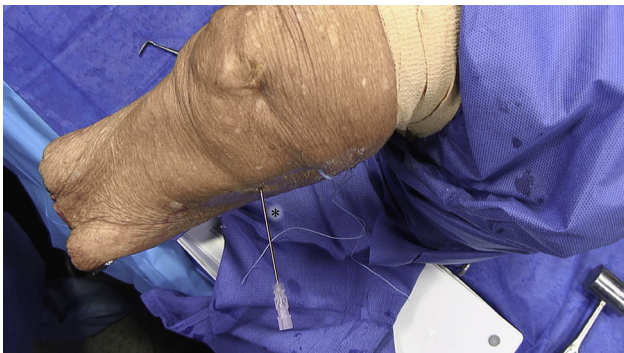**Fig 5.** (A) With the patient placed in a supine position, the right knee at 30° flexion, and at neutral rotation, the medial collateral ligament (dashed white arrows) and the prospective site for the tibial anchor (solid white arrow) are identified. (NOTE. The green line is the midline function on the ultrasound machine. The green dot corresponds to the orientation of the ultrasound transducer.) (B) With the patient placed in a supine position, the right knee at 30° flexion, and at neutral rotation, the spinal needle (solid black arrow) is seen being placed at the site for the tibial anchor from an exterior view, corresponding with the ultrasound view. The spinal needle acts as a guide for anatomic socket placement and eventual anchor fixation.

open procedure, this technique only creates 2 small, percutaneous incisions (Table 2).

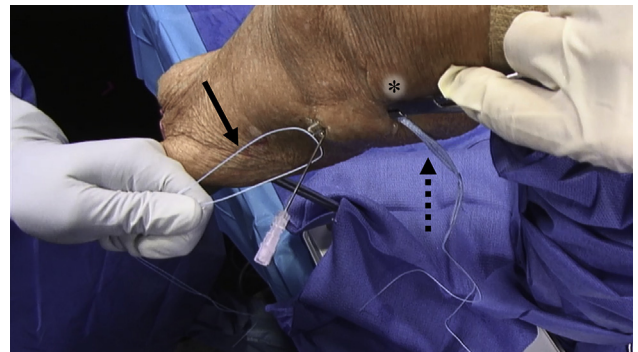
The MCL complex is known to be the primary static stabilizer of the medial knee against valgus and rotational loads.<sup>12,19,20</sup> In their study, examining the static function of the components of the medial knee, Griffith et al.<sup>19</sup> note that damage to 1 division of the MCL may predispose the other portions to injury because of the functional loss of fibers that work synergistically to provide medial knee stability. They advocate for operating on both divisions of the MCL to resolve biomechanical deficiencies seen in isolated or combined injury.<sup>19</sup> With the MCL demonstrating the ability to heal in animal models,<sup>21-23</sup> the suture tape augmentation and stabilization would provide stability to all regions of the MCL while one or multiple attachments try to heal—negating the need for invasive surgical procedures. Most operative techniques use

landmark palpation to guide anchor placement; however, palpation-guided procedures have proven to be inaccurate and unreliable as seen in comparison with ultrasound-guided injections and surgical procedures.<sup>24-32</sup> Using diagnostic ultrasound in this technique enables physicians to establish the anatomy and integrity of the MCL intraoperatively. The simple nature of the procedure makes it an excellent option for surgeons addressing damage to the MCL.

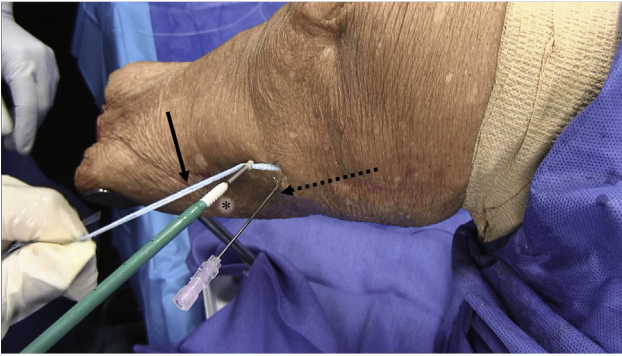
The suture tape augmentation and stabilization is not a reconstruction or repair of the MCL, but rather acts as a backstop, assuming forces that would normally be distributed through the ligament itself. As the MCL has the potential to heal on its own,<sup>21-23</sup> the augmentation and stabilization provides the necessary stability while



**Fig 6.** With the patient placed in a supine position, the right knee at 30° flexion, and at neutral rotation, the spinal needle (asterisk) in the tibial socket is seen from an exterior view. The spinal needle is placed into the socket after it is drilled to act as a marker for the eventual placement of the tibial anchor.

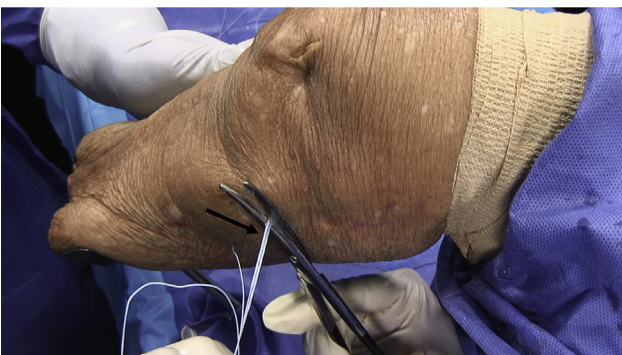

**Fig 7.** With the patient placed in a supine position, the right knee at 30° flexion, and at neutral rotation, the looped end of the FiberWire (solid black arrow) can be seen being passed to the femoral site from an exterior view. A plane is created between the femoral and tibial incisions by a 90° hemostat (asterisk), which is then used to pass the looped end of the FiberWire to the femoral site. The FiberTape (dashed black arrow) is then looped through the FiberWire and passed to the tibial site.



**Fig 8.** With the patient placed in a supine position, the right knee at 30° flexion, and at neutral rotation, the tibial anchor can be seen at the tibial site from an exterior view. The BioComposite Vented SwiveLock (asterisk) attached to the FiberTape (solid arrow) will be fixed into the tibial socket. In this image, the spinal needle (dashed arrow) is sitting in the tibial socket. The spinal needle acts as a marker for the location of the socket, while a plane is established between the 2 incisions and the FiberTape is passed from the femoral anchor. After removal of the spinal needle, the BioComposite Vented SwiveLock can be fixed into position.

the natural healing processes occur. Grade III tears of the MCL, however, do not always heal and can require surgical intervention. In this setting, prolonged immobilization is necessary as a knee lacking medial stability during the early phases of recovery can dispose a patient to failure of the MCL procedure. Augmenting a repair or reconstruction with an ultrahigh-strength suture tape allows patients to begin their rehabilitation earlier without fear of putting the construct at risk. This simple procedure would then allow for natural healing and prevent late reconstruction of the MCL. Because reinforcing the MCL in this way negates the need for immobilization and allows natural healing to take place, patients can



**Fig 9.** With the patient placed in a supine position, the right knee at 30° flexion, and at neutral rotation, the excess FiberTape (solid black arrow) can be seen from an exterior view. Once the tibial anchor has been fixed into position and the FiberWire sutures are removed, the excess FiberTape can be cut. This completes the procedure.

**Table 2.** Advantages/Disadvantages

Advantages	Disadvantages
Provides instant stability to the medial knee	Requires proficiency in diagnostic ultrasound
Can return patients to activity sooner	
Less muscle atrophy and loss of function	
Percutaneous procedure	
Easily reproducible	

return to function and rehabilitation earlier, leading to decreased muscle atrophy and risk of reinjury.

Reider et al.<sup>13</sup> performed a 5-year follow-up study on patients with isolated MCL injuries who took part in early functional rehabilitation with rapid return to sports. They found that the subjective and objective results of their study patients were comparable with those who were operated on and immobilized. Of the 34 study patients, however, 32% (11/34) required more than 35 days to return to their sport and 44% (15/34) reported needing 2 or more months to fully recover.<sup>13</sup> In the example of American football players, these time frames represent a significant portion of their competitive season. Although time and bracing has been shown to work, athletes in particular need to return to their sport quickly. Our technique is a simple, quick procedure that provides instant stability to the MCL. The suture tape augmentation and stabilization allows patients to regain movement and begin rehabilitation quickly, limiting loss of function and leading to better results.

The attachments of the MCL, both proximally and distally, are quite broad.<sup>12,19,20</sup> As the ligament travels distally from its femoral attachment, it bifurcates to distinct superficial and deep insertions.<sup>12,19,20</sup> Using diagnostic ultrasound, surgeons can visualize the breadth of these attachments to determine placement of the anchors. In this technique, we aim to center the broad femoral attachment for the femoral anchor and center the deep insertion at the tibia for the tibial anchor. We chose to use the deep attachment at the tibia, as opposed to the superficial attachment, because the superficial insertion is much more distal and broad. With no biomechanical data on the effects of varying anchor placement for augmentation, it is hard to determine the best location for fixation. Optimal positioning of anchors for the given attachments of this ultrahigh-strength suture tape augmentation and stabilization with or without repair of the MCL should be the focus of future research, along with clinical outcomes of patients who undergo this procedure. Although the need for continued analyses exists, the ultrahigh-strength suture tape augmentation and stabilization of the MCL procedure is appropriate, beneficial, and should be considered by surgeons assessing MCL injury.



## References

- Deo S, Getgood A. A technique of superficial medial collateral ligament reconstruction using an adjustable-loop suspensory fixation device. *Arthrosc Tech* 2015;4:e261-e265.
- Dong JT, Chen BC, Men XQ, et al. Application of triangular vector to functionally reconstruct the medial collateral ligament with double-bundle allograft technique. *Arthroscopy* 2012;28:1445-1453.
- Feeley BT, Muller MS, Allen AA, Granchi CC, Pearle AD. Biomechanical comparison of medial collateral ligament reconstructions using computer-assisted navigation. *Am J Sports Med* 2009;37:1123-1130.
- Koga H, Muneta T, Yagishita K, Ju YJ, Sekiya I. Surgical management of grade 3 medial knee injuries combined with cruciate ligament injuries. *Knee Surg Sports Traumatol Arthrosc* 2012;20:88-94.
- Lind M, Jakobsen BW, Lund B, Hansen MS, Abdallah O, Christiansen SE. Anatomical reconstruction of the medial collateral ligament and posteromedial corner of the knee in patients with chronic medial collateral ligament instability. *Am J Sports Med* 2009;37:1116-1122.
- Lubowitz JH, MacKay G, Gilmer B. Knee medial collateral ligament and posteromedial corner anatomic repair with internal bracing. *Arthrosc Tech* 2014;3:e505-e508.
- Marx RG, Hetsroni I. Surgical technique: Medial collateral ligament reconstruction using Achilles allograft for combined knee ligament injury. *Clin Orthop Relat Res* 2012;470:798-805.
- Prince MR, Blackman AJ, King AH, Stuart MJ, Levy BA. Open anatomic reconstruction of the medial collateral ligament and posteromedial corner. *Arthrosc Tech* 2015;4:e885-e890.
- Serra Cruz R, Olivetto J, Dean CS, Chahla J, LaPrade RF. Superficial medial collateral ligament of the knee: Anatomic augmentation with semitendinosus and gracilis tendon autografts. *Arthrosc Tech* 2016;5:e347-e352.
- Yoshiya S, Kuroda R, Mizuno K, Yamamoto T, Kurosaka M. Medial collateral ligament reconstruction using autogenous hamstring tendons: Technique and results in initial cases. *Am J Sports Med* 2005;33:1380-1385.
- Holden DL, Eggert AW, Butler JE. The nonoperative treatment of grade I and II medial collateral ligament injuries to the knee. *Am J Sports Med* 1983;11:340-344.
- Marchant MH Jr, Tibor LM, Sekiya JK, Hardaker WT Jr, Garrett WE Jr, Taylor DC. Management of medial-sided knee injuries, part 1: Medial collateral ligament. *Am J Sports Med* 2011;39:1102-1113.
- Reider B, Sathy MR, Talkington J, Blyznak N, Kollias S. Treatment of isolated medial collateral ligament injuries in athletes with early functional rehabilitation: A five-year follow-up study. *Am J Sports Med* 1993;22:470-477.
- Cho BK, Park KJ, Kim SW, Lee HJ, Choi SM. Minimal invasive suture-tape augmentation for chronic ankle instability. *Foot Ankle Int* 2015;36:1330-1338.
- Cho BK, Park KJ, Park JK, SooHoo NF. Outcomes of the modified Broström procedure augmented with suture-tape for ankle instability in patients with generalized ligamentous laxity. *Foot Ankle Int* 2017;38:405-411.
- McWilliam JR, Mackay G. The internal brace for mid-substance Achilles ruptures. *Foot Ankle Int* 2016;37:794-800.
- Schuh R, Benca E, Willegger M, et al. Comparison of Broström technique, suture anchor repair, and tape augmentation for reconstruction of the anterior talofibular ligament. *Knee Surg Sports Traumatol Arthrosc* 2016;24:1101-1107.
- Smith PA, Bley JA. Allograft anterior cruciate ligament reconstruction utilizing internal brace augmentation. *Arthrosc Tech* 2016;5:e1143-e1147.
- Griffith CJ, LaPrade RF, Johansen S, Armitage B, Wijdicks C, Engebretsen L. Medial knee injury: Part I, static function of the individual components of the main medial knee structures. *Am J Sports Med* 2009;37:1762-1770.
- LaPrade RF, Engebretsen AH, Ly TV, Wentorf FA, Engebretsen L. The anatomy of the medial part of the knee. *J Bone Joint Surg Am* 2007;89:2000-2010.
- Lechner CT, Dahners LE. Healing of the medial collateral ligament in unstable rat knees. *Am J Sports Med* 1991;19:508-512.
- Sparrow KJ, Finucane SD, Owen JR, Wayne JS. The effects of low-intensity ultrasound on medial collateral ligament healing in the rabbit model. *Am J Sports Med* 2004;33:1048-1056.
- Woo SLY, Inoue M, McGurk-Burleson E, Gomez MA. Treatment of the medial collateral ligament injury. Part II: Structure and function of canine knees in response to differing treatment regimens. *Am J Sports Med* 1987;15:22-29.
- Henkus HE, Cobben LP, Coerkamp EG, Nelissen RG, van Arkel ER. The accuracy of subacromial injections: A prospective randomized magnetic resonance imaging study. *Arthroscopy* 2006;22:277-282.
- Hirahara AM, Andersen WJ. Ultrasound-guided percutaneous reconstruction of the anterolateral ligament: Surgical technique and case report. *Am J Orthop (Belle Mead NJ)* 2016;45:418-460.
- Hirahara AM, Andersen WJ. Ultrasound-guided percutaneous repair of medial patellofemoral ligament: Surgical technique and outcomes. *Am J Orthop* 2017;46:152-157.
- Hirahara AM, Panero AJ. A guide to ultrasound of the shoulder, part 3: Interventional and procedural uses. *Am J Orthop* 2016;45:440-445.
- Jackson DW, Evans NA, Thomas BM. Accuracy of needle placement into the intra-articular space of the knee. *J Bone Joint Surg Am* 2002;84:1522-1527.
- Naredo E, Cabero F, Beneyto P, et al. A randomized comparative study of short term response to blind versus sonographic-guided injection of local corticosteroids in patients with painful shoulder. *J Rheumatol* 2004;31:308-314.
- Panero AJ, Hirahara AM. A guide to ultrasound of the shoulder, part 2: The diagnostic evaluation. *Am J Orthop* 2016;45:233-238.
- Sibbit WL Jr, Peisajovich A, Michael AA, et al. Does sonographic needle guidance affect the clinical outcome of intraarticular injections? *J Rheumatol* 2009;36:1892-1902.
- Yamakado K. The targeting accuracy of subacromial injection to the shoulder: An arthrographic evaluation. *Arthroscopy* 2002;18:887-891.