

# Selective Bilateral Vestibular Neuropathy in a Turkish CMT1B Family With a Novel *MPZ* Mutation

Gülden Akdal, MD, Koray Koçoğlu, MSc, Elçin Bora, MD, PhD, Altuğ Koç, MD, PhD, Ayfer Ülgenalp, PhD, Mithat Bedir, MD, Rahmi Tümay Ala, MD, Esra Battaloğlu, PhD, Günay Kırkım, PhD, İhsan Şükür Şengün, MD, and Gábor Michael Halmágyi, MD

**Correspondence**  
Dr. Halmágyi  
gmh@icn.usyd.edu.au

*Neurology: Clinical Practice* April 2021 vol. 11 no. 2 e129-e134 doi:10.1212/CPJ.0000000000000930

## Abstract

### Purpose of Review

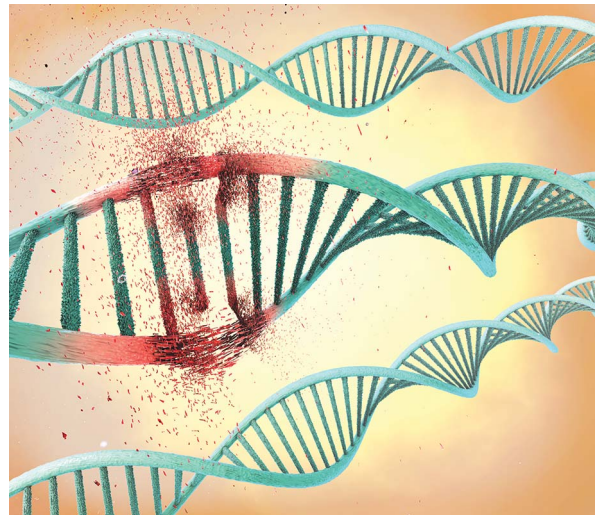
To report the findings in 12 members over 3 generations of a family with dominantly inherited Charcot-Marie-Tooth disease (CMT1B) due to a novel *MPZ* mutation, who all had moderately severe selective impairment of vestibular function with normal hearing. Methods used were video head impulse testing of the function of all 6 semicircular canals, Romberg test on foam, nerve conduction studies, and whole exome and Sanger sequencing.

### Recent Findings

All affected patients had a demyelinating neuropathy and a novel *MPZ* mutation: c.362A>G (chr1: 161276584, p.D121G). All also had normal hearing for age but a moderately severe impairment of semicircular canal function and a positive Romberg test on foam.

### Summary

Some CMT mutations can impair vestibular function, presumably because of a vestibular nerve involvement but spare hearing. In such patients, impairment of vestibular function and impairment of proprioception contribute to imbalance.



Although some patients with Charcot-Marie-Tooth disease (CMT) have obvious hearing impairment from auditory nerve involvement, vestibular impairment will not be obvious because the patient already has imbalance from distal weakness and somatosensory impairment.<sup>1,2</sup> Some patients with CMT—CMT1B/*MPZ*<sup>3</sup> have only auditory impairment, whereas others—CMT4C/*H3TC2*<sup>4,5</sup> or CMT4D/*NDRG1*<sup>6</sup>—have severe, early impairment of both auditory and vestibular function. Here, we report 12 members in 3 generations of a Turkish family with CMT1B demyelinating neuropathy due to a novel *MPZ* mutation, who have selective bilateral vestibular impairment with normal hearing. In some, vestibular rather than proprioceptive impairment seems the principal cause of postural instability.

Department of Neurology (GA, RTA, İŞŞ) and Department of Neurosciences (GA, KK), Institute of Health Sciences, Department of Medical Genetics (E. Bora, AK, AÜ), Dokuz Eylül University, İzmir, Turkey; Department of Neurology (MB), Mardin State Hospital, Mardin, Turkey; Department of Molecular Biology and Genetics (E. Battaloğlu), Boğaziçi University, Istanbul, Turkey; Hearing, Speech and Balance Unit (GK), Department of Otorhinolaryngology, Dokuz Eylül University, İzmir, Turkey; and Department of Neurology (GMH), Royal Prince Alfred Hospital, University of Sydney, Australia.

Funding information and disclosures are provided at the end of the article. Full disclosure form information provided by the authors is available with the full text of this article at [Neurology.org/cp](https://www.neurology.org/cp).

The Article Processing Charge was funded by the authors.

This is an open access article distributed under the terms of the Creative Commons Attribution-NonCommercial-NoDerivatives License 4.0 (CC BY-NC-ND), which permits downloading and sharing the work provided it is properly cited. The work cannot be changed in any way or used commercially without permission from the journal.

## Methods

### Genetic Testing

#### Sample Collection and DNA Extraction

Minimum 3 mL of peripheral blood was collected in ethylenediaminetetraacetic acid. The DNA extraction was performed by the commercial QIAcube method (Qiagen, Hilden, Germany) according to the recommended extraction and purification protocols. The DNA was stored  $-20^{\circ}\text{C}$ .

#### Fragment Analysis for HNPP by STR Markers

The index case (IV.3) was tested for 17p11.2–12 duplication by fragment analysis.

#### Multiplex Ligation-Dependent Probe Amplification

The multiplex ligation-dependent probe amplification (MLPA) assay was used for 4 family members (III.6, IV.4, IV.3, and V.2). The DNA samples were investigated by SALSA MLPA Probeset P033-B4 CMT1 (MRC-Holland, Holland), which contains 38 probes specific for *PMP22*, *KIF1b* genes, and control regions according to the producer's recommendations.

#### Whole Exome Sequencing

The DNA of index case was studied by whole exome sequencing (WES), and a novel, heterozygous variation of *MPZ* gene (ENST00000533357.4) was found: c.362A>G (chr1: 161276584, p.N121G), confirmed by Sanger sequencing. The variation is classified as likely pathogenic according to the ACMG criteria.<sup>7</sup>

#### Sanger Sequencing

Conventional Sanger sequencing was used for the confirmation of *MPZ* c.362A>G variation and for screening family members (III.6, IV.3, IV.4, IV.8, IV.9, V.1, V.2, and V.5).

#### Vestibular Testing

Function of each semicircular canal (SCC) was tested in turn by measuring the vestibulo-ocular reflex (VOR) gain in response to rapid, passive, head accelerations in the plane of each SCC—the Head Impulse Test (GN Otometrics, Tastrup, Denmark).<sup>8</sup> The test assesses both VOR gain and any catch-up saccades compensating for low VOR gain.

#### Balance Testing

In the modified Romberg test, the patient first stands on a firm surface (the floor) and then on a foam surface, with eyes open and then closed. Postural stability is observed for 30 seconds. Sway is graded as follows: 1 = minimal, 2 = mild, 3 = moderate, and 4 = potential fall.<sup>9</sup>

The study was approved by the Hospital's institutional review board. Each adult patient and the parent of each child gave written permission for testing and for publication of the results.

## Results

### Clinical Features

The initial problem was imbalance, starting in infancy in 7.<sup>10</sup> All except 3 (V.1, V.12, and V.13) had pes cavus; 4 with pes

cavus (IV.5, V.5, V.6, and V.7) also had hammer toes. None had appreciable weakness. All those old enough for reliable sensory testing had distal impairment of vibration sense in the lower limbs. None had lower limb tendon reflexes. None had symptomatic hearing loss; 3 (III.6, IV.3, and IV.10) had audiograms—all 3 normal for age.

### Nerve Conduction Studies

Of the 12 mutation-positive patients tested (table), 11 had marked slowing of motor conduction (10–26 m/s) and also of sensory conduction (20–28 m/s) in the 5 patients (IV.3, IV.8, IV.9, V.1, and V.12) with sensory action potentials.

### Vestibular Function

Every patient had some impairment of SCC function in one or more canals. There appeared to be no association of extent or severity with patient age (table). The oldest patient (III.6) had impairment of all 6 SCCs (figure 1), whereas the youngest (V.7) who could have 6 SCC testing had impairment of 4 SCCs. In all patients, the SCC impairment was bilateral and of moderate severity with gains of 0.57–0.85 for the lateral canals (normal >0.85), 0.46–0.80 (normal >0.80) for the anterior canals, and 0.30–0.70 for the posterior canals (normal >0.70).

### Balance

Of the 12 patients, 9 attempted Romberg testing. On a firm surface, all 9 could stand with eyes open, but 5 (III.6, IV.3, IV.5, IV.9, and IV.10) could not do so with eyes closed—i.e., these 5 had a positive firm Romberg test, indicating proprioceptive impairment. On a foam surface, 5 (IV.3, IV.8, IV.9, IV.10, and V.5) could stand with eyes open but not with eyes closed—i.e., these 5 had a positive foam Romberg test, indicating vestibular impairment. Of the 9 patients, 5 (III.6, IV.3, IV.5, IV.9, and IV.10) had positive firm and foam Romberg tests, indicating that both somatosensory and vestibular impairment contributed to their imbalance.<sup>9</sup>

### Family Tree and Genetics

The index case (IV.3) has a consanguineous marriage with a fourth degree relative, the only consanguineous marriage in the family (figure 2). There is no other genetic disorder in the family. The results of specific fragment analysis targeting for HNPP-related 17p11.2–12 deletion and MLPA analysis for *PMP22* are all normal. The WES analysis identified *MPZ* c.362A>G (chr1: 161276584, p.D121G) variation. Sanger sequencing confirmed the presence of heterozygous *MPZ* c.362A>G variation in the index case (IV.3) and was used for screening of other family members. The variation was also found in the index case's mother (III.6), son (V.1), brothers (IV.5 and IV.10), sisters (IV.8 and IV.9), and nephews (V.5, V.6, V.7). They all have polyneuropathy. Cosegregation of the variation and the disorder is revealed in the family. Therefore, the variation is considered as likely pathogenic according to the ACMG criteria: PS4, PM1, PM2, and PP3.<sup>7</sup> This result was confirmed in the index case (IV.3) at an independent laboratory.

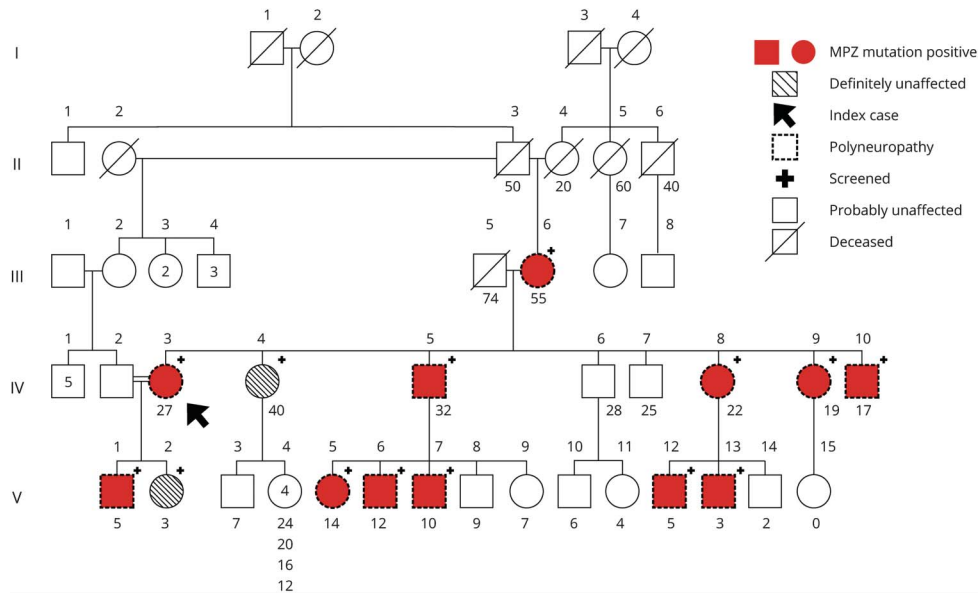
**Table** Nerve Conduction, Head Impulse, and Romberg Test Results

Generation degree (gender, age)	Nerve conduction studies						VOR gain						Romberg test score			
	Ulnar motor			Ulnar sensory			Lateral canal; normal >0.85		Anterior canal; normal >0.80		Posterior canal; normal >0.70		Firm		Foam	
	Amplitude, mV	Latency, ms	Velocity, m/s	Amplitude, $\mu$ V	Latency, ms	Velocity, m/s	Left	Right	Left	Right	Left	Right	EO	EC	EO	EC
<b>Affected</b>																
III.6 (F, 55)	5.4	4	21.6	0	0	0	<b>0.75 s</b>	<b>0.67 s</b>	<b>0.56 s</b>	<b>0.46</b>	<b>0.30</b>	<b>0.58 s</b>	3	4	4	4
IV.3 (F, 27)	6.5	4.0	22.3	10	4.1	28	<b>0.57 s</b>	<b>0.57 s</b>	<b>0.74 s</b>	<b>0.71 s</b>	<b>0.48 s</b>	<b>0.46 s</b>	2	4	3	4
IV.5 (M, 32)	6.7	4.1	20	0	0	0	<b>0.85 s</b>	0.90 s	0.86	<b>0.80</b>	<b>0.55 s</b>	<b>0.49 s</b>	2	4	4	4
IV.8 (F, 22)	8.3	3.9	18.2	6.5	4.7	23.4	<b>0.79 s</b>	<b>0.69 s</b>	1.02 s	1.26	0.82 s	0.76 s	1	3	2	4
IV.9 (F, 19)	3.8	3.9	25.9	16.2	4.2	25.3	<b>0.70 s</b>	<b>0.76 s</b>	<b>0.64</b>	<b>0.79</b>	<b>0.56 s</b>	<b>0.62</b>	1	4	2	4
IV.10 (M, 17)	4.7	5.5	21	0	0	0	0.87 s	0.96 s	<b>0.51</b>	0.92	<b>0.62</b>	<b>0.62</b>	1	4	2	4
V.1 (M, 5)	5.9	4.2	10.1	4.9	3.8	19.7	<b>0.81</b>	<b>0.81</b>								
V.5 (F, 14)	6.7	4.7	22	0	0	0	<b>0.72 s</b>	<b>0.71 s</b>	0.85	1.07	<b>0.66 s</b>	<b>0.62 s</b>	1	1	2	4
V.6 (M, 12)	3.3	3.5	20	0	0	0	0.86 s	0.89 s	<b>0.76</b>	<b>0.67</b>	<b>0.65</b>	<b>0.70</b>	1	1	4	4
V.7 (M, 10)	5.1	3.5	21	0	0	0	<b>0.66 s</b>	0.85 s	<b>0.80</b>	<b>0.76</b>	<b>0.62</b>	<b>0.66 s</b>	1	1	4	4
V.12 (M, 5)	3.6	3.1	21.2	8.2	2.9	24.1	<b>0.78</b>	0.86								
<b>Unaffected</b>																
IV.4 (F, 40)							1.05	1.26	<b>0.67</b>	1.00	0.84	<b>0.60</b>	1	1	1	1
V.2 (F, 3)							<b>0.83</b>	0.88					1	1	1	1

Abbreviations: EC = eyes closed; EO = eyes open; SCC = semicircular canal; VOR = vestibulo-ocular reflex.

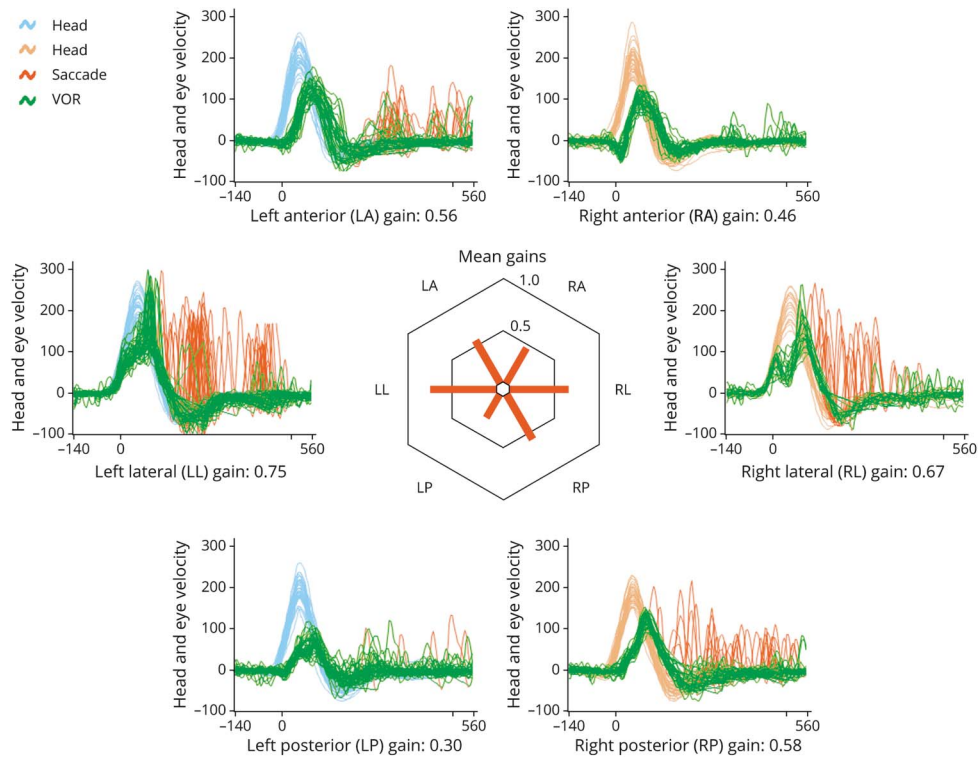
Motor and sensory conduction velocities are all in the demyelinating range. With EC, none of the patients could stand on foam. The deficits in VOR gain are shown in bold. Catch-up saccades (s) can be a confirmatory sign of VOR deficit but are not always present, even when the VOR is defective. In 2 patients (III.6 and IV.9), VOR from all 6 canals were defective. In the others, there was no obvious pattern as to which canals were involved and which were not. Patient V.1 (age 5) could cooperate only with lateral SCC canal testing.

**Figure 1** Family Tree



Each clinically affected patient is also electrophysiologically affected (indicated by dotted symbols) and is *MPZ* mutation positive (indicated by crimson shading and a plus sign "+"). Conversely, each *MPZ* mutation-positive patient is clinically and electrophysiologically affected. Patient IV.4 (unaffected) has 5 unaffected children; only the youngest (age 4) is indicated with a symbol; the ages of the other 4 are appended. The only exception is patient V.13, a clinically affected, *MPZ*-positive 3 years old, too young to cooperate with electrophysiologic or vestibular testing. The arrow indicates index case.

**Figure 2** Video Head Impulse Testing



A typical example, from patient III.6, a woman aged 55. Vestibulo-ocular reflex (VOR) gain is reduced from each of the 6 semicircular canals (SCCs). Head velocity is shown in blue for 30 leftward head impulses and in orange for 30 rightward head impulses in the plane of each SCC. VOR eye velocity is shown in green. Catch-up saccades compensating for any VOR inadequacy are shown in red. This patient happens to make fewer catch-up saccades in response to head impulses in the right anterior-left posterior canal plane. In the centre of the figure, VOR gains are illustrated as a polar plot.

## Discussion

CMT1B is a hereditary demyelinating neuropathy due to one of more than 200 possible mutations in the *MPZ* gene. In patients with early onset disease, the neuropathy is demyelinating.<sup>11</sup> In this family with a novel *MPZ* mutation (exon 3, c.362A>G; p.D121G), there was a contrast between the invariable vestibular impairment and the normal hearing. All our patients had bilateral impairment of SCC function affecting some but not all SCCs. There was no relationship between the patient age and vestibular impairment severity, suggesting that the vestibular impairment is static.

Poretti et al.<sup>1</sup> reported bilateral vestibular impairment affecting both otolith function (tested with cervical vestibular-evoked myogenic potentials) and lateral SCC function (tested with head impulses using the scleral search coil method) in 15 patients with CMT. Of these 15, 13 had a demyelinating neuropathy, 4 had CMT1A (*PMP22* dupl), 3 had CMTX1 (*GJB1x32*), one each had DI-CMT (*MPZ*), CMT2 (undef), CMT4D (undef), and 5 had clinically and genetically undefined CMT but a positive family history. In general, video Head Impulse Test gains were reduced and cervical vestibular evoked myogenic potential latency was increased; findings suggesting that these patients had a demyelinating vestibular and peripheral neuropathy. Of these 15 patients, 6 had auditory and vestibular impairment. In Dejerine-Sottas syndrome (motor conduction velocity 3–4 m/s) because of a T420C mutation predicting an L71P amino acid change of *PMP22* protein, there can be total bilateral absence of lateral SCC canal function and a 40–50 dB sensorineural hearing loss.<sup>12</sup>

Although we cannot distinguish vestibular end-organ from vestibular nerve involvement causing vestibular impairment, physiologic and histologic data indicate that vestibular nerve demyelination is the cause. The marked delay in cVEMPs suggests demyelination.<sup>1</sup> Otopathologic examination of 2 separate CMT1A/*MPZ* cases showed extensive demyelination of the vestibular and cochlear nerves with preservation of receptor hair cells. In one case with a heterozygous missense variant in exon 2 of the *MPZ* gene (c.193A>G; p.Thr65Ala), both auditory and vestibular function were impaired.<sup>13</sup> In the other with a missense mutation in exon 3 of the *MPZ* gene (c.434A>C; p.Tyr145Ser), neither auditory or vestibular function was evaluated.<sup>14</sup>

## Study Funding

This work was funded by the Scientific and Technological Research Council of Turkey (TÜBİTAK) under Grant Number (216S658). The content is merely the responsibility of the authors and does not necessarily represent the views of TÜBİTAK.

## Disclosure

G. Akdal, K. Koçoğlu, E. Bora, A. Koç, A. Ülgenalp, M. Bedir, R.T. Ala, E. Battaloğlu, G. Kırkım, and İ.Ş. Şengün

## TAKE-HOME POINTS

- Clinicians should consider a vestibular contribution to patients with CMT imbalance.
- Video head impulse testing can accurately measure function of each of the 6 semicircular canals.
- It is well tolerated and takes only approximately 20 minutes.

report no disclosures. G.M. Halmágyi was formerly unpaid consultant to GN Otometrics for the development of video head impulse testing. Full disclosure form information provided by the authors is available with the full text of this article at [Neurology.org/cp](http://Neurology.org/cp).

## Publication History

Received by *Neurology: Clinical Practice* December 19, 2019. Accepted in final form April 23, 2020.

## Appendix Authors

Name	Location	Contribution
<b>Gülden Akdal, MD</b>	Dokuz Eylül University, Izmir, Turkey	Design and conceptualization of the study and drafting intellectual content of manuscript
<b>Koray Koçoğlu, MSc</b>	Dokuz Eylül University, Izmir, Turkey	Data collection, analysis, and presentation
<b>Elçin Bora, MD, PhD</b>	Dokuz Eylül University, Izmir, Turkey	Genetic testing and analysis
<b>Altuğ Koç, MD, PhD</b>	Dokuz Eylül University, Izmir, Turkey	Genetic testing and analysis
<b>Ayfer Ülgenalp, PhD</b>	Dokuz Eylül University, Izmir, Turkey	Genetic testing and analysis
<b>Mithat Bedir, MD</b>	Mardin State Hospital, Mardin, Turkey	Clinical and neurophysiologic evaluation
<b>Rahmi Tümay Ala, MD</b>	Dokuz Eylül University, Izmir, Turkey	Clinical and neurophysiologic evaluation
<b>Esra Battaloğlu, PhD</b>	Boğaziçi University, Istanbul, Turkey	Genetic testing and analysis
<b>Günay Kırkım, PhD</b>	Dokuz Eylül University, Izmir, Turkey	Audiological evaluation
<b>İhsan Şükrü Şengün, MD</b>	Dokuz Eylül University, Izmir, Turkey	Clinical and neurophysiologic evaluation
<b>Gábor Michael Halmágyi, MD</b>	Royal Prince Alfred Hospital, Sydney, Australia	Design and conceptualization of study and drafting intellectual content of manuscript

## References

1. Poretti A, Palla A, Tarnutzer AA, et al. Vestibular impairment in patients with Charcot-Marie-tooth disease. *Neurology* 2013;80:2099–2105.
2. Akdal G, Koçoğlu K, Tanriverdizade T, et al. Vestibular impairment in Charcot-Marie-Tooth disease. *J Neurol Epub* 2020 Aug 30.
3. Duan X, Gu W, Hao Y, et al. A Novel Asp121Asn mutation of myelin protein zero is associated with late-onset axonal Charcot-Marie-Tooth disease, hearing loss and pupil abnormalities. *Front Aging Neurosci* 2016;8:222.
4. Pérez-Garrigues H, Sivera R, Vilchez JJ, Espinós C, Palau F, Sevilla T. Vestibular impairment in Charcot-Marie-Tooth disease type 4C. *J Neurol Neurosurg Psychiatry* 2014;85:824–827.
5. Sivera R, Cavalle L, Vilchez JJ, Espinós C, Pérez Garrigues H, Sevilla T. Audiological findings in Charcot-Marie-Tooth disease type 4C. *J Int Adv Otol* 2017;13:93–99.
6. Dačković J, Keckarević-Marković M, Komazec Z, et al. Hereditary motor and sensory neuropathy Lom type in a Serbian family. *Acta Myol* 2008;27:59–62.
7. Richards S, Aziz N, Bale S, et al. Standards and guidelines for the interpretation of sequence variants: a joint consensus recommendation of the American College of Medical Genetics and Genomics and the Association for Molecular Pathology. *Genet Med* 2015;17:405–423.
8. Halmagyi GM, Curthoys IS. The video head impulse test in clinical practice. *Neurol Sci Neurophysiol* 2018;35:1–5.
9. Horak FB. Clinical measurements of postural control in adults. *Phys Ther* 1987;67:1881–1885.
10. Estilow T, Glanzman AM, Burns J, et al. Balance impairment in pediatric Charcot-Marie-Tooth disease. *Muscle Nerve* 2019;60:219–221.
11. Callegari I, Gemelli C, Geroldi A, et al. Mutation update for myelin protein zero-related neuropathies and the increasing role of variants causing a late-onset phenotype. *J Neurol* 2019;266:2629–2645.
12. Jen J, Baloh RH, Ishiyama A, Baloh RW. Dejerine-Sottas syndrome and vestibular loss due to a point mutation in the *PMP22* gene. *J Neurol Sci* 2005;237:21–24.
13. Nadol JB Jr, Hedley-Whyte ET, Amr SS, O Apos Malley JT, Kamakura T. Histopathology of the inner ear in Charcot-Marie-Tooth syndrome caused by a missense variant (p.Thr65Ala) in the *MPZ* gene. *Audiol Neurootol* 2018;23:326–334.
14. Starr A, Michalewski HJ, Zeng FG, et al. Pathology and physiology of auditory neuropathy with a novel mutation in the *MPZ* gene (Tyr145->Ser). *Brain* 2003;126:1604–1619.