

# The Pre-1D Lesion of the TFCC—A New Variant of the Palmer 1D Class



Riccardo Luchetti, M.D., Roberto Cozzolino, M.D., Lucian Lior Marcovici, M.D., and Andrea Atzei, M.D.

**Abstract:** The triangular fibrocartilage complex (TFCC) is the most important stabilizer of the distal radioulnar joint (DRUJ). Its injury is the main cause for ulnar sided pain after wrist trauma. In recent years, advancements of wrist arthroscopy improved the diagnostics and treatment of the TFCC tears. The purpose of this article is to describe a variant of radial tears (1D according to Palmer), in which the radio-ulnar ligaments were ruptured in the midsubstance just before (Pre) their insertion on the sigmoid notch and illustrate the arthroscopic surgical technique used for its treatment. We name this variant of the Palmer 1D lesion, the pre-1D TFCC lesion.

## Introduction

Palmer and Werner<sup>1</sup> have classified triangular fibrocartilage complex (TFCC) tears in 2 main groups: traumatic (Type 1) and degenerative (Type 2). Among the traumatic lesions, 4 patterns have been described. Radial sided tears are classified as type 1-D tears. These lesions are defined as an avulsion of the radio-ulnar ligaments from the sigmoid notch, which may be associated with a bony fragment. In recent years with the advance of wrist arthroscopy, the TFCC gained a lot of attention, and several of studies highlighted new forms of lesions that are not described in the Palmer classification.<sup>1</sup> Atzei<sup>2</sup> and Atzei and Luchetti,<sup>3</sup> introduced the arthroscopic classification of 1B Palmer lesions [Table 1](#); Estrella et al.<sup>4</sup> defined the dorsal tears of the TFCC located in the area between the extensor carpi ulnaris (ECU) subsheath, the extensor digiti minimi (EDM), and del Piñal and Nakamura<sup>5</sup> described the coronal tear pattern.

The purpose of this article is to describe a variant of radial tears (1D according to Palmer), in which the radio-ulnar ligaments were ruptured in the midsubstance just before (Pre) their insertion on the

sigmoid notch and illustrate the arthroscopic surgical technique used for its treatment. We name this variant the pre-1D TFCC lesion.

## Patient Evaluation, Imaging, and Indications

A 27-year-old male—a policeman, right hand dominant, tai boxer—was referred to us with ulnar sided pain at the right wrist after trauma (fall). Clinical examination showed normal range of motion (ROM) associated with a decrease of the grip strength. Dynamic maneuvers of the wrist showed a minimal instability of the distal radioulnar joint (DRUJ), along with pain on fovea palpation and during the stress test. Radiographs showed bilateral long ulnar styloid with a small medial incisure for the triquetrum. The right side the posterior ulnar corner of the distal radius showed a small bone detachment. Lateral view was normal without dorsal subluxation of the ulnar head. Magnetic resonance imaging (MRI) showed a lunate bone edema due to ulno-carpal conflict and arthrosynovitis in the ulnar side and a radial central discontinuity of the TFCC close to the radius. Wrist function according with MMWS

From the Rimini Hand Surgery & Rehabilitation Center, Rimini, Italy (R.L., R.C.); Hand & Microsurgery Unit, Jewish Hospital of Rome, Rome, Italy (L.L.M.); and PRO-Mano, Treviso, Italy (A.A.).

Full ICMJE author disclosure forms are available for this article online, as [supplementary material](#).

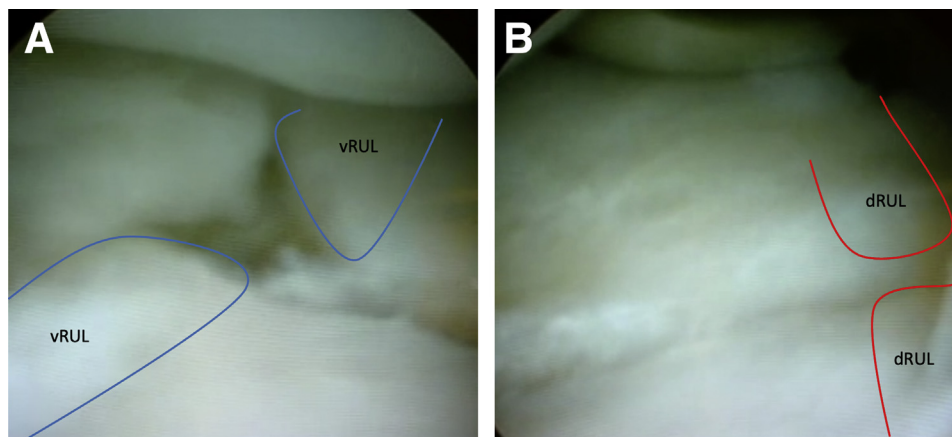
Received January 2, 2022; accepted March 20, 2022.

Address correspondence to Lucian Lior Marcovici, M.D., Via Pindaro 116, 00125 Rome, Italy. E-mail: [lucian.marcovici@gmail.com](mailto:lucian.marcovici@gmail.com)

© 2022 THE AUTHORS. Published by Elsevier Inc. on behalf of the Arthroscopy Association of North America. This is an open access article under the CC BY-NC-ND license (<http://creativecommons.org/licenses/by-nc-nd/4.0/>).

2212-6287/225

<https://doi.org/10.1016/j.eats.2022.03.031>



**Fig 1.** Wrist arthroscopy findings showing the Pre-1D TFCC lesion with a clear sharp transversal rupture of its radial part involving the volar and the dorsal radio-ulnar ligaments ([A] volar radio-ulnar ligament and [B] dorsal radio-ulnar ligament) branches at 0.5 to 1 cm from its insertion to the ulnar border of the radius.

was evaluated before surgery. Disabilities of the arm, shoulder and hand score and patient-rated wrist evaluation score were also obtained.

Patient was submitted to arthroscopy in order to evaluate ulnocarpal structures, identify lesions, and perform correct treatment.

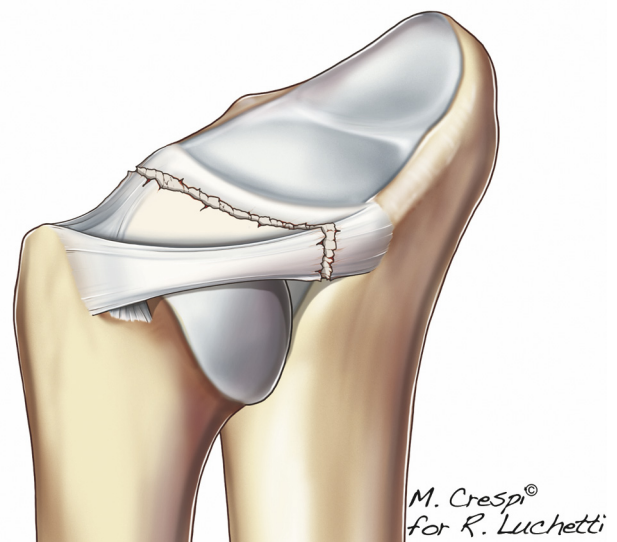
### Surgical Technique

Regional anesthesia was administered, and, before surgery, DRUJ ballottement test was executed and showed mild DRUJ instability. Arthroscopy was performed with standard set-up,<sup>6</sup> using a 1.9-mm wide-angle video arthroscope (Smith and Nephew). With the scope in 3-4 portal, an unusual TFCC tear was found at ulnocarpal exploration. The TFCC had a clear sharp transverse rupture on its radial part, involving both the volar and the dorsal RU ligaments at 0.5 and 1 cm, respectively from its insertion to the ulnar border of the radius (Fig 1 and Fig 2). The hook tests showed competent foveal insertions of the TFCC.<sup>7</sup>

Although resembling the type 1D tear described by the Palmer classification, the above findings differed from the typical description as the radioulnar (RU) ligaments were not detached from its insertions on the radius, but the rupture was located within the mid-substance of the ligament, at least at 5 mm from the radius. Consequently, this rupture was not amenable to the technique of transosseous repair, which is commonly proposed for type 1D tears. Therefore, an alternative technique of suture was adopted (Fig 3). Starting from the palmar RU ligament, a 21 G shuttle needle was used to pass a 2/0 Nylon Monofilament (Ethicon ETHILON), a nonabsorbable suture through the tear from the ulnar side toward the radial stump, still attached to the radius. A second shuttle needle with a suture loop was introduced in the same manner and direction, parallel to the previous one. Both the Nylon suture and the loop were retrieved outside the joint.

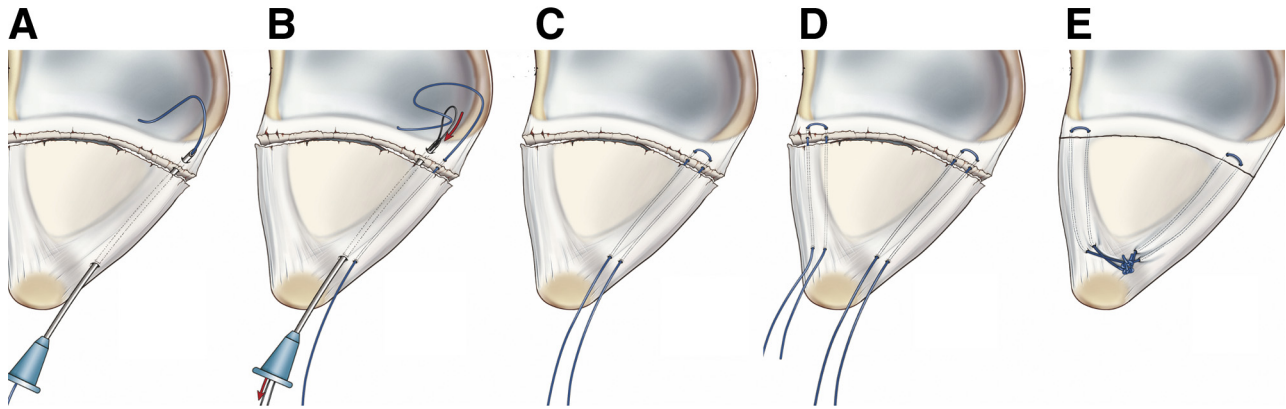
The suture was loaded on the loop, which was then pulled backward, so that the Nylon suture crossed the tear. Procedure was done for the palmar and dorsal RU ligaments. Then the extremities of both the Nylon sutures were knotted on the ulnar side, close to the prestyloid recess, achieving a strong repair of both RU ligaments. (Fig 4 and Fig 5). Arthroscopy was recorded, and the video demonstrates the technique (Video 1). At the end of the repair, pronosupination was tested, and clinical stability was checked.

The upper limb was immobilized in neutral pronosupination with an above elbow spica cast for 45 days, then the wrist was protected with a removable wrist splint for 30 days more. Return to work was permitted after 3 months (Figs 6 and 7).



**Fig 2.** Artist rendering of the Pre-1D TFCC lesion aspect in which the radio-ulnar ligaments are ruptured in the mid-substance just before (Pre) their insertion on the sigmoid notch.

*M. Crespi<sup>®</sup>  
for R. Luchetti*



**Fig 3.** Artist rendering of surgical technique. A shuttle needle is used to pass the suture through the volar branch of the radio-ulnar ligament starting from the ulnar side crossing the tear and passing to the radial stump of both branches attached to the radius (A). A second shuttle needle with suture loop is introduced in the same manner through the radio-ulnar branch, parallel to the previous one, reaching to radial stump and catching the free suture (B). Finally, the suture is transported outside the ulnar part of the TFCC retrieving the last needle (C). Procedure is repeated for dorsal branch (D). Finally, the knot was done in the volo-ulnar side superficially to the fovea, producing a strong contact between the free margin of both branches and the radial stump of them (E).

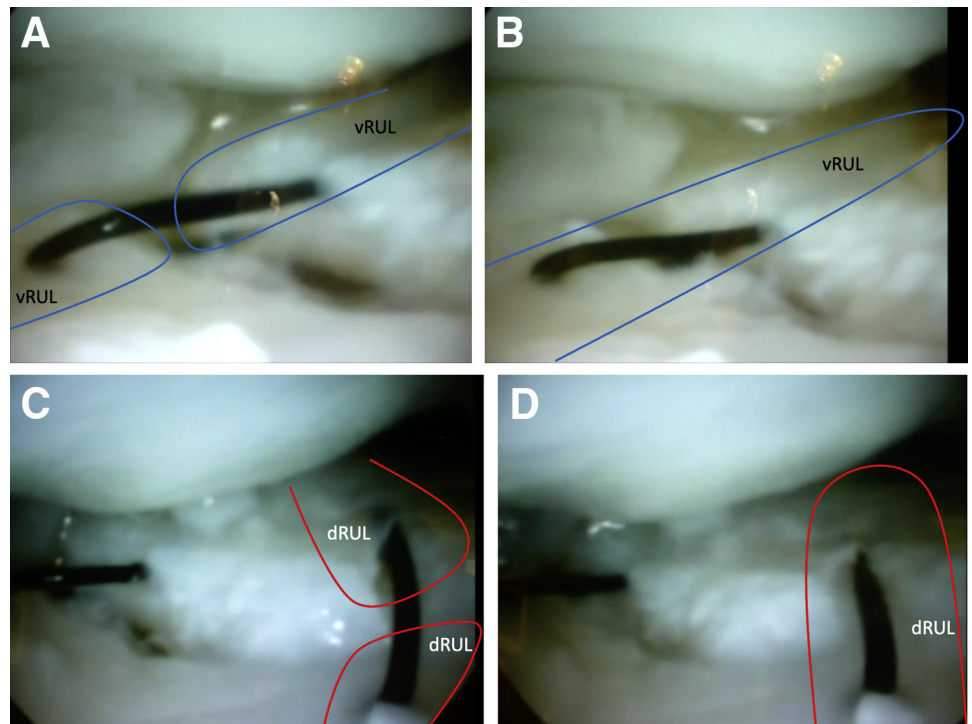
### Discussion

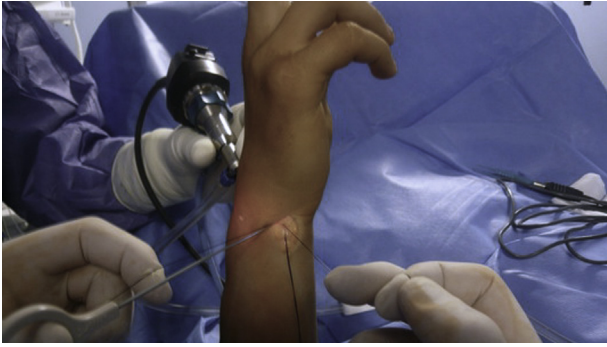
Classifications of TFCC injuries are useful for understanding the type of lesion and their correct treatment.<sup>2,3</sup> However, there are unconventional TFCC injuries that cannot be treated according to the indications given in literature.<sup>5</sup> Furthermore, their recognition is only possible through arthroscopy.<sup>2,3,5</sup> Imaging studies such as MRI and arthroMRI cannot give certainty on the type of injury or, above all, on the reparability of the injury, based on the type of injury,

site of injury, quality of damaged ligament tissue and, finally, associated injuries.<sup>8</sup> Arthroscopy, therefore, plays a fundamental role for this purpose and remains the gold standard.

The unusual variant of the 1D of TFCC tear described in this article confirms that only arthroscopic assessment of ulnar wrist pain allows appropriate diagnosis and treatment. We supposed that the injury was caused by a crush-traction of the ligament between the head of the ulna and the lunate (Fig. 8).

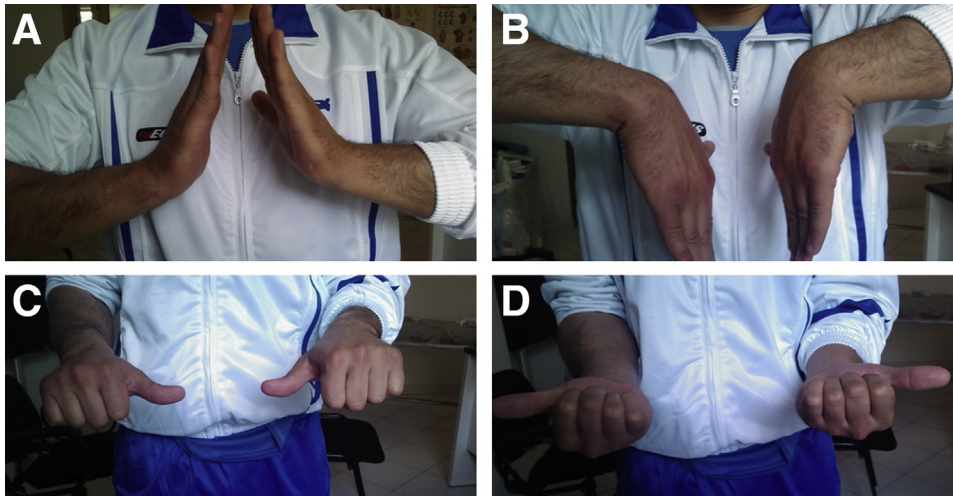
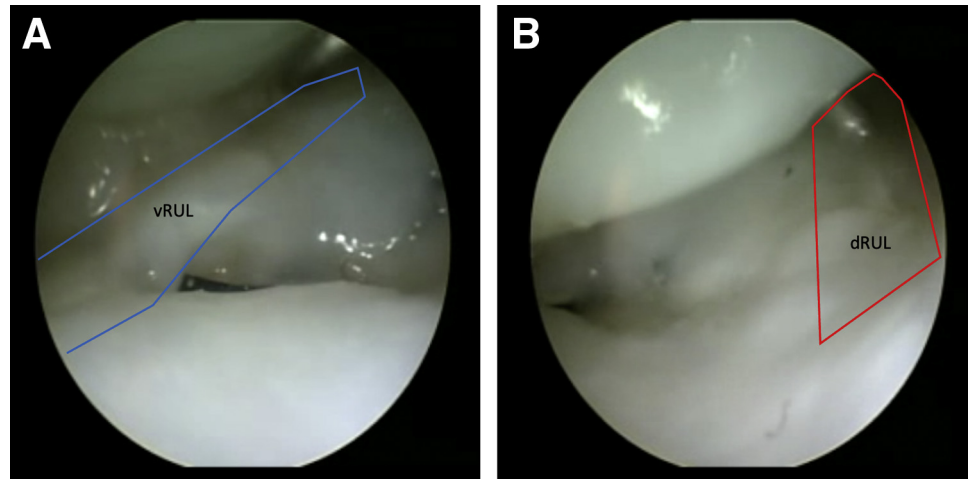
**Fig 4.** Arthroscopic view of suture passing in the volar branch of the radio-ulnar ligament before (A) and after (B) making the knot and at the dorsal branch before (C) and after (D) making the knot.





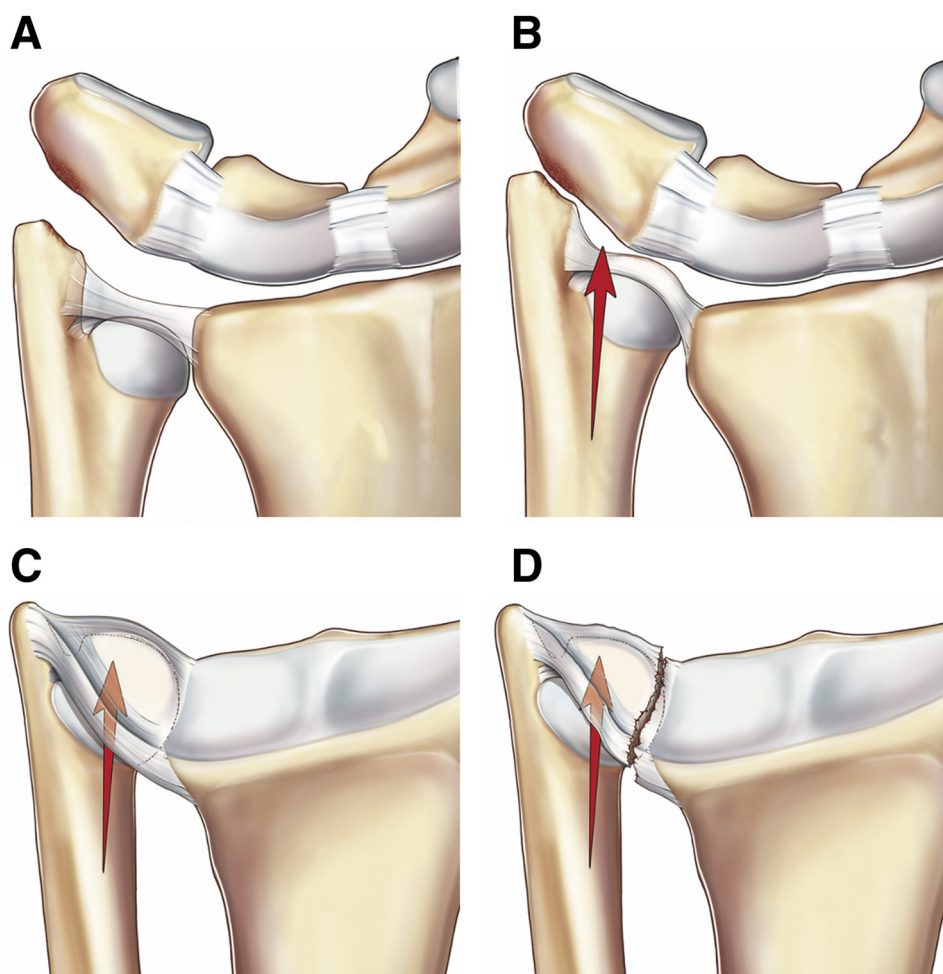
**Fig 5.** Intraoperative view of knot making at the volo-ulnar side of the wrist.

**Fig 6.** Second-look arthroscopic finding evidence healing of the sutured ligaments volar radio ulnar (A) and dorsal radio-ulnar (B).



**Fig 7.** Postoperative findings showing a satisfactory range of motion. (A) extension. (B) flexion. (C) Pronation. (D) Supination.

**Fig 8.** Artist rendering of injury mechanism. Patient wrist (A) sustained a violent trauma with crushing traction of the ligament between the head of the ulna and the lunate (B and C), which caused a rupture of the central disc and the dorsal and volar radio-ulnar ligaments (D).



**Table 1.** Palmer Classification of TFCC Acute Traumatic Tears (Type 1), Including Subtypes

Type of Tear	Description
<ul style="list-style-type: none"> <li>• 1A</li> <li>• 1B</li> </ul>	<ul style="list-style-type: none"> <li>• Isolated central TFCC articular disk perforation</li> <li>• Ulnar-sided TFCC tear (with or without ulnar styloid fracture)               <ul style="list-style-type: none"> <li>○ Repairable distal tear</li> <li>○ Repairable complete tear</li> <li>○ Repairable proximal tear</li> </ul> </li> </ul>
Subtypes: <ul style="list-style-type: none"> <li>○ Atzei-EWAS 1</li> <li>○ Atzei-EWAS 2</li> <li>○ Atzei-EWAS 3</li> </ul>	
<ul style="list-style-type: none"> <li>• 1C</li> <li>• 1D</li> </ul>	<ul style="list-style-type: none"> <li>• Distal TFCC disruption (disruption from distal ulnocarpal ligaments)</li> <li>• Radial TFCC disruption from (with or without sigmoid notch fracture)               <ul style="list-style-type: none"> <li>○ Mid-substance tear of the radio-ulnar ligaments 5-10 mm before their insertion on the sigmoid notch</li> </ul> </li> </ul>
Subtype: <ul style="list-style-type: none"> <li>○ Pre-1D</li> </ul>	

TFCC, triangular fibrocartilage complex.

**Table 2.** Advantages and Disadvantages of the Technique

Advantages of the Technique	Disadvantages of the Technique
<ol style="list-style-type: none"> <li>1. Arthroscopic visualization of the TFCC allows the surgeon to diagnose this lesion, which is likely to be missed in an open approach.</li> <li>2. The arthroscopic technique is less invasive with minimal tissue exposure and damage.</li> <li>3. Soft tissue preservation allows a better reconstruction with faster gain of function.</li> <li>4. Arthroscopic approach to the ligament tear allows a more accurate and precise repair.</li> </ol>	<ol style="list-style-type: none"> <li>1. Suturing of such a small portion of the ligament may damage the ligament during suture.</li> <li>2. Non perfect ligament repair</li> <li>3. Small space in stiff wrist or small wrist may result in difficult of repair.</li> </ol>

**Table 3.** Pearls and Pitfalls of the Technique

Pearls	Pitfalls
The use of two 21G parallel needles (one with the suture wire and the other one with suture loop makes the suture pass easier with less damage to the ligament.	The use of a suture passer may damage the ligament. Moreover, when the needles are used but not in parallel fashion suture rupture is frequent.
Needle should be curved at tip to facilitate passage at ligament site.	Leaving the needle straight will make difficult being accurate when passing inside the ligament and might damage the ligament branch.
A resorbable suture such as Vycril 3/0 will irritate the wrist less and is more tolerable for the patient.	A nonabsorbable suture like nylon may give site irritation with a painful wrist.
Dry arthroscopic technique will give a more anatomic visualization of tissues and facilitate the repair.	A wet arthroscopic technique may be more challenging when suturing the ligaments.

The trauma was, probably, so violent that it broke not only the central disc of the TFCC but also the palmar and dorsal RU ligaments. The arthroscopic appearance of a clear-cut transverse tear passing from the dorsal to the palmar RU ligaments, also involving the central disc, sustained our hypothesis. Since the lesion of the ligament was localized in its midsubstance, at about 1 cm from the radius itself, not at the bony insertion of the radius, a soft tissue repair technique was required using an unconventional but efficient arthroscopic method. Considering that the two branches converge in the ulnar part or at the ulnar fovea, it was decided to perform a volar-ulnar surgical approach at the site of the 6U and DF portals. After we exposed the site and identified the convergence site of the two branches under arthroscopic control, the repair technique was performed using two shuttle needles for each branch to transport and take back the sutures, respectively. The knot-tying was made at the convergence site of the two branches, close to the prestyloid recess.

For this peculiar tear location, arthroscopic repair has many advantages compared to an open treatment, which would have involved a double approach, both volar and dorsal, requiring extensive anatomical exposure with additional soft tissue damage and possible ligament devascularization (Tables 2 and 3).

## References

- Palmer AK, Werner FW. The triangular fibrocartilage complex of the wrist—*anatomy and function*. *J Hand Surg Am* 1981;6:153-162.
- Atzei A. New trends in arthroscopic management of type 1-B TFCC injuries with DRUJ instability. *J Hand Surg Eur* 2009;34:582-591.
- Atzei A, Luchetti R. Foveal TFCC tear classification and treatment. *Hand Clin* 2011;27:263-272.
- Estrella EP, Hung LK, Ho PC, Tse WL. Arthroscopic repair of triangular fibrocartilage complex tears. *Arthroscopy* 2007;23:729-737.
- del Piñal F, Nakamura T. Coronal tears of the TFCC. In: Mathoulin C, Nakamura T, del Piñal F, eds. *Arthroscopic management of ulnar pain*. 1st ed. Berlin, Germany: Springer, 2012;199-211.
- Badur N, Luchetti R, Atzei A. Arthroscopic wrist anatomy and setup. In: Geissler WB, ed. *Wrist and elbow arthroscopy. A practical surgical guide to techniques*. 2nd ed. New York: Springer Verlag, 2015;1-27.
- Atzei A, Luchetti R, Carletti D, Marcovici LL, Cazzoletti L, Barbon S. The hook test is more accurate than the trampoline test to detect foveal tears of the triangular fibrocartilage complex of the wrist. *Arthroscopy* 2021;37:1800-1807.
- De Santis S, Cozzolino R, Luchetti R, Cazzoletti L. Comparison between MRI and arthroscopy of the wrist for the assessment of posttraumatic lesions of intrinsic ligaments and the triangular fibrocartilage complex. *J Wrist Surg* 2021;11:28-34.