

Tubular Colonic Duplication Presenting as Rectovestibular Fistula

Parag J. Karkera, Pradnya Bendre, Flavia D'souza, Mukunda Ramchandra, Amol Nage, and Nitin Palse

Department of Pediatric Surgery, Bai Jerbai Wadia Hospital for Children, Mumbai, India

Complete colonic duplication is a very rare congenital anomaly that may have different presentations according to its location and size. Complete colonic duplication can occur in about 15% of all gastrointestinal duplications. Double termination of tubular colonic duplication in the perineum is even more uncommon. We present a case of a Y-shaped tubular colonic duplication which presented with a rectovestibular fistula and a normal anus. Radiological evaluation and initial exploration for sigmoidostomy revealed duplicated colons with a common vascular supply. Endorectal mucosal resection of the duplicated distal segment till the colostomy site with division of the septum of the proximal segment and colostomy closure proved curative without compromise of the continence mechanism. Tubular colonic duplication should always be ruled out when a diagnosis of perineal canal is considered in cases of vestibular fistula along with a normal anus.

Key Words: Rectovestibular fistula, Colonic duplication, Tubular duplication

INTRODUCTION

Alimentary tract duplications are rare congenital malformations of the gastrointestinal tract, which may be cystic or tubular and occur anywhere from the mouth to the anus [1]. More than 80% of cases present before the age of 2 years as an acute abdomen or bowel obstruction [2,3]. The commonest site for duplication is the ileum, while colonic duplication is rare, accounting for 6-13% of all gastrointestinal duplications, commonly located in the ce-

cum [1,4]. These lesions, if encountered incidentally, should be surgically managed to prevent any future complications. Although perineal canal or H-type congenital fistula is a relatively common anomaly in Asian countries, its association with Y-shaped tubular colonic duplication is rare [5]. We report a case of colorectal duplication in a two month old female child passing stools from normal anal opening and a fistulous opening in the vestibule.

Received : December 23, 2014, Revised : February 1, 2015, Accepted : February 9, 2015

Corresponding author: Parag J. Karkera, Department of Pediatric Surgery, Bai Jerbai Wadia Hospital for Children, Acharya Donde Marg, Parel, Mumbai 400012, India. Tel: +91-22-4146963/64/65/66/67, E-mail: drpaggy@gmail.com

Copyright © 2015 by The Korean Society of Pediatric Gastroenterology, Hepatology and Nutrition

This is an open-access article distributed under the terms of the Creative Commons Attribution Non-Commercial License (<http://creativecommons.org/licenses/by-nc/4.0/>) which permits unrestricted non-commercial use, distribution, and reproduction in any medium, provided the original work is properly cited.

CASE REPORT

A two-month-old female child presented with the complaints of passing stools from normal anal opening and a fistulous opening in the vestibule. A provisional diagnosis of perineal canal was made. Abdo-

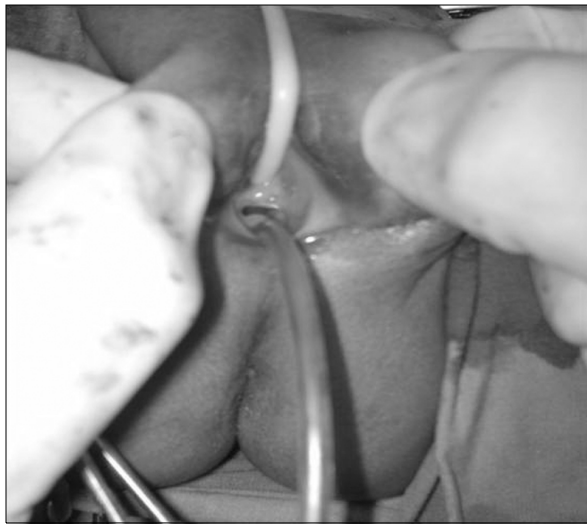


Fig. 1. Clinical picture showing 3 openings in the vestibule-urethra (foley catheter), vagina, vestibular fistula (infant feeding tube), in addition to the normal sited anus.

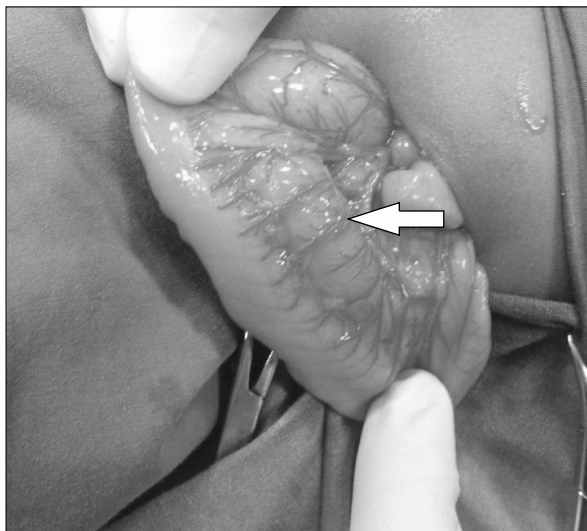

Fig. 2. Intra-operative picture showing duplicated colon (arrow points to the duplicated segment at the mesenteric border of native colon).

minimal sonography, echocardiography and spinal radiography were normal, ruling out associated urinary tract, cardiac and vertebral anomalies. Examination under anaesthesia revealed a normal anal opening. The vestibule had 3 openings, which were a normal urethral and vaginal opening and a rectovestibular fistula (Fig. 1) with no communication with the normal anorectum. Considering this to be a complex anomaly, a diverting stoma was planned. On exploration of the abdomen for the stoma, tubular duplication of the sigmoid colon was noted (Fig. 2). A high sigmoid loop colostomy was done which resulted in four stomal lumens. Later, for better delineation of the anatomy of the anomaly, a proximal and distal colostomogram was performed (Fig. 3). It revealed duplicated colon with separate lumens from the transverse colon downwards with two anal openings. The duplicated colonic segment towards the mesenteric side terminated as a rectovestibular fistula (Fig. 4). At 6 months of age, the patient was taken up for definitive surgical management. An abdominoperineal approach was used, in which initially the colostomy was mobilized. For the distal duplicated colonic segment, the mucosal cuff of the colon leading to the vestibular fistula was dissected like

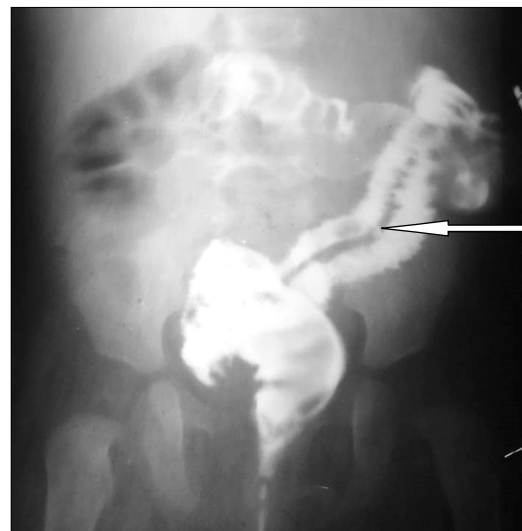

Fig. 3. Distal and proximal cologram showing duplicated colon with 2 separate lumens (arrow points to negative shadow of the intervening septum between the duplicated colons).

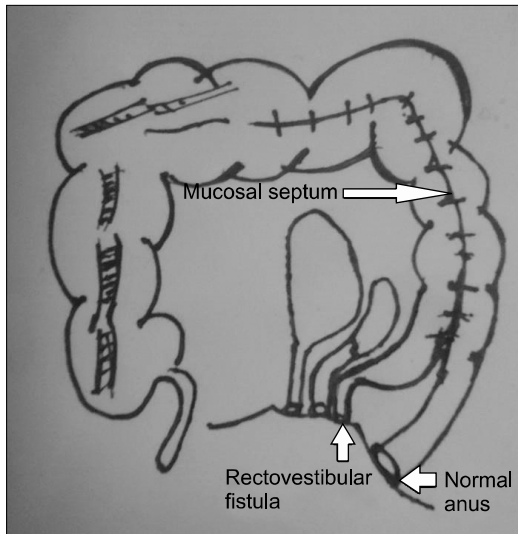


Fig. 4. Diagrammatic presentation of the anatomy.

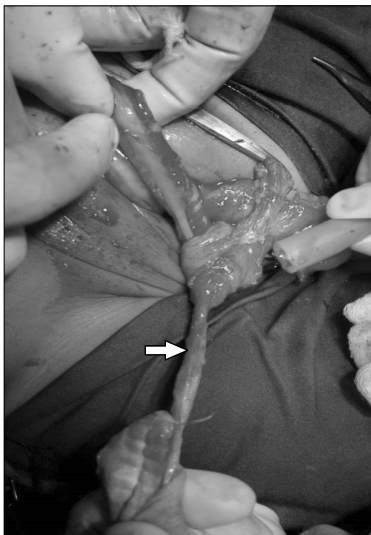

Fig. 5. Mucosal resection (arrow-mucosal cuff) of the distal duplicated colon.

a Soave's endorectal pullthrough from the distal stoma to the vestibular fistula and excised (Fig. 5). The remaining muscular cuff was plicated and closed.

The proximal duplicated colonic segment shared the vascular supply with the native colon, hence resection was not possible. The duplicated segment extended proximally till the ascending colon and common wall comprised of two layers of mucosa. There-

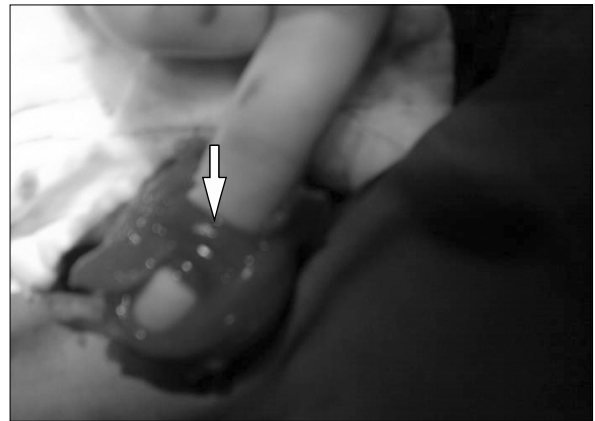


Fig. 6. Septum (arrow) between the duplicated colons.

fore, the intervening mucosal septum between the duplicated colon, upto the non-duplicated ascending colon was divided (Fig. 6). A colo-colic anastomosis between the proximal unified colon with the distal native colon leading to the normal anus was done. In view of the significant disparity in the proximal and distal colonic luminal diameter, a covering ileostomy was also done. The postoperative course was uneventful and the ileostomy was closed after 3 months. At follow up of 6 months post-surgery, the opening in the vestibule had closed, with no bowel complaints.

DISCUSSION

Duplications of the colon are uncommon malformations, which are tubular or cystic in nature. Early aberration in the formation of the primitive hindgut is hypothesized to cause a split or twinning process of the anlage, which results in terminal gut duplication with or without duplication of the genitourinary organs [6]. Tubular colonic duplications are double-barreled or Y-shaped. They possess a double muscular layer and epithelium similar to the rest of the colon [1,7]. Either both lumina may be unobstructed and function normally as two perineal ani, or terminate distally blindly as imperforate anus of one or both lumina. In some cases, the ventral colon may end as a rectourinary, rectovaginal or vestibular fistula [7].

The presenting features are constipation, vomiting, volvulus, perforation, and, most commonly, intestinal obstruction due to compression of the normal bowel by the blind end of the duplication [8]. Associated anomalies include genitourinary duplications, skeletal anomalies bladder exstrophy, malrotation of gut, omphalocele, Meckel's diverticulum [1,7,8]. In absence of other associated malformations or an ectopic opening, tubular duplications of the colon remain unnoticed, until its complications warrant surgical intervention.

Most authors recommend that once the diagnosis is made, an elective surgical procedure in an optimal state of the patient should be performed to avoid complications. The recommended surgical procedure is excision of the duplicated colon. Although malignant changes have been reported in adults [9], colorectal duplications are essentially benign lesions and radical surgical excision is not required. Need for surgery when asymptomatic is debatable [8].

In most cases, resection of the duplicated colon may not be possible because of common blood supply with a single mesentery to the two colons [8]. In our case, separation of the two proximal colonic segments was impossible because in addition to the common blood supply, the intervening wall comprised of only mucosa. Also, excision of common wall resulted in gross disparity between proximal and distal loops.

The options to manage unresectable proximal duplicated colons include dividing the septum to convert it into a common colonic channel; long side-to-side anastomosis of adjacent duplicated bowel; transection of the rectum over the peritoneal reflection and anastomosis of the proximal end of the neighboring colon to the main colon, excision of the distal common septum with creation of a common channel should prevent accumulation of feces in the false lumen or performing mucosectomy on one limb of the proximal duplication [10-13].

Excision of the distal duplicated segment is even more difficult, as although, all ectopic openings require surgical intervention, it can compromise the continence mechanism of the normal sited anus.

Stephens and Smith [14] presented a series of double perineal ani and opined that, provided that there is no neurogenic element, and both recta appear to lie within the same puborectalis muscle sling and within a single external sphincter, it may be best to accept the 2 ani permanently. Attempt to excise one rectum from the other may jeopardize normal continence.

Hence, for the distal segment, if the colon proper ends as a fistula, posterior sagittal anorectoplasty approach helps to prevent compromise of continence mechanism [15]. Management options for the distal duplicated segment include fistula closure with excision of distal few centimeters of septum to create a common distal channel; and mucosal stripping of the duplicated colon like a soave's procedure [15-17].

Also, in cases in whom hindgut duplication is discovered unexpectedly at initial laparotomy for stoma formation for anorectal malformations, sigmoidostomy has proven to be well tolerated as it does not compromise subsequent reconstruction, and facilitates easier radiological evaluation of the complex anatomy [15]. To prevent unexpected findings on surgical exploration, radiological evaluation is recommended. Contrast enema and a fistulogram performed concomitantly, preferably with contrast media of differing densities, helps to delineate both colons. Occasionally, upper gastrointestinal contrast follow-through studies may help to locate the proximal extent of duplication [10,18].

In our case, the child was asymptomatic for the proximal colonic duplication and the duplicated colon could not be resected without resection of almost the entire colon in view of the shared vascular supply. Hence, dividing the septum between the two lumens of the proximal colonic segment with mucosectomy and closure of fistula treated the problem without hindering continence.

In conclusion, tubular colorectal duplication should be considered as one of the differential diagnosis with perineal canal in cases of vestibular fistula along with a normal anus. Resection of the duplicated colon may not be possible due to shared blood supply between the duplicated segments. Sigmoid-

dostomy at initial laparotomy is useful for future reconstruction and radiographic evaluation. Endorectal mucosal resection of the duplicated segment effectively manages the condition without compromise of the continence mechanism.

REFERENCES

1. Macpherson RI. Gastrointestinal tract duplications: clinical, pathologic, etiologic, and radiologic considerations. *Radiographics* 1993;13:1063-80.
2. Kekez T, Augustin G, Hrstic I, Smud D, Majerovic M, Jelincic Z, et al. Colonic duplication in an adult who presented with chronic constipation attributed to hypothyroidism. *World J Gastroenterol* 2008;14:644-6.
3. Merrot T, Anastasescu R, Pankevych T, Tercier S, Garcia S, Alessandrini P, et al. Duodenal duplications. Clinical characteristics, embryological hypotheses, histological findings, treatment. *Eur J Pediatr Surg* 2006;16:18-23.
4. Liu R, Adler DG. Duplication cysts: diagnosis, management, and the role of endoscopic ultrasound. *Endosc Ultrasound* 2014;3:152-60.
5. Bryndorf J, Madsen CM. Ectopic anus in the female. *Acta Chir Scand* 1960;118:466-78.
6. Ravitch MM. Hind gut duplication; doubling of colon and genital urinary tracts. *Ann Surg* 1953;137:588-601.
7. Kaur N, Nagpal K, Sodhi P, Minocha VR. Hindgut duplication--case report and literature review. *Pediatr Surg Int* 2004;20:640-2.
8. Jellali MA, Mekki M, Saad J, Zrig A, Elanes I, Mnari W, et al. Perinatally discovered complete tubular colonic duplication associated with anal atresia. *J Pediatr Surg* 2012;47:e19-23.
9. Inoue Y, Nakamura H. Adenocarcinoma arising in colonic duplication cysts with calcification: CT findings of two cases. *Abdom Imaging* 1998;23:135-7.
10. Aworanti O, Twomey E, Awadalla S. Terminal ileum and total colonic duplication associated with a rectovestibular fistula in a child. *Ir Med J* 2014;107:241-2.
11. Yucesan S, Zorludemir U, Olcay I. Complete duplication of the colon. *J Pediatr Surg* 1986;21:962-3.
12. Ravitch MM. Duplication of the gastrointestinal tract. In: Ravitch MM, Welch KJ, Bandolph JG, eds. *Pediatric surgery*. 4th ed. Chicago: Year Book Medical, 1986:911-20.
13. Fuchs JR, Clark K, Breckler FD, Rescorla FJ. Complete colonic duplication--a case report. *J Pediatr Surg* 2008; 43:E11-3.
14. Stephens FD, Smith ED. Duplications and vesicointestinal fissure. In: *Anorectal malformations in children: update 1988 (birth defects, original article series)*. New York: Alan R Liss, 1988:554-5.
15. Craigie RJ, Abbaraju JS, Ba'ath ME, Turnock RR, Baillie CT. Anorectal malformation with tubular hindgut duplication. *J Pediatr Surg* 2006;41:e31-4.
16. Khaleghnejad Tabari A, Mirshemirani A, Khaleghnejad Tabari N. Complete colonic duplication in children. *Caspian J Intern Med* 2012;3:436-9.
17. Zhang Z, Huang Y, Wang D, Su P. Rectosigmoid tubular duplication presenting as perineal sepsis in a neonate. *J Pediatr Surg* 2010;45:627-9.
18. Rathi V, Singh S, Bhargava SK, Kaur N, Seth N. Diagnosis of tubular colonic duplication by barium follow-through study. *Australas Radiol* 2005;49:157-9.