

Case series

Diaphragm hernia after debulking surgery in patients with ovarian cancer

Sarah Ehmann^a, Emeline M. Aviki^{a,b}, Yukio Sonoda^{a,b}, Thomas Boerner^a, Dib Sassine^a,
David R. Jones^{b,c}, Bernard Park^{b,c}, Murray Cohen^d, Norman G. Rosenblum^d, Dennis S. Chi^{a,b,*}

^a Gynecology Service, Department of Surgery, Memorial Sloan Kettering Cancer Center, New York, NY, USA

^b Joan and Sanford I. Weill Medical College of Cornell University, New York, NY, USA

^c Thoracic Service, Department of Surgery, Memorial Sloan Kettering Cancer Center, New York, NY, USA

^d Division of Gynecologic Oncology, Department of Obstetrics and Gynecology, Thomas Jefferson University Hospital, Philadelphia, PA, USA

ARTICLE INFO

Keywords

Diaphragmatic hernia
Ovarian cancer
Debulking surgical procedures
Postoperative complications

ABSTRACT

Over 80% of patients with epithelial ovarian cancer present with advanced disease, FIGO stage III or IV at the time of diagnosis. The majority require extensive upper abdominal surgery to obtain complete gross resection. This may include splenectomy, distal pancreatectomy, partial hepatectomy, cholecystectomy, and usually diaphragmatic peritonectomy or resection. Following surgery, diaphragmatic hernia—a very rare but serious complication—may occur.

We describe four cases of left-sided diaphragmatic hernia resulting after debulking surgery, which included left diaphragm peritonectomy and splenectomy, in patients with advanced ovarian cancer. In association with the current shift towards more extensive debulking surgery for ovarian cancer, more patients may present with postoperative left-sided diaphragm hernia, making the prevention, diagnosis, and management of this complication important to practicing gynecologic oncologists. Intraoperatively the diaphragm should be checked thoroughly to rule out any defects, which should be closed. A diaphragmatic hernia may be easily misdiagnosed because the patient can present with various symptoms. While rare, these hernias require prompt identification, intervention and surgical correction to avoid serious complications.

1. Introduction

Each year, approximately 239,000 patients are diagnosed with epithelial ovarian cancer worldwide (Ferlay, 2015). At the time of diagnosis over 80% of patients have advanced disease, FIGO stage III or IV (Minig, 2015). Whether the patient is treated initially with primary debulking surgery (PDS) followed by chemotherapy, or neoadjuvant chemotherapy (NACT) followed by interval debulking surgery (IDS), the majority of the patients will need some sort of extensive upper abdominal surgery in order to receive complete gross resection (Eisenhauer, et al., 2006; Kang, et al., 2011). Extensive upper abdominal surgery may include splenectomy, distal pancreatectomy, partial hepatectomy, cholecystectomy, and most commonly diaphragmatic peritonectomy/resection (Eisenhauer, et al., 2006). Filippova et al recently reported that, of 389 advanced ovarian cancer patients undergoing PDS or IDS at our institution between 6/2015 – 12/2017, diaphragm peritonectomy/resection and splenectomies were performed in 61% and 27% of PDS patients, respectively, and 43% and 14% of IDS patients, respectively

(Filippova, 2019).

While the most common complication after diaphragm peritonectomy/resection during debulking is symptomatic pleural effusion (Sandadi, et al., 2014), a very rare complication is herniation of the stomach or bowel through the diaphragm into the thoracic cavity. The definition of a diaphragmatic hernia is an opening of the diaphragm through which abdominal contents can enter the thoracic cavity (Spellar and Gupta, 2020). There are two types of diaphragmatic hernia: congenital and acquired. The most common causes of acquired diaphragmatic hernias are trauma and iatrogenic injury (Tsuboi, et al., 2008). Iatrogenic damage of the diaphragm can occur during major abdominal or thoracic surgery (Scharff and Naunheim, 2007). Herein we describe four cases of left-sided diaphragmatic hernia after debulking surgery with left diaphragm peritonectomy and splenectomy, in patients with advanced ovarian cancer.

Case 1. A 36-year-old patient with no significant past medical history and no previous surgeries underwent PDS for stage IVB high-grade serous ovarian carcinoma (HGSOC). To achieve a complete gross resection, upper

* Corresponding author at: Gynecology Service, Department of Surgery, Memorial Sloan Kettering Cancer Center, 1275 York Avenue, New York, NY 10065, USA.
E-mail address: chid@mskcc.org (D.S. Chi).

abdominal surgery included bilateral diaphragm peritonectomy, splenectomy, and cholecystectomy was performed. Additionally, an involved right mediastinal lymph node was resected, and a right chest tube was inserted. Post-operative chemotherapy was completed with standard systemic paclitaxel and carboplatin.

Five months later, she presented to our urgent care center with a history of nausea and vomiting, but no other complaints. CT imaging showed a left diaphragmatic hernia, with a 0.8 cm defect and incarceration of the stomach (Fig. 1). A left thoracotomy and a repair of the diaphragmatic hernia was performed by the Thoracic Surgery service. Intraoperatively the stomach was viable, and the diaphragmatic defect was very restrictive, measuring approximately 1 cm. Following further opening of the defect, the stomach was reduced into the abdomen, and the remaining defect was repaired primarily with multiple interrupted horizontal mattress sutures. The patient did well and was discharged home on postoperative day 5. A follow-up computed tomography (CT) 10 months later revealed some scarring along the left diaphragm but no hernia.

Case 2. A 50-year-old was diagnosed with stage IVB HGSO with involved supradiaphragmatic lymph nodes. Her past medical history was insignificant. Given her extent of disease, she was treated with NACT. She underwent IDS after four cycles of paclitaxel and carboplatin. Complete gross resection was achieved. The surgery included a splenectomy, left diaphragm peritonectomy, full thickness resection of the right diaphragm, resection of right mediastinal lymph nodes and insertion of a right-sided chest tube. She received an additional two cycles of chemotherapy after surgery. Approximately 18 months postoperatively, the patient was diagnosed with a left diaphragmatic hernia and underwent repair at an outside hospital. She has been asymptomatic since the hernia repair. No follow-up CT scan has been performed.

Case 3. A 45-year-old with stage IVB HGSO, and a history of Graves' disease status post total thyroidectomy, underwent PDS including bilateral diaphragm peritonectomy, splenectomy, resection of a right mediastinal lymph node and insertion of a right chest tube. She received adjuvant chemotherapy with paclitaxel and carboplatin. Bevacizumab was added with cycle three. Approximately 6 months after primary surgery, a CT scan revealed a small left hemidiaphragm hernia containing parts of the stomach (Fig. 2). Initially she was asymptomatic. She was followed closely. On follow-up she developed some mild symptoms, belching and infrequent right upper discomfort, especially when lying supine, and the follow-up CT showed an increase of the diaphragm defect. The defect in the diaphragm measured 4×6 cm and showed herniated stomach. Corrective surgery was performed robotically (Fig. 3) after she completed maintenance therapy with bevacizumab, and the defect was closed primarily using vertical mattress sutures and a continuous full thickness suture. The patient was discharged home on postoperative day 1. On follow-up her symptoms had resolved, and the chest x-ray two weeks after surgery showed no signs of a diaphragmatic hernia. No follow-up CT imaging has been performed as of this time.

Case 4. A 56-year-old patient with stage IVB HGSO underwent three

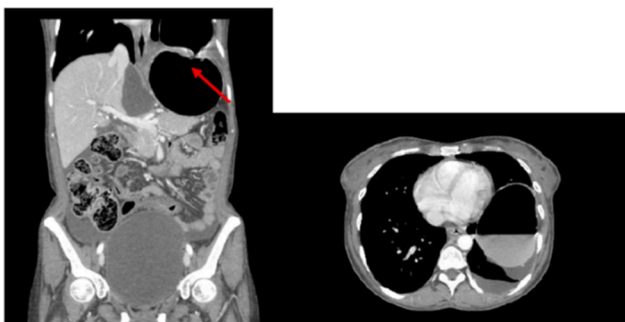

Fig. 1. Computed Tomography (CT) scan: left diaphragmatic hernia with incarceration of stomach in the chest (arrow).

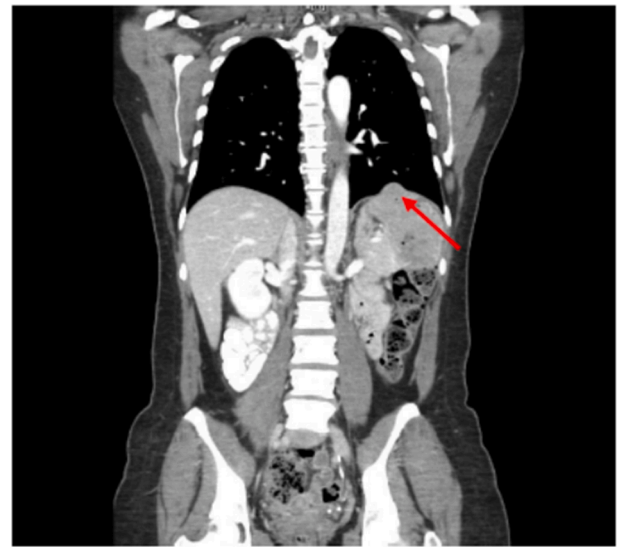

Fig. 2. Computed Tomography (CT) scan: small left diaphragmatic hernia (arrow).

cycles of NACT with paclitaxel and carboplatin, followed by IDS with a left-sided thoracoscopic procedure, left diaphragmatic peritonectomy, full thickness resection of the right diaphragm, resection of a liver lesion, partial gastrectomy with a gastrojejunostomy, small bowel resection with a side-to-side anastomosis, splenectomy, a modified posterior exenteration with end-to-end anastomosis and diverting loop ileostomy. The residual tumor was less than 5 mm. Her past medical history was significant for hepatitis B. Approximately 8 months after IDS, the patient had a CT scan which revealed progressive disease and an asymptomatic left diaphragm hernia containing bowel and stomach contents (Fig. 4). The patient underwent a left thoracotomy, reduction of the intrathoracic stomach and repair of the left diaphragm hernia with mesh reinforcement. She was discharged on postoperative day 2. A follow-up CT scan 1.5 months later showed a repaired diaphragm.

2. Discussion

In patients with advanced ovarian cancer, the diaphragm is frequently involved and generally must be stripped or resected in order to achieve complete gross resection at either PDS or IDS. Gynecologic oncologists should be trained to perform this step in a debulking surgery and to manage possible postoperative complications. The most common complications after diaphragm surgery are pleural effusion, pneumothorax and pneumonia (Papadia, A. and M. Morotti, *Diaphragmatic surgery during cytoreduction for primary or recurrent epithelial ovarian cancer: a review of the literature. Arch Gynecol Obstet*, 2013). The occurrence of a left diaphragmatic hernia after debulking surgery in ovarian cancer patients is a rare but significant complication that the surgeon should be familiar with. To our knowledge, this is the first case series reporting on patients with advanced ovarian cancer who developed left diaphragmatic hernias following cytoreductive surgery.

There is a total of three case reports in the published literature to date. These describe 4 patients who reportedly had left diaphragmatic hernias after surgery. One case report describes a patient with advanced ovarian cancer who underwent debulking surgery with hyperthermic intraperitoneal chemotherapy (HIPEC), and two case reports describe patients with other cancers who underwent cytoreductive surgery with HIPEC and developed hernias of the left diaphragm postoperatively (Caronna, 2013; Lampl, et al., 2014; Sorrentino, et al., 2017). The first case report, mentioned above, described a patient with advanced ovarian cancer who underwent a debulking surgery including bilateral diaphragm peritonectomy, cholecystectomy, and HIPEC. Approximately 4 months later, she presented with a gastric volvulus herniating

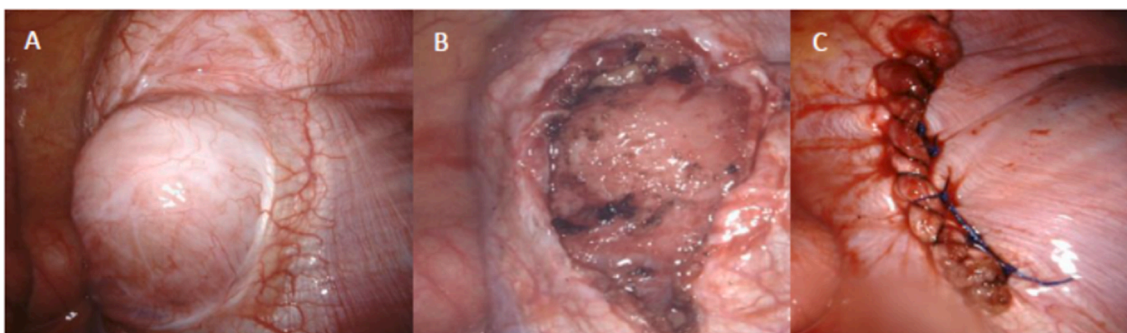


Fig. 3. Intraoperative imaging: robotic-assisted left diaphragm hernia repair. A: Left diaphragm hernia prior to surgery; B: After resection of the hernia sac; C: After suturing the defect.

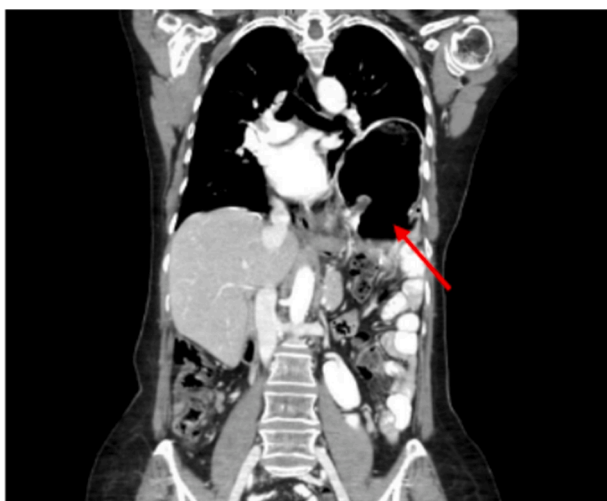

Fig. 4. Computed Tomography (CT) scan: large left diaphragmatic hernia with stomach and bowel content (arrow).

through the left diaphragm, which required emergency laparotomy and repair (Caronna, 2013). A second case report described a patient diagnosed with pseudomyxoma peritonei due to adenocarcinoma of the appendix. Cytoreductive surgery included right colectomy with an anastomosis of the ileum and transverse colon, partial gastrectomy, splenectomy, cholecystectomy, , peritonectomy of the right and left upper quadrant, , and HIPEC. The patient had symptoms of chest pain and dyspeptic disorder, and CT scan showed a left diaphragmatic hernia. This report also described a second patient with locally advanced gastric cancer, status post cytoreductive surgery including total gastrectomy, splenectomy and segment resection of the transverse colon, and HIPEC. Postoperatively she was diagnosed with a left-sided pleural abscess. A biopsy was performed on the abscess and showed intestinal contents, due to an anastomotic leak of the left colonic flexure communicating with the left hemithorax (Lampl, et al., 2014). The third published case report describes a patient with pseudomyxoma peritonei of the appendix, who underwent cytoreductive surgery including peritonectomy of the right and left upper quadrant, cholecystectomy, and HIPEC, and presented postoperatively with a left-sided diaphragmatic hernia (Sorrentino, et al., 2017).

The similarity between our cases and the cases in the published

Table 1
Summary of characteristics of our cohort and cases in the reviewed literature.

	Age (year)	Diagnosis	PDS/IDS	HIPEC	Splenectomy	Diaphragmatic peritonectomy	Time interval surgery to diagnosis diaphragm hernia	Hernia repair surgery
Case 1:	36	HGSOC IVB	PDS: CGR	No	Yes	Bilateral	5 months	Emergency surgery
Case 2:	50	HGSOC IVB	IDS: CGR	No	Yes	Left peritonectomy, right full thickness resection	18 months	Emergency surgery
Case 3:	45	HGSOC IVB	PDS: CGR	No	Yes	Bilateral	6 months	Elective surgery
Case 4:	56	HGSOC IVB	IDS: residual disease <5 mm	No	Yes	Left peritonectomy, right full thickness resection	8 months	Elective surgery
Caronna et al	51	Serous ovarian cancer IIIC	IDS: CGR	Yes	No	Bilateral	4 months	Emergency surgery
Lampl et al Case 1	36	Pseudomyxoma peritonei - highly differentiated adenocarcinoma of the appendix	PDS: N/A	Yes	Yes	Bilateral	N/A, discovered during follow up CT	Elective surgery
Lampl et al Case 2	65	Locally advanced gastric cancer	IDS: N/A	Yes	Yes	N/A	2 weeks	Emergency surgery
Sorrentino et al	50	Pseudomyxoma peritonei of the appendix	PDS: CGR	Yes	Yes s/p splenectomy 6 months prior due to trauma	Bilateral	15 months	Emergency surgery

Abbreviations: HGSOC, high-grade serous ovarian cancer; PDS, primary debulking surgery; IDS, interval debulking surgery; CGR, complete gross resection; N/A, not available; s/p, status post.

literature is that all but one patient had a splenectomy and all but one had a left diaphragm peritonectomy. However, all of the surgeries reported in the previous literature included HIPEC, whereas none of our cases included HIPEC (Table 1).

During the HIPEC procedure, there is increased intraabdominal pressure, which might put a patient who has received peritonectomy of the diaphragm with splenectomy at higher risk of developing a diaphragmatic hernia. Nevertheless, there could be other reasons why those patients developed hernias. Diaphragmatic peritonectomy leads to thinning of the diaphragm, which makes it more vulnerable. The right diaphragm is protected by the liver, while on the left side only an intact spleen provides protection from herniation. After splenectomy, the left diaphragm is exposed. In addition, the bowel is mobilized during a debulking surgery and may leave the diaphragm further prone to weakening. An additional consideration is that the diaphragm may become injured intraoperatively during splenectomy or diaphragm peritonectomy. This may be caused by thermal injury with electrocautery or by inadvertent perforation with a surgical instrument. Additionally, peritonectomy of the diaphragm might cause some ischemia of the diaphragm, ultimately weakening it and resulting in a diaphragm hernia. All of these factors may contribute to increased pressure on the diaphragm or weakening of the diaphragm, thereby leading to herniation.

Intraoperatively the diaphragm must be thoroughly checked for a defect. In the literature a “bubble test” has been described to identify such defects. The patient is positioned in shallow Trendelenburg and the upper quadrant is filled with saline. Air bubbles with inspiration would indicate a defect in the diaphragm (Kehoe et al., 2008; Eisenhauer and Chi, 2007). Even the smallest defect should be closed with a stitch to prevent the possible development of a hernia, or another sequelae such as pneumothorax. Once a diaphragmatic hernia is diagnosed, it is important that patients undergo a timely repair, to avoid the feared complication of bowel strangulation and incarceration. In fact, a hernia defect of any size requires surgical repair, as it will not close otherwise and will likely only expand over time (Siow, 2016). The thoracoabdominal pressure gradient will lead to widening of the diaphragmatic defect, allowing abdominal contents to herniate into the thoracic cavity (Sangster, et al., 2007). A monofilament, nonabsorbable or long-lasting absorbable suture like Polypropylene or Polydioxanone suture can be used to repair a diaphragm defect during a debulking surgery.

In summary, a left-sided diaphragmatic hernia after debulking surgery for ovarian cancer is a rare complication, but one that requires attention and intervention. Risk factors for hernia may include left diaphragm peritonectomy with splenectomy, and possibly HIPEC. After peritonectomy of the diaphragm, the diaphragm should be carefully checked for defects. If the defect is questionable or very large, an intraoperative thoracic surgery consultation should be considered. Use of a biodegradable mesh should also be considered. In debulking surgery there has been a paradigm shift to a more aggressive approach, in order to achieve complete gross resection. Therefore, it is possible that, in the future, more patients will present with a postoperative left-sided diaphragm hernia. Patients with diaphragmatic hernias may present with a variety of different symptoms, which can lead to a misdiagnosis. Once the hernia is diagnosed on imaging, prompt surgical correction should be considered.

3. Consent

Informed consent was obtained from the patients for publication of this report and accompanying images.

4. Disclosures

SE reports non-financial support from Tesaro, outside the submitted work. DRJ serves as a consultant for AstraZeneca and Merck, outside the submitted work. DSC reports personal fees from Bovie Medical Co.,

personal fees from Verthermia Inc. (now Apyx Medical Corp.), personal fees from C Surgeries, personal fees from Biom 'Up, other from Intuitive Surgical Inc., and other from TransEnterix Inc., outside the submitted work.

Funding

This research was supported in part by the NIH/NCI Memorial Sloan Kettering Cancer Center support grant P30 CA008748. This study was funded in part through the NIH/NCI Support Grant P30 CA008748.

CRediT authorship contribution statement

Sarah Ehmann: Conceptualization, Data curation, Formal analysis, Writing - original draft, Writing - review & editing. **Emeline M. Aviki:** Conceptualization, Data curation, Formal analysis, Supervision, Writing - review & editing. **Yukio Sonoda:** Writing - review & editing. **Thomas Boerner:** Writing - review & editing. **Dib Sassine:** Writing - review & editing. **David R. Jones:** Writing - review & editing. **Bernard Park:** Writing - review & editing. **Murray Cohen:** Writing - review & editing. **Norman G. Rosenblum:** Writing - review & editing. **Dennis S. Chi:** Conceptualization, Data curation, Formal analysis, Supervision, Writing - review & editing.

Declaration of Competing Interest

The authors declare that they have no known competing financial interests or personal relationships that could have appeared to influence the work reported in this paper.

References

- Ferlay, J., et al., 2015. Cancer incidence and mortality worldwide: sources, methods and major patterns in GLOBOCAN 2012. *Int. J. Cancer* 136 (5), E359–86.
- Minig, L., et al., 2015. Selecting the best strategy of treatment in newly diagnosed advanced-stage ovarian cancer patients. *World J. Methodol.* 5 (4), 196–202.
- Eisenhauer, E.L., et al., The addition of extensive upper abdominal surgery to achieve optimal cytoreduction improves survival in patients with stages IIIC-IV epithelial ovarian cancer. *Gynecol Oncol*, 2006. 103(3): p. 1083-90.
- Kang, S., et al., Is neo-adjuvant chemotherapy a “waiver” of extensive upper abdominal surgery in advanced epithelial ovarian cancer? *Ann Surg Oncol*, 2011. 18(13): p. 3824-7.
- Filippova, O.T., et al., 2019. Trends in specific procedures performed at the time of cytoreduction for ovarian cancer: Is interval debulking surgery truly less radical? *Gynecol Oncol* 154, 142–143. <https://doi.org/10.1016/j.ygyno.2019.04.337>.
- Sandadi, S., et al., Postoperative outcomes among patients undergoing thoracostomy tube placement at time of diaphragm peritonectomy or resection during primary cytoreductive surgery for ovarian cancer. *Gynecol Oncol*, 2014. 132(2): p. 299-302.
- Spellar, K. and N. Gupta, Diaphragmatic Hernia, in *StatPearls*. 2020: Treasure Island (FL).
- Tsuboi, K., et al., Delayed traumatic diaphragmatic hernia after open splenectomy: report of a case. *Surg Today*, 2008. 38(4): p. 352-4.
- Scharff, J.R. and K.S. Naunheim, Traumatic diaphragmatic injuries. *Thorac Surg Clin*, 2007. 17(1): p. 81-5.
- Papadia, A. and M. Morotti, Diaphragmatic surgery during cytoreduction for primary or recurrent epithelial ovarian cancer: a review of the literature. *Arch Gynecol Obstet*, 2013. 287(4): p. 733-41.
- Caronna, R., et al., 2013. Intrathoracic gastric volvulus as a severe, delayed surgical complication after left subphrenic peritonectomy and hyperthermic intraperitoneal chemotherapy (HIPEC) for advanced ovarian cancer. *World J. Surg. Oncol.* 11, 239.
- Lampl, B., et al., Rare diaphragmatic complications following cytoreductive surgery and HIPEC: report of two cases. *Surg Today*, 2014. 44(2): p. 383-6.
- Sorrentino, L., et al., A rare case of diaphragmatic hernia after cytoreductive surgery and hyperthermic intraperitoneal chemotherapy. *Journal of Peritoneum (and other serosal surfaces)*, 2017; 2(75): 95-8.
- Kehoe, S.M., Eisenhauer, E.L., Chi, D.S., 2008. Upper abdominal surgical procedures: liver mobilization and diaphragm peritonectomy/resection, splenectomy, and distal pancreatectomy. *Gynecol Oncol* 111 (2 Suppl), S51–5.
- Eisenhauer, E.L. and D.S. Chi, Liver mobilization and diaphragm peritonectomy/resection. *Gynecol Oncol*, 2007. 104(2 Suppl 1): p. 25-8.
- Siow, S.L., et al., 2016. Successful laparoscopic management of combined traumatic diaphragmatic rupture and abdominal wall hernia: a case report. *J. Med. Case Rep.* 10, 11.
- Sangster, G., et al., Diaphragmatic rupture: a frequently missed injury in blunt thoracoabdominal trauma patients. *Emerg Radiol*, 2007. 13(5): p. 225-30.