



Received: 2016.06.16
Accepted: 2016.06.18
Published: 2016.10.13

Authors' Contribution:

- A** Study Design
- B** Data Collection
- C** Statistical Analysis
- D** Data Interpretation
- E** Manuscript Preparation
- F** Literature Search
- G** Funds Collection

Evaluation the Aortic Aneurysm Remodeling After a Successful Stentgraft Implantation

Monika Nowicka^{1ABEF}, Agnieszka Kowalczyk^{1ABEF}, Grażyna Rusak^{2ABCDEF},
Przemysław Ratajczak^{2D}, Bartosz Sobociński^{2D}

¹ Faculty of Medicine, Collegium Medicum, Nicolaus Copernicus University, Bydgoszcz, Poland

² Department of Radiology and Diagnostic Imaging, Nicolaus Copernicus University in Toruń, Collegium Medicum in Bydgoszcz, Poland

Author's address: Grażyna Rusak, Department of Radiology and Diagnostic Imaging, Nicolaus Copernicus University, Collegium Medicum, M. Skłodowskiej-Curie 9 Str., 85-094 Bydgoszcz, Poland, e-mail: g.rusak@cm.umk.pl

Summary

Background:

Routine imaging follow-up after endovascular treatment of abdominal aortic aneurysms (EVAR) is mainly aimed at detection of endoleaks. The aim of the study was to assess changes in the size of the abdominal aortic aneurysm sack using CT angiography (CTA) after successful treatment using endovascular stent graft implantation.

Material/Methods:

A retrospective analysis of CTA results included 102 patients aged 54–88, who had no postoperative complications. Patients underwent CTA before EVAR and after the treatment (mean time between studies, 7.6 months). The largest cross-sectional area of the aneurysm sac was measured using a curved multiplanar reconstruction. A change of the aneurysm cross-sectional over 10% was considered significant.

Results:

The average cross-sectional area decreased after EVAR by 3% and this change was not statistically significant. Regression of the cross-sectional area was observed in 18.6% of patients, progression was in 23.5%, and no change was seen in 57.8%. Cross-sectional areas before and after EVAR were significantly correlated ($r=0.75$, $p<0.0001$). There was no correlation between the cross-sectional area change after EVAR and patients' age or the time between the treatment and the follow-up CTA. Cross-sectional area before the treatment predicted changes in the aneurysm size after EVAR ($p=0.0045$).

Conclusions:

Remodeling of abdominal aortic aneurysms after EVAR is not uniform. The change of aneurysm size depends on the initial aneurysm size but not on the time from EVAR. The size of the aneurysm after EVAR should not be considered as a measure of the treatment efficacy.

MeSH Keywords:

Angiography • Aortic Aneurysm, Abdominal • Endovascular Procedures • Multidetector Computed Tomography

PDF file:

<http://www.polradiol.com/abstract/index/idArt/900116>

Background

Abdominal aortic aneurysm (AAA) is defined as at least 1.5-fold increase in diameter of the abdominal aorta compared to its normal size, or widening of more than 3 cm along the maximal diameter [1]. AAA occurs 3-4 times more often in males than females [1]. It is estimated that it affects approximately 4-8% of men and ca. 1-2% of women aged above 65 [2-4].

Qualification and planning of surgical treatment of an abdominal aortic aneurysm is based on two essential criteria, i.e. its maximal diameter and growth rate. In recent years, indications for endovascular aneurysm repair (EVAR) have been expanded. Although EVAR is a minimally invasive technique, patients treated using this method require systematic imaging control in order to determine the effectiveness of the procedure, detect possible complications and verify the need for secondary procedures [5,6]. In clinical practice, EVAR is considered successful when an

Table 1. Cross-sectional area measurements for aneurysms.

Parameter	Mean value (SD)		Minimal value	Maximal value
Cross-sectional area before surgery [cm ²]	29.1	(14.3)	5.6	106.3
Cross-sectional area after surgery [cm ²]	28.5	(14.5)	5.8	110.8
Change of the area	-3%	(-29%)	-118%	130%

endoleak is excluded, there is no progression of the aneurysm outside the stent region and the patient's symptoms resolve [7]. There is limited knowledge about the processes involving thrombus after implantation of a stent graft and the purpose of measuring the aneurysm after successful EVAR.

The aim of the study was to assess the change in size of an abdominal aortic aneurysm using CT angiography (CTA) after successful endovascular aneurysm repair.

Material and Methods

CTA scans of the abdominal aorta in 102 consecutive patients aged 54 to 88 (involving 16 women and 86 men) were a subject to a retrospective analysis. The inclusion criteria were as follows: routine control of the abdominal aorta after EVAR, infrarenal aortic location of EVAR and good technical quality of the scan. The exclusion criteria included: placement of an atypical stent graft (custom-made, fenestrated, branched, Nellix), postoperative complications requiring reoperation, long-term complications found on CTA (significant angulations, contrast media leakage, migration of the stent).

The patients underwent CTA prior to EVAR and 1 to 41 months after the intervention (the mean time between scans was 7.6 months). CTA scans were performed using Siemens DEFINITION AS+ tomograph, after administration of Ultravist 370 contrast agent in the dose of 70 ml with 4 ml/s flow, with layer thickness of 1 mm. The maximal transverse and anteroposterior (AP) diameters were measured on multiplanar reconstruction, and the area of the cross-section was calculated. The measurements were obtained using GE AW VolumeShare 5 diagnostic station.

Parametric data were presented in terms of mean value and standard deviation (SD). The greatest cross-sectional areas before and after EVAR were compared, while only differences of more than 10% were considered significant. Relationships between the studied variables were assessed using the Spearman's correlation rank coefficient. To assess parameters between the groups, the Kruskal-Wallis test was implemented. The statistical analysis was conducted using Statistica 10 software (StatSoft Inc., Tulsa, OK), as well as MedCalc Statistical Software v. 13.3 (MedCalc Software bvba, Ostend, Belgium). $P < 0.05$ was considered significant.

Results

Mean cross-sectional areas prior to and following EVAR did not differ significantly (Table 1) and the mean area change

was 3%. A decrease of cross-sectional area was observed in 19 patients (18.6%) – Figure 1A, progression – in 24 (23.5%) – Figure 1B, and no change in size in 59 (57.8%) – Figure 2.

No relationship was found between the time since the stent grafting and the patient's age, in relation to change in size of the aneurysm. The cross-sectional area after EVAR was significantly correlated with the initial size of the aneurysm ($r=0.75$, $p < 0.0001$) – Figure 3. A weak significant correlation was shown between the initial size of an aneurysm and the size change after treatment ($r=0.38$, $p=0.0021$) – Figure 4. The greatest tendency for regression after EVAR was observed in aneurysms with smaller initial cross-sectional area. However, aneurysms with greater initial size showed regression or no significant change of their area between the scans – Figure 5. The initial cross-sectional area of an aneurysm was a predictive factor of its change in size after procedure ($p=0.0045$).

Discussion

Abdominal aortic aneurysms are an important health issue in individuals above the age of 65, and it is 3–4 times more frequent in males than females [1–3]. Most aneurysms are located infrarenally (>80%), and less often they are located juxta- or suprarenally. AAA formation is a result of weakening of the aortic wall, which leads to focal dilation of the vessel [4]. Usually, it develops without causing any symptoms or the associated symptoms are atypical. The diagnosis is often made only after the rupture of the aneurysm or during autopsy [8]. According to population studies, 66% of patients with a ruptured aneurysm die before the surgery can start, and 41–48% during the emergency intervention [9–11].

Despite possible complications, such as leakage, stent migration or obstruction [12–14], endovascular techniques become increasingly common in abdominal aortic aneurysm management, especially in the case of its infrarenal location. The studies showed that EVAR is effective in preventing rupture of an aneurysm and presents certain benefits compared to open surgery, including shorter hospital stay and improved quality of life [12,15–18]. Moreover, EVAR reduces the overall mortality related to aneurysm compared to open surgery, which is a fundamental endpoint [19].

CTA is a basic method of qualification for endovascular procedures and control of therapeutic outcomes [20–25]. In the case of EVAR, it brings data that are crucial to perform the procedure, namely it determines location of the aneurysm in relation to other anatomical structures, it is used to assess the proximal and distal region of the

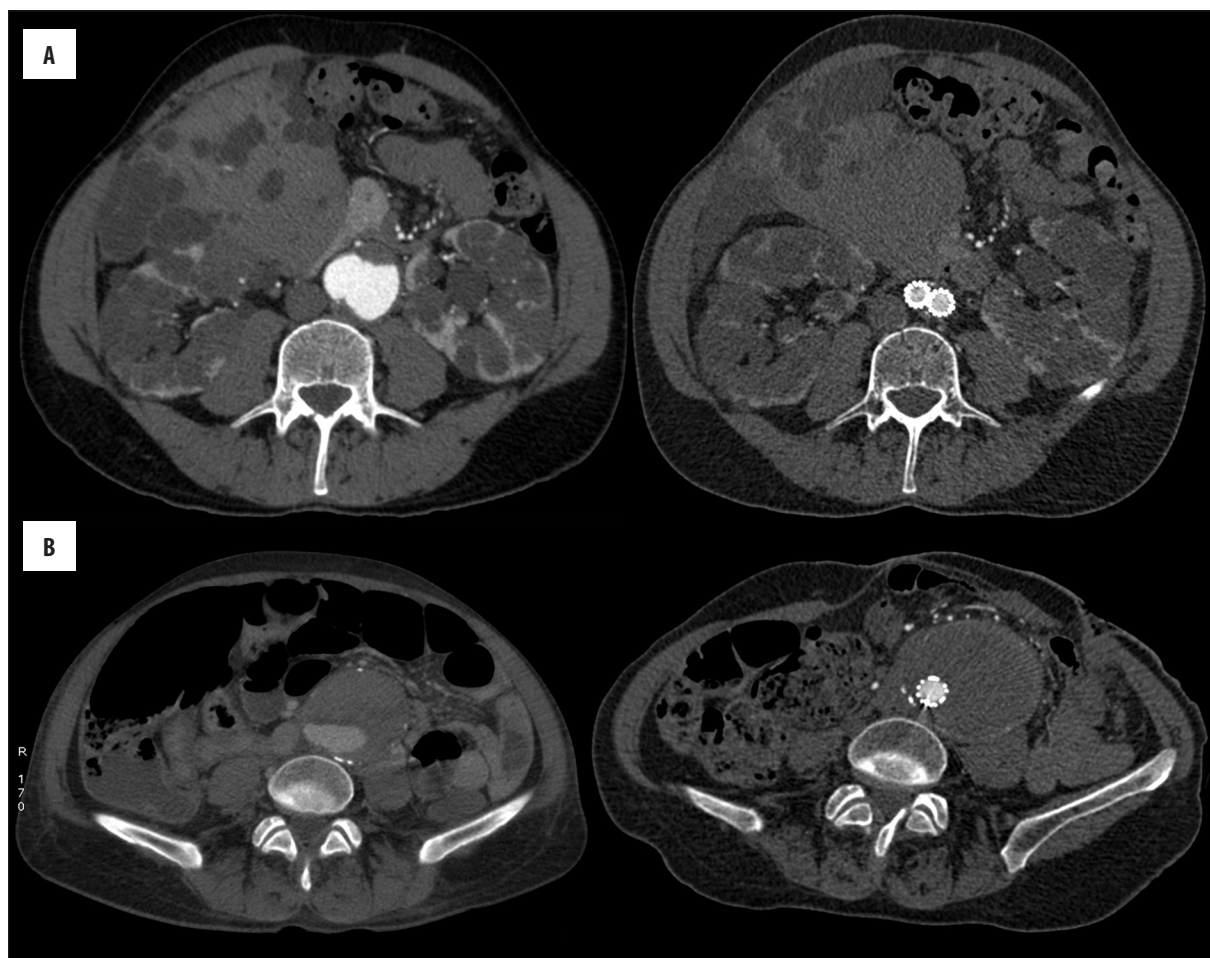


Figure 1. An example of aneurysms, which presented regression (A) and progression (B) after EVAR.

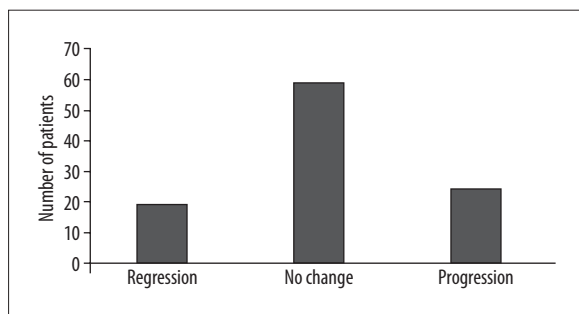


Figure 2. Number of analyzed aneurysms, in which regression, progression or no change between the scans were observed.

implantation site and it allows to assess the iliac arteries [20]. Furthermore, CTA allows to check the proper positioning of the stent after EVAR, detect possible complications (e.g. leakage, breaking of the material) and to assess the change in size of the aneurysm. The most commonly used method for determination of change in size of an aneurysm is to measure its maximal diameter [7,26–31]. In this study, the area of the largest cross-section was measured in order to prevent the error relating to the shape of an aneurysm.

According to the guidelines by EUROSTAR and the German Society for Vascular Surgery [32], CTA is recommended in the first year after intervention at 3, 6 and 12-month

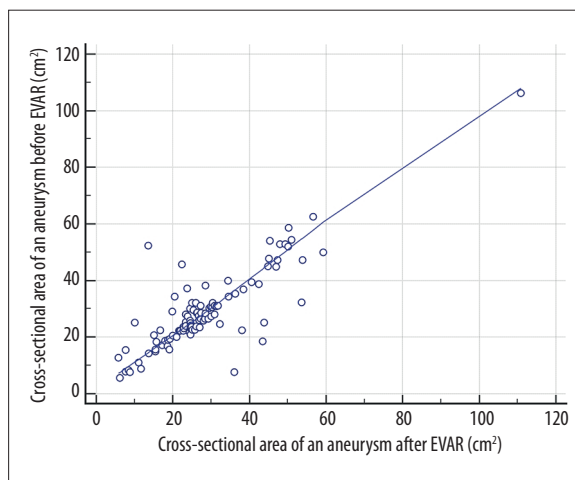


Figure 3. Relationship between the cross-sectional area of an aneurysm before and after EVAR.

intervals, and after that, it is recommended to repeat the scan every year, and later every two years. However, it is associated with radiation exposure of, on average, 145–205 mSv in the course of 5 years. Exposure to radiation of 145 mSv during CTA scan correlates with the risk of developing cancer, ranging from 0.42% (1 in 240 patients) for a 70-year old male to 0.73% (1 in 140 patients) for a

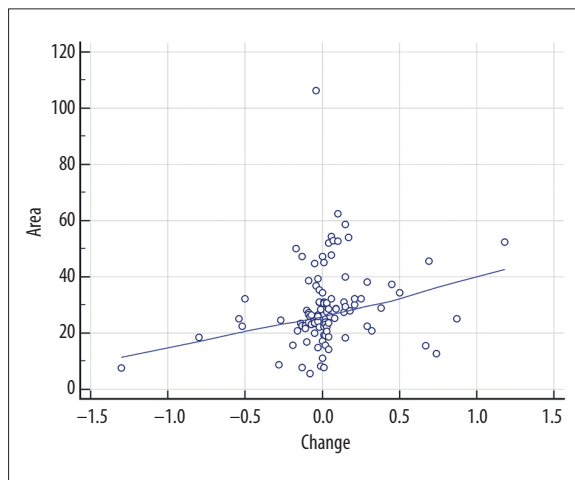


Figure 4. Relationship between the cross-sectional area of an aneurysm and its size after EVAR.

50-year old female [33]. For this reason, the scientific basis of such guidelines is disputable [34].

Some authors consider reduction in size of an aneurysm to be an indicator of a successful EVAR [35-36]. For instance, in the study by Wolf et al., the diameter of an aneurysm decreased by 0.28-0.34mm/month after EVAR [37]. In our study, however, most aneurysms (57.8%) did not change their size significantly, and only approximately one out of four (23.5%) became smaller. In the study by Nityanand et al., a statistically significant reduction in size of an aneurysm was observed in 43% of patients who underwent a planned EVAR [38]. Baumüller et al. defined a significant increase in size of an aneurysm as a change of its

References:

1. Scott RA, Wilson NM, Ashton HA, Kay D: Influence of screening on the incidence of ruptured abdominal aortic aneurysm: 5-year results of a randomised controlled study. *Br J Surg*, 1995; 82: 1066-70
2. Vardulaki KA, Walker NM, Couto E et al: Late results concerning feasibility and compliance from a randomized trial of ultrasonographic screening for abdominal aortic aneurysm. *Br J Surg*, 2002; 89: 861-64
3. Scott RA, Bridgewater SG, Ashton HA: Randomized clinical trial of screening for abdominal aortic aneurysm in women. *Br J Surg*, 2002; 89: 283-85
4. Alcorn HG, Wolfson SK Jr., Sutton-Tyrell K: Risk factors for abdominal aortic aneurysms in older adults enrolled in Cardiovascular Health Study. *Arterioscler Thromb Vasc Biol*, 1996; 16: 963-70
5. May J: Symposium on distortion and structural deterioration of endovascular grafts used to repair abdominal aortic aneurysms. *J Endovasc Surg*, 1999; 6: 1-3
6. Harris P, Brennan J, Martin J et al: Longitudinal aneurysm shrinkage following endovascular aortic aneurysm repair: A source of intermediate and late complications. *J Endovasc Surg*, 1999; 6: 11-16
7. White RA, Donayre CE, Walot I et al: Computed tomography assessment of abdominal aortic aneurysm morphology after endograft exclusion. *J Vasc Surg*, 2001; 33: S1-10
8. Fink HA, Lederle FA, Roth CS et al: The accuracy of physical examination to detect abdominal aortic aneurysm. *Arch Intern Med*, 2000; 160: 833-36
9. Bengtsson H, Bergqvist D: Ruptured abdominal aortic aneurysm: a population-based study. *J Vasc Surg*, 1993; 18: 74-80
10. Visser P, Akkersdijk GJ, Blankensteijn JD: In-hospital operative mortality of ruptured abdominal aortic aneurysm: A population-based analysis of 5593 patients in The Netherlands over a 10-year period. *Eur J Vasc Endovasc Surg*, 2005; 30: 359-64
11. Bown MJ, Sutton AJ, Bell PR, Sayers RD: A meta-analysis of 50 years of ruptured abdominal aortic aneurysm repair. *Br J Surg*, 2002; 89: 714-30
12. Parodi JC, Palmaz JC, Barone HD: Transfemoral intraluminal graft implantation for abdominal aortic aneurysms. *Ann Vasc Surg*, 1991; 5(6): 491-99
13. Woodburn KR, May J, White GH: Endoluminal abdominal aortic aneurysm surgery. *Br J Surg*, 1998; 85: 435-43
14. May J, White G, Waugh R et al: Treatment of complex abdominal aortic aneurysms by a combination of endoluminal and extraluminal aortofemoral grafts. *J Vasc Surg*, 1994; 19: 924-33
15. Moore WS, Rutherford RB: Transfemoral endovascular repair of abdominal aortic aneurysm: Results of the North American EVT phase I trial. *J Vasc Surg*, 1996; 23(4): 543-53
16. White GH, May J, Mcgahan T et al: Historic control comparison of outcome for endoluminal versus open repair of abdominal aortic aneurysms. *J Vasc Surg*, 1996; 23(2): 201-12
17. Brewster DC, Geller SC, Kaufman JA et al: Initial experience with endovascular aneurysm repair: Comparison of early results with outcome of conventional open repair. *J Vasc Surg*, 1998; 27(6): 992-1005
18. Zarins CK, White RA, Schwarten D et al: Aneurysm repair: open surgical repair of abdominal aortic aneurysms: Multicenter prospective clinical trial. *J Vasc Surg*, 1999; 29(5): 292-308
19. Arko FR, Lee WA, Hill BB et al: Aneurysm-related death: Primary endpoint analysis for comparison of open and endovascular repair. *J Vasc Surg*, 2002; 36(2): 297-304

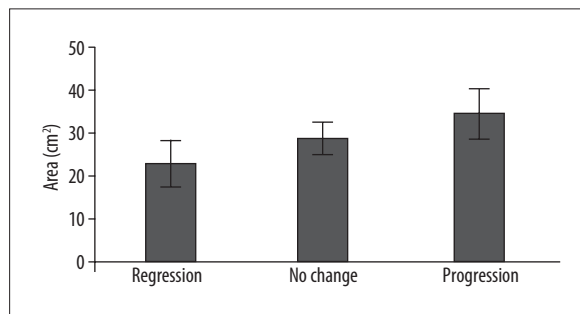


Figure 5. The initial size of aneurysms, which decreased, enlarged or did not show any change after procedure.

diameter by 0.5 cm and volume by 10% and they observed such an increase in 8% of patients. In another 8%, they also found a small type II leak, but, according to their studies, the presence of endoleaks does not influence the change of the maximal size of an aneurysm [39]. Wolf and et. state, however, that a significantly larger decrease in size of an aneurysm can be observed in patients, who did not present endoleaks, compared to patients with endoleaks [37].

Conclusions

Abdominal aortic aneurysms change their size in various ways after stent implantation. The change in size of an aneurysm does not depend on the time since the intervention, but rather on its initial size. It seems that the behavior presented by an aneurysm after EVAR is influenced by its initial mechanical properties, not the hemodynamic effect of the procedure. The size of an aneurysm following EVAR should not be used to assess the effectiveness of treatment.

20. Apfalter P, Hanna EL, Schoepf UJ et al: Radiation dose and image quality at high-pitch CT angiography of the aorta: Intraindividual and interindividual comparisons with conventional CT angiography. *Am J Roentgenol*, 2012; 199(6): 1402-9
21. White HA, Macdonald S: Estimating risk associated with radiation exposure during follow-up after endovascular aortic repair (EVAR). *J Cardiovasc Surg*, 2010; 51: 95-104
22. Iezzi R, Cotroneo AR: Endovascular repair of abdominal aortic aneurysms: CTA evaluation of contraindications. *Abdom Imaging*, 2006; 31: 722-31
23. Serafin Z, Strzeńniewski P, Lasek W, Beuth W: Follow-up after embolization of ruptured intracranial aneurysms: A prospective comparison of two-dimensional digital subtraction angiography, three-dimensional digital subtraction angiography, and time-of-flight magnetic resonance angiography. *Neuroradiology*, 2012; 54(11): 1253-60
24. Serafin Z, Strzeńniewski P, Lasek W, Beuth W: Comparison of remnant size in embolized intracranial aneurysms measured at follow-up with DSA and MRA. *Neuroradiology*, 2012; 54(12): 1381-88
25. Łukasiewicz A, Mindykowski R, Serafin Z: The influence of carotid endarterectomy on cerebral blood flow in significant carotid stenosis-perfusion computed tomography study. *Int Angiol*, 2014; 33(4): 309-15
26. Chaikof EL, Blankensteijn JD, Harris PL et al: Reporting standards for endovascular aortic aneurysm repair. *J Vasc Surg*, 2002; 35: 1048-60
27. Parry DJ, Kessel DO, Robertson I et al: Type II endoleaks: Predictable, preventable, and sometimes treatable? *J Vasc Surg*, 2002; 36: 105-10
28. Beebe HG, Cronenwett JL, Katzen BT et al: Results of an aortic endograft trial: Impact of device failure beyond 12 months. *J Vasc Surg*, 2001; 33: S55-63
29. Wolf YG, Hill BR, Rubin GD et al: Rate of change in abdominal aortic aneurysm diameter after endovascular repair. *J Vasc Surg*, 2000; 32: 108-15
30. Parent FN, Meier GH, Godziachville V et al: The incidence and natural history of type I and II endoleak: A 5-year follow-up assessment with color duplex ultrasound scan. *J Vasc Surg*, 2002; 35: 474-81
31. Heilberger P, Schunn C, Ritter W et al: Postoperative color-flow duplex scanning in aortic endografting. *J Endovasc Surg*, 1997; 4: 262-71
32. Harris PL, Buth J, Mialhe C et al: The need for clinical trials of endovascular abdominal aortic aneurysm stent-graft repair: The EUROSTAR Project. EUROpean collaborators on Stent-graft Techniques for abdominal aortic Aneurysm Repair. *J Endovasc Surg*, 1997; 4: 72-77 discussion 78-79
33. White HA, Macdonald S: Estimating risk associated with radiation exposure during follow-up after endovascular aortic repair (EVAR). *J Cardiovasc Surg*, 2010; 51: 95-104
34. Sardanelli F, Bashir H, Berzaczy D et al: The role of imaging specialists as authors of systematic reviews on diagnostic and interventional imaging and its impact on scientific quality: Report from the EuroAIM Evidence-based Radiology Working Group. *Radiology*, 2014; 272(2): 533-40
35. White RA, Donayre CE, Walot I et al: Computed tomography assessment of abdominal aortic aneurysm morphology after endograft exclusion. *J Vasc Surg*, 2001; 33: S1-10
36. Parent FN, Meier GH, Godziachville V et al: The incidence and natural history of type I and II endoleak: A 5-year follow-up assessment with color duplex ultrasound scan. *J Vasc Surg*, 2002; 35: 474-81
37. Wolf YG, Hill BB, Rubin GD et al: Rate of change in abdominal aortic aneurysm diameter after endovascular repair. *J Vasc Surg*, 2000; 32: 108-15
38. Arya N, Lee B, Loan W et al: Change in aneurysm diameter after stent-graft repair of ruptured abdominal aortic aneurysms. *J Endovasc Ther*, 2004; 11: 319-22
39. Baumüller S, Nguyen TD, Goetti RP et al: Maximum diameter measurements of aortic aneurysms on axial CT images after endovascular aneurysm repair: Sufficient for follow-up? *Cardiovasc Intervent Radiol*, 2011; 34: 1182-89