

# Laparoscopic Resection of an Adrenal Schwannoma

Toutouzas G. Konstantinos, MD, PhD, Tsamis Dimitrios, MD, MSc, Kekis B. Panagiotis, MD, PhD, Michalopoulos V. Nikolaos, MD, PhD, Flessas Ioannis, MD, Manouras Andreas, MD, PhD, Zografos Geogrios, MD, PhD

## ABSTRACT

**Background and Objectives:** Schwannomas are tumors originating from Schwann cells of the peripheral nerve sheath (neurilemma) of the neuroectoderm. Rarely, schwannomas can arise from the retroperitoneum and adrenal medulla. We describe a case of a 71-y-old woman who presented with an incidentally discovered adrenal tumor.

**Methods:** Ultrasound and computed tomography scans revealed a lesion with solid and cystic areas originating from the left adrenal gland. The patient underwent complete laparoscopic resection of the tumor and the left adrenal gland.

**Results:** Histopathological examination and immunohistochemical staining of the excised specimen revealed a benign schwannoma measuring 5.5×5×3.7 cm. To our knowledge, few other cases of laparoscopic resection of adrenal schwannomas have been reported.

**Conclusion:** Because preoperative diagnosis of adrenal tumors is inconclusive, complete laparoscopic excision allows for definitive diagnosis with histological evaluation and represents the treatment of choice.

**Key Words:** Laparoscopy, Adrenal gland, Schwannoma.

## INTRODUCTION

Neural sheath tumors are a subgroup of soft tissue neoplasms that include both benign and malignant schwannomas.<sup>1-3</sup> Schwannomas, also referred to as neurilemmomas or neurinomas, generally are benign and occur as solitary tumors from the cranial and peripheral nerves of the head, neck, extremities, and stomach. Additionally, they may arise from the retroperitoneal space, spinal nerves, and less frequently the adrenal medulla in the adrenal glands.<sup>4-9</sup> This latter localization is extremely rare, and only a few case reports can be found in the medical literature. Studies have shown that approximately 0.5% to 5% of schwannomas are retroperitoneal, constituting <0.2% of adrenal incidental tumors.<sup>10</sup>

The most common clinical presentation of a retroperitoneal schwannoma is a vague abdominal or dull flank pain and discomfort. Nevertheless, most schwannomas in the adrenal glands are commonly detected incidentally by imaging of the abdomen and retroperitoneal space for irrelevant reasons or during autopsy.<sup>11-13</sup>

Schwannomas are tumors that originate primarily from neural crest cells. The role of Schwann cells is to produce the myelin sheath that covers peripheral nerves. Most often, malignant schwannomas are associated with neurofibromatosis types 1 and 2.<sup>14-18</sup> Histologically, they are distinguished by the presence of areas with high and low cellularity, called Antoni A and Antoni B, respectively.<sup>9,14</sup> Diagnosis of a schwannoma is based on detection of spindle cells with Antoni A and Antoni B regions in histological sections and positive staining for S-100 protein by immunohistochemical analysis.<sup>19-22</sup>

We report a case of an incidentally discovered and laparoscopically excised retroperitoneal schwannoma arising from the left adrenal gland. A brief review of the corresponding literature is also presented.

## CASE REPORT

A 71-y-old woman was referred to our institution with a retroperitoneal left adrenal mass that was incidentally found by ultrasound 3 mo prior. The patient complained of an intermittent, vague left flank pain with dorsal reflection during the last 6-mo period. Her medical history revealed mild hypertension under medication and an operation of appendicectomy 47 y

First Department of Propaedeutic Surgery, Hippokrateion General Hospital, Athens Medical School, University of Athens, Greece (all authors).

Address correspondence to: Tsamis Dimitrios, MD, MSc, 7 Kalvou Street, 11473 Athens, Greece. Phone: 0030 6937334858, Fax: 0030 2107792819, E-mail: tsamisdim@hotmail.com

DOI: 10.4293/108680812X13517013316753

© 2012 by JSLS, *Journal of the Society of Laparoendoscopic Surgeons*. Published by the Society of Laparoendoscopic Surgeons, Inc.

earlier. She had no remarkable family history. Physical examination of her abdomen revealed no palpable mass. The patient had no cutaneous lesions or palpable lymphadenopathy.

Routine blood tests of the patient were normal, and the 24-h urinary catecholamines, cortisol, and chromogranin values were within normal ranges. Ultrasonography demonstrated a 6 cm in maximal diameter heterogeneous expansive mass near the left adrenal. A computed tomography (CT) scan of the abdomen confirmed the ultrasound finding and revealed an 8.2 cm in diameter heterogeneous mass with both solid and cystic components arising from the left adrenal gland (**Figure 1**). Taking into account the size of the tumor and after informed consent was received from the patient, the authors proceeded with surgical treatment. The patient underwent a laparoscopic resection of the lesion, as well as an en bloc excision of the left adrenal gland. The patient, whose postoperative course was uneventful, was discharged on the third postoperative day.

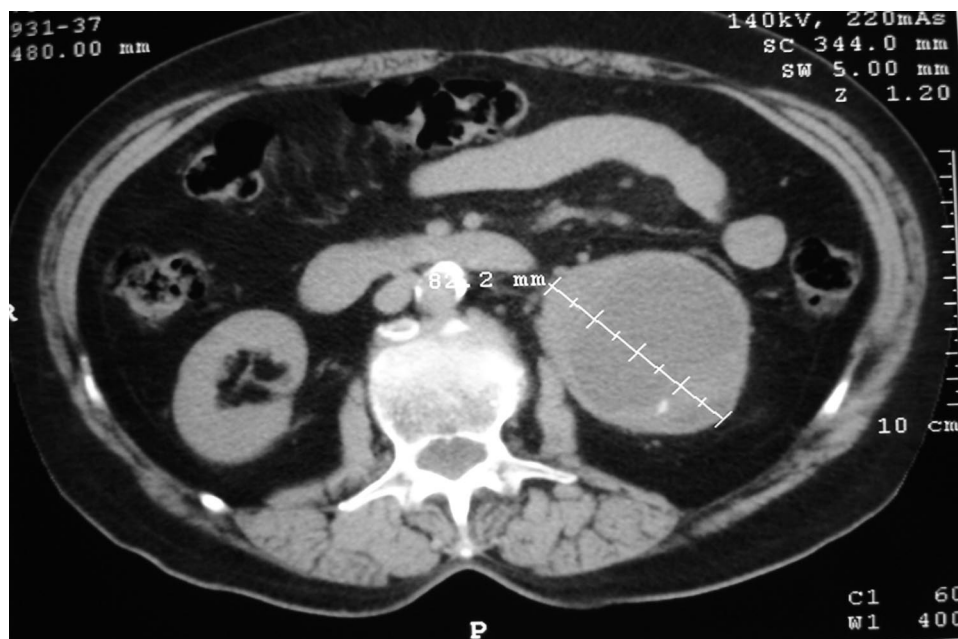
### Surgical Technique

The patient was positioned in the right lateral decubitus position, and a 4-trocar technique was used.<sup>20,23,24</sup> After thorough laparoscopic inspection of the abdominal cavity, the left upper abdominal quadrant was explored with special attention given to examination of the subphrenic space and costal margins. With careful dissection using

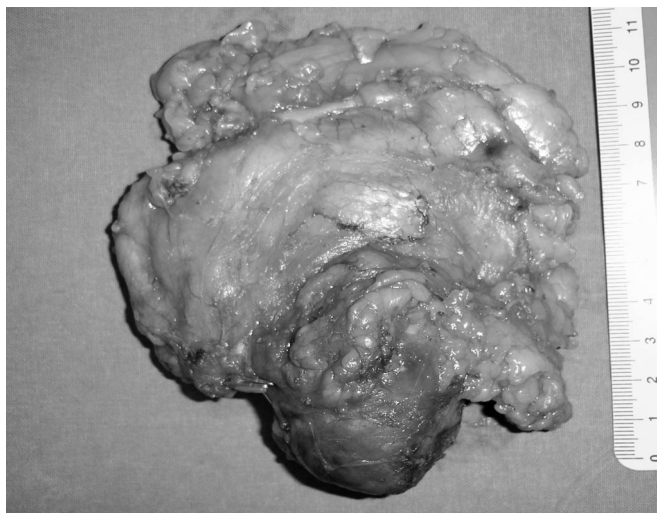
blunt maneuvers and Harmonic scalpel (Ethicon Endosurgery, Cincinnati, OH), the left adrenal vein was identified and dissected. Thereafter, the mass and the left adrenal gland were dissected and removed.

The operative time was approximately 1 h and 55 min, and intraoperative blood loss was approximately 100 mL. A drain was installed; it was withdrawn on the second postoperative day. The patient proceeded to oral intake on the first postoperative day and was discharged on the third postoperative day.

Histological examination of the resected specimen revealed macroscopically a capsulated mass, which measured 5.5×5×3.7 cm and consisted of cystic and solid bright-yellow areas (**Figure 2**). Microscopic examination showed that the lesion was composed of Antoni A areas, where short spindle cells with a long conical nucleus and scant cytoplasm aggregated and formed a spiral structure, and Antoni B areas, where inflammatory cells were scattered within a loose matrix (**Figure 3**). The tumor represented benign characteristics. Within the lesion, cells undergoing cell division were not abundant, and in the hyaline vascular structure, lymphocytes were detected. Hemorrhage, hemosiderin deposition, calcification, inflammatory cell infiltration by siderophages, and histiocytes were also present. In immunohistochemical analyses, the tumor did not stain for c-kit (CD117), CD34, or SMA, but stained strongly for S-100 protein and CD68 (**Figure 4**).



**Figure 1.** Computed tomography showing an 82.2-mm, well-circumscribed, enhanced round tumor with solid and cystic components arising from the left adrenal gland.



**Figure 2.** Photograph showing the gross appearance of the resected encapsulated tumor.

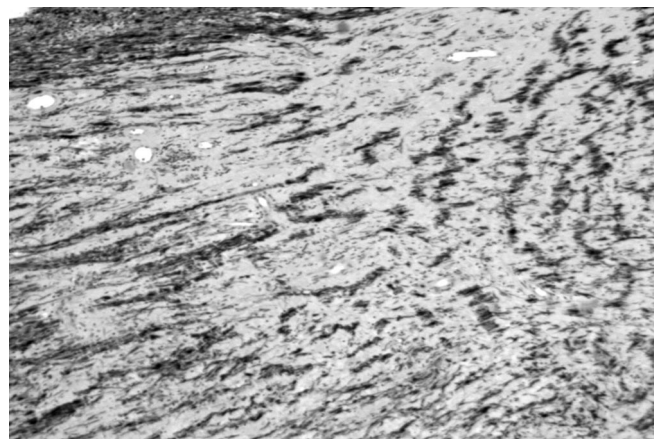


**Figure 3.** Microscopic view showing benign schwannoma cells, along with alternating Antoni A and Antoni B patterns with fibrinoid degeneration, thrombosis, and hyalinization (H&E, magnification  $\times 100$ ).

After a 6-mo follow-up period, the patient remained asymptomatic, and there was no evidence of locoregional recurrence or distant metastasis.

## DISCUSSION

Schwannomas are uncommon tumors arising from Schwann cells of the peripheral nerve sheaths.<sup>25–27</sup> Verocay was the first to present histologically a tumor that occurred by neurons.<sup>28</sup> Masson elucidated that these tumors originate from Schwann cells and termed them schwannomas.<sup>29</sup> Most these



**Figure 4.** Immunohistochemical stain positive for S-100 protein ( $\times 400$ ).

tumors originate from cranial nerves or peripheral nerves of upper extremities. Rarely, they can arise from the retroperitoneum. Usually, in the retroperitoneum these tumors are near fat tissue, psoas muscle, pancreas, or adrenal glands, but it is uncommon for these tumors to involve the urogenital system.<sup>3</sup>

Schwannomas constitute approximately 1% to 5% of all retroperitoneal tumors. Malignant degeneration of a schwannoma is infrequent; however, when it occurs, the schwannoma acts as a high-grade sarcoma with a high probability of causing local dissemination and distant metastasis. Generally, malignant forms are suggested histologically by increased mitosis, pleomorphism, and vessel infiltration. Malignant schwannomas are typically found in the extremities, and often they occur in association with Von Recklinghausen's disease.<sup>1,3</sup> Although schwannomas can occur at any age, they predominantly occur in females between the second and fifth decade of life. In the retroperitoneum, these tumors are most commonly found in individuals between 40 and 60 y of age, with a slight female predominance (male/female ratio 2:3).<sup>1,12,24</sup>

Preoperative diagnosis of schwannoma of the adrenal gland is often incidental, because large, deeply situated tumors are usually present for long periods of time before patients complain of symptoms. The size of lesions at the time of diagnosis is frequently  $>4$  cm in diameter. However, the size of the lesion and the depth of invasion are not associated with the possibility of malignancy.<sup>15</sup> Patients commonly present with vague, nonspecific, and often misleading symptoms, such as mild abdominal pain or simply abdominal distension, depending on the size and location of the lesion. Reports have been published of a few patients with digestive



problems or lower back pain. Atypical presentations are rare and include dysesthesia, deterioration of gait, headache, secondary hypertension, flank pain, hematuria, or recurrent renal colic pain.<sup>11–13,24</sup>

In cases of retroperitoneal schwannomas that appear to localize in the adrenal glands, the differential diagnosis, which may be made by magnetic resonance imaging (MRI), ultrasonography, and CT, includes tumors of the area, such as adenoma of the adrenal gland, pheochromocytoma, myelolipoma, metastatic lesion, neurofibroma, paraganglioma, lipoma, and malignant fibrous histiocytoma.<sup>1,7</sup> Preoperative diagnosis is difficult, however, because these imaging techniques are nonspecific for demonstration of pathognomonic features unique to this lesion. It is imperative in circumstances with adrenal lesions that the clinician excludes the presence of a hormone-releasing tumor, especially pheochromocytoma.<sup>15</sup>

In cases of retroperitoneal lesions, MRI is the imaging modality of choice, because it allows better demonstration of their origin, vascular architecture, and relation to surrounding structures. MRI typically demonstrates benign schwannomas as well-circumscribed homogeneous masses that enhance slightly after intravenous administration of contrast material. Moreover, MRI shows low signal intensity on T1-weighted images and high signal intensity on T2-weighted images. These findings, although nonspecific, are commonly exhibited by schwannomas and have been reported to be present in 57% of cases.<sup>2</sup>

However, imaging modalities cannot provide a definitive diagnosis. Surgical resection of the lesion is necessary to make the diagnosis, differentiate it from other soft tissue neoplasms, palliate symptoms, and eliminate the possibility of malignancy. Biopsy is not recommended as a diagnostic tool, because hemorrhage, infection, and seeding of tumor cells are known risks of this modality, as are the lethal consequences if a pheochromocytoma exists.<sup>1,19</sup>

Histologic examination including immunohistochemistry is the definitive method to confirm the diagnosis of a schwannoma in the adrenal glands. The histological characteristics of schwannoma are 2 distinct subtypes of areas. The first area is hyper-cellular where spindle cells are arranged in fascicles with little stromal matrix (Antoni type A areas). The second type is thought to be a degenerated form of the former type, and loose hypocellular myxoid lesions with microcystic spaces intermixed with the tumor cells are found (Antoni type B areas). Nuclear free zones called “Verocay bodies” can also be found. In the vast majority of adrenal schwannomas, both areas are apparent.<sup>9,14,19,20</sup>

A strong positive staining for S-100 protein in the cytoplasm of the tumor cells and collagen IV in immunohistochemical analysis and absence for reactivity for keratin, muscle-related antigens (actin), and CD34 strongly supports the diagnosis of schwannoma.<sup>19–22</sup> Older lesions, which also are characterized as ‘ancient’ types, may also express degenerative changes like hemorrhage, hemosiderin deposition, calcification, inflammatory cell infiltration by siderophages and histiocytes, dense fibrosis and hyalinization, and nuclear pleomorphism or cystic formation.<sup>2,19</sup> In a review of 133 cases of retroperitoneal schwannomas, Takatera et al.<sup>17</sup> found that 66% had cystic components.

Recent studies demonstrate laparoscopy as an excellent approach for surgical excision of adrenal lesions, and it is the modality of choice in many circumstances. Thus, at present, minimally invasive surgical approaches are being applied with increasing frequency. With the exception of cases where a high index of suspicion for malignancy exists, tumor size and previous operations are not considered an absolute contraindication. Therefore, the laparoscopic approach is currently the first option for an experienced surgical team. Laparoscopy allows the surgeon to investigate the entire abdomen, search for metastatic peritoneal lesions, take biopsies if needed, and take a closer look at the tumor, assessing the prospects of completing the operation laparoscopically. Moreover, the advantages of laparoscopic adrenalectomy are well documented.<sup>23,24</sup> In the case we describe, imaging studies demonstrated a presumably benign lesion of approximately 6 cm. Laparoscopy was the ideal approach, and the patient was discharged quickly and with minimal postoperative pain and quick return to her usual activities and normal life.

As evident from the medical literature, schwannomas that arise from the adrenal medulla are very rare entities. Often, schwannomas from the retroperitoneum, especially in the juxta-adrenal space, can be misdiagnosed when they mimic adrenal lesions.<sup>2</sup> In Poland among 1111 adrenal incidentalomas, only 2 (0.18%) patients appeared to have schwannomas.<sup>10</sup> Fewer than 20 adrenal schwannomas are reported in the literature, and 2 cases were discovered during autopsy.<sup>13</sup> The ages of the patients ranged from 11 to 89 y old, and no sex predilection was observed. The size of the lesions that are reported varies between 0.6 cm and 14 cm. All of the lesions are characterized by benign features.<sup>9–11,14,15,19,20,25–27</sup> The common surgical approach that was followed was laparotomy and complete excision of the mass and the adrenal gland, with controversy existing over the necessity of negative margins, especially when adjacent tissues were in close proximity. In one case, partial adrenalectomy took place. In less than half of the cases, the patients underwent laparoscopic excision.<sup>10,11,14,15</sup>

## CONCLUSION

Schwannoma of the adrenal glands is a very rare entity, which in the vast majority of cases possesses benign behavior. This lesion is found predominately incidentally, and the clinician must have a high index of suspicion to recognize it when special features are demonstrated in imaging modalities, especially MRI. Histological and immunohistochemistry analyses provide the definitive diagnosis. Laparoscopic excision is the treatment of choice when relevant experience in the surgical team exists.

## References:

- Brian G, Yu-Meng T, Yaw-Fui A, Pierce C, London O, Wai-Keong W. Retroperitoneal schwannoma. *Am J Surg*. 2006;192(1):14–18.
- Inokuchi T, Takiuchi H, Moriwaki Y, et al. Retroperitoneal ancient schwannoma presenting as an adrenal incidentaloma: CT and MR findings. *Magn Reson Imaging*. 2006;24(10):1389–1393.
- Li Q, Gao C, Juzi JT, Hao X. Analysis of 82 cases of retroperitoneal schwannoma. *Aust N Z J Surg*. 2007;77:237–240.
- Ohta I, Lin PH, Rau CL, Wang KC. Evaluation of perinephric, retroperitoneal schwannomas: Case report and review of the literature. *South Med J*. 2007;100(1):80–82.
- Gubbay AD, Moschilla G, Gray BN, Thompson I. Retroperitoneal schwannoma: a case series and review. *Aust N Z J Surg*. 1995;65(3):197–200.
- Regan J, Juler G, Schmutzer K. Retroperitoneal neurilemmoma. *Am J Surg*. 1977;134:140–145.
- Felix EL, Wood D, Das Gupta TK. Tumors of the retroperitoneum. *Curr Probl Cancer*. 1981;6(1):1–47.
- Vaughan ED Jr., Javidian P. Benign schwannoma of the retroperitoneal space: case report. *J Urol*. 1993;150:179–181.
- Lau SK, Spagnolo DA, Weiss LM. Schwannoma of the adrenal gland: report of two cases. *Am J Surg Pathol*. 2006;30:630–634.
- Kasperlik-Zaluska AA, Roslonowska E, Slowinska-Szednicka J, et al. 1,111 patients with adrenal incidentalomas observed at a single endocrinological center: incidence of chromaffin tumors. *Ann N Y Acad Sci*. 2006;1073:38–46.
- Yang CY, Chou CW, Lin MB, Li CF. Schwannomas of the left adrenal gland and posterior mediastinum. *J Chin Med Assoc*. 2009;72(2):83–87.
- Cury J, Coelho RF, Srougi M. Retroperitoneal schwannoma: case series and literature review. *Clinics*. 2007;62(3):359–362.
- Arena V, De Giorgio F, Drapeau CM, Monego G, De Mercurio D, Capelli A. Adrenal schwannoma. Report of two cases. *Folia Neuropathol*. 2004;42(3):177–179.
- Onoda N, Ishikawa T, Tokugawa T, Takashima T, Wakasa K, Hirakawa K. Adrenal schwannoma treated with laparoscopic surgery. *JLSLS*. 2008;12(4):420–425.
- Tarcoveanu E, Dimofte G, Bradea C, et al. Adrenal schwannoma. *JLSLS*. 2009;13(1):116–119.
- Schindler OS, Dixon JH, Case P. Retroperitoneal giant schwannomas: report on two cases and review of the literature. *J Orthop Surg*. 2002;10:77–84.
- Takatera H, Takiuchi H, Namiki M, Ohnishi S, Sonoda T. Retroperitoneal schwannoma. *Urology*. 1986;28:529–531.
- Daneshmand S, Youssefzadeh D, Chamie K, et al. Benign retroperitoneal schwannoma: A case series and review of literature. *Urology*. 2003;62(6):993–997.
- Jakowski JD, Wakely PE Jr., Jimenez RE. An uncommon type of adrenal incidentaloma: a case report of a schwannoma of the adrenal medulla with cytological, histological and ultrastructural correlation. *Ann Diagn Pathol*. 2008;12(5):356–361.
- Liegl B, Bennett MW, Fletcher CD. Microcystic/reticular schwannoma: a distinct variant with predilection for visceral locations. *Am J Surg Pathol*. 2008;32(7):1080–1087.
- Fanburg-Smith JC, Majidi M, Miettinen M. Keratin expression in schwannoma; a study of 115 retroperitoneal and 22 peripheral schwannomas. *Mod Pathol*. 2006;19:115–121.
- Yamamoto K, Miyagawa S, Katsura H. Retroperitoneal cellular schwannoma: Report of a case diagnosed by the presence of S-100 protein. *Jpn J Med*. 1991;30:487–490.
- Descazeaud A, Coggia M, Bourriez A, Goeau-Brissonniere O. Laparoscopic resection of a retroperitoneal schwannoma. *Surg Endosc*. 2002;17(3):520–522.
- Pinto D, Kaidar-Person O, Cho M, Zundel N, Szomstein S, Rosenthal RJ. Laparoscopic resection of a retroperitoneal degenerative schwannoma: A case report and review of the literature. *Surg Laparosc Endosc Percutan Tech*. 2008;18:121–123.
- Gazula S, Mammen KJ. Schwannoma with concomitant tuberculosis in the adrenal gland. *Indian J Urol*. 2007;23(4):469–470.
- Korets R, Berkenblit R, Ghavamian R. Incidentally discovered adrenal schwannoma. *JLSLS*. 2007;11(1):113–115.
- Garg S, Mathew M, Goel T. Adrenal schwannoma: a case report and review of literature. *Indian J Pathol Microbiol*. 2007;50(3):587–588.
- Verocay J. Geschwulste als systemerkrankung am nervosen apparate, festschrift fur chiari. *Wien Leipzig*. 1907;378–384.
- Masson P. Experimental and spontaneous schwannomas (peripheral gliomas): part I. *Am J Pathol*. 1932;8:367–370.