

Retinopathy of prematurity screening and retinal hemorrhages – Our experience among Indian babies

Hemalatha B C, Kalpana B N, Shilpa Y D, Ravi B, Bhavana G, Meghana S, Jessica Basumatary

Purpose: To evaluate the clinical characteristics of intraocular hemorrhages among babies screened for retinopathy of prematurity (ROP) and thereby their additional risk to the progression of ROP. **Methods:** A descriptive study was conducted at a tertiary referral hospital, which included 108 eyes of 60 neonates who were discovered to have retinal hemorrhages on retinal screening of 540 babies at risk for ROP. Maternal, obstetric, and neonatal risk factors were assessed in neonates with retinal hemorrhages. Retinal hemorrhages were assessed in terms of type, area, and relation to different retinal zones. **Results:** Among 540 neonates who were screened, retinal hemorrhages were found in 11.2% ($n = 60$ babies). Elderly primigravida mothers and spontaneous vaginal deliveries with prolonged second stage of labor were a common maternal risk factors for retinal hemorrhages. Low birth weight and preterm were fetal risk factors with neonatal retinal hemorrhages. These hemorrhages were more often bilateral (no. of babies = 48, 80%). Flame-shaped hemorrhages were more common than dot and blot ones. The majority of cases (no. of eyes = 74, 65%) resolved within 4 weeks, whereas four babies (8 eyes, 7.4%) progressed to ROP were treated with laser. **Conclusion:** Retinal hemorrhages in neonates are commonly associated with prolonged duration of second stage of labor, advanced maternal age, and anemia. Although not all progress to ROP, recognizing preterm and low birth weight babies with junctional hemorrhages is crucial not to delay the treatment. Regular follow-up until the clearance of hemorrhages and monitoring systemic conditions in these babies of amblyogenic age-group are required.

Key words: Preterm babies, retinal hemorrhages, retinopathy of prematurity

Retinal hemorrhages in neonates can be of varied etiology. Neonatal retinal hemorrhage may occur independently in retinopathy of prematurity (ROP) associated with neovascularization. It may be associated with birth trauma, sepsis, shaken baby syndrome, or intracranial hemorrhage. Retinal hemorrhages due to ROP tend to occur on the surface of the neovascularization towards the periphery, whereas in other conditions, it tends to be more toward the posterior pole. The reported incidence of neonatal retinal hemorrhages varies widely from 2.6% to 50%.^[1] The proposed hypothesis is that an acute rise in intracranial pressure is associated with central retinal artery pressure change along with venous stasis in the central retinal vein.^[2,3] Foveal hemorrhage is known to occur due to maternal risk factors such as prolonged vaginal delivery or neonatal factors at birth. Macular hemorrhage can lead to amblyopia due to the delayed absorption of blood.^[4]

Jensen *et al.*'s^[5] case report shows widespread retinal hemorrhages following examination of babies with scleral depression while screening for ROP. The mechanism was related to fragile immature retinal vasculature with poor autoregulation. This alerts us to handle babies with care while screening. Neonatal retinal hemorrhage can be of

protean manifestation. There are very few studies related to retinal hemorrhages among Indian neonatal babies. Thus, we planned this study to evaluate the varied causes and clinical characteristics of retinal hemorrhages, and their predictability of ROP in neonates.

Methods

A descriptive study was conducted in our tertiary eye care center from March 2019 to November 2020, the duration being 20 months. A total of 540 newborns visiting for ROP screening, including hospitalized babies at the neonatal intensive care unit, were included in our study. All babies underwent screening as per the Indian guidelines: babies with gestational age ≤ 34 weeks or birth weight $\leq 2,000$ g, for ROP (2–3 weeks after birth). As, the Indian guidelines recommend broad eligibility criteria for screening, babies up to 43 weeks of gestation were also screened in our study when associated with risk factors. Babies were screened using an indirect ophthalmoscope and scleral depression with proparacaine 0.5% topical anesthetic. After an ethics committee approval on 14-

Access this article online

Website:

www.ijo.in

DOI:

10.4103/ijo.IJO_3616_20

Quick Response Code:



Minto Regional Institute of Ophthalmology, Bangalore Medical College and Research Institute, Bangalore, Karnataka, India

Correspondence to: Dr. Hemalatha B C, House No 156, Kantha Nivas, 3rd Phase, 1st Block, Banashankari 3rd Stage, Bangalore 560 085, Karnataka, India. E mail: subhema@gmail.com

Received: 06-Dec-2020

Revision: 27-Feb-2021

Accepted: 19-Apr-2021

Published: 26-Jul-2021

This is an open access journal, and articles are distributed under the terms of the Creative Commons Attribution-NonCommercial-ShareAlike 4.0 License, which allows others to remix, tweak, and build upon the work non-commercially, as long as appropriate credit is given and the new creations are licensed under the identical terms.

For reprints contact: WKHLRPMedknow_reprints@wolterskluwer.com

Cite this article as: Hemalatha BC, Kalpana BN, Shilpa YD, Ravi B, Bhavana G, Meghana S, *et al.* Retinopathy of prematurity screening and retinal hemorrhages – Our experience among Indian babies. Indian J Ophthalmol 2021;69:2147-50.

11-2018, 108 eyes of 60 babies which were found to have retinal hemorrhages on ROP screening were included in this study.

The date of each examination, the stage and zone of disease for each eye were recorded. Documentation using Clarity RetCam Shuttle was done as and when required. Data regarding maternal, obstetric, and neonatal risk factors were assessed in neonates with retinal hemorrhages. Retinal hemorrhages were classified according to their location in three retinal zones. Retinal hemorrhages were further assessed in terms of type, area, and location concerning the zones. The various types of hemorrhages such as vitreous hemorrhage, preretinal hemorrhage, flame-shaped hemorrhage, dot and blot hemorrhage, and blotchy hemorrhage were analyzed. Although both blot and blotchy hemorrhages are hemorrhages in the deep retinal layers, blotchy hemorrhages are larger in size due to capillary rupture in comparison with blot hemorrhage.^[6] The affected babies were followed up for 8 to 12 weeks, at weekly intervals.

Results

Among the 540 babies we screened, 60 (11.2%) babies had retinal hemorrhages. These hemorrhages were more often bilateral ($n = 48$, 80%). Unilateral hemorrhages ($n = 12$, 20%) were most commonly seen in forceps delivery babies ($n = 5$, 8.4%) followed by sepsis ($n = 2$, 3.3%), hypoxia due to respiratory distress syndrome ($n = 3$, 5%), and with precipitate labor ($n = 2$, 3.3%).

Type of retinal hemorrhages were predominantly flame-shaped hemorrhages in 12 (20%) babies; dot and blot hemorrhages in 10 babies (16.6%); preretinal hemorrhages in four babies (6.7%), among them two eyes had a foveal hemorrhage; blotchy hemorrhages in six babies (10%); and two babies (3.3%) had unilateral vitreous hemorrhage [Fig. 1]. Combined type of hemorrhages was found among 26 babies (43%). The distribution of retinal hemorrhages was 56 eyes (52%) with hemorrhages at Zone 2, including the junction between Zones 1 and 2; 28 eyes (26%) at Zone 3, including junctional hemorrhages between Zones 2 and 3; and 22 eyes (20%) at Zones 1 and 2 [Table 1].

Among the maternal risk factor for retinal hemorrhages, there were elderly primigravida mothers ($n = 12$, 27%), spontaneous vaginal deliveries with prolonged second stage of labor ($n = 10$, 23%), vacuum-assisted vaginal deliveries ($n = 8$, 18%), and forceps-assisted delivery ($n = 6$, 14%), babies with twin gestation ($n = 4$, 9%), precipitate labor with accidental head injury ($n = 2$, 4.5%), and with cesarean deliveries ($n = 2$, 4.5%). Thus, the major maternal risk factors for retinal hemorrhages were elderly primigravida, prolonged labor, and assisted delivery. Cesarean deliveries were the least

associated with retinal hemorrhages, suggesting its protective role ($n = 2$, 4.5%).

On analysis, the fetal risk factors were low birth weight ($<2,000$ g, $n = 24$, 38%), preterm (<34 weeks, $n = 20$, 31%), fetal anemia ($n = 8$, 12.5%), respiratory distress syndrome ($n = 8$, 12.5%), and sepsis ($n = 4$, 8%). Among the babies diagnosed with sepsis, two were proven by blood culture. One had Klebsiella and the other Streptococci. One baby was diagnosed with meningitis due to sepsis shock. Neonatal intracranial hemorrhage ($n = 2$, 3.3%) was associated with neonatal retinal hemorrhages.

On correlating gestational age at birth with birth weight, there were retinal hemorrhages in 18 babies born at 32 to 35 weeks with the average weight being 1.8 kg, 14 babies were between 28 and 31 weeks with an average birth weight of 1.2 kg, six babies were born 36 to 39 weeks with average birth weight 2.8 kg, and 10 babies with average weight 3.4 kg were born between 40 and 43 weeks [Graph 1]. All the babies had hemorrhages cleared on follow-up at 8 to 12 weeks, by 4 weeks in 74 eyes (68.5%), and by 6 weeks in 34 eyes (31%) and showed spontaneous clearance of retinal hemorrhages [Graph 2]. Among 18 babies between 32 and 35 weeks with birth weight less than 1.9 kg, four babies (eight eyes) with superficial hemorrhages at the junction of vascular and avascular zone progressed to ROP Stage 3 with plus disease. Among them, one baby had features of acute progressive ROP features. All these babies underwent red diode laser treatment at neonatal intensive care unit under monitoring by indirect laser ophthalmoscopy.

Discussion

The various causes for hemorrhages at birth reported are hypoxemia, hypercapnia, metabolic acidosis, and neonatal coagulopathies.^[3,4] Retinal hemorrhage occurring in healthy newborn infants during delivery was related to the birth process.^[2] In our study retinal hemorrhages were seen in 11.2% of the neonates screened for ROP. Most often they were bilateral ($n=48$, 80%) similar to the study by Levin *et al.*^[7] In our study, retinal hemorrhages seen between 34 and 36 weeks of birth were more confined to the posterior pole, as reported by Kedar and Abha^[8] Also, in our study, hemorrhages were associated with fetal risk factors such as prematurity, low birth weight, anemia, and metabolic acidosis,^[1] and maternal risk factors such as prolonged second stage of labor,^[9] vacuum-assisted delivery,^[10] and elderly primigravida mothers.^[11] Cesarean deliveries had a lesser incidence of hemorrhages.

Although 18 (30%) preterm babies with birth weight 1.8 kg, between 32 and 35 weeks had retinal hemorrhages, we found 16 (26%) full-term babies were associated with retinal

Table 1: Distribution of retinal hemorrhages in various zones

Gestational age (weeks)	Average birth weight (kg)	No. of eyes with hemorrhage	Distribution of hemorrhages		
			Zone 1 (%)	Zone 2 (%)	Zone 3 (%)
28-31	1.2	22	10	8	Nil
32-35	1.9	34	4	24	2
36-39	2.8	22	4	10	8
40-43	3.4	26	2	8	14

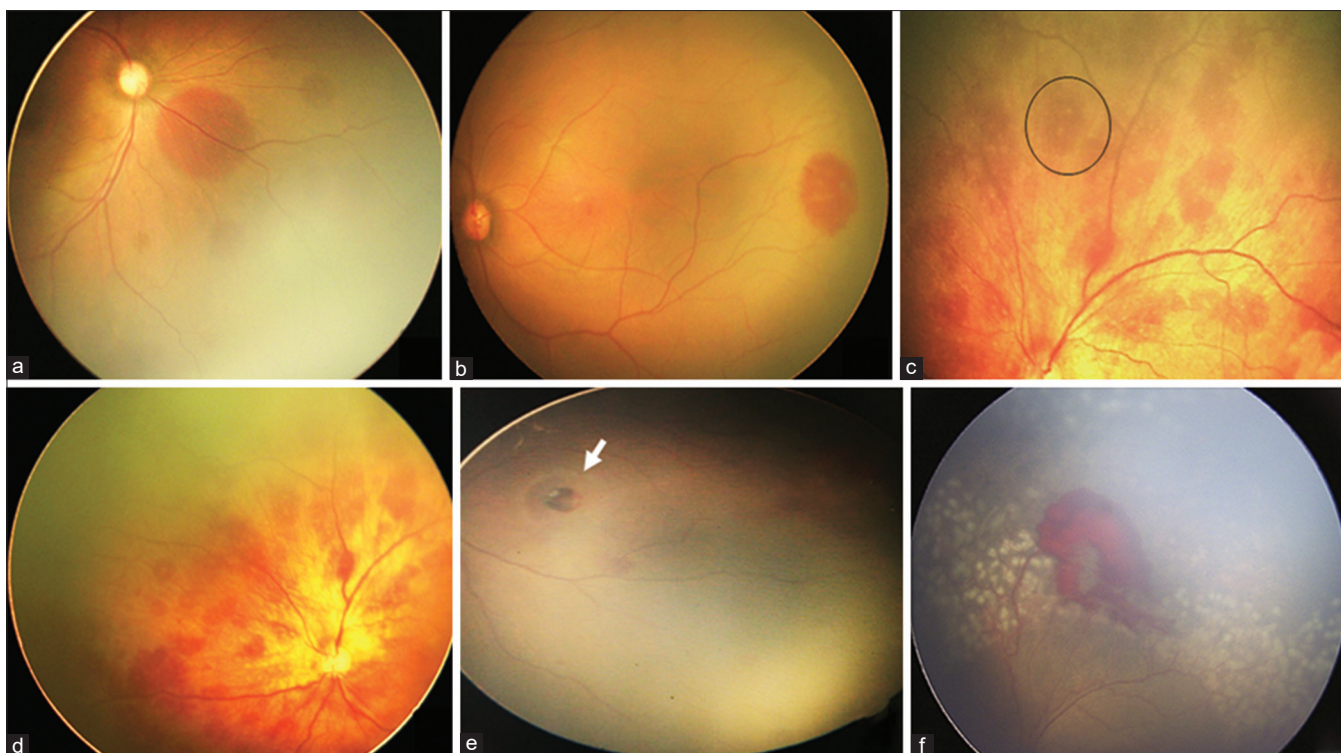
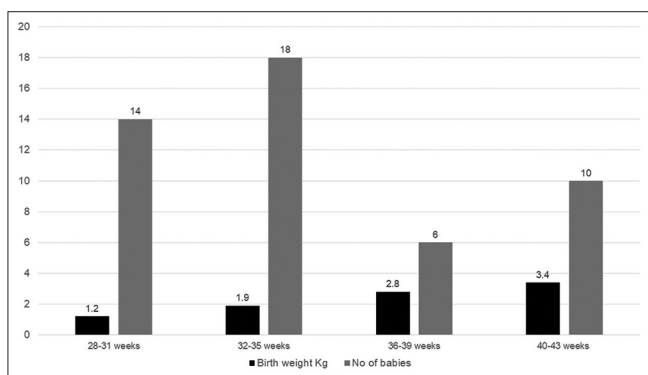


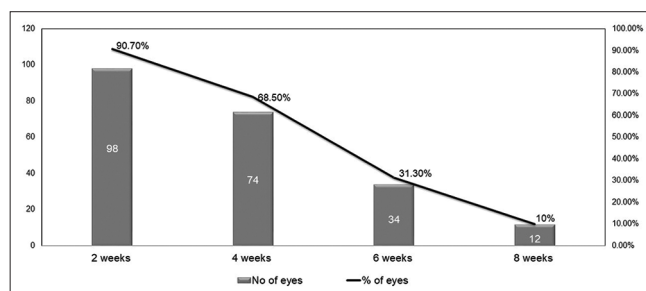
Figure 1: Fundus photographs showing various types of hemorrhages. (a) Subretinal hemorrhages in Zones 1 and 2. (b) Retinal hemorrhages at the junction between vascular and avascular retina. (c and d) Superficial retinal hemorrhages in the posterior pole, area encircled depicts Roth's spot in c. (e) Presence of hemorrhage at the fovea. (f) Preretinal between Zones 1 and 2 in the case of aggressive posterior ROP



Graph 1: The correlation between gestational age, birth weight, and the number of babies with retinal hemorrhages

hemorrhages similar to a study by Wang *et al.*^[12] Also, Emerson *et al.*^[13] and Hughes *et al.*^[1] reported that approximately 90% of retinal hemorrhages detected at birth resolved within 2 weeks, in comparison with 2 to 4 weeks in our study. But long-standing, dense hemorrhages obscuring the macula and vitreous hemorrhage may lead to severe vision deprivation amblyopia, hence should be monitored strictly, especially with a unilateral presentation.

Regarding the type of retinal hemorrhages and their correlation with varied etiology, flame-shaped hemorrhages with Roth's spots were more associated with anemia and low birth weight babies, Dot and blot hemorrhages were predominantly associated with preterm babies with prolonged second stage of labor, and blotchy type of hemorrhages



Graph 2: Number of eyes showing clearance of hemorrhage at 2 weekly follow-ups

were associated with metabolic acidosis due to respiratory distress syndrome and sepsis. Foveal hemorrhage noted in two (2.16%) eyes were associated with prolonged labor vaginal delivery, and the results were comparable with Callaway *et al.*'s study with the incidence being 3%.^[14] It is important to analyze the type of hemorrhage. As mentioned by Naderian *et al.*,^[15] superficial retinal hemorrhages resolve by 1 week, whereas dot and blot retinal hemorrhages take a longer duration (2–4 weeks) postpartum to resolve. Foveal, preretinal, and vitreous hemorrhage may persist longer. Thus, these hemorrhages require close monitoring among the amblyogenic age-group.^[2]

Watts *et al.*^[4] reported that birth-related retinal hemorrhages resolve quickly within 6 to 8 weeks and with nil subsequent visual or neurological sequelae, similar to what we observed in our study. Shaikh *et al.*^[16] reported an association of retinal hemorrhages with intracranial bleed due to nuchal cord

strangulation associated with subconjunctival hemorrhage. In our study, eight babies (18%) had intracranial bleed due to vacuum-assisted vaginal delivery. Thus, it is important to look for other systemic associations. In our study, two babies had a vitreous hemorrhage, one with forceps delivery and the other with sepsis. The baby with sepsis also had intracranial hemorrhage, similar to Milligan's^[17] study. According to the author, fragile arterioles can bleed due to poor vascular autoregulation in sick preterm infants.

In the e-ROP study by Daniel *et al.* using telemedicine approach reported that one in five preterm infants with intraocular hemorrhages are at higher risk for both presence and severity of ROP.^[18] Hemorrhages at the junction of vascular and avascular zones can be due to rupture of fragile shunt vessels or due to neovascularization. In our study, three babies with junctional retinal hemorrhages progressed to Stage 3 ROP with plus disease and one baby had features of aggressive posterior ROP.

Limitations of our study are small sample size and that only 6.6% of the babies had ROP. We need to do larger number of prospective studies exclusively on ROP eyes with hemorrhages to correlate the characteristics of retinal hemorrhage with the risk of ROP progression.

Conclusion

Retinal hemorrhages in neonates are commonly associated with prolonged duration of second stage of labor, advanced maternal age, and anemia, and can be rarely associated with a grave condition such as neonatal intracranial hemorrhage. Retinal hemorrhage is an incidental finding in our study while screening for ROP babies. Although not all progress to ROP, recognizing preterm and low birth weight babies with junctional hemorrhages is crucial not to delay the treatment. Regular follow-up until the complete clearance of hemorrhages and monitoring the systemic conditions in these babies of amblyogenic age-group are required.

Financial support and sponsorship

Nil.

Conflicts of interest

There are no conflicts of interest.

References

- Hughes LA, May K, Talbot JF, Parsons MA. Incidence, distribution, and duration of birth-related retinal hemorrhages: A prospective study. *J AAPOS* 2006;10:102-6.
- Choi YJ, Jung MS, Kim SY. Retinal hemorrhage associated with perinatal distress in newborns. *Korean J Ophthalmol* 2011;25:311-6.
- Lashutka MK, Chandra A, Murray HN, Phillips GS, Hiestand BC. The relationship of intraocular pressure to intracranial pressure. *Ann Emerg Med* 2004;43:585-91.
- Watts P, Maguire S, Kwok T, Talabani B, Mann M, Wiener J, *et al.* Newborn retinal hemorrhages: A systematic review. *J AAPOS* 2013;17:70-8.
- Jensen AK, Forbes BJ, Wilson LB, Prieto D, Binenbaum G. Widespread retinal hemorrhages following retinopathy of prematurity screening with scleral depression. *J AAPOS* 2011;15:609-11.
- Bhende MP, Karpe AP, Pal BP. High altitude retinopathy. *Indian J Ophthalmol* 2013;61:176-7.
- Levin S, Janive J, Mintz M, Kreisler C, Romem M, Klutznik A, *et al.* Diagnostic and prognostic value of retinal hemorrhages in the neonate. *Obstet Gynecol* 1980;55:309-14.
- Kedar N, Abha B. Retinal haemorrhages in the newborn. *Acta Ophthalmol (Copenh)* 1980;58:231-6.
- Zhao Q, Zhang Y, Yang Y, Li Z, Lin Y, Liu R, *et al.* Birth-related retinal hemorrhages in healthy full-term newborns and their relationship to maternal, obstetric, and neonatal risk factors. *Graefes Arch Clin Exp Ophthalmol* 2015;253:1021-5.
- Laghmari M, Skiker H, Handor H, Mansouri B, Ouazzani Chahdi K, Lachkar R, *et al.* Birth-related retinal hemorrhages in the newborn: Incidence and relationship with maternal, obstetric and neonatal factors. A prospective study of 2,031 cases. *J Fr Ophthalmol* 2014;37:313-9.
- Shimin Y. An analysis of the effect of psychological nursing intervention for 43 high-risk pregnant women. *Jilin Med J* 2010;31:3912.
- Wang Y, Geng S, Li Y, Wang Y, Zhang H, Zhang T, Zhang J, Zhang W. An investigation of the standard of classification of retinal hemorrhage in full-term normal delivery newborns according to digital wide-angle retinal imaging device RetCam-3. *J Otolaryngol Ophthalmol Shandong Univ* 2015;29:78-81.
- Emerson MV, Pieramici DJ, Stoessel KM, Berreen JP, Gariano RF. Incidence and rate of disappearance of retinal haemorrhage in newborns. *Ophthalmology* 2001;108:36-9.
- Callaway NF, Ludwig CA, Blumenkranz MS, Jones JM, Fredrick DR, Moshfeghi DM. Retinal and optic nerve hemorrhages in the newborn infant: One-year results of the newborn eye screen test study. *Ophthalmology* 2016;123:1043-52.
- Naderian G, Fesharaki H, Sajjadi V, Naderian M-A. Retinal hemorrhages in a neonate following vacuum extraction. *J Ophthalmic Vis Res* 2013;8:179-81.
- Shaikh S, Fishman ML, Gaynon M, Alcorn D. Diffuse unilateral hemorrhagic retinopathy associated with accidental perinatal strangulation. A clinicopathologic report. *Retina* 2001;21:252-5.
- Milligan DW. Failure of autoregulation and intraventricular hemorrhage in preterm infants. *Lancet* 1980;1:896-8.
- Daniel E, Ying G-S, Michael Siatkowski R, Pan W, Smith E, Quinn GE, e-ROP Cooperative Group. Intraocular hemorrhages and ROP in the telemedicine approaches to evaluating acute-phase Retinopathy of prematurity (e-ROP) study. *Ophthalmology* 2017;124:374-81.