

Case Report

Transient ventriculoperitoneal shunt malfunction in a pediatric patient: An illustrative case

Michel Gustavo Mondragon-Soto¹, Lior Elkaim², Alexander G. Weil³

¹Department of Neurosurgery, Instituto Nacional de Neurologia y Neurocirugia, Mexico City, Mexico, ²Department of Neurology and Neurosurgery, McGill University, ³Division of Neurosurgery, Centre Hospitalier Saint-Justine, Montreal, Quebec, Canada.

E-mail: *Michel Gustavo Gustavo Mondragon-Soto - mmondragon@innn.edu.mx; Lior Elkaim - Lior.Elkaim@mail.mcgill.ca; Alexander G. Weil - alexandergweil@gmail.com



*Corresponding author:

Michel G. Mondragon-Soto,
Department of Neurosurgery,
Instituto Nacional de
Neurologia y Neurocirugia,
Mexico City, Mexico.

mmondragon@innn.edu.mx

Received : 25 June 2021

Accepted : 20 September 2021

Published : 05 January 2022

DOI:

10.25259/SNI_636_2021

Quick Response Code:



ABSTRACT

Background: Ventriculoperitoneal shunt (VPS), the mainstay of the treatment for hydrocephalus, is associated with relatively high revision rates. Transient hydrocephalus due to intermittent VPS obstruction should be recognized as a cause of VPS malfunction. While transient VPS dysfunction is well-recognized complication, there is a relative paucity of well-documented cases in the literature.

Case Description: We present the case of a 4-year-old boy with a history of vascular malformation and hydrocephalus secondary to intraventricular hemorrhage. The patient presented with transient, self-resolving hydrocephalus (without intervention), as documented by clinical and radiological findings.

Conclusion: Transient hydrocephalus due to intermittent VPS dysfunction in children is a rare entity, but it should be suspected in certain patients with VPS presenting with transient or self-improving symptoms.

Keywords: Choroid plexus, Hydrocephalus, Pediatric, Shunt malfunction

BACKGROUND

Hydrocephalus affects both pediatric and adult populations, with an estimated prevalence in the general populations of between 1.0% and 1.5%.^[16] While hydrocephalus is a relatively common and life-threatening condition, transient hydrocephalus is rare, and only a few case reports are available in the current literature.

There are, to the best of our knowledge, 15 available case reports describing transient hydrocephalus in pediatric patients. Of these, only four represent patients with ventriculoperitoneal shunt (VPS) dysfunctions; other suspected etiologies include subarachnoid hemorrhage and intraventricular clots,^[7,13] carbon monoxide poisoning,^[17] head trauma,^[18] lead poisoning,^[19] suspension of adrenocorticotrophic hormone (ACTH) therapy,^[9] central nervous system infections, meningitis, on/off dysfunction of the VPS, and one of unknown etiology.^[4,19,23] While transient VPS dysfunction is a relatively well-recognized cause of transient symptoms in patients harboring VPS, there is a relative paucity of well-documented cases in the literature.

This is an open-access article distributed under the terms of the Creative Commons Attribution-Non Commercial-Share Alike 4.0 License, which allows others to remix, transform, and build upon the work non-commercially, as long as the author is credited and the new creations are licensed under the identical terms.

©2022 Published by Scientific Scholar on behalf of Surgical Neurology International

In this report, we provide radiographic evidence on computed tomography (CT) and magnetic resonance imaging (MRI) of spontaneously resolving hydrocephalus secondary to suspected VPS dysfunction in a 4-year-old boy.

CASE DESCRIPTION

A 4-year-old boy presented to the Emergency room with recurrent episodes of vomiting. He had a prior history of embolized Vein of Galen malformation (treated at the age of 3 months) complicated by intraventricular hemorrhage and hydrocephalus which was treated with a VPS (age of 3 months). Over a 6-month period, he was hospitalized on four separate occasions for transient episodes of intractable vomiting, lasting on average <1 day. On his third hospitalization, a brain MRI [Figure 1a] and CT head showed ventriculomegaly (compared to baseline), and a decision was made to proceed with a surgical shunt revision [Figure 1b]. A brain MRI was planned for the morning of the surgery to assess the feasibility of endoscopic third ventriculostomy (ETV) for the treatment of hydrocephalus. On the morning of the scheduled surgery, he had symptomatically improved; his surgery was cancelled after MRI demonstrated spontaneous reduction of ventricle size [Figure 1c]. He was followed clinically and discharged after a few days of observation. He had one more transient episode of vomiting before being hospitalized 2 weeks later where imaging demonstrated ventriculomegaly [Figure 1d], and he was treated surgically through ETV. During ETV, it was noted that there was partial obstruction of the VPS catheter by the choroid plexus. On his past follow-up 24 months later, he was clinically well with no recurrence.

DISCUSSION

Transient hydrocephalus has been described in pediatric patients with several proposed mechanisms, including intraventricular hemorrhage, suspension of ACTH therapy, carbon monoxide suspension, as well as other unknown etiologies.^[6,9,10] A summary of known case reports discussing transient hydrocephalus is shown in [Table 1].

This case report is unique in that the 4-year-old boy already had a VP shunt in place. The transient hydrocephalus was most likely due to transient shunt dysfunction. The on-off shunt failure, as mentioned by Cengiz *et al.*,^[3] can present as slit-ventricle syndrome, which includes the triad of intermittent headache, smaller than normal ventricles on imaging, and slow refilling of the shunt pumping device. The phenomenon is explained by the proximal catheter initially being in an adequate position, but potentially malfunctioning as the child grows. It is thought that the shunt proximal tip eventually migrates to the border of the ventricle; here, the fenestrated portion of the catheter can be

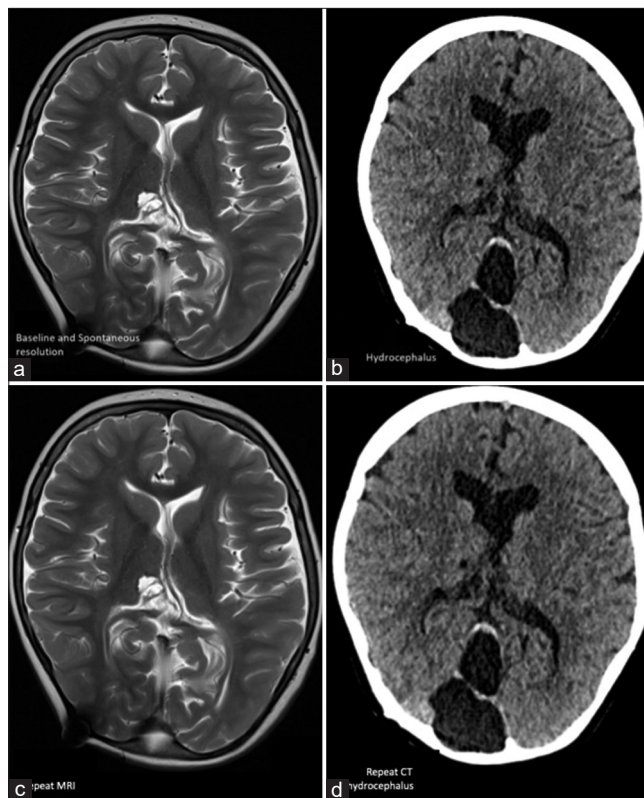


Figure 1: (a) Baseline noncontrast axial T2 magnetic resonance imaging (MRI) demonstrating baseline ventricle size. (b) Noncontrast axial computed tomography (CT) in a 4-year-old boy with known ventriculoperitoneal shunt demonstrating acute hydrocephalus and increased ventricle size when compared with his baseline. (c) Repeat MRI on the morning of the scheduled OR demonstrating spontaneous resolution of hydrocephalus coinciding with symptomatic improvement. (d) Noncontrast axial CT performed a few weeks later demonstrating acute hydrocephalus.

very easily obstructed by tissue, such as brain parenchyma and/or choroid plexus.^[5,11,20] As the ventricle's size increases because of CSF fluid accumulation, it may allow the end of the catheter to move back in the right place and drain cerebrospinal fluid (CSF) adequately, explaining the transient symptoms.

It is also possible that the catheter could transiently have been obstructed by blood cells or a heap of proteins in the CSF. One review analyzed patients after VP shunt insertion (15-year follow-up); here, 84% of patients required a revision, with catheter occlusion being the primary reason for VPS revision.^[21] Tissue debris could also obstruct the proximal catheter and cause shunt migration. These clots could be transiently dissolved, which may explain the transient symptoms. Mild viral or bacterial infections before the obstruction could also explain this phenomenon by affecting the efficiency of the drainage.^[8] There are case reports where abdominal issues, such as bladder infections, transiently cause

Table 1: Case reports of transient hydrocephalus in pediatric patients.

Author	Age	Etiology	Date	Treatment
Abubacker <i>et al.</i> ^[1]	4 months	Ventricular hemorrhage	2001	Conservative management
Braitman and Friedman ^[2]	3 months	Idiopathic	1982	Conservative
Cengiz <i>et al.</i> ^[3]	3 years	On-off malfunction	2009	Shunt revision
Mao <i>et al.</i> ^[11]	2 weeks	Choroid plexus obstruction	2017	Conservative
Inamura <i>et al.</i> ^[6]	7 years	AVM rupture and IVH	2001	Conservative
Laverda <i>et al.</i> ^[9]	4 months	Suspension of ACTH therapy leading to benign intracranial hypertension	1984	Conservative management
Martínez-Lage <i>et al.</i> ^[12]	16 months 55 days	VPS dysfunction due to chronic constipation	2008	Desimpaction VPS shunt pressure adjustment Shunt revision
Morais <i>et al.</i> ^[14]	6 years	VPS dysfunction due to chronic constipation	2018	Shunt revision
Muzumdar and Ventureyra ^[15]	16 years	VPS dysfunction due to chronic constipation	2006	Enemas
Powers <i>et al.</i> ^[16]	2 years	VPS dysfunction due to chronic constipation	2006	Enemas
Vakis <i>et al.</i> ^[23]	13 months	Idiopathic	2006	Conservative management
Sasaki <i>et al.</i> ^[18]	–	Traumatic	1981	Conservative management
Sharma <i>et al.</i> ^[19]	3 weeks 4 months	Cerebellar vermis enlargement due to lead poisoning	1990	Chelation therapy Mannitol
Ramos-Zuñiga and Jiménez-Guerra ^[13]	15 years	Hemorrhagic infarct of a cerebellar cavernoma		Suboccipital craniectomy/ cavernoma resection
Tubbs <i>et al.</i> ^[22]	16 years 9 years	Transient shunt dysfunction due to urinary bladder infection	2002-2004	Antibiotics
Present case	4 years	Choroid plexus obstruction	2021	Third ventriculostomy

VPS: Ventriculoperitoneal shunt

VPS dysfunction.^[22] Another possible etiology is chronic constipation, in which elevated intraperitoneal pressure causes VPS dysfunction due to the elimination of the pressure gradient through the shunt tubing,^[16] although it is difficult to determine whether the constipation was a consequence of or the trigger for hydrocephalus.^[14] The appropriate management of constipation, including disimpaction, may relieve distal shunt malfunction and help reestablish CSF circulation.^[12] In these situations, surgical exploration of the shunt can be avoided.^[15]

CONCLUSION

Although transient hydrocephalus due to VPS dysfunction in children is rare, it should be suspected in certain patients with a VPS shunt presenting with transient or improving symptoms.

Treatment may range from conservative medical management to surgical intervention and shunt revision. Thorough workup and careful monitoring of patient status are important to guide surgical decision-making in patients suffering from suspected transient VPS malfunction.

Declaration of patient consent

The authors certify that they have obtained all appropriate patient consent.

Financial support and sponsorship

Nil.

Conflicts of interest

There are no conflicts of interest.

REFERENCES

1. Abubacker M, Bosma JJ, Mallucci CL, May PL. Spontaneous resolution of acute obstructive hydrocephalus in the neonate. *Childs Nerv Syst* 2001;17:182-4.
2. Braitman RE, Friedman M. Spontaneous resolution of acute hydrocephalus. *Clin Pediatr (Phila)* 1982;21:757-8.
3. Cengiz C, Aydın K, Kocabağcı E. On-off malfunction in a pediatric shunt: A case report. *J Exp Clin Med* 2009;26:142-4.
4. Erol FS, Ozturk S, Akgun B, Kaplan M. Ventriculoperitoneal shunt malfunction caused by fractures and disconnections

- over 10 years of follow-up. *Childs Nerv Syst* 2017;33:475-81.
5. Goeser CD, McLeary MS, Young LW. Diagnostic imaging of ventriculoperitoneal shunt malfunctions and complications. *Radiographics* 1998;18:635-51.
 6. Inamura T, Kawamura T, Inoha S, Nakamizo A, Fukui M. Resolving obstructive hydrocephalus from AVM. *J Clin Neurosci* 2001;8:569-70.
 7. Jergović I, Budinčević H, Planjar-Prvan M, Bielen I. Transient obstructive hydrocephalus in patients with intracerebral hemorrhage: Report of two cases. *Acta Clin Croat* 2016;55:497-500.
 8. Klarica M, Oresković D, Božić B, Vukić M, Butković V, Bulat M. New experimental model of acute aqueductal blockage in cats: Effects on cerebrospinal fluid pressure and the size of brain ventricles. *Neuroscience* 2009;158:1397-405.
 9. Laverda AM, Casara G, Battistella PA, Drigo P. Acute-onset transient hydrocephalus after suspension of ACTH therapy for infantile spasms: A case report. *Ital J Neurol Sci* 1984;5:219-22.
 10. Lusi EA, Vellimana AK, Ray WZ, Chicoine MR, Jost SC. Transient obstructive hydrocephalus due to intraventricular hemorrhage: A case report and review of literature. *J Clin Neurol* 2013;9:1925.
 11. Mao G, Agarwal N, Zuccoli G, Tyler-Kabara EC. Intermittent entrapment of choroid plexus in ventricular catheter. *Interdiscip Neurosurg* 2017;9:17-9.
 12. Martínez-Lage JF, Martos-Tello JM, Ros-de-San Pedro J, Almagro MJ. Severe constipation: An under-appreciated cause of VP shunt malfunction: A case-based update. *Childs Nerv Syst* 2008;24:431-5.
 13. Morais BA, Cardeal DD, Andrade FG, Paiva WS, Matushita H, Teixeira MJ. Reversible ventriculoperitoneal shunt dysfunction and chronic constipation: Case report. *J Neurosurg Pediatr* 2018;22:147-50.
 14. Muzumdar D, Ventureyra EC. Transient ventriculoperitoneal shunt malfunction after chronic constipation: Case report and review of literature. *Childs Nerv Syst* 2007;23:455-8.
 15. Powers CJ, George T, Fuchs HE. Constipation as a reversible cause of ventriculoperitoneal shunt failure. Report of two cases. *J Neurosurg* 2006;105 Suppl 3:227-30.
 16. Prabhu SS, Sharma RR, Gurusinghe NT, Parekh HC. Acute transient hydrocephalus in carbon monoxide poisoning: A case report. *J Neurol Neurosurg Psychiatry* 1993;56:567-8.
 17. Ramos-Zuñiga R, Jiménez-Guerra R. Rational management of transient obstructive hydrocephalus secondary to a cerebellar infarct. *Minim Invasive Neurosurg* 2006;49:302-4.
 18. Sasaki O, Furusawa Y, Takahara Y. Transient obstructive hydrocephalus of an infant following mild head injury (author's transl). *No Shinkei Geka* 1981;9:407-9.
 19. Sharma RR, Chandry MJ, Lad SD. Transient hydrocephalus and acute lead encephalopathy in neonates and infants. Report of two cases. *Br J Neurosurg* 1990;4:141-5.
 20. Sivaganesan A, Krishnamurthy R, Sahni D, Viswanathan C. Neuroimaging of ventriculoperitoneal shunt complications in children. *Pediatr Radiol* 2012;42:1029-46.
 21. Stone JJ, Walker CT, Jacobson M, Phillips V, Silberstein HJ. Revision rate of pediatric ventriculoperitoneal shunts after 15 years. *J Neurosurg Pediatr* 2013;11:15-9.
 22. Tubbs RS, Wellons JC 3rd, Blount JP, Oakes WJ. Transient ventriculoperitoneal shunt dysfunction in children with myelodysplasia and urinary bladder infection. Report of three cases. *J Neurosurg* 2005;102 Suppl 2:221-3.
 23. Vakis AF, Karabetsos DA, Koutentakis DI, Flouris G, Fasoulaki M. Transient acute obstructive hydrocephalus of unknown origin in a 13-month-old infant. *Eur J Paediatr Neurol* 2006;10:197-201.

How to cite this article: Mondragon-Soto MG, Elkaim L, Weil AG. Transient ventriculoperitoneal shunt malfunction in a pediatric patient: An illustrative case. *Surg Neurol Int* 2022;13:6.