

# Incidents and Complications of Permanent Venous Central Access Systems: A Series of 1,460 Cases

Massine El Hammoumi, M.D.<sup>1</sup>, Mohammed El Ouazni, M.D.<sup>2</sup>, Adil Arsalane, M.D.<sup>1</sup>,  
Fayçal El Oueriachi, M.D.<sup>1</sup>, Hamid Mansouri, M.D., Ph.D.<sup>3</sup>, El Hassane Kabiri, M.D., Ph.D.<sup>1</sup>

**Background:** Implanted venous access devices or permanent central venous access systems (PCVASs) are routinely used in oncologic patients. Complications can occur during the implantation or use of such devices. We describe such complications of the PCVAS and their management. **Methods:** Our retrospective study included 1,460 cases in which PCVAS was implanted in the 11 years between January 2002 and January 2013, including 810 women and 650 men with an average age of 45.2 years. We used polyurethane or silicone catheters. The site of insertion and the surgical or percutaneous procedure were selected on the basis of clinical data and disease information. The subclavian and cephalic veins were our most common sites of insertion. **Results:** About 1,100 cases (75%) underwent surgery by training surgeons and 360 patients by expert surgeons. Perioperative incidents occurred in 33% and 12% of these patients, respectively. Incidents (28%) included technical difficulties (n=64), a subcutaneous hematoma (n=37), pneumothoraces (n=15), and an intrapleural catheter (n=1). Complications in the short and medium term were present in 14.2% of the cases. Distortion and rupture of the catheter (n=5) were noted in the costoclavicular area (pinch-off syndrome). There were 5 cases of catheter migration into the jugular vein (n=1), superior vena cava (n=1), and heart cavities (n=3). No patient died of PCVAS insertion or complication. **Conclusion:** PCVAS complications should be diagnosed early and treated with probable removal of this material for preventing any life-threatening outcome associated with complicated PCVAS.

Key words: 1. Central venous access  
2. Complications  
3. Incidents

## INTRODUCTION

Implanted venous access devices or permanent central venous access systems (PCVASs) have been routinely used in oncologic patients since the 1980s [1]. They are made of a central venous catheter connected to a chamber or reservoir surgically implanted in a subcutaneous pocket [2]. The most common insertion sites are the internal jugular, subclavian

veins, and, more rarely, the cephalic veins, external jugular, and brachial and femoral veins [3]. These implantable chambers ensure the possibility of direct, repetitive central venous access with a lower risk of infection [4] by sparing the patients' venous integrity, which can be compromised by drug toxicity [2].

Additionally, parenteral nutrition, blood transfusion, and blood sampling can be performed via PCVAS [5]. A few au-

<sup>1</sup>Department of Thoracic Surgery, Mohamed V Military University Hospital; <sup>2</sup>Department of General Surgery, Avicenne Hospital; <sup>3</sup>Department of Radiotherapy, Mohamed V Military University Hospital

Received: May 29, 2013, Revised: October 2, 2013, Accepted: October 7, 2013

Corresponding author: Massine El Hammoumi, Department of Thoracic Surgery, Mohamed V Military University Hospital, Riad 10100 Rabat, Morocco

(Tel) 212-6-7601-7058 (Fax) 212-537-879652 (Email) hamoumimassine@hotmail.fr

© The Korean Society for Thoracic and Cardiovascular Surgery. 2014. All right reserved.

© This is an open access article distributed under the terms of the Creative Commons Attribution Non-Commercial License (<http://creativecommons.org/licenses/by-nc/3.0>) which permits unrestricted non-commercial use, distribution, and reproduction in any medium, provided the original work is properly cited.

**Table 1.** Perioperative incidents of implantation of permanent central venous access system

Perioperative incidents	Percutaneous procedure (n=1,008; mean time=31 min)	Direct Surgical procedure (n=452; mean time=46 min)
Technical difficulty	45 (14.4)	19 (19)
Subcutaneous hematoma <sup>a)</sup>	16 (5.1)	21 (21)
pneumothorax	15 (4.8)	0
Intra pleural catheter	1 (0.32)	0
Heart rhythm disorder	70 (22.5)	55 (55)
Arterial puncture	112 (36)	0
Catheter displacement	52 (16.6)	5 (5)
Total	311 (30.8)	100 (22.2)

Values are presented as number (%).

<sup>a)</sup>Patients with platelet inhibitors.

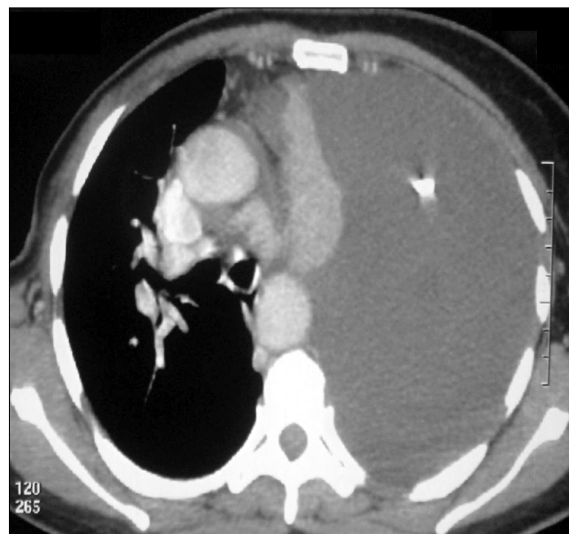
thors have reported the benefit of PCVAS use in refractory ascites and pleural effusions for avoiding morbidity and patients’ anxiety related to repeated puncture and aspiration [6].

Nevertheless, the presence of an intravascular catheter could lead to 4 major complications: infection, thrombosis, catheter rupture, and extravasations of fluid around the reservoir [5]. Although rare, these complications could be severe and life threatening. We aim to report retrospectively the prevalence and management of perioperative incidents and complications associated with PCVAS.

## METHODS

Our retrospective study comprised 1,460 cases with PCVAS implanted between January 2002 and February 2013, including 810 women and 650 men with an average age of 45.2 years. Radiopaque polyurethane catheters were the most commonly used, whereas silicone catheters were used less frequently. These catheters had an internal diameter of 1 mm and a reservoir capacity of 0.3 or 0.5 mL. The chambers were made of metallic (titanium) or plastic material. The insertion site was selected on the basis of clinical data. In patients with lung cancer, we used the same side to perform a vessel puncture, while the opposite side was preferred in cases of breast cancer. The cephalic and subclavian veins were our most common insertion sites.

We used a direct approach toward the cephalic vein if the



**Fig. 1.** Chest computed tomography showing a left intrapleural catheter.

patient presented with subclavian lymph nodes or hematological diseases, or had undergone a pneumonectomy previously. This approach could prevent arterial puncture in the case of hematological disease with a probable coagulation disorder, was easier than performing percutaneous puncture in the case of subclavian lymph nodes, and protected the pneumonectomy cavity from septic puncture. In this report, we call any perioperative problem an ‘incident’ and any medium- or long-term problem a ‘complication.’

## RESULTS

The procedures were direct surgery of the cephalic or the jugular vein in 452 cases and percutaneous subclavian or jugular vein puncture in 1,008 cases. All patients underwent radioscopic control on the operating table or a chest X-ray after surgery.

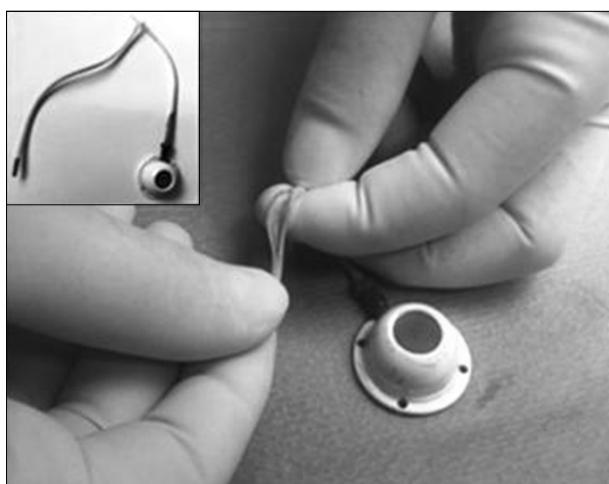
Perioperative incidents (Table 1) included a technical difficulty in 64 cases, subcutaneous hematoma in 37 cases, pneumothoraces in 15 cases, and accidental intrapleural catheter placement in 1 case (Fig. 1). We considered the case of intrapleural catheter as an accidental displacement because the catheter was not located inside a vessel but was free in the pleural space. Short- and medium-term complications developed in 14.2% of the cases (Table 2). Subclavian vein throm-

**Table 2.** Complications of the PCVAS and related-disease data

Complications (medium and long term)	Hematological disease (N1=520)		Non hematological disease (solid tumor) (N2= 940)		n <sup>1</sup> +n <sup>2</sup> and percentage of N		Removal of PCVAS (% of n <sup>1</sup> +n <sup>2</sup> )
	n <sup>1</sup>	% of N1	n <sup>2</sup>	% of N2	n <sup>1</sup> +n <sup>2</sup>	% of N	
Infectionsgram negative bacillus, gram positif cocci)	61	11.7	34	3.6	95	6.5	95 (100)
Sepsis (peripheral vein and catheter)	11	2.1	9	0.9	20	1.3	20 (100)
Deep vein thrombosis	12	2.3	10	1	22	1.5	22 (100)
Skin necrosis	20	3.8	15	1.5	35	2.4	10 (28.5)
Pinch-off (distortion and rupture)	2	0.3	3	0.3	5	0.3	4 (80)
Catheter occlusion or disconnection	15	2.8	13	1.3	28	1.9	28 (100)
Catheter migration	3	0.5	2	0.2	5	0.3	4 (80)
Total	120	23	88	9.3	208	14.2	183 (87) <sup>a)</sup>
% of N (N=1,460)		8.21		6		14.2	12.5

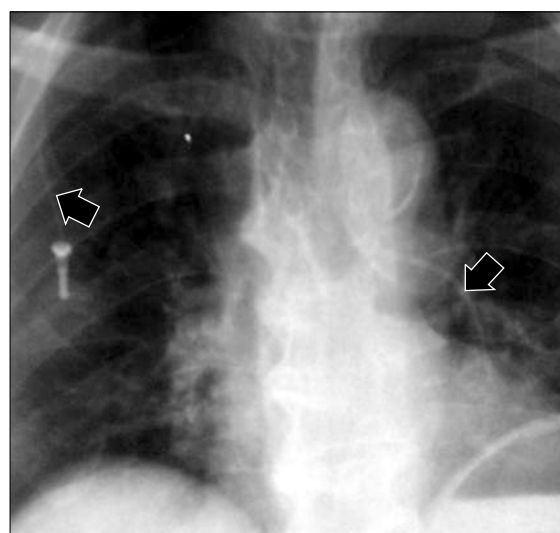
PCVAS, permanent central vein access system.

<sup>a)</sup>Eighty-seven percent of complicated PCVAS were removed.



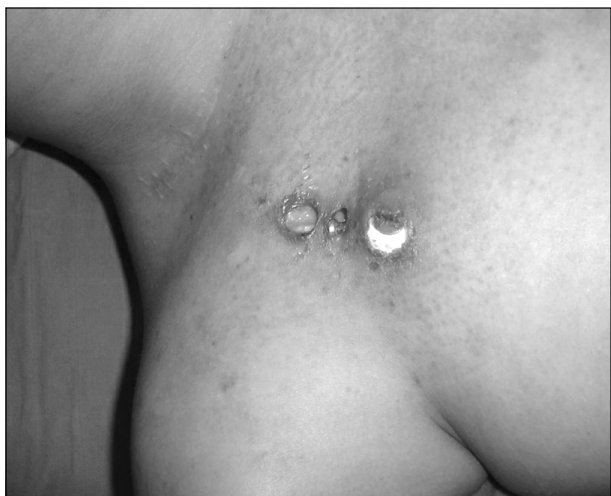**Fig. 2.** Perioperative view showing the rupture distortion of the catheter (pinch-off syndrome).

basis was not observed in our patients, either uniquely or in association with another complication. Catheter distortion and rupture was noted in the costoclavicular area (pinch-off syndrome) (n=5) (Fig. 2). The 5 noted cases of catheter migration were into the jugular vein (n=1), superior vena cava (n=1), and heart chambers (n=3) (Fig. 3). The treatment of these complications consisted of PCVAS removal in the cases of catheter infection, sepsis, occlusion, disconnection, or associated vein thrombosis. Skin necrosis (Fig. 4) was repaired surgically if possible or if not infected. Migrated catheter ex-



**Fig. 3.** Chest radiograph with a catheter ruptured and migrated into the right ventricle with complete disconnection between the distal and the proximal catheters.

traction was performed by venous catheterization or via catheterization of the femoral artery in the case of migration into the cardiac chambers. In 13 cases, device occlusion was successfully treated without PCVAS removal by tunneling the catheter and injecting heparin into the reservoir. None of the patients included in our study died of a complication arising from PCVAS insertion. We observed no complications related to inadvertent arterial puncture during percutaneous PCVAS

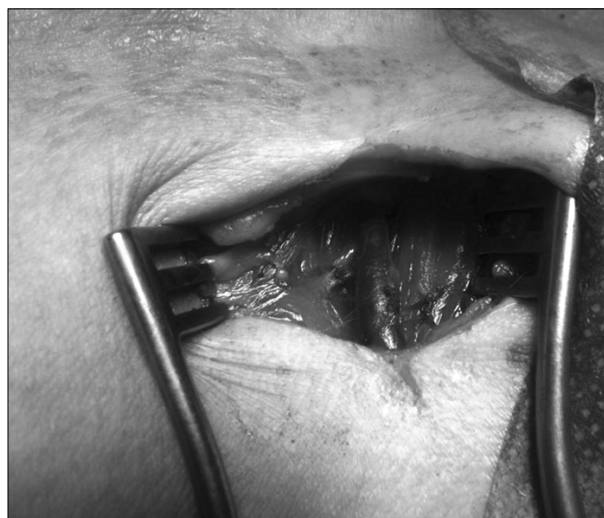

**Fig. 4.** Perioperative view of a skin necrosis related to permanent central vein access system.

insertion. The mean operation time was 34.7 minutes (median, 30; range, 19 to 92 minutes). The cephalic vein (Fig. 5) was not detected in 10 cases, and the cephalic vein was too narrow to insert the catheter in 5 cases. About 1,100 cases (75%) underwent surgery by in-training surgeons, and 360 patients were operated on by expert surgeons. Perioperative incidents occurred in 33% and 12%, respectively, of the patients in these groups. The use of ultrasound for locating and puncturing a vein involves delicate operator coordination between the hand holding the needle and syringe, the hand holding the probe over the vein, and the eyes watching the image on the screen of a portable ultrasound machine. These skills are naturally developed over time. We used ultrasound in just 52 cases (3.5%). We consider direct venous abord to be indicated after three missed punctures.

## DISCUSSION

PCVASs are now routinely used for facilitating the care of chronically ill patients. A PCVAS contains a chamber covered by a silicone membrane and with a lateral opening to which a catheter tube is connected. The catheter tube is tunneled subcutaneously or by using the open venous cut-down technique, usually under local anesthesia. Vein dissection and pouch creation for the portal can be performed through the same 4-cm-long incision, and the catheter is introduced by



**Fig. 5.** Perioperative view with an exposure of the left cephalic vein before insertion of the permanent central vein access system.

way of the subclavian or jugular vein to a position just above the right atrium.

The port can be used directly after implantation. Port punctures must be performed with a strictly aseptic technique [7]. Depending on the particular model, ports can be punctured 1,000 to 8,000 times [8].

When palpated, the port membrane can be punctured easily. The port membrane and the skin should be punctured at a site different from that of the last puncture [9]. Redness, swelling, or discharge at the implantation site should be noted before any puncture.

Technical difficulties include difficult venous puncture. A few risk factors are known to be associated, such as obesity, female gender, previous local surgery or radiotherapy, and lack of operator training.

A few intraoperative complications are slightly related to the chosen procedure. Pneumothorax is more frequently associated with subclavian rather than jugular vein puncture [10]. The direct vein cut-down ensures a safe procedure because it preserves the pleural space. The intrapleural catheter placement was accidental. Therefore, we insist that PCVAS surgery should be performed by experienced personnel or under supervision at training hospitals.

Subcutaneous hematoma or bleeding complications must be anticipated. Management of antiplatelet agents and anti-

coagulants should be subject to the same rules as any other surgery, particularly in patients with hematological diseases or in the case of probable arterial puncture. Intraoperative heart rhythm disorder principally induced by the presence of the catheter in the cardiac cavities is a classical sign for confirming that the catheter is in the right direction before radiological control. The catheter length should be reduced just above the right atrium.

PCVAS infection is a relatively common complication (frequency of up to 6.5%) [11]. In our series, infection or PCVAS-related sepsis was almost 7.8%. Gram-negative bacilli and gram-positive cocci were the most commonly isolated microorganisms (60% and 31%, respectively). A meta-analysis of 14 prospective studies reported a 3.6% prevalence of infection in hemato-oncological patients and an incidence density of 0.1/1,000 catheter-days [12]. The main risk factors are neutropenia, parenteral nutrition, young age, difficulties during insertion, and poor general status. Recent guidelines have defined intravascular catheter-related infections [13]. A strict clinical and microbiological work-up, including simultaneous culture of blood drawn from the catheter and a peripheral vein, should be performed.

More recently, an observational study showed an association between the frequency of complications and the time of first use: 10.6%, 6.7%, and 2%, respectively, when the PCVAS was used within 3 days, between 4 and 7 days, and 7 days after the placement [14]. We allowed device use 24 hours after its implantation. Device removal was mandatory when an infection was documented.

The use of prophylactic antibiotics is controversial. A few investigators use them, but many do not. We chose to not use them initially and have stuck to our original choice. We insist on prevention by the strict aseptic handling of the PCVAS. Only special needles with a 'Huber tip' should be used for puncturing the device: conventional needles punch holes in the membrane, and once the needle is removed, the port is unusable because the membrane is no longer reliably sealed.

Venous thrombosis has been described as an early complication of PCVAS [15]. The literature contains only a few reports of the complete thrombosis of the superior vena cava and the development of a superior vena cava syndrome [16].

In our study, the occurrence of venous thrombosis is 1.5%, and the majority of the occurrences were recorded in the second month after implantation. In the literature, it is higher and ranges from 6% to 61% due to different clinical and radiologic diagnostic criteria. We performed Doppler ultrasonography only in the presence of clinical phlebitis symptoms and differentiated central venous catheter thrombosis (1.9% in our series) from venous thrombosis. Doppler ultrasonography has low sensitivity in the diagnosis of PCVAS, particularly in the detection of subclavian vein thrombosis [17]. However, in our study, no case of subclavian thrombosis was detected.

A recent study recommended the combination of venography and echography for the diagnosis of asymptomatic thrombosis [18]. In the literature, several risk factors have been studied, such as large bulky cervical or mediastinal tumors. Silicone and polyurethane catheters are less thrombogenic than polyvinylchloride and polyethylene catheters [19]. Catheter heparinization was not proven to prevent thrombosis [20]. There is no consensus concerning therapy for the vein thrombosis of PCVAS. The catheter tip must be placed at the level or under T4 using radioscopic guidance. Luciani et al. [16] have demonstrated an association between the positioning of the distal catheter tip and thrombotic complications. There is no study on the role of the insertion method (percutaneously versus direct surgery) and the choice of vein (jugular or subclavian). The patient's age, primary tumor type, and chemotherapy were not considered specific risk factors [21]. Systematic prophylactic treatment with low-molecular-weight heparin did not show any benefit in the treated patients [22]. We typically heparinize the catheter after any perfusion to prevent fibrin adhesion to the catheter wall and distal end occlusion.

The pinch-off syndrome (POS) has been reported as a PCVAS complication. This syndrome is caused by the compression of the catheter by the clavicle and the first rib [23], which leads to catheter obstruction and fracture. The cut-down technique seems to have a lower association with the pinch-off syndrome in a number of studies [24,25]. In our study, 2 of the 5 cases with POS were asymptomatic and incidentally discovered. The other cases were diagnosed with luminal narrowing or complete catheter fracture on a chest

radiograph. In our opinion, the use of the subclavian route and polyurethane catheters seems to have a greater association with this complication. POS treatment involves careful catheter removal. If the catheter tip is embolized, it can usually be retrieved percutaneously with a transvenous snare. POS can be prevented by using the internal jugular vein for access rather than the subclavian vein. This complication can be ascribed to forceful injections or to intrathoracic pressure changes generated by coughing or intrathoracic disorders [26].

Catheter migration was secondary to the total rupture of the catheter, which warrants percutaneous retrieval. Transvenous retrieval was successful in 4 cases. In the fifth case of catheter migration, there was a high risk of surgery, therefore the catheter was retained in place and the patient died six months later by an advanced lymphoma.

In summary, PCVAS provides a safe and inexpensive means of venous access and patient comfort. The exclusion criteria for PCVAS installation are infected areas, major coagulation disorders, skin metastasis, previously irradiated areas, and thrombosis of the superior vena cava or the subclavian vein. Appropriate handling is of crucial importance so that complications such as port thrombosis and infections can be avoided. Clinicians should carefully watch for the evidence of central venous line dysfunction that usually accompanies these complications.

## CONFLICT OF INTEREST

No potential conflict of interest relevant to this article was reported.

## REFERENCES

- Niederhuber JE, Ensminger W, Gyves JW, Liepman M, Doan K, Cozzi E. *Totally implanted venous and arterial access system to replace external catheters in cancer treatment*. *Surgery* 1982;92:706-12.
- Vescia S, Baumgartner AK, Jacobs VR, et al. *Management of venous port systems in oncology: a review of current evidence*. *Ann Oncol* 2008;19:9-15.
- Wolosker N, Yazbek G, Nishinari K, et al. *Totally implantable venous catheters for chemotherapy: experience in 500 patients*. *Sao Paulo Med J* 2004;122:147-51.
- Groeger JS, Lucas AB, Thaler HT, et al. *Infectious morbidity associated with long-term use of venous access devices in patients with cancer*. *Ann Intern Med* 1993;119:1168-74.
- Bow EJ, Kilpatrick MG, Clinch JJ. *Totally implantable venous access ports systems for patients receiving chemotherapy for solid tissue malignancies: a randomized controlled clinical trial examining the safety, efficacy, costs, and impact on quality of life*. *J Clin Oncol* 1999;17:1267.
- Inan I, De Sousa S, Myers PO, et al. *Management of malignant pleural effusion and ascites by a triple access multi perforated large diameter catheter port system*. *World J Surg Oncol* 2008;6:85.
- Muller H. *Risiken und Komplikationen implantierter Kathetersysteme*. *Deutsch Z Onkol* 2006;38:79-84.
- Hasskarl J, Koberich S, Frydrychowicz A, Illerhaus G, Waller CF. *Complete caval thrombosis secondary to an implanted venous port: a case study*. *Dtsch Arztebl Int* 2008; 105:18-21.
- Beckmann M, Lorenz C, Dall P. *Platzierung und pflege von venosen verweilkathetern und portsystemen*. *Gynakologie* 2000;33:255-60.
- El Hammoumi MM, Drissi G, Achir A, Benchekroun A, Benosman A, Kabiri EH. *Iatrogenic pneumothorax: experience of a Moroccan Emergency Center*. *Rev Port Pneumol* 2013;19:65-9.
- Stelzer S. *Langzeitergebnisse nach implantation von zentralvenosen port- systemen: dissertation Klinik und Poliklinik fur Mund-, Kiefer- und Gesichtschirurgie, Klinikum rechts der Isar*. *Dtsch Arztebl Int* 2008;105:18-21.
- Maki DG, Kluger DM, Crnich CJ. *The risk of bloodstream infection in adults with different intravascular devices: a systematic review of 200 published prospective studies*. *Mayo Clin Proc* 2006;81:1159-71.
- Lebeaux D, Zarrouk V, Leflon-Guibout V, Lefort A, Fantin B. *Totally implanted access port-related infections: features and management*. *Rev Med Interne* 2010;31:819-27.
- Narducci F, Jean-Laurent M, Boulanger L, et al. *Totally implantable venous access port systems and risk factors for complications: a one-year prospective study in a cancer centre*. *Eur J Surg Oncol* 2011;37:913-8.
- Luciani A, Clement O, Halimi P, et al. *Catheter-related upper extremity deep venous thrombosis in cancer patients: a prospective study based on Doppler US*. *Radiology* 2001; 220:655-60.
- Stockx L, Raat H, Donck J, Wilms G, Marchal G. *Repositioning and leaving in situ the central venous catheter during percutaneous treatment of associated superior vena cava syndrome: a report of eight cases*. *Cardiovasc Intervent Radiol* 1999;22:224-6.
- Haire WD, Lynch TG, Lieberman RP, Lund GB, Edney JA. *Utility of duplex ultrasound in the diagnosis of asymptomatic catheter-induced subclavian vein thrombosis*. *J Ultrasound Med* 1991;10:493-6.

18. Male C, Chait P, Ginsberg JS, et al. *Comparison of venography and ultrasound for the diagnosis of asymptomatic deep vein thrombosis in the upper body in children: results of the PARKAA study. Prophylactic Antithrombin Replacement in Kids with ALL treated with Asparaginase.* *Thromb Haemost* 2002;87:593-8.
19. Borow M, Crowley JG. *Evaluation of central venous catheter thrombogenicity.* *Acta Anaesthesiol Scand Suppl* 1985;81: 59-64.
20. Theard JL, Robard S. *Outcome of usage protocols on implantable devices.* *Ann Fr Anesth Reanim* 1995;14:534-5.
21. Brown DF, Muirhead MJ, Travis PM, Vire SR, Weller J, Hauer-Jensen M. *Mode of chemotherapy does not affect complications with an implantable venous access device.* *Cancer* 1997;80:966-72.
22. Reichardt P, Kretschmar A, Biakhov M, et al. *A phase III, randomized, double-blind, placebo-controlled study evaluating the efficacy and safety of daily low-molecular-weight-heparin (dalteparin sodium) in preventing catheter-related complications (CRCs) in cancer patients with central venous catheters (CVCs).* *Proc Am Soc Clin Oncol* 2002;21:369a.
23. Hinke DH, Zandt-Stastny DA, Goodman LR, Quebbeman EJ, Krzywda EA, Andris DA. *Pinch-off syndrome: a complication of implantable subclavian venous access devices.* *Radiology* 1990;177:353-6.
24. Sarzo G, Finco C, Parise P, et al. *Insertion of prolonged venous access device: a comparison between surgical cutdown and percutaneous techniques.* *Chir Ital* 2004;56:437-42.
25. Chang HM, Hsieh CB, Hsieh HF, et al. *An alternative technique for totally implantable central venous access devices: a retrospective study of 1311 cases.* *Eur J Surg Oncol* 2006; 32:90-3.
26. Desruennes E. *Mechanical complications at implantation sites.* *Pathol Biol (Paris)* 1999;47:269-72.