

Paradoxical preexcitation following successful ablation of a concealed accessory pathway



Maged F. Nageh, MD, FHRS, Kamal Kotak, MD

From the Department of Electrophysiology, Los Angeles Medical Center, Kaiser Permanente Southern California, Los Angeles, California.

Introduction

Catheter ablation is an established curative treatment for accessory pathways (APs), but in spite of the great progress made in the diagnosis and treatment, there is limited knowledge of the underlying cellular pathophysiology that determines the different clinical presentations. The case presented highlights the complex presentation and properties of some APs that can be encountered at the time of the ablation procedure.

Case presentation

A 24-year-old man with daily palpitations presented to the Emergency Department with sustained regular long RP supraventricular tachycardia (SVT) that spontaneously terminated. Telemetry and 12-lead electrocardiogram showed frequent unifocal premature atrial contractions (PACs) with similar P-wave morphology and axis to that of SVT (Figure 1A,B).

The patient was referred for a catheter ablation procedure, which revealed nondecremental retrograde conduction with earliest activation at the coronary sinus (CS) ostium (posteroseptal), similar to the activation of PACs (Figure 1C). There was no evidence of preexcitation at any time at baseline with PR duration >240 ms/HV interval = 55 ms, with atrial pacing, or on Isuprel (Figure 1C).

When the patient was on Isuprel, an incessant regular long RP SVT was induced. The pacing maneuvers were all consistent with an orthodromic atrioventricular reentry tachycardia (AVRT); post pacing interval following entrainment from the right ventricles was <115 ms, and His-timed ventricular extrastimulus terminated the SVT with ventriculoatrial conduction block (Figure 1D). Based on these findings, mapping and ablation of the concealed posteroseptal AP was performed.

KEYWORDS Paradoxical preexcitation; Dormant pathways; Ablation (Heart Rhythm Case Reports 2016;2:149–152)

Address reprint requests and correspondence: Dr Maged F. Nageh, Southern California Permanente Medical Group, Kaiser Permanente Los Angeles Medical Center—Regional Arrhythmia Center, 4867 Sunset Blvd, Los Angeles, CA 90036. E-mail address: Maged.F.Nageh@Kp.org.

Electroanatomic mapping (Biosense Webster Inc, Diamond Bar, CA) of the earliest retrograde atrial activation was noted inside the CS, at the ostium of the middle cardiac vein, as shown in Figure 3A, which was verified by CS venogram. Radiofrequency (RF) ablation at that site terminated the SVT in <2 seconds (Figure 1E).

Post ablation, there were no ventriculoatrial conduction and no PACs, which were most likely reentrant atrioventricular echo beats via the concealed posteroseptal AP, facilitated by the slow antegrade (AG) atrioventricular (AV) nodal conduction at baseline (PR >240 ms).^{1,2} However, a few minutes post ablation, preexcitation in sinus rhythm as well as with CS pacing was observed (Figure 2A).

The manifest AP conducted only antegradely (AG block <280 ms), with -ve (negative) delta waves in V1 and +ve (positive) in lead II, lead III, and aVF. Ventricular activation mapping of right and left posteroseptum, mapped via patent foramen ovale, was late.

Early activation was recorded at the left mid-septum (Figure 2B), where RF applications transiently eliminated the AP. Mapping of the right mid-septum showed a similar early pre-delta interval (Figure 2C). Although RF applications higher at the right mid-septum eliminated AP conduction in <5 seconds, they were associated with fast junctional beats, indicating close proximity to the compact AV node and high risk for complete heart block; therefore no further ablations were performed. At the end of the procedure, preexcitation was intermittent, with normal AV nodal conduction, but the postprocedure electrocardiogram performed an hour later showed neither preexcitation nor PACs with normal PR interval.

Discussion

The phenomenon of paradoxical preexcitation after successful ablation of a concealed pathway can be explained by:

- 1) A single AP with 2 different ventricular insertions: linking between the posteroseptal and midseptal (concealed retrograde conduction of the midseptal insertion) AP limits AG conduction and manifest preexcitation at baseline.³ In support of this mechanism is the close distance between the mapped pathways, which measured

KEY TEACHING POINTS

- The manifestation of accessory pathways can be modified by several factors, including other pathways nearby.
- Catheter ablation of active pathways—concealed or manifest—can facilitate the manifestation of dormant pathways.
- Dormant pathways have the potential for fast conduction and can participate in atrioventricular reentry.

10–14 mm (midseptal AP location points on either side of the septum are almost equidistant from the posteroseptal AP, Figure 3A). However, the midseptal AP AG conduction properties, which are neither decremental nor weak (<300 ms), do not explain the absence of preexcitation at baseline

2) Two separate APs (the more plausible explanation): an active concealed posteroseptal pathway and a dormant midseptal AP. The following are potential mechanism(s) that could have promoted the manifestation of the dormant AP post ablation:

- Electrotonic* modulation (suppression) of the midseptal AP transmembrane potential by the neighboring active posteroseptal AP.^{4,5}
- Modification of the transmembrane potential of the dormant midseptal AP by the *thermal* effects of RF

applications at the posteroseptum leading to hyperpolarization and facilitation of AP conduction. The thermal effects of RF ablation, though, are expected to be transient.⁶

- Source (current)–sink mismatch at the level of the ventricular insertion of the midseptal pathway that limits the spread of AG conduction. The mismatch is modified (corrected),⁷ after ablation at the *ventricular* insertion of the concealed posteroseptal AP (Figure 3B).

It is also possible that the combined effects of all 3 mechanisms promoted the manifestation of the dormant midseptal AP.

The presented case highlights the importance of recognizing dormant APs when studying active APs—whether concealed or manifest—as well as understanding the complex interactions between APs in close proximity, the AV conduction system, and the myocardial tissue at their insertion sites.

Dormant APs should not always be dismissed as innocent bystanders, as they can be capable of fast conduction, as seen in this case, and can be involved in reentrant tachycardia.

In one study of 54 patients with recurrence of clinical symptoms post successful AP ablation, dormant APs were responsible for the clinical arrhythmias in 9 patients (16%).⁸

The decision to ablate dormant APs that conduct only antegradely (as in our patient) can be challenging. Since dormant APs manifest intermittently, they would be expected to have slow AG conduction; however, owing to

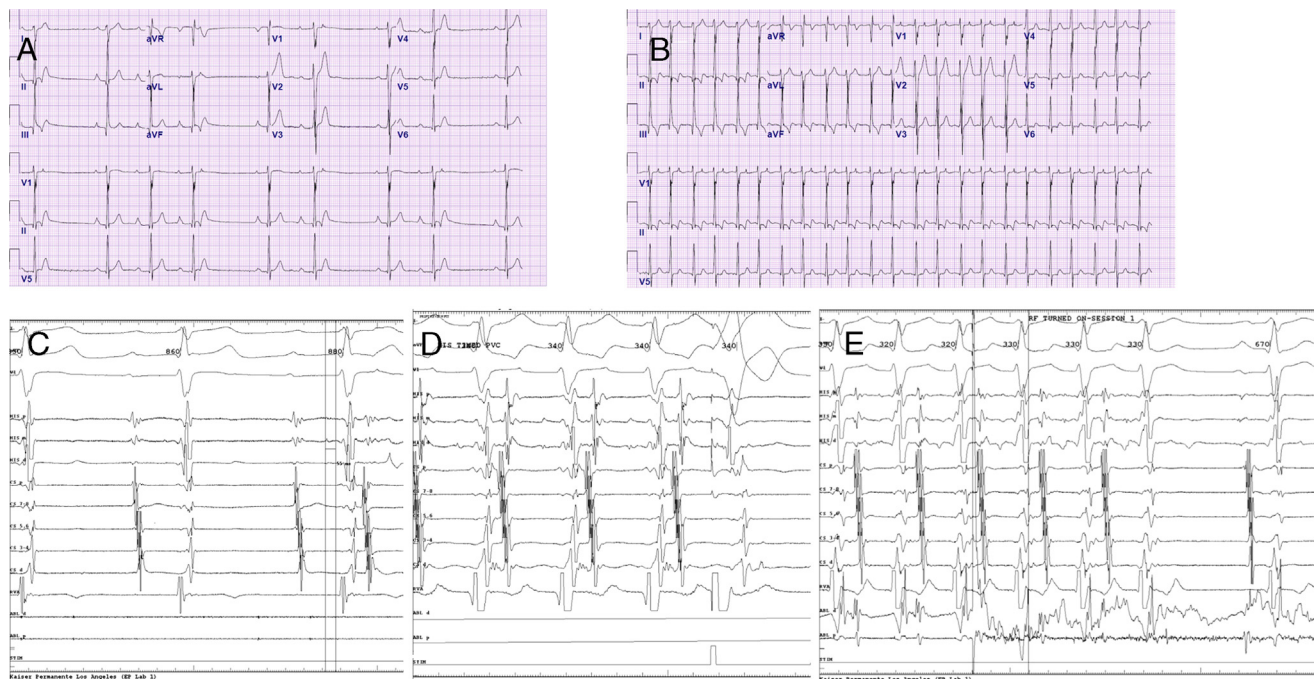


Figure 1 A: Twelve-lead electrocardiogram (EKG) of sinus rhythm with echo beats from the concealed posteroseptal pathway in trigeminy and quadrigeminy pattern. B: Twelve-lead EKG of long RP supraventricular tachycardia (SVT). C: Sinus rhythm showing HV interval = 53 ms and echo beats from the concealed posteroseptal pathway. D: His-timed ventricular extrastimulus terminated the SVT with ventriculoatrial conduction block. E: Ablation of concealed pathway at the ostium of the middle cardiac vein with termination of incessant SVT.

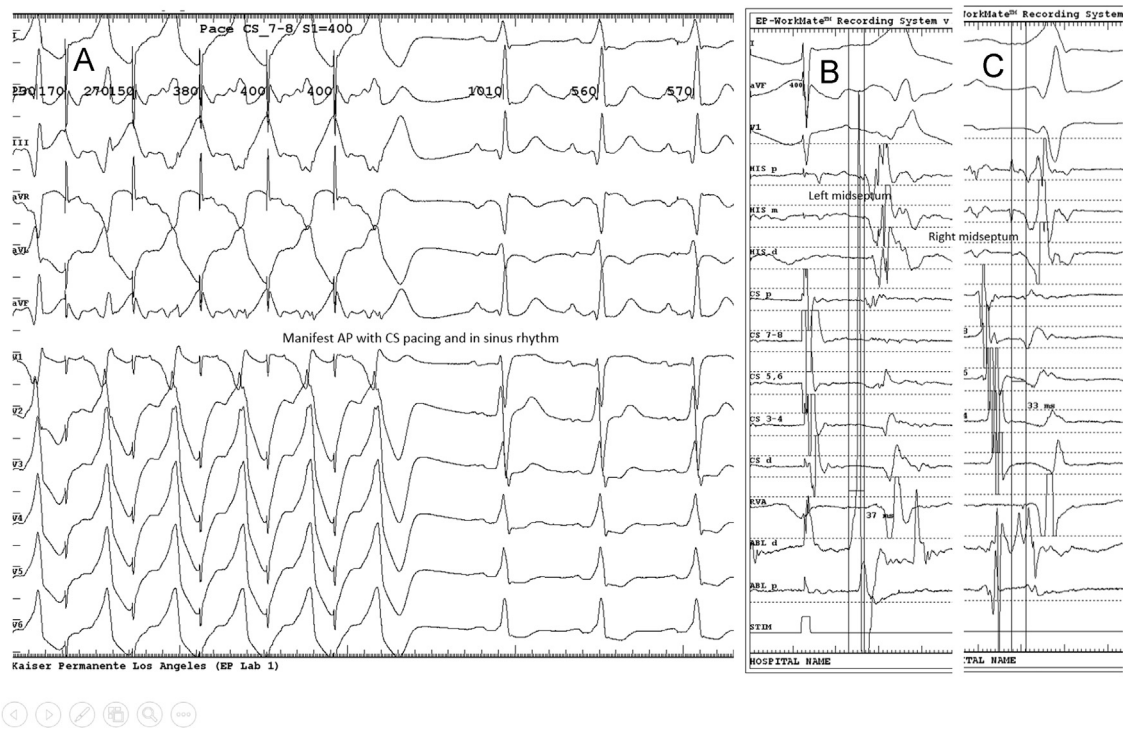


Figure 2 A: Twelve-lead electrocardiogram of manifest accessory pathway (AP) with coronary sinus (CS) pacing and in sinus rhythm. B: Earliest site mapped at left midseptum (pre-delta = 37 ms). C: Earliest site mapped at right midseptum (pre-delta = 33 ms).

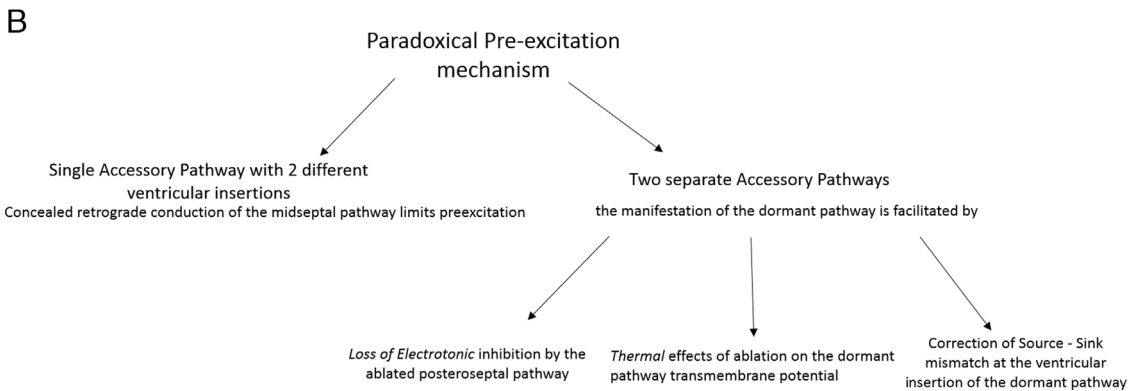
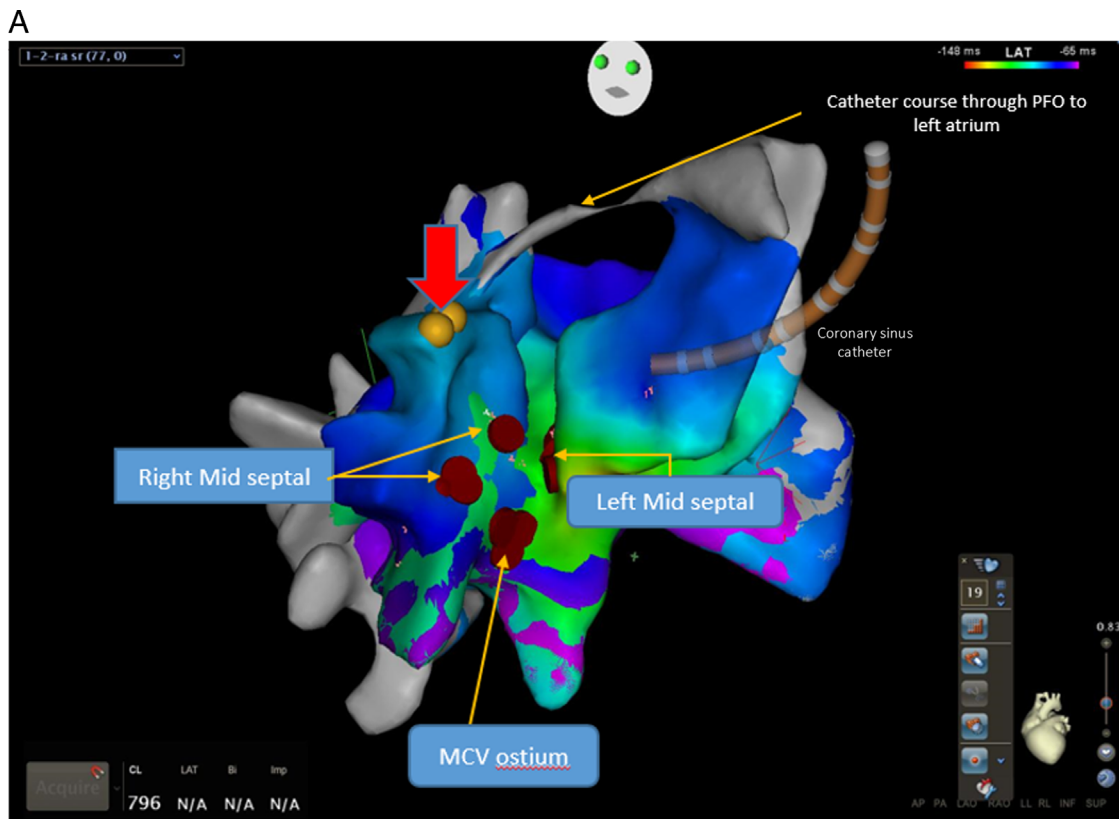


Figure 3 **A:** Left anterior oblique view of electroanatomic map with cranial tilt to visualize right and left sides of atrial septum. Red dots indicate ablation sites of the concealed accessory pathway (AP) at middle cardiac vein (MCV) ostium and of the manifest AP at right and left midseptum. *Red arrow:* His location; also shown is the position of the coronary sinus catheter. **B:** Summary of the proposed mechanisms for the phenomenon of paradoxical preexcitation.

the wide fluctuation of their conduction velocities and their nondecremental conduction properties, the potential for rapid conduction—as seen in some patients with intermittent preexcitation—cannot be completely ruled out.^{9,10}

References

- Spach MS, Josephson ME. Initiating reentry: the role of nonuniform anisotropy in small circuits. *J Cardiovasc Electrophysiol* 1994;5:182–209.
- Suzuki F, Kawara T, Tanaka K, Harada TO, Endoh T, Kanazawa Y, Okishige K, Hirao K, Hiejima K. Electrophysiological demonstration of anterograde concealed conduction in accessory atrioventricular pathways capable only of retrograde conduction. *Pacing Clin Electrophysiol* 1989;12:591–603.
- Gonzalez MD, Greenspon AJ, Kidwell GA. Linking in accessory pathways. Functional loss of antegrade preexcitation. *Circulation* 1991;83:1221–1231.
- Antzelevitch C, Moe GK. Electrotonic inhibition and summation of impulse conduction in mammalian Purkinje fibers. *Am J Physiol* 1983;245:H42–H53.
- Krahn AD, Klein GJ, Yee R. Time-dependent change in fast pathway refractoriness after slow pathway ablation in atrioventricular node reentrant tachycardia. *Mansfield Polaris Investigators. Can J Cardiol* 1997;13:583–588.
- Simmers TA, De Bakker JM, Wittkamp FH, Hauer RN. Effects of heating on impulse propagation in superfused canine myocardium. *J Am Coll Cardiol* 1995;25:1457–1464.
- Rohr S, Kucera JP, Fast VG, Kleber AG. Paradoxical improvement of impulse conduction in cardiac tissue by partial cellular uncoupling. *Science* 1997;275:841–844.
- Schlüter M, Cappato R, Ouyang F, Antz M, Schlüter CA, Kuck KH. Clinical recurrences after successful accessory pathway ablation: the role of "dormant" accessory pathways. *J Cardiovasc Electrophysiol* 1997;8:1366–1372.
- Gemma L, Steinberg L, Prystowsky E, Padanilam B. Development of rapid preexcited ventricular response to atrial fibrillation in a patient with intermittent preexcitation. *J Cardiovasc Electrophysiol* 2013;24:347–350.
- Niwano S, Kitano Y, Moriguchi M, Izumi T. Transient appearance of antegrade conduction via an AV accessory pathway caused by atrial fibrillation in a patient with intermittent Wolff-Parkinson-White syndrome. *Heart* 2000;83:E8.