



Contents lists available at ScienceDirect

International Journal of Surgery Case Reports

journal homepage: www.casereports.com

Case report of the use of videolaryngoscopy in thyroid goiter masses: An airway challenge



Stacey Watt (M.D.) (Associate Professor)^{a,*}, Jonathan Kalpan (M.D.)^b, Venkatesware Kolli (M.D.) (Chief of Surgery)^c

^a University at Buffalo, Women and Children's Hospital of Buffalo, Department of Anesthesia, 219 Bryant Street, Buffalo, N.Y., 14222, United States

^b University at Buffalo, Anesthesiology Resident, United States

^c Niagara Falls Memorial Medical Center, United States

ARTICLE INFO

Article history:

Received 29 January 2016

Received in revised form 12 June 2016

Accepted 12 June 2016

Available online 5 August 2016

Keywords:

Thyroid

Airway

Obstruction

Difficult Airway

Glidescope

Thyroid mass

ABSTRACT

INTRODUCTION: The use of videolaryngoscopy continues to play a larger role in the approach to patients with airway pathology. Looking specifically at patients with potential difficulty in ventilation and intubation due to thyroid goiter, video laryngoscopy may provide a faster and easier technique to secure the airway compared to direct laryngoscopy.

PRESENTATION OF CASE: In the case we will present to you, a 60-year-old female with a large goiter presented to a community hospital emergency room where she was found to be in respiratory distress with increased work of breathing. Urgent subtotal thyroidectomy was planned. The patient was intubated using a Glidescope technique and the airway was secured in a safe and timely fashion.

DISCUSSION/CONCLUSION: A literature review of PubMed and Web of Science of the use of videolaryngoscopy in goiter, difficult airway, and airway obstruction yielded information supporting the use of the video laryngoscopy as a first choice for laryngoscopy with a proven benefit over direct laryngoscopy.

© 2016 The Author(s). Published by Elsevier Ltd on behalf of IJS Publishing Group Ltd. This is an open access article under the CC BY-NC-ND license (<http://creativecommons.org/licenses/by-nc-nd/4.0/>).

1. Introduction

The utilization of videolaryngoscopy in operating room cases involving difficult airways has become common place. Operating room cases involving the removal of goiters falls within this difficult airway case classification. Goiters often involve a number of anatomical locations and result in many implications to the airway and vascular structures. This can lead to upper and lower airway obstruction, laryngeal malacia, and lymphatic and vascular congestion causing edema that will further compromise the patient's airway. In patients with identified difficult airways we recommend the utilization of videolaryngoscopy to secure the airway due to the ability of this technique to be faster, easier and cause less trauma.

2. Presentation of case

A 60-year-old African American female presented to the emergency department with hoarseness, dysphasia, choking episodes, and swelling of the face and eyes. On review of systems the patient complained of snoring, dyspnea, wheezing, palpitations, and lower extremity edema. Her past medical history includes thyroid goi-

ter, asthma, and obstructive sleep apnea. She is a current smoker of tobacco and cocaine. Home medications include Ipratropium-albuterol 0.5–2.5 mg/3 mL solution four times per day, Ventolin HFA 108 (90base) mcg/ACT aerosol solution 2 puffs q 4 h PRN, Singulair 10 mg PO q HS, nicotine patch 12 mg/24 h 1 patch to skin once a day, Vitamin D 5000 IU twice per week, Tylenol 500 mg 1 capsule PO q 6 h PRN.

Computed tomography of the neck with IV contrast revealed a massive diffuse enlargement of the thyroid gland with numerous additional nodules (Figs. 1 and 2). The right lobe measures 6.5 × 7.5 cm × 9.1 cm. The left lobe measures 10 × 8.1 × 9.2 cm. The thyroid isthmus measures approximately 6.3 × 6.6 × 4.0 cm. There is some mild narrowing of the airway along the lower aspect of the thyroid. There is symmetry throughout the oropharynx. There is no significant adenopathy. Vascular structures are intact. The surgeon had moved her status from elective to urgent upon seeing her the morning of surgery in pre-operative holding. Vital signs were: Blood Pressure = 130/80,

HR = 80, RR = 18, T = 98.6 F, SaO₂ = 94%. Physical exam revealed a H = 5'4", W = 193 lbs., Body Mass Index = 33.12, obese female with a massive goiter and gross tracheal deviation to the right. The patient was transported to the operating room. After head up, ramped positioning on the operating room table she was premedicated with midazolam 2 mg IV and 0.2 mg of glycopyrrolate. The airway was topicalized with aerosolized benzocaine. After pre-oxygenation, 100 mcg of IV fentanyl was administered and a preliminary awake

* Corresponding author.

E-mail addresses: staceywattmd@yahoo.com, swatt@kaleidahealth.org (S. Watt), jskaplan2@gmail.com (J. Kalpan), venkatkolli@aol.com (V. Kolli).

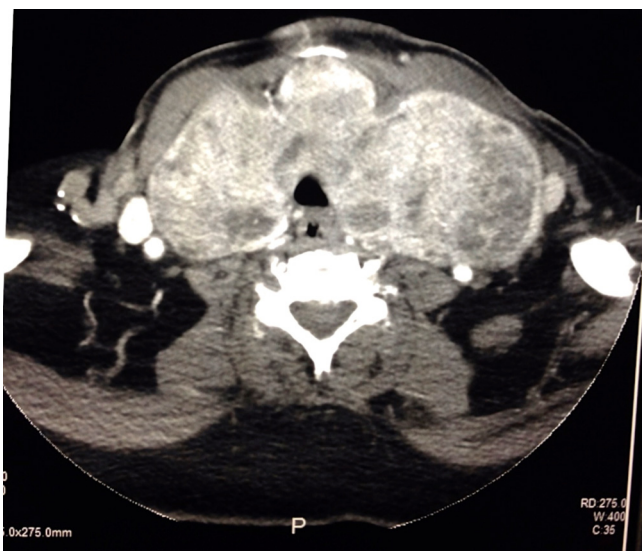


Fig. 1. Transverse CT image.

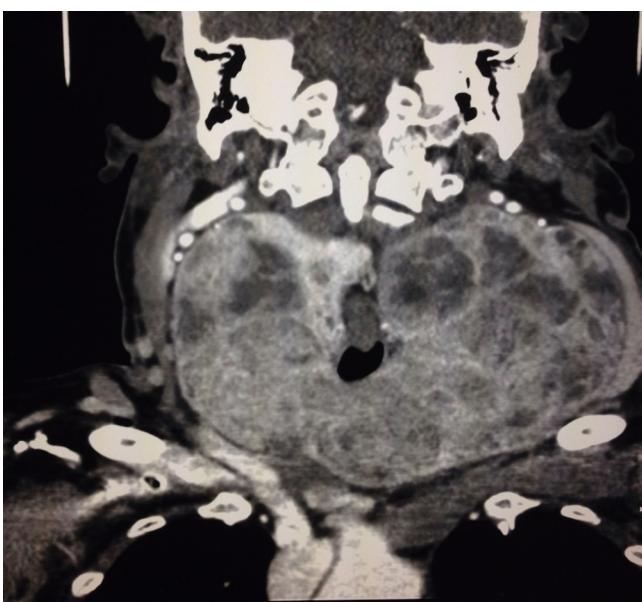


Fig. 2. Coronal CT image.

laryngoscopy with the Glidescope was attempted to determine if this technique would provide an adequate laryngeal view for instrumentation. The vocal cords were visualized and after additional pre-oxygenation intubation proceeded using lidocaine 50 mg, propofol bolus 150 mg, and succinylcholine 200 mg. The Glidescope view on intubation revealed a Cormack-Lehane grade 1 view of laryngeal aperture. A 7.5 internal diameter armored tube was unable to be passed through the cords. Two-provider ventilation was established and the patient was ventilated easily. The Glidescope was again used to pass a 7.0 internal diameter endotracheal tube easily through the glottis to secure airway. The surgery successfully removed the mass and the patient did well in the perioperative period (Fig. 3).

3. Discussion

The use of videolaryngoscopy in patients presenting with airway pathology including, but not limited to a goiter should be carefully considered as a first line tool over direct laryngoscopy.

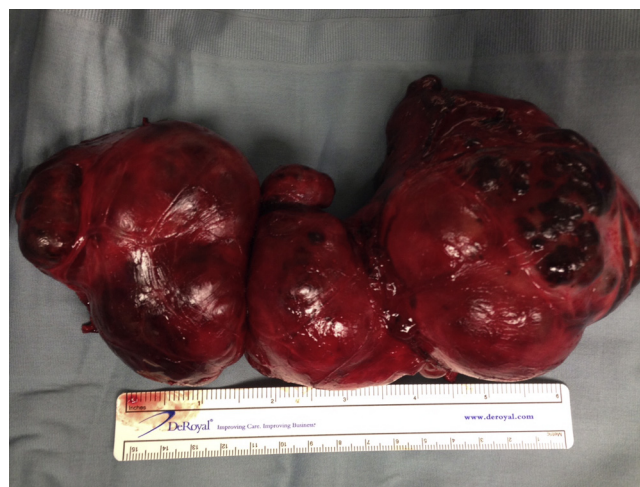


Fig. 3. Pathology Image.

This patient population benefits from thorough pre-operative evaluation, as there are a number of risk factors specific to patients with goiters that predict difficult intubation and ventilation due to upper airway obstruction. It is in the best interest of the patient for the anesthesiologist to intubate quickly to avoid prolonged obstruction, minimize trauma and avoidance of difficult to intubate circumstances. These goals are more likely to be achieved with videolaryngoscopy over direct laryngoscopy.

Several authors have described risk factors for difficult intubation in patients with goiters. Independent risk factors identified are older age, Cormack-Lehane grade 3 or 4, cancerous goiters, tracheal stenosis on imaging, increased neck circumference, decreased mouth opening, larger goiters, and pathological changes in airway anatomy [1–4]. These identifiable factors should alert the Anesthesiologist that the patient may be difficult to intubate and therefore, direct laryngoscopy may be insufficient in securing the airway. Other authors have found only traditional difficult to intubate risk factors in the thyroid pathology group and dismiss these goiter-specific risk factors [5]. Despite these differing findings, the video laryngoscope has been shown to be more useful than direct laryngoscopy in patients with risk factors for difficult intubation. Specifically, there is decreased time of intubation attempts, fewer repositioning maneuvers, and it provides better visualization of the glottis [6].

A study of flow-volume loops in patients with goiters determined that upper airway obstruction in this patient subset might not be appreciated, as patients are often asymptomatic [7]. This should prompt the Anesthesiologist to consider the duration of intubation as the patient's airway may be further obstructed after induction medications are administered. The time to intubate patients undergoing thyroid surgery has been shown to be less with a video laryngoscope than with a direct laryngoscope and also decreased scores on the Intubation Difficulty Scale (IDS) [8].

Voyagis et Al. looked at 4742 consecutive patients undergoing general anesthesia. This research found that there is increased risk of difficult intubation in patients with goiters compared to the general population without risk factors for difficult intubation [4]. It has also been shown that IDS scores are higher in patients with goiters [2]. However, other authors refute any difficulty in intubating patients with goiters compared to the general population [9]. Bensghir et al. conducted a prospective study of 105 patients presenting for thyroid surgery and compared direct laryngoscopy to the Airtraq and X-Lite devices while excluding patients with difficult intubation risk factors. Regardless of the presentation of difficult to intubate incidence among patients with goiters, patients

with goiters were shown to have a lower IDS scores when a video-laryngoscope was used compared to direct laryngoscopy as well as lower Cormack-Lehane scores [8]. In the general population, the Glidescope has shown to improve glottic view and decrease intubation attempts as well as time to securing the airway [10–12].

Griesdale et al. performed a meta-analysis comparing the Glidescope to direct laryngoscopy. Although there was improved first attempt success and decreased time to intubation for inexperienced users with the Glidescope, experts showed no such difference. There was however an important finding that the Glidescope was associated with improved glottic visualization especially in patients with potential or simulated difficult airways. In patients with difficult airways, videolaryngoscopy was more effective in providing visualization of the glottis [13]. Another meta-analysis was concurrently performed by Lu et al. which also supported the notion that videolaryngoscopy provided a more rapid and accurate intubation particularly by novices and difficult airways when compared to direct laryngoscopy [14].

Many patients with a goiter will present for the purpose of thyroidectomy. The use of a neural integrity monitor (NIM) endotracheal tube in this procedure has decreased morbidity related to the recurrent laryngeal nerve. It is imperative that correct placement of a NIM tube be confirmed for optimal use. The video laryngoscope provides gentle and more accurate placement of the NIM tube [15,16]. An additional benefit of using videolaryngoscopy is that confirmation of correct NIM tube placement can be confirmed by the surgeon in addition to the anesthesiologist, providing greater confidence of correct placement by all OR personnel.

4. Conclusion

The anesthesiologist has many techniques to choose from when confronted with goiter. In comparison to direct laryngoscopy, video laryngoscopy has shown a benefit in terms of ease of use, time to intubate, first attempt success, lower Cormack-Lehane scores, and lower IDS both in patients undergoing thyroidectomy and patients with difficult intubation risk factors. Its use should be considered as a first line tool to intubate these patients.

Goiters can extend to a number of anatomical locations with many implications on airway and vascular structures. This can lead to upper and lower airway obstruction, malacia, and lymphatic and vascular congestion causing edema. The implications can cause various problems in securing the airway and therefore further study is warranted for reliable techniques in these similar but distinct circumstances.

Conflicts of interest

None.

Funding

None.

Ethical approval

Patient gave approval for use of images and case information.

Author contribution

Dr. Stacey Watt – writing. Dr. Jonathan Kaplan – writing. Dr. Venkatesware Kolli – writing.

Guarantor

Dr. Stacey Watt. Dr. Venkatesware Kolli.

References

- [1] Abderrahmane Bouaggad, Sif Eddine Nejmi, Moulay Ahmed Bouderkha, O. Abbassi, Prediction of difficult tracheal intubation in thyroid surgery, *Anesth. Analg.* (2004) 603–606 (Web).
- [2] J. Mallat, E. Robin, A. Pironkov, G. Lebuffe, B. Tavernier, Goitre and difficulty of tracheal intubation, *Annales Françaises D'Anesthésie Et De Réanimation* 29 (6) (2010) 436–439 (Web).
- [3] A.F. Khan, Mohammad Nasir Ayub Rabbani, Mohammad Zafar Qureshi, Rashid Zubair, Muhammad Zafar, Muhammad Jawad, Predictors of difficult tracheal intubations In patients undergoing thyroid surgery for euthyroid goitre, *J. Pak. Med. Assoc.* 60 (9) (2010) 736–738 (Web).
- [4] S. Voyagis Gregory, P. Kyriakos Kyriakis, The effect of goiter on endotracheal intubation, *Anesth. Analg.* 84 (3) (1997) 611–612 (Web).
- [5] R. Amathieu, N. Smail, J. Catineau, M.P. Poloujadoff, K. Samii, H. Adnet, Difficult intubation in thyroid surgery: myth or reality? *Anesth. Analg.* 103 (4) (2006) 965–968 (Web).
- [6] C.H. Maharaj, J.F. Costello, B.H. Harte, J.G. Laffey, Evaluation of the Airtraq® and macintosh laryngoscopes in patients at increased risk for difficult tracheal intubation*, *Anaesthesia* 63 (2) (2008) 182–188 (Web).
- [7] T.K. Thusoo, U. Gupta, K. Kochhar, H.S. Hira, Upper airway obstruction in patients with goiter studied by flow volume loops and effect of thyroidectomy, *World J. Surg.* 24 (12) (2000) 1570–1572 (Web).
- [8] A.U. Benschir, C. Chouikh, N. Bouhabba, S. Fjjouji, J. Kasouati, H. Azendour, Comparison between the airtraq, X-Lite, and direct laryngoscopes for thyroid surgery: a randomized clinical trial, *Can. J. Anesth.* 60 (4) (2013) 377–384 (Print).
- [9] P.A. Loftus, T.J. Ow, B. Siegel, A.B. Tassler, R.V. Smith, H.W. Cohen, B.A. Schiff, Risk factors for perioperative airway difficulty and evaluation of intubation approaches among patients with benign goiter, *Ann. Otol. Rhinol. Laryngol.* 123 (4) (2014) 279–285 (Web).
- [10] Richard M. Cooper, John A. Pacey, Michael J. Bishop, Stuart A. McCluskey, Early Clinical Experience with a New Videolaryngoscope (Glidescope®) in 728 Patients, *Can. J. Anesth.* 52 (2) (2005) 191–198 (Web).
- [11] Richard M. Cooper, Use of a new videolaryngoscope (Glidescope®) in the management of a difficult airway, *Can. J. Anesth.* 50 (6) (2003) 611–613 (Web).
- [12] Sofia M. Khan, Richard M. Cooper, Superior glottic views with the Glidescope® and Airtraq® laryngoscopes compared with an anterior commissure laryngoscope, *Can. J. Anesth.* 58 (2) (2010) 224–225 (Web).
- [13] E.G. Griesdale Donald, David Liu, James Mckinney, T. Peter Choi, Glidescope® video-laryngoscopy versus direct laryngoscopy for endotracheal intubation: a systematic review and meta-analysis, *Can. J. Anesth.* 59 (1) (2011) 41–52 (Web).
- [14] Y. Lu, H. Jiang, Y.S. Zhu, Airtraq laryngoscope versus conventional macintosh laryngoscope: a systematic review and meta-analysis, *Anaesthesia* 66 (12) (2011) 1160–1167 (Web).
- [15] S.P. Kanotra, D.B. Kuriloff, J. Lesser, F. Rest-Flarer, Glidescope- assisted nerve integrity monitoring tube placement for intra-operative recurrent laryngeal nerve monitoring, *J. Laryngol. Otol.* 126 (12) (2012) 1271–1273 (Web).
- [16] Lauren Berkow, Alan P. Dackiw, Ralph P. Tufano, Use of the glidescope for placement of a recurrent laryngeal nerve monitoring endotracheal tube, *J. Clin. Anesth.* 23 (1) (2011) 81–83 (Web).

Open Access

This article is published Open Access at sciendo.com. It is distributed under the [IJSCR Supplemental terms and conditions](#), which permits unrestricted non commercial use, distribution, and reproduction in any medium, provided the original authors and source are credited.