



# Sinuvertebral nerve block treats discogenic low back pain: a retrospective cohort study

Ze Zheng Liu<sup>#</sup>, Runxun Ma<sup>#</sup>, Chaohui Fan<sup>#</sup>, Junjie Chen, Rusen Zhang, Zhiyang Zheng, Yejie Xu, Zexian Liu, Qinghao Zhao, Qingchu Li

Department of Orthopedics, The Third Affiliated Hospital of Southern Medical University, Guangzhou, China

**Contributions:** (I) Conception and design: Q Zhao, Q Li; (II) Administrative support: Q Li; (III) Provision of study materials or patients: Z Liu; (IV) Collection and assembly of data: Z Liu, Q Li; (V) Data analysis and interpretation: Z Liu, R Ma, C Fan; (VI) Manuscript writing: All authors; (VII) Final approval of manuscript: All authors.

<sup>#</sup>These authors contributed equally to this work and are co-first authors.

**Correspondence to:** Qinghao Zhao, PhD; Qingchu Li, PhD. Department of Orthopedics, The Third Affiliated Hospital of Southern Medical University, No. 183, Zhongshan Rd West, Guangzhou 510630, China. Email: qinghao.z@foxmail.com; liqingchu12@qq.com.

**Background:** Discogenic low back pain (DLBP) is considered the most common type of chronic low back pain (CLBP). Sinuvertebral nerve block (SVNB) is a rapid and precise intervention performed under local anesthesia to treat DLBP induced CLBP. Thus, in this study, we aimed to explore the clinical efficacy of SVNB for DLBP.

**Methods:** We retrospectively included 32 DLBP patients from July 2020 and April 2021. Inclusion criteria: The patients had chronic pain, diagnosed as single-segment disc degeneration induced DLBP, and suffered from one-year ineffective conservative treatment. SVNB was performed and the patients were followed up at 3 and 7 days, and at 1 and 3 months after SVNB. The basic clinical characteristics, including age and gender, were collected. The measurements of Visual Analogue Scale (VAS) and Oswestry Disability Index (ODI) were assessed.

**Results:** The average age was  $49.31 \pm 14.37$  years, and females *vs.* males was 20 (62.50%) *vs.* 12 (37.50%). The preoperative VAS and ODI score were  $5.75 \pm 1.41$  and  $32.59 \pm 21.56$ , respectively. The VAS score was reduced to  $2.50 \pm 1.46$ ,  $2.63 \pm 1.60$ ,  $3.53 \pm 2.17$ , and  $3.78 \pm 2.18$  at 3 and 7 days, and 1 and 3 months after SVNB, respectively ( $P < 0.05$ ). The improvement rates in the VAS score were 56.52%, 54.34%, 38.61%, and 34.26% at 3 and 7 days, and 1 and 3 months after SVNB, respectively. 18 patients (56.25%) experienced varying degrees of pain recurrence within 3 months. The ODI score was reduced by  $17.28 \pm 13.06$ ,  $16.84 \pm 13.51$ ,  $19.63 \pm 17.12$ , and  $21.44 \pm 19.03$  points at 3, 7 days and 1, 3 months after SVNB, respectively ( $P < 0.05$ ). At 3 day and 3 month after SVNB, the ODI scores of 22 patients (68.75%) and 20 patients (62.50%) decreased to  $\leq 20$ , respectively. The ODI improvement rates were 46.98%, 48.33%, 39.80%, and 34.24% at 3, 7 days and 1, 3 months after SVNB, respectively.

**Conclusions:** We conducted a retrospective study of the clinical efficacy of SVNB for DLBP. As a rapid and cost-effective minimally invasive treatment, SVNB provided some assistance for the short-term pain relief and physical functional improvement of DLBP. SVNB could be a good choice for the treatment of DLBP.

**Keywords:** Intervertebral disc; discogenic low back pain (DLBP); sinuvertebral nerves (SVNs); nerve block

Submitted Oct 11, 2022. Accepted for publication Nov 15, 2022.

doi: 10.21037/atm-22-5297

View this article at: <https://dx.doi.org/10.21037/atm-22-5297>

## Introduction

Chronic low back pain (CLBP) is the most common cause of discomfort in daily life and affects approximately 632 million people (1,2). It has become a serious medical and social problem due to the increasing aging population (3). CLBP causes chronic symptoms in patients that result in serious pain. Discogenic low back pain (DLBP) is considered the most common type of CLBP (4,5). The lumbar sinuvertebral nerve (SVN) is the main nerve associated with lumbar disc pain signal transduction and is mainly distributed in the vertebral body, intervertebral disc, posterior longitudinal ligament, and ventral dural sac (5-8).

For DLBP patients in whom conservative treatment is ineffective, subsequent treatment includes spinal fusion and minimally invasive surgery (9). Traditional fusion surgery generally results in low patient satisfaction due to extensive trauma (9,10). Based on the pain mechanism of DLBP, minimally invasive surgery, such as percutaneous endoscopic discectomy and radiofrequency thermoplasty, is increasingly being applied (11,12). Kim *et al.* (13) believed that basivertebral nerve and SVN play an important role in the pain conduction pathway of vertebral disk low back pain, and spinal endoscopic radiofrequency ablation of both basivertebral nerve and sinuvertebral nerve was performed in 30 patients with DLBP, and excellent outcomes were showed in these patients. However, 16.5–26.5% of patients still experience poor postoperative outcomes, especially in the medium and long-term (14).

Sinuvertebral nerve block (SVNB) is a procedure that can be used as a diagnostic and therapeutic tool for lumbar diseases. Schliessbach reported the sensitivity is 73% (5,15). Anesthetics are usually injected into the intervertebral foramen under fluoroscopy (6,7). Based on theoretical

SVN conduction studies, the use of SVNB can reduce pain in patients with DLBP. The pain-blocking mechanism of SVNB is similar to intradiscal anesthetics injection (7). Yeom *et al.* (16) found only moderate accuracy for diagnostic lumbar selective nerve root blocks. However, previous anatomical study by our team revealed the characteristics of the anatomical distribution of the SVN (17). However, not all patients are sensitive to SVNB treatment. There are some reasons: (I) ramus communicans griseus conducted pain signal; (II) the pain sensing nerve is destroyed during the disc rupture; (III) false-positive of diskography. Thus, accurate and effective SNVB is very important for the treatment of DLBP (15). This current investigation aimed to accurately block the SVN to evaluate the efficacy of SVNB based on our previous observations of the anatomical characteristics of the SVN. We present the following article in accordance with the STROBE reporting checklist (available at <https://atm.amegroups.com/article/view/10.21037/atm-22-5297/rc>).

## Methods

This was a single centre retrospective cohort study. The data of 32 patients who underwent SVNB at the Third Affiliated Hospital of Southern Medical University, between July 2020 and April 2021 were collated. The study was conducted in accordance with the Declaration of Helsinki (as revised in 2013). The study was approved by ethics board of Third Affiliated Hospital of Southern Medical University (No. 2021027). Individual consent for this retrospective analysis was waived.

## Patients

Patients were included in this study if they presented with the following: (I) chronic pain (symptoms that persisted for more than 6 months); (II) DLBP with clinical symptoms (pain with increased abdominal pressure, or when sedentary, lift heavy objects, difficulty maintain the same position, or alleviation of pain upon lying flat); (III) low efficacy of conservative treatment after one year; (IV) magnetic resonance imaging (MRI) showed single-segment disc degeneration, with or without annulus fibrosus tears (*Figure 1*); and (V) an understanding of the situation and acceptance of the treatment plan. Patients with associated lower extremity pain, spinal stenosis, lumbar instability, lumbar spondylolisthesis, lumbar compression fracture, tumors, spinal infection, or a history of other spinal

### Highlight box

#### Key findings

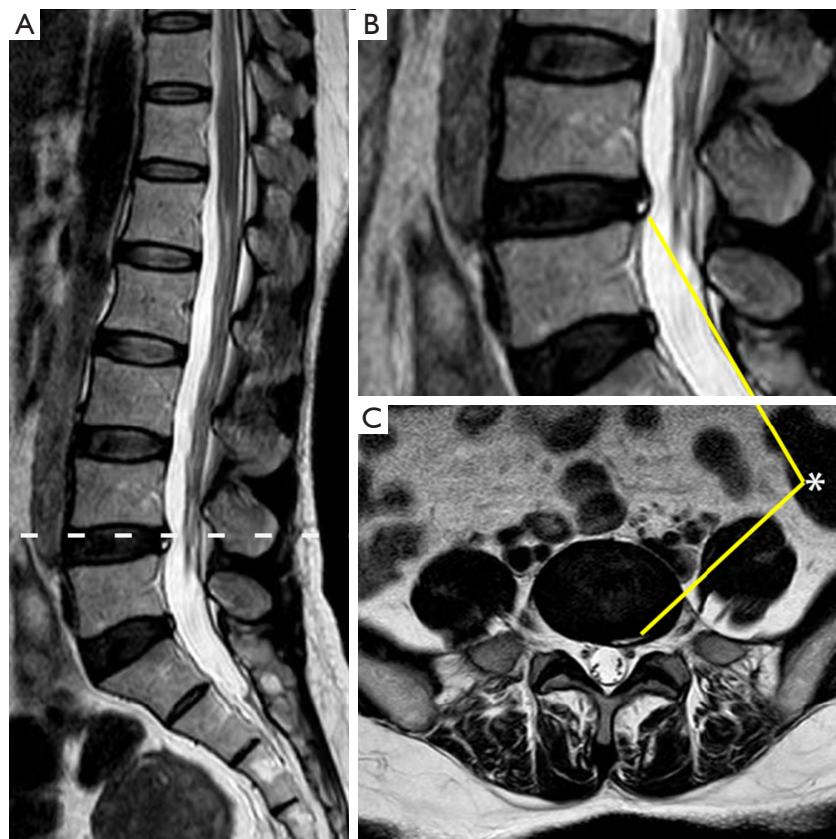
- Sinuvertebral nerve block is effective for discogenic low back pain (DLBP).

#### What is known and what is new?

- DLBP is considered the most common type of chronic low back pain (CLBP).
- As a rapid and cost-effective minimally invasive treatment, SVNB provided some.

#### What is the implication, and what should change now?

- SVNB could be a good choice for the treatment of DLBP.



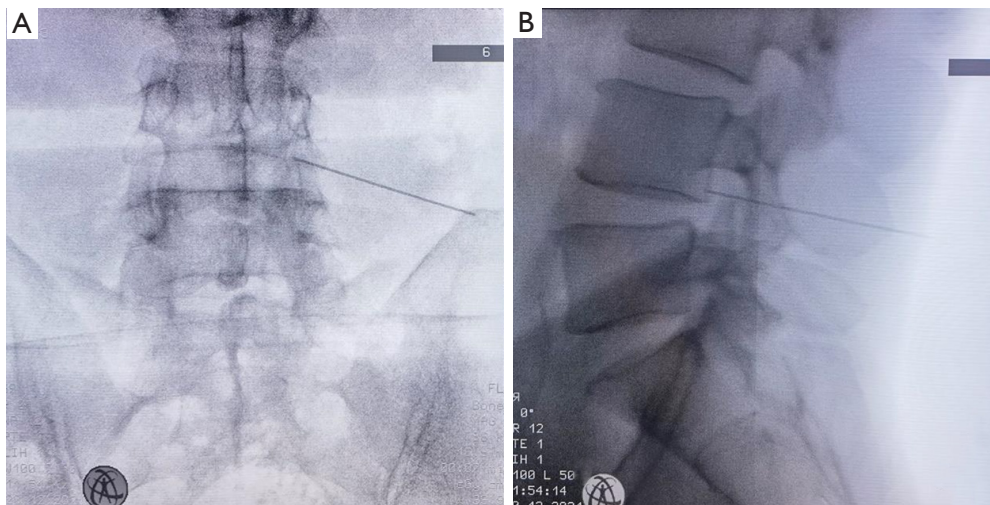
**Figure 1** A magnetic resonance image of a L4/5 disc annulus fibrosus tear. (A,B) Lumbar-spine MRI, sagittal. (C) Lumbar-spine MRI, transverse L4/5 disc degeneration with annular tear, no spinal stenosis nor disc herniation. \*, torn annulus fibrosus. MRI, magnetic resonance imaging.

surgery were excluded. All patients with a history of other significant surgeries or who were unable to cooperate with the study were excluded. All patients received telephone followed up for 3 months. The Visual Analogue Scale (VAS) and Oswestry Disability Index (ODI) value were recorded. Finally, a total of 32 patients satisfied the inclusion and exclusion criteria. All 32 patients were followed up after SVN. The average age was  $49.31 \pm 14.37$  years, and there were 20 (62.50%) females and 12 (37.50%) males.

### Operation procedure

All patients were fully informed about the procedure and signed the consent form before undergoing SVN. The patient was placed in the prone position, with a soft pillow on the chest and iliac spine. The abdomen was suspended, and the hips and knees were slightly flexed. The operating table was adjusted to ensure that the lumbar spine was properly flexed. The body surface projections of the pedicle,

spinous process, lateral edge of the lamina, and upper edge of the intervertebral space were located on both sides of the responsible segment with the aid of the C-arm fluoroscopy. A longitudinal line (line B) was marked 6–8 cm next to the spinous process. The intersection of the line marked on the upper edge of the vertebral body and the line B was determined to be the needle insertion point. Routine disinfection with iodine tincture and alcohol disinfection were performed, followed by sterile draping towel sheets. Under C-arm fluoroscopic guidance, the needle tip of the syringe needle (26G) was inserted at the puncture point (anteroposterior X-ray view: the intersection of the line connecting the posterolateral upper margin of the disc and the line connecting the adjacent pedicles; lateral X-ray view: posterior edge of the vertebral body). As the puncture point is close to the nerve root, some patients may experience radiating pain in the lower limbs during the puncture process due to the needle tip touching the nerve root. This is because the needle tip touches the nerve



**Figure 2** The position of the puncture needle during X-ray-guided nerve block. (A) The lumbar-spine anteroposterior view, and (B) the lumbar-spine lateral view. The needle was inserted through the foraminal approach, and the intersection of the line connecting the posterolateral upper margin of the disc and the line connecting the adjacent pedicles was selected as the site of injection.

root. At this time, needle insertion should be stopped, and the puncture direction should be adjusted until the needle tip is punctured in the correct position. After injection of 0.3 mL lidocaine solution (0.66%) into the puncture site, the needle was pulled out. The patients were allowed to move immediately after the procedure without bed rest (Figure 2).

### Statistical analysis

The level of pain severity was assessed prospectively at 5 time points, namely, before intervention, on the 3 and 7 days, and on the 1 and 3 months after SVN. The VAS score, the ODI, the responsible segment of the lumbar spine, and the improvement of symptoms were recorded. The SPSS 20.0 software was used to analyze the recorded measurements. The relevant data were expressed as " $\bar{x} \pm s$ ". Continuous data were analyzed by paired *t*-test, and statistical significance was defined at  $\alpha < 0.05$  two-side. The VAS score improvement rate = (preoperative score – follow-up score)/preoperative score  $\times$  100%; and the ODI improvement rate = (preoperative score – follow-up score)/preoperative score  $\times$  100%.

### Results

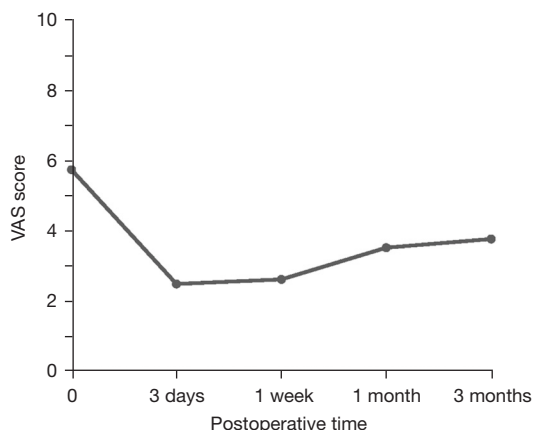
In this study, no pain recurrence within 3 days after the

procedure was considered a positive result of the SVN test, while pain recurrence or ineffectiveness within 3 days after the procedure was considered a negative result. A total of 24 (75.00%) patients had no pain recurrence within 3 days after the procedure, namely, a positive result. Meanwhile, 8 patients (25.00%) experienced pain recurrence or no pain relief within 3 days after the procedure, namely a negative result. Among the negative cases, the procedure was completely ineffective in 5 patients (15.63%), and pain recurrence occurred within 3 days after the operation in 3 cases (9.38%).

### The visual analogue scale

The most treated segment was L4/5 (17 cases, 53.1%), followed by L5/S1 (10 cases, 31.3%), L3/4 (4 cases, 12.5%), and L2/3 (1 case, 3.1%). The average preoperative VAS score of the 32 patients was  $5.75 \pm 1.41$  points. This was significantly different from the postoperative VAS scores of  $2.50 \pm 1.46$  points at 3 days after SVN,  $2.63 \pm 1.60$  points at 7 days after SVN,  $3.53 \pm 2.17$  points at 1 month after SVN, and  $3.78 \pm 2.18$  points at 3 months after SVN ( $P < 0.001$ ; Figure 3; Table 1). From 3 days to 3 months after SVN, the patients' symptoms significantly improved, with VAS score improvement rates of 56.52%, 54.34%, 38.61%, and 34.26%, respectively.

Among the 27 patients in whom the procedure was



**Figure 3** The trend in the VAS score before and after SVN. VAS, Visual Analogue Scale (0–10); SVN, sinuvertebral nerve block.

**Table 1** A comparison of the VAS score before SVN, and at 3 days, 1 week, 1 month, and 3 months after SVN in 32 patients

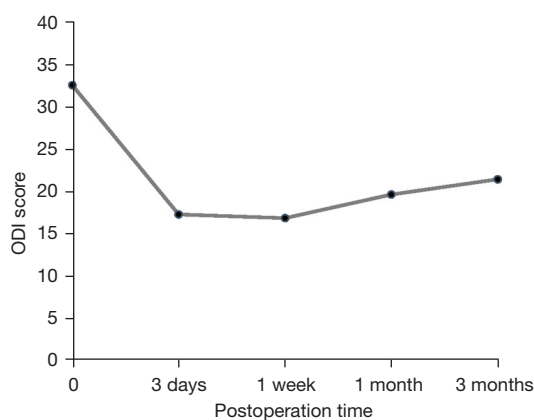
Time	VAS score (mean ± SD)	P value <sup>a,b</sup>
Preoperative	5.75±1.41	–
Postoperative		
3 days	2.50±1.46	<0.001
1 week	2.63±1.60	<0.001
1 month	3.53±2.17	<0.001
3 months	3.78±2.18	<0.001

<sup>a</sup>, P value compares preoperative and postoperative VAS score;

<sup>b</sup>, *t*-test to compare means. VAS, Visual Analogue Scale (0–10); SVN, sinuvertebral nerve block.

effective on the same day after SVN, 24 patients (88.89%) had no recurrence within 3 days after SVN, and only 3 patients (11.11%) experienced various degrees of pain recurrence within 3 days after SVN. The VAS score of 13 patients (40.63%) decreased to  $\leq 2$  points at 3 days after SVN, and 3 patients (9.38%) experienced no pain. The maximum score decreased by 6 points (1 case), the minimum decreased by 0 points (4 cases), and the mean decreased was  $3.25 \pm 1.72$  points.

Of the 32 patients, 14 (43.75%) had long-term pain relief after SVN, with no recurrence within the following 3 months. A total of 18 patients (56.25%) experienced varying degrees of pain recurrence within 3 months. Regarding follow-up treatment, 11 of the 18 patients underwent a secondary block procedure or conservative



**Figure 4** The trend in the ODI score before and after SVN. ODI, Oswestry Disability Index (0–100%); SVN, sinuvertebral nerve block.

**Table 2** A comparison of the ODI score before SVN, and at 3 days, 1 week, 1 month, and 3 months after SVN in 32 patients

Time	ODI score (mean ± SD)	P value <sup>a,b</sup>
Preoperative	32.59±21.56	–
Postoperative		
3 days	17.28±13.06	<0.001
1 week	16.84±13.51	<0.001
1 month	19.63±17.12	<0.001
3 months	21.44±19.03	<0.01

<sup>a</sup>, P value compares preoperative and postoperative ODI score;

<sup>b</sup>, *t*-test to compare means. ODI, Oswestry Disability Index (0–100%); SVN, sinuvertebral nerve block.

treatment with further improvement in symptoms, and 7 underwent surgery. A total of 25 patients (78.13%) did not require surgery.

### The ODI

The average ODI score of the 32 patients was  $32.59 \pm 21.56$  before SVN,  $17.28 \pm 13.06$  at 3 days after SVN,  $16.84 \pm 13.51$  at 7 days after SVN,  $19.63 \pm 17.12$  at 1 month after SVN, and  $21.44 \pm 19.03$  at 3 months after SVN, with statistically significant differences ( $P < 0.01$ ; *Figure 4*; *Table 2*). Three days after SVN, the ODI scores of 22 patients (68.75%) decreased to  $\leq 20$ , with an average decrease of  $15.31 \pm 17.07$ . At 3 months after SVN, the ODI

scores of 20 patients (62.50%) decreased to  $\leq 20$ , with a mean decreased of  $11.16 \pm 18.91$ . From 3 days to 3 months after SVN, the patients' symptoms significantly improved, with ODI score improvement rates of 46.98%, 48.33%, 39.80%, and 34.24% respectively.

## Discussion

DLBP is a difficult problem for clinicians to diagnose and treat because of its extremely complex pathological mechanisms and atypical clinical manifestations (11). Although X-ray imaging can help exclude certain diseases, such as lumbar spondylosis and spinal stenosis, it shows no specificity nor sensitivity for DLBP (18,19). High-intensity zones, modic changes, and black discs are characteristic features of DLBP on MRI but may also be seen in people without DLBP. Thus, the use of MRI to diagnose DLBP is associated with a high false-positive rate (20). Discography, as an invasive operation, had previously been considered the gold standard for diagnosing DLBP owing to the pain replication effect (21). However, its feasibility has been questioned and widely rejected because of the high rate of false-positive results and it remains unclear whether it can be used in patients with mild or no symptoms (22). Holt (23) reported that the false-positive rate of discography was 26% in asymptomatic people. Carragee *et al.* (24) found that the diagnostic specificity of discography was only 50–60% by performing interbody fusion for patients with positive discography findings. Schliessbach *et al.* (15) speculated that nerve block might be an effective method for the diagnosis of DLBP. Therefore, these results of current retrospective study could indicate the effectiveness of SVN in the diagnosis of DLBP.

Study has shown that the lumbar SVN is the main nerve involved in lumbar disc pain signal transduction (5). The lumbar SVN has a sympathetic nerve component and transmits the pain impulses from the sympathetic trunk to the lumbar medullary spinal nerve ganglion, the lumbar sympathetic ganglion, the T12-L3 segment sympathetic ganglion, and finally the pain center to complete the reflex arc of the incoming path (6,7,15). Therefore, DLBP is related to the SVN and blocking the conduction of SVN with drugs can help diagnose patients with DLBP (16,25).

Schliessbach *et al.* (15) diagnosed DLBP by administering nerve block between the medial facet of the articular process and the dural sac. Pain was relieved in 80% of patients, with

a diagnostic sensitivity of 73%, but only a 40% specificity. The procedure was also associated with frequent contact with nerve roots. Our previous study found that the lumbar SVN originates from the ventral ganglion and the origin of the gray communicating branch. In addition, the initial portion of the SVN is located along the intersection of the line connecting the posterolateral upper margin of the disc and the line connecting the adjacent pedicles (17). Considering the downward infiltration of the drug, the area of the initial portion of the SVN was used as the target for injection in this study.

Of the 32 patients enrolled in this study, 24 (75.00%) were shown to be positive for the SVN test. False negatives may be caused by an inadequate anesthetic dose or concentration, inaccurate block localization, and differences in patient's subjective pain. Although the positive rate of SVN is still not ideal, its unique advantages, such as low cost, low risk of side effects, and combined diagnostic and therapeutic effect, make it a viable option in the diagnosis of DLBP.

Current treatments for DLBP include conservative treatment, minimally invasive surgery, and open surgery (9). Bydon *et al.* (26) believed that patients with DLBP should first receive conservative treatment for at least 6 months; however, the procedure for long-term maintenance remains uncertain. Interbody fusion is the current gold standard for DLBP treatment (11). It eliminates pain receptors by removing the affected disc directly and reduces mechanical stress stimulation by immobilizing the segment (10). Vieli *et al.* (9) showed that while the current rate of interbody fusion is 89–95%, only 60–78% of patients are satisfied with the treatment. Minimally invasive surgery is widely applied owing to the controllable time, low risk, and little to no damage to physiological structures (11,12). Currently, the main methods of minimally invasive surgical treatment include intradermal methylene blue therapy, radiofrequency nucleus pulposus ablation, and nerve block (27). Intradermal methylene blue therapy works by controlling local inflammatory factors and lowering pain thresholds. Guo *et al.* (28) found that the long-term efficacy of intradermal methylene blue therapy for patients with DLBP was poor. Radiofrequency ablation of the annulus fibrosus reduces pain by generating high-frequency radio waves to inactivate inflammatory pain-causing factors around the disc, but its efficacy is unknown because of iatrogenic injury to the intervertebral disc (29). Study has shown that SVN can alleviate pain in patients with LBP (15). However, the

effect has been reported to be unpredictable. Quinones *et al.* (30) found that The SVN had a recurrent course below the inferior vertebral notch and suggest blocking the SVN at the level of the inferior vertebral notch of two adjacent segments to obtain good therapeutic effect. Breemer *et al.* (31) believed that lower lumbar discogenic pain is presumably mediated segmentally via the somatic SVN root and non-segmentally through the autonomic SVN root; targeting only the non-segmental pathway may provide incomplete pain reduction. In theory, both the segmentally and non-segmentally pathways were blocked by selecting the initial part of the sinuvertebral nerve as the site of injection.

In our study, the VAS scores and ODI scores were improved on the 3rd day, 1 week, 1 month, and 3 months after SVN, and the decrease in the VAS score was most obvious on the 3rd day after SVN compared with that before SVN. Fourteen patients (43.75%) experienced long-term pain relief after SVN, with no recurrence within the following 3 months. The VAS improvement rates were 56.52%, 54.34%, 38.61%, and 34.26% respectively. Therefore, we believe that SVN is effective for early pain relief and functional improvement in patients with DLBP (within 3 months); however, its efficacy over the medium and long term remains unclear.

SVN is a rapid and precise intervention performed under local anesthesia. The procedure uses amide local anesthetics and steroids to selectively block the initial segment of the SVN and block the transmission of intervertebral disc pain signals. Its ultimate goal is to relieve pain over the long term, reduce unnecessary operations and the burden of disease. At the same time, as a diagnostic and therapeutic technique, SVN has certain clinical significance in the diagnosis and treatment of DLBP. Our study shows that 43.75% of patients achieved long-term remission, and 78.13% of patients temporarily avoided surgery. Therefore, SVN is a good first-line treatment. For suspected cases of DLBP, we believe that SVN can be used to assist in the diagnosis. There are several factors affect the treatment efficiency: (I) nerve root anomalies; (II) there are other causes of low back pain; (III) inaccurate block position (inaccurate puncture needle position); (IV) psychological factors; (V) pain threshold. If the diagnosis is clear, the pain relief is obvious, and the duration of relief is long, a secondary block procedure can be performed to enhance the efficacy and possibly avoid the need for surgery.

This study has some limitations. The main limitation is

the lack of additional data for clinical validation. Therefore, a large-sample, multicentered, and long-term follow-up study is warranted to provide a more sufficient basis for the application and promotion of SVN.

## Conclusions

This was a retrospective study of the diagnostic and clinical efficacy of SVN for DLBP. As a rapid and cost-effective minimally invasive treatment, SVN provided some assistance for the diagnosis, short-term pain relief, and physical functional improvement of DLBP.

## Acknowledgments

*Funding:* None.

## Footnote

*Reporting Checklist:* The authors have completed the STROBE reporting checklist. Available at <https://atm.amegroups.com/article/view/10.21037/atm-22-5297/rc>

*Data Sharing Statement:* Available at <https://atm.amegroups.com/article/view/10.21037/atm-22-5297/dss>

*Conflicts of Interest:* All authors have completed the ICMJE uniform disclosure form (available at <https://atm.amegroups.com/article/view/10.21037/atm-22-5297/coif>). The authors have no conflicts of interest to declare.

*Ethical Statement:* The authors are accountable for all aspects of the work in ensuring that questions related to the accuracy or integrity of any part of the work are appropriately investigated and resolved. The study was conducted in accordance with the Declaration of Helsinki (as revised in 2013). The study was approved by ethics board of Third Affiliated Hospital of Southern Medical University (No. 2021027). Individual consent for this retrospective analysis was waived.

*Open Access Statement:* This is an Open Access article distributed in accordance with the Creative Commons Attribution-NonCommercial-NoDerivs 4.0 International License (CC BY-NC-ND 4.0), which permits the non-commercial replication and distribution of the article with the strict proviso that no changes or edits are made and the original work is properly cited (including links to both the

formal publication through the relevant DOI and the license).  
See: <https://creativecommons.org/licenses/by-nc-nd/4.0/>.

## References

1. Mathew J, Singh SB, Garis S, et al. Backing up the stories: The psychological and social costs of chronic low-back pain. *Int J Spine Surg* 2013;7:e29-38.
2. Li Y, Pan D, Liu S, et al. Identification of circ-FAM169A sponges miR-583 involved in the regulation of intervertebral disc degeneration. *J Orthop Translat* 2021;26:121-31.
3. Shmagel A, Foley R, Ibrahim H. Epidemiology of Chronic Low Back Pain in US Adults: Data From the 2009-2010 National Health and Nutrition Examination Survey. *Arthritis Care Res (Hoboken)* 2016;68:1688-94.
4. Simon J, McAuliffe M, Shamim F, et al. Discogenic low back pain. *Phys Med Rehabil Clin N Am* 2014;25:305-17.
5. Raoul S, Faure A, Robert R, et al. Role of the sinuvertebral nerve in low back pain and anatomical basis of therapeutic implications. *Surg Radiol Anat* 2003;24:366-71.
6. Nakamura S, Takahashi K, Takahashi Y, et al. Origin of nerves supplying the posterior portion of lumbar intervertebral discs in rats. *Spine (Phila Pa 1976)* 1996;21:917-24.
7. Nakamura SI, Takahashi K, Takahashi Y, et al. The afferent pathways of discogenic low-back pain. Evaluation of L2 spinal nerve infiltration. *J Bone Joint Surg Br* 1996;78:606-12.
8. Ohtori S, Takahashi Y, Takahashi K, et al. Sensory innervation of the dorsal portion of the lumbar intervertebral disc in rats. *Spine (Phila Pa 1976)* 1999;24:2295-9.
9. Vieli M, Staartjes VE, Eversdijk HAJ, et al. Safety and Efficacy of Anterior Lumbar Interbody Fusion for Discogenic Chronic Low Back Pain in a Short-stay Setting: Data From a Prospective Registry. *Cureus* 2019;11:e5332.
10. Cheng JS, Lee MJ, Massicotte E, et al. Clinical guidelines and payer policies on fusion for the treatment of chronic low back pain. *Spine (Phila Pa 1976)* 2011;36:S144-63.
11. Fujii K, Yamazaki M, Kang JD, et al. Discogenic Back Pain: Literature Review of Definition, Diagnosis, and Treatment. *JBMR Plus* 2019;3:e10180.
12. Ma K, Zhuang ZG, Wang L, et al. The Chinese Association for the Study of Pain (CASP): Consensus on the Assessment and Management of Chronic Nonspecific Low Back Pain. *Pain Res Manag* 2019;2019:8957847.
13. Kim JY, Kim HS, Wu PH, et al. Alleviating Paravertebral Muscle Spasm after Radiofrequency Ablation Treatment of Hypersensitive Basivertebral and Sinuvertebral Nerves for Chronic Discogenic Back Pain. *Pain Physician* 2021;24:E883-92.
14. Helm Ii S, Simopoulos TT, Stojanovic M, et al. Effectiveness of Thermal Annular Procedures in Treating Discogenic Low Back Pain. *Pain Physician* 2017;20:447-70.
15. Schliessbach J, Siegenthaler A, Heini P, et al. Blockade of the sinuvertebral nerve for the diagnosis of lumbar diskogenic pain: an exploratory study. *Anesth Analg* 2010;111:204-6.
16. Yeom JS, Lee JW, Park KW, et al. Value of diagnostic lumbar selective nerve root block: a prospective controlled study. *AJNR Am J Neuroradiol* 2008;29:1017-23.
17. Zhao Q, Cheng L, Yan H, et al. The Anatomical Study and Clinical Significance of the Sinuvertebral Nerves at the Lumbar Levels. *Spine (Phila Pa 1976)* 2020;45:E61-6.
18. López WO, Vialle EN, Anillo CC, et al. Clinical and radiological association with positive lumbar discography in patients with chronic low back pain. *Evid Based Spine Care J* 2012;3:27-34.
19. Deyo RA, Diehl AK. Lumbar spine films in primary care: current use and effects of selective ordering criteria. *J Gen Intern Med* 1986;1:20-5.
20. Boden SD, Davis DO, Dina TS, et al. Abnormal magnetic-resonance scans of the lumbar spine in asymptomatic subjects. A prospective investigation. *J Bone Joint Surg Am* 1990;72:403-8.
21. Weinstein J, Claverie W, Gibson S. The pain of discography. *Spine (Phila Pa 1976)* 1988;13:1344-8.
22. Chou R, Loeser JD, Owens DK, et al. Interventional therapies, surgery, and interdisciplinary rehabilitation for low back pain: an evidence-based clinical practice guideline from the American Pain Society. *Spine (Phila Pa 1976)* 2009;34:1066-77.
23. Holt EP Jr. The question of lumbar discography. *J Bone Joint Surg Am* 1968;50:720-6.
24. Carragee EJ, Lincoln T, Parmar VS, et al. A gold standard evaluation of the "discogenic pain" diagnosis as determined by provocative discography. *Spine (Phila Pa 1976)* 2006;31:2115-23.
25. Richardson J, Collinghan N, Scally AJ, et al. Bilateral L1 and L2 dorsal root ganglion blocks for discogenic low-back pain. *Br J Anaesth* 2009;103:416-9.
26. Bydon M, De la Garza-Ramos R, Macki M, et al. Lumbar



- fusion versus nonoperative management for treatment of discogenic low back pain: a systematic review and meta-analysis of randomized controlled trials. *J Spinal Disord Tech* 2014;27:297-304.
27. Salman AE, Salman MA, Saricaoglu F, et al. Pain on injection of propofol: a comparison of methylene blue and lidocaine. *J Clin Anesth* 2011;23:270-4.
28. Guo X, Ding W, Liu L, et al. Intradiscal Methylene Blue Injection for Discogenic Low Back Pain: A Meta-Analysis. *Pain Pract* 2019;19:118-29.
29. Khalil JG, Smuck M, Koreckij T, et al. A prospective, randomized, multicenter study of intraosseous basivertebral nerve ablation for the treatment of chronic low back pain. *Spine J* 2019;19:1620-32.
30. Quinones S, Korschake M, Aguilar LL, et al. Clinical anatomy of the lumbar sinuvertebral nerve with regard to discogenic low back pain and review of literature. *Eur Spine J* 2021;30:2999-3008.
31. Breemer MC, Malessy MJA, Notenboom RGE. Origin, branching pattern, foraminal and intraspinal distribution of the human lumbar sinuvertebral nerves. *Spine J* 2022;22:472-82.
- (English Language Editor: J. Teoh)

**Cite this article as:** Liu Z, Ma R, Fan C, Chen J, Zhang R, Zheng Z, Xu Y, Liu Z, Zhao Q, Li Q. Sinuvertebral nerve block treats discogenic low back pain: a retrospective cohort study. *Ann Transl Med* 2022;10(22):1219. doi: 10.21037/atm-22-5297