

# Anastomotic Aneurysm Formation after High Flow Bypass Surgery: A Case Report with Histopathological Study

Tatsuya Uchida,<sup>1</sup> Masanori Yoshino,<sup>1</sup> Shinji Ito,<sup>2</sup> and Takayuki Hara<sup>1</sup>

Bypass surgery is often used in the treatment of large and giant aneurysms. Major complications that often arise during the perioperative period include cranial nerve palsy, ischemic complications, and hyperperfusion. However, there have been a few reports about late onset complications such as anastomotic aneurysms. In particular, anastomotic aneurysm after high flow bypasses has never been reported. A 57-year-old woman who had been suffering from left eye pain was diagnosed with a large aneurysm of the left internal carotid artery (ICA) in the cavernous portion. She was treated with high flow bypass surgery using radial artery graft and proximal ICA ligation. One and a half year after surgery, a de novo aneurysm (7.5 mm in maximum diameter) was detected in the anastomotic site. To prevent rupture, the aneurysm was resected and the middle cerebral artery (MCA) was reconstructed via superficial temporal artery (STA)-MCA bypass. Postoperative course was uneventful and the anastomotic aneurysm did not recur until 2 years after second surgery. Histological evaluation of the anastomotic aneurysm demonstrated loss of smooth muscle cells and proliferation of neointima, features consistent with a true aneurysm. Interestingly, the above changes were prominent in the radial artery graft while the MCA was almost histologically intact. As such, intraoperative intimal damage and postoperative hemodynamic stress to the radial artery graft may be a cause of aneurysm formation. Anastomotic aneurysm may occur after high flow bypass, necessitating careful postoperative follow-up.

**Keywords:** anastomotic aneurysm, high flow bypass, giant aneurysms, complication

## Introduction

Bypass surgery is often used in the treatment of large and giant aneurysms.<sup>1)</sup> The major complications that often arise in the perioperative period include cranial nerve palsy, ischemic complications and hyperperfusion.<sup>2,3)</sup> However, there have been a few reports documenting late onset complications such as anastomotic aneurysms. In particular, anastomotic

aneurysms after high flow bypasses have never been reported.

In this report, we present a case study of a large internal carotid artery (ICA) aneurysm in the cavernous sinus, which was treated with proximal ICA ligation and high-flow bypass surgery. Eighteen months later, an extremely rare complication of an arterial aneurysm affecting the intracranial vascular anastomotic site occurred.

## Case Report

A 57-year-old woman presented with a history of hypertension and left eye pain. A large aneurysm of the left ICA in the cavernous portion with a maximum diameter of 13 mm was observed during examination for headache (Fig. 1a). She was treated with high flow bypass surgery using radial artery graft and proximal ICA ligation.

Postoperative cerebrovascular angiography revealed good patency of the bypass vessels, and the cerebrovascular aneurysm was confirmed to have disappeared (Figs. 1b, and 1c). Additionally, the pain in her left eye improved.

Antiplatelet agents and antihypertensive agents were administered, and the patient was followed-up as an outpatient. One and a half year after surgery, magnetic resonance imaging showed a de novo aneurysm in the anastomotic site. Cerebrovascular angiography was performed, revealing dilation at the intracranial vascular anastomotic site in a saccular shape to 7.5 × 6.3 mm. Consequently, the patient was diagnosed with an anastomotic aneurysm (Figs. 2a–2c). Balloon occlusion test (BOT) was performed, and revealed that there were no neurological problems and cross flow was perfused to the left hemisphere via the posterior communicating artery.

A resection was scheduled so as to prevent rupture of the aneurysm. First, the aneurysm was exposed (Fig. 3a). Next, an anastomosis of the superficial temporal artery (STA) and the middle cerebral artery (MCA) distal to the original anastomotic site (at the inferior trunk of the second branch of the MCA, hereafter referred to as M2) was performed. The aneurysm was trapped and resected beyond the anastomotic site to preserve distal blood flow (Figs. 3b, and 3c). The superior trunk of the MCA demonstrated good anterograde flow during Doppler flow measurements and indocyanine green (ICG), and no decrease in motor and somatosensory evoked potentials was observed even after 30 min of cross clamping. As such, the superior trunk was not revascularized. There was enough collateral flow via the posterior communicating artery. If motor and somatosensory evoked potentials were decreased, it was necessary to perform an additional revascularization, so we were prepared to

<sup>1</sup>Department of Neurosurgery, Toranomon Hospital, Tokyo, Japan  
<sup>2</sup>Department of Pathology, Toranomon Hospital, Tokyo, Japan

Received: February 17, 2017; Accepted: April 11, 2017  
Online August 24, 2017

Copyright© 2017 by The Japan Neurosurgical Society  
This work is licensed under a Creative Commons Attribution-NonCommercial-NoDerivatives International License.

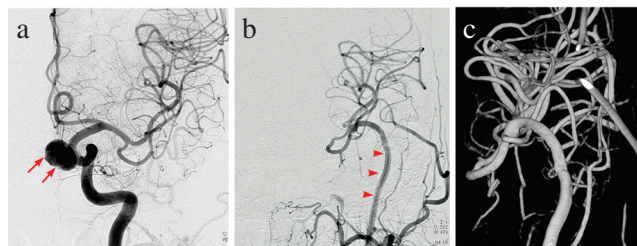
perform high flow bypass again using the vein graft (saphenous vein). Postoperatively, the patient had no new abnormal neurological findings, and postoperative cerebrovascular angiography showed that the additional bypass was patent along with a disappearance of the lesion (Fig. 3d). Cross flow was perfused to the area of superior trunk via the posterior communicating artery. (Fig. 4 left and right).

A subsequent follow-up two years after the second surgery indicated no recurrence of the anastomotic aneurysm. Histopathological findings of the resected anastomotic aneurysm included marked damage to the intima of the radial artery and a decrease or complete absence of smooth muscle cells. In addition, neointima proliferation and vascular lumen dilation were observed, features consistent with a true aneurysm (Fig. 5d). In contrast, several areas of the intima and medial smooth muscle cells in the MCA were relatively preserved (Figs. 5a–5c). Overall, these changes were prominent in the radial artery graft and the MCA was almost histologically intact.

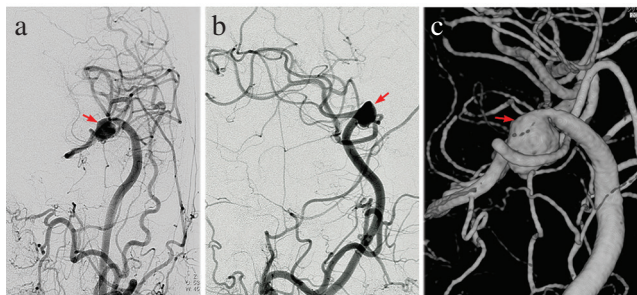
**Discussion**

In this report, we present a case study of an anastomotic aneurysm after treatment of a large ICA aneurysm with proximal ICA ligation and high-flow bypass surgery.

To the best of our knowledge, there are no reports documenting any complications of an anastomotic aneurysm in the clinical course following high-flow bypass surgery.



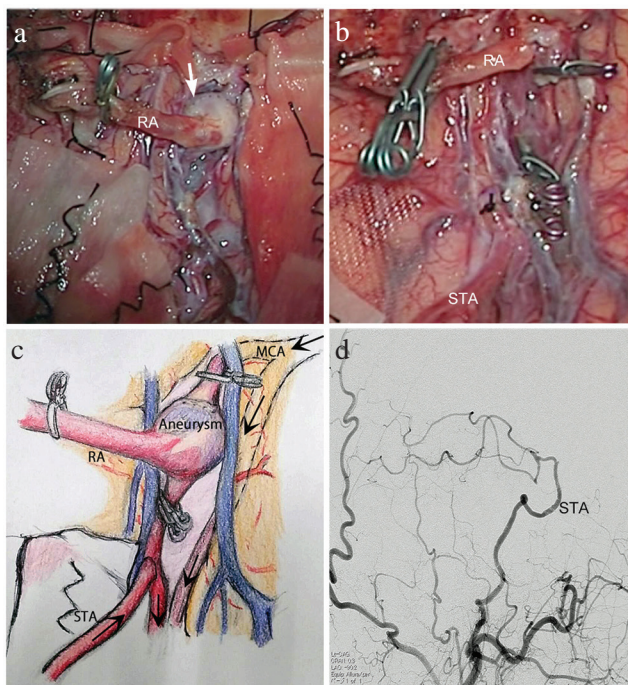
**Fig. 1** A large aneurysm (arrow) of the left internal carotid artery (ICA) in the cavernous portion with a maximum diameter of 13 mm. High flow bypass using the radial artery (arrow head) graft and proximal ICA ligation. Anterior-posterior cerebrovascular angiography (a: preoperative), (b: postoperative) showing good patency of the bypass vessels and disappearance of the cerebrovascular aneurysm. (c), A detailed 3D image of the anastomotic site.



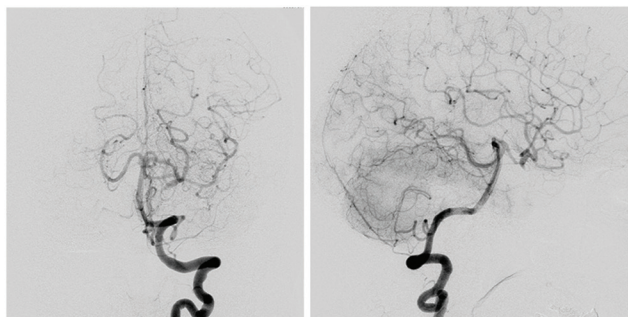
**Fig. 2** Anastomotic aneurysm. Cerebrovascular angiography showed that the intracranial vascular anastomosis had dilated in a saccular shape to 7.5 × 6.3 mm (arrow), and the patient was diagnosed with an anastomotic aneurysm. (a: anterior-posterior, b: lateral, c: 3D).

In the field of cardiovascular surgery, there are several reports on anastomotic aneurysms occurring after bypass surgery using radial artery or blood vessel prosthesis.<sup>4,5</sup> The frequency of an anastomotic aneurysm is estimated to be approximately 1–5%. Although the underlying mechanism leading to an anastomotic aneurysm is currently unclear, it is believed to be due to infection, intimal injury, hypertension and mechanical stress.<sup>6,7</sup>

Conversely, there have been several reports in the field of neurosurgery on anastomotic aneurysms complicating STA–MCA anastomoses.<sup>8–10</sup> Kohno et al. reported a case of an anastomotic aneurysm occurring >2 months postoperatively

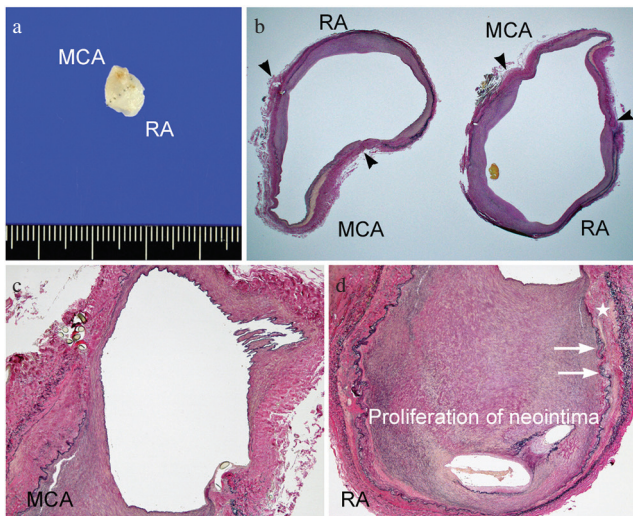


**Fig. 3** Intraoperative photographs obtained illustration. (a) The anastomotic aneurysm (arrow) was exposed. (b) An anastomosis of the STA and MCA distal to the original anastomotic site was performed. The anastomotic aneurysm was trapped and resected beyond the anastomotic site. (c) Illustration showing surgical image. (d) Anterior-posterior cerebrovascular angiography showed that the lesion had disappeared and that the additional bypass was patent.



**Fig. 4** Cross flow. Vertebral angiography (VAG) after second surgery showed that there was enough collateral flow to the left hemisphere via the posterior communicating artery. (left: anterior-posterior, right: lateral).





**Fig. 5** The histopathological findings of the resected anastomotic aneurysm. (a) Macroscopic photograph revealing the anastomotic aneurysm. (b) Photomicrograph of the anastomotic site. (arrow head: anastomotic site) Elastica Van Gieson stain; original magnification,  $\times 12.5$ . (c) Photomicrograph of the MCA. Several areas of the intima and medial smooth muscle tissue were relatively preserved. Elastica Van Gieson stain; original magnification,  $\times 40$ . (d) Photomicrograph of the RA. Smooth muscle cells ( $\otimes$ ) changes and complete disappearance of these cells were observed. Proliferation of neointima, features consistent with a true aneurysm, was observed and the vascular lumen was dilated. (arrow; intima) Elastica Van Gieson stain; original magnification,  $\times 40$ .

as a late-onset complication of an STA–MCA anastomosis.<sup>11)</sup> According to the report, anastomotic aneurysms are caused by destruction of the internal elastic membrane by surgical manipulation followed by accelerated arterial aneurysm formation at the site of suturing. This accelerated formation could be due to destruction of the medial smooth muscle cells during transient elevations in MCA pressure. Similarly, Kurokawa et al. reported a case of an anastomotic aneurysm that occurred as a late-onset complication of STA–MCA anastomoses, with an incidence rate of 0.66%.<sup>12)</sup> This group also discussed hemodynamic stress on the vascular anastomotic site as a cause of arterial aneurysms. In both reports, formation of an aneurysm could thus have been caused by injury to the vascular wall through surgical procedures followed by stress-like hypertension, which increased at the anastomotic site. In our case study, formation of neointima caused hypertrophy in the radial artery and was suggestive of intimal injury. Furthermore, the smooth muscle cells situated in the two sheets of the elastic plate were largely destroyed. Congruent with the reports thus far, the causes of an aneurysm could include intimal injury followed by injury to the medial smooth muscle cells from the surgical operation, leading to a postoperative increase in blood pressure and formation of an anastomotic aneurysm.

At present, there have been incredible advancements in the development of treatments targeting large or giant aneurysms such as the Flow Diverter. However, complex vascular aneurysms that require resection of aneurysms with endovascular occlusion of the parent vessel still need to be treated with revascularization through high-flow bypass. It is imperative that anastomotic aneurysms as a complication of high-flow bypass be made known to surgeons. Consequently, high-flow bypass surgery involving the use of the radial artery should consider patient risk factors, as well as enforcing a strict treatment plan and follow-up. To the best of our knowledge, this is the first report of an anastomotic aneurysm occurring after revascularization through high-flow bypass. Going forward, we expect that the incidence and etiology will be elucidated through further accumulation of case studies.

### Informed Consent

The patient has consented to submission of this case report to the journal.

### Conflicts of Interest Disclosure

We have no potential conflict of interest.

### References

- 1) al-Rodhan NR, Piepgras DG, Sundt TM Jr: Transitional cavernous aneurysms of the internal carotid artery. *Neurosurgery* 33: 993–996; discussion 997–998, 1993
- 2) Cuatico W, Cook AW, Tyshchenko V, Khatib R: Massive enlargement of intracranial aneurysms following carotid ligation. *Arch Neurol* 17: 609–613, 1967
- 3) Diaz FG, Ausman JI, Pearce JE: Ischemic complications after combined internal carotid artery occlusion and extracranial-intracranial anastomosis. *Neurosurgery* 10: 563–570, 1982
- 4) Courbier R, Aboukhatir R: Progress in the treatment of anastomotic aneurysms. *World J Surg* 12: 742–749, 1988
- 5) Pogorzelski R, Fiszer P, Toutouchi S, et al.: Anastomotic aneurysms—20-years of experience from one center. *Pol Przegl Chir* 85: 181–191, 2013
- 6) Szilagyi DE, Smith RF, Elliott JP, Hageman JH, Dall’Olmo CA: Anastomotic aneurysms after vascular reconstruction: problems of incidence, etiology, and treatment. *Surgery* 78: 800–816, 1975
- 7) Gaylis H: Pathogenesis of anastomotic aneurysms. *Surgery* 90: 509–515, 1981
- 8) Lantos G, Fein JM, Knep S: Cortical artery aneurysm formation after extracranial to intracranial bypass surgery. Case report. *J Neurosurg* 60: 636–639, 1984
- 9) Fujiwara S, Fujii K, Fukui M: De novo aneurysm formation and aneurysm growth following therapeutic carotid occlusion for intracranial internal carotid artery (ICA) aneurysms. *Acta Neurochir (Wien)* 120: 20–25, 1993
- 10) Anson JA, Stone JL, Crowell RM: Rupture of a giant carotid aneurysm after extracranial-to-intracranial bypass surgery. *Neurosurgery* 28: 142–147, 1991
- 11) Kohno K, Ueda T, Kadota O, Sakaki S: Subdural hemorrhage caused by de novo aneurysm complicating extracranial-intracranial bypass surgery: case report. *Neurosurgery* 38: 1051–1055, 1996
- 12) Tir M, Devos D, Blond S, et al.: Exhaustive, one-year follow-up of subthalamic nucleus deep brain stimulation in a large, single-center cohort of parkinsonian patients. *Neurosurgery* 61: 297–304; discussion 304–305, 2007

Corresponding author:

Takayuki Hara, MD, PhD, Department of Neurosurgery, Toranomon Hospital, 2-2-2 Toranomon, Minato-ku, Tokyo 105-8470, Japan.

✉ takayuki\_hara@syd.odn.ne.jp