

## Usefulness of CT imaging for segmental lung lobe torsion without typical radiographic imaging in a Pomeranian

Mihyun CHOI<sup>1)</sup>, Namsoon LEE<sup>1)</sup>, Seoyeon KEH<sup>1)</sup>, Heeyeon CHOI<sup>1)</sup>, Yoonji YIM<sup>1)</sup>, Hyunwook KIM<sup>1)</sup>, Joohyun JUNG<sup>2)</sup> and Mincheol CHOI<sup>3)</sup>\*

<sup>1)</sup>Haemaru Referral Animal Hospital, Seongnam 463-050, South Korea

<sup>2)</sup>Ilsan Animal Medical Center, Daehwa-dong 2030, Ilsanseo-gu, Goyang-si, Gyeonggi-do, South Korea, 411-803

<sup>3)</sup>Department of Veterinary Medical Imaging, College of Veterinary Medicine, Seoul National University, Seoul 151-742, South Korea

(Received 27 September 2013/Accepted 29 September 2014/Published online in J-STAGE 30 October 2014)

**ABSTRACT.** A 3-year-old, intact female Pomeranian presented with a 1-month history of coughing. Thoracic radiography showed focal infiltration of the left cranial lung lobe and widening of the cranial mediastinum. Subsequent computed tomography revealed torsion of the caudal segment of the left cranial lung lobe, which was confirmed by exploratory thoracotomy. There was no apparent underlying etiology for the condition. To the authors' knowledge, this is the first report of lung lobe torsion in this breed and the first detailed CT imaging report for segmental lung lobe torsion.

**KEY WORDS:** canine, CT, lung lobe torsion, segment of the left cranial lung lobe

doi: 10.1292/jvms.13-0473; *J. Vet. Med. Sci.* 77(2): 229–231, 2015

Lung lobe torsion (LLT) is a rare, life-threatening pulmonary disorder in small animals [3, 8]. Large-breed dogs with a deep narrow chest are predisposed to spontaneous LLT, but LLT can also occur in small-breed dogs, often in association with predisposing conditions, such as pleural effusion, trauma, diaphragmatic hernia or prior surgery [5].

The imaging findings of LLT have been well described [9]. Thoracic radiography demonstrates pleural effusion and evidence of consolidation in the affected lobe [2, 7]. Thoracic ultrasonography may show the affected lobe with a liver-like appearance [11]. Computed tomography findings include pleural effusion, an abruptly terminating bronchus, emphysema of the affected lung and no contrast enhancement in the rotated lobe [10]. The only treatment for LLT is surgical resection, and successful medical therapy has not been reported [3].

This case report describes LLT affecting the caudal segment of the left cranial lung lobe (LCrL) in a Pomeranian. To the authors' knowledge, this is the first report of lung lobe torsion in this breed and the first detailed CT imaging report for segmental LLT.

A 3-year-old, intact female Pomeranian was referred to us with a 1-month history of coughing. At the referring hospital, the dog had been treated with antibiotics for 1 week, but there was no response. On presentation, the dog showed a normal status but exciting, and it showed intermittent coughing (sounded like a goose honking). The results of laboratory

examinations (complete blood count, serum chemistry and coagulation time) were within the normal range, except for increased levels of serum alanine aminotransferase (162  $\mu$ l/l; reference range, 10–100  $\mu$ l/l), aspartate aminotransferase (111  $\mu$ l/l; reference range, 0–50  $\mu$ l/l) and glucose (172 mg/dl; reference range, 74–143 mg/dl). Orthogonal radiographic views were obtained (Fig. 1A and 1B). The lateral view revealed narrowing of the cervical trachea and increased soft tissue opacity in the cranial thorax. There was also dorsal elevation of the intrathoracic trachea. On the ventrodorsal view, focal alveolar infiltration of the left cranial lung field was identified, along with a mediastinal shift to the left and widening of the cranial mediastinum. Subsequent thoracic ultrasonography showed an echogenic mass (0.63  $\times$  16.3 mm) near a large blood vessel (Fig. 1C). Differential diagnosis was lung parenchymal infiltration or mediastinal mass. In order to clarify anatomical locations, computed tomography (CT) was performed. CT revealed torsion of the caudal segment of the LCrL toward the medial side of the cranial segment (Fig. 2B and 2C). Normally, cranial and caudal segments of the LCrL were aligned with the thoracic wall (Fig. 2A), but this patient showed a caudal segment of the LCrL aligned with the mediastinum and it was surrounded by the cranial segment of the LCrL. The bronchus of the caudal segment of the LCrL showed torsion and abrupt termination, whereas as the more distal segment was filled with air and dilated, giving the bronchus as twisted appearance (Fig. 2D). There was rarely pleural effusion (Fig. 2D). The twisted lobe contained trapped gas, which appeared as a vesicular gas pattern (Fig. 3A). Focal alveolar infiltration of the cranial segment of the LCrL and mild cranial mediastinal lymphadenopathy were also identified. After intravenous contrast medium was administered (Fig. 3B and 3C), the mean increase in enhancement of the twisted lung lobe (39 Hounsfield units [HU]) was similar to the enhancement of

\*CORRESPONDENCE TO: CHOI, M., Department of Veterinary Medical Imaging, College of Veterinary Medicine, Seoul National University, Seoul 151-742, South Korea. e-mail: mcchoi@snu.ac.kr

©2015 The Japanese Society of Veterinary Science

This is an open-access article distributed under the terms of the Creative Commons Attribution Non-Commercial No Derivatives (by-nc-nd) License <<http://creativecommons.org/licenses/by-nc-nd/3.0/>>.

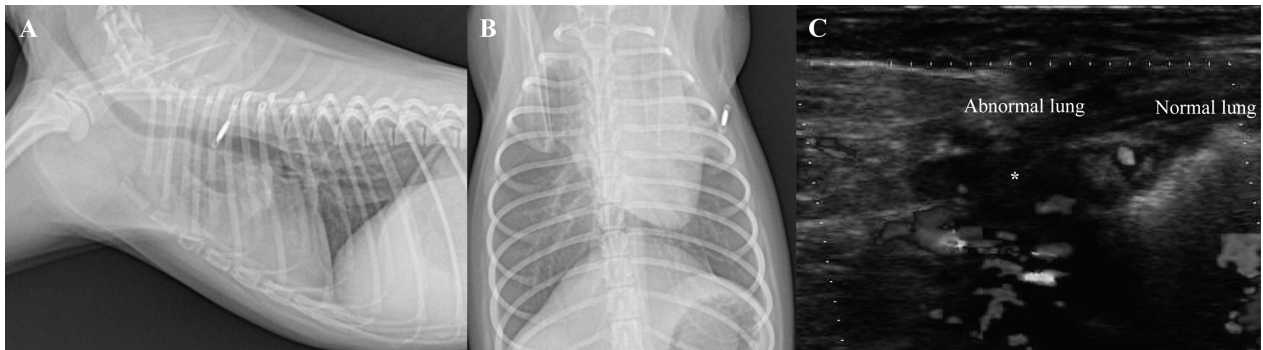


Fig. 1. Thoracic radiographs (A, B) and longitudinal intercostal ultrasonogram (C) of the left cranial thorax. In the lateral view (A), there is increased soft tissue opacity in the cranial thorax with dorsal elevation of the intrathoracic trachea. In the ventrodorsal view (B), there is mediastinal shift to the left and widening of the cranial mediastinum. An echogenic mass (C, asterisk) was observed near the large blood vessel.

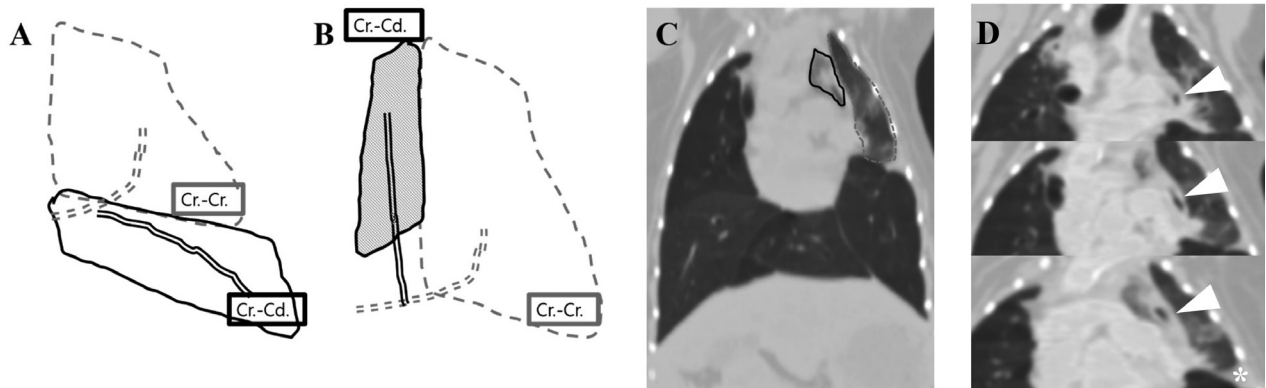


Fig. 2. Diagram of normal left cranial lung lobe (A). The left cranial lobe is incompletely divided into a cranial (Cr.-Cr.) and a caudal segment (Cr.-Cd.); the 2 segments share a common lobar bronchus. In our case (B), the caudal segment was twisted toward the medial side (toward the mediastinum) of the cranial segment. Dorsally reformatted computed tomography image (C) of the dog (solid line, caudal segment; dashed line, cranial segment) and the bronchus (arrowhead) of the caudal segment of the LCrL, which was twisted, with abrupt termination (D). There was rarely pleural effusion (D, asterisk).

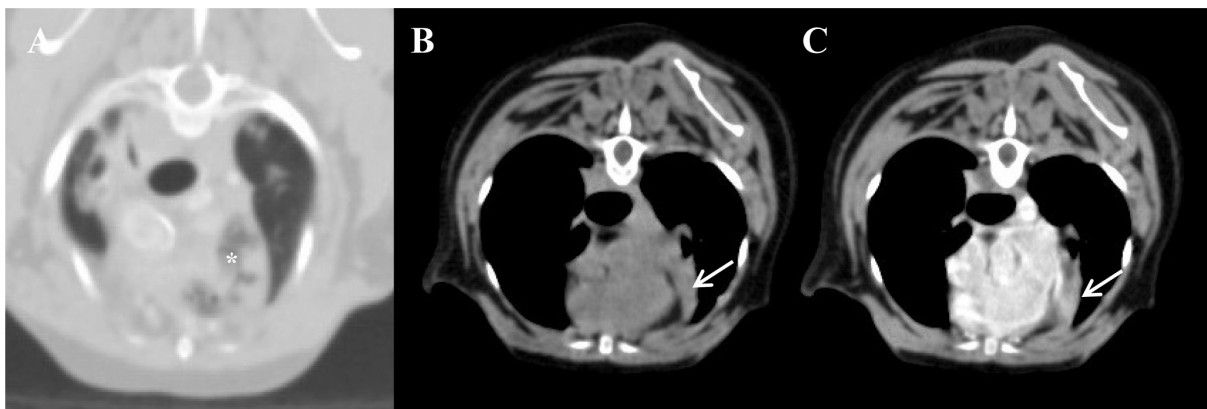


Fig. 3. Axially reformatted image of the lung (A) and mediastinal window (B, C). (A) The twisted lung lobe contained trapped gas (bottom, asterisk). (B, C) After intravenous contrast medium was administered (B, before; C, after), the mean increase in enhancement of the twisted lung lobe (arrow) was similar to the enhancement of focal infiltration in a normal lung lobe.

focal infiltration in a normal lung lobe (34 [HU]).

A total left cranial lung lobectomy was performed. Exploration of the left hemithorax revealed LLT in the caudal segment of the LCrL (segmental torsion), in agreement with the CT findings. Grossly, the caudal segment of the LCrL appeared congested, and atelectasis was noted. Histopathologic examination (IDEXX Laboratories) revealed marked locally extensive necrosis, hemorrhage and fibrosis. An underlying cause of the torsion was not evident.

Segmental LLT in dogs has only been reported three times, involving the cranial segment in a 5-month-old chow chow [6] and 7-week-old pug [4], and the caudal segment in a 9-year-old Yorkshire terrier [1]. All dogs showed typical results of LLT in radiographic imaging like lung consolidation and pleural effusion [2, 7]. At the time of diagnosis, the animals were considered to have general LLT, but after the surgery, they were diagnosed with segmental LLT. Our case, on the other hand, was diagnosed with lung consolidation (pneumonia, etc.) or a mediastinal mass based on radiographic findings at first. A definitive diagnosis of segmental LLT diagnosis is difficult using only radiographic findings. A definitive diagnosis requires an additional study, such as CT or bronchoscopy.

Our case was different from general LLT as well as previous cases of segmental LLT. First, the patient did not show general characteristics of LLT like marked pleural effusion and no contrast enhancement of the twisted lung lobe on imaging [2, 7]. These differences might have been because the arterial blood supply appeared to be intact, and the lobe was possibly in the early stages of LLT, although the exact timing of development of the torsion was unknown. Second, the torsion of the segment lobe looked like an additional lung lobe, because it displaced the medial side of the normal segment. A mediastinal reflection-like membrane (lung to lung interface) had formed between torsion and normal segment. To distinguish between torsion and a rudimentary normal lung lobe, the appearance of the bronchus (displacement, abrupt ending) needs to be confirmed. Compared with our case, previous cases of segmental LLT might have been in the chronic stage, so they showed a general signature of LLT. But, in the acute (early) stage, as in our case, a mediastinal reflection-like membrane and the appearance of the bronchus represent essential diagnostic information on CT imaging for segmental LLT.

There are several theories as to why LLT occurs. This patient made a sound like a goose honking when exciting, so we hypothesized that it had concurrent bronchial abnormalities because the presence of pulmonary atelectasis is recognized to predispose to rotation [6]. As surgical findings, atelectasis was noted in the twisted caudal segment of the LCrL, so this change might be due to inflammation or the

suspected bronchial abnormalities. But, no underlying cause was identified by histopathologic examination, and spontaneous LLT was suspected.

LLT should be considered in any patient presenting with a history of acute dyspnea and supporting radiographic signs of pleural effusion, increased opacity of a lung lobe and the presence of air bronchogram. However, our case illustrated that segmental LLT can occur without dramatic radiographic changes in the thorax. Therefore, if there are nonspecific findings on thoracic radiography, an additional study, such as CT, should be performed for definitive diagnosis, as prompt surgical intervention gives the patient the best chance for survival.

**ACKNOWLEDGMENT.** This study was supported by the Research Institute for Veterinary Science at Seoul National University.

#### REFERENCES

1. Choi, J. and Yoon, J. 2006. Lung lobe torsion in a Yorkshire terrier. *J. Small Anim. Pract.* **47**: 557. [Medline] [CrossRef]
2. d'Anjou, M. A., Tidwell, A. S. and Hecht, S. 2005. Radiographic diagnosis of lung lobe torsion. *Vet. Radiol. Ultrasound* **46**: 478–484. [Medline] [CrossRef]
3. Gicking, J. and Aumann, M. 2011. Lung lobe torsion. *Compend. Contin. Educ. Vet.* **33**: E4. [Medline]
4. Hansen, N. L., Hall, S. A., Christie, B. A. and Charles, J. A. 2006. Segmental lung lobe torsion in a 7-week-old pug. *J. Vet. Emerg. Crit. Care* **16**: 215–218. [CrossRef]
5. Hofeling, A. D., Jackson, A. H., Alsup, J. C. and O'Keefe, D. 2004. Spontaneous midlobar lung lobe torsion in a 2-year-old Newfoundland. *J. Am. Anim. Hosp. Assoc.* **40**: 220–223. [Medline] [CrossRef]
6. Hoover, J. P., Henry, G. A. and Panciera, R. J. 1992. Bronchial cartilage dysplasia with multifocal lobar bullous emphysema and lung torsions in a pup. *J. Am. Vet. Med. Assoc.* **201**: 599–602. [Medline]
7. Murphy, K. A. and Brisson, B. A. 2006. Evaluation of lung lobe torsion in Pugs: 7 cases (1991–2004). *J. Am. Vet. Med. Assoc.* **228**: 86–90. [Medline] [CrossRef]
8. Neath, P. J., Brockman, D. J. and King, L. G. 2000. Lung lobe torsion in dogs: 22 cases (1981–1999). *J. Am. Vet. Med. Assoc.* **217**: 1041–1044. [Medline] [CrossRef]
9. Schultz, R. M., Peters, J. and Zwingenberger, A. 2009. Radiography, computed tomography and virtual bronchoscopy in four dogs and two cats with lung lobe torsion. *J. Small Anim. Pract.* **50**: 360–363. [Medline] [CrossRef]
10. Seiler, G., Schwarz, T., Vignoli, M. and Rodriguez, D. 2008. Computed tomographic features of lung lobe torsion. *Vet. Radiol. Ultrasound* **49**: 504–508. [Medline] [CrossRef]
11. White, R. N. and Corzo-Menendez, N. 2000. Concurrent torsion of the right cranial and right middle lung lobes in a whippet. *J. Small Anim. Pract.* **41**: 562–565. [Medline] [CrossRef]