


**Original Article: Clinical Investigation****Urethroplasty for chordee with a paper-thin hypoplastic urethra: A long-term study**Guanglun Zhou,<sup>†</sup> Jianchun Yin,<sup>†</sup> Junjie Sun, Xiaodong Liu, Jiahong Su and Shoulin Li 

Department of Urology and Laboratory of Pelvic Floor Muscle Function, Shenzhen Children's Hospital, Shenzhen, Guangdong, China

**Abbreviations & Acronyms**

OIF = onlay island flap  
PTHU = paper-thin hypoplastic urethra  
TIP = tubularized incised plate

**Correspondence:** Shoulin Li M.D., Department of Urology and Laboratory of Pelvic Floor Muscle Function, Shenzhen Children's Hospital, Futian District, Shenzhen 518000, Guangdong, China. Email: szetyzyt@163.com

This is an open access article under the terms of the Creative Commons Attribution-NonCommercial-NoDerivs License, which permits use and distribution in any medium, provided the original work is properly cited, the use is non-commercial and no modifications or adaptations are made.

Received 2 February 2022; accepted 4 March 2022.  
Online publication 19 March 2022

<sup>†</sup>These authors contributed equally to this work.

**Objectives:** To establish a standard surgical procedure for children with chordee with a paper-thin hypoplastic urethra, which was based on the degree of curvature and urethral plate quality. To guidelines for the management of this disorder.

**Methods:** We reviewed 58 cases of chordee with a paper-thin hypoplastic urethra, managed between March 2006 and September 2020. The age of the patients ranged from 23 to 89 months. Operative details and postoperative complications were analyzed.

**Results:** Mild-moderate chordee with a paper-thin hypoplastic urethra correction was performed using a tubularized incised plate (13 cases) or onlay island flap (five cases) technique after penile degloving. Severe chordee with a paper-thin hypoplastic urethra required transection of the urethra and underwent a Duckett (11 cases) or staged (29 cases) urethroplasty. Complications in the tubularized incised plate and onlay island flap groups were 7.7% and 20%, respectively. The overall complication rate was 10.3% in the staged group and 27.3% in the Duckett group.

**Conclusions:** Reconstruction of the entire hypoplastic urethra should be recommended in the management of chordee with a paper-thin hypoplastic urethra. We propose an algorithm based on the degree of curvature and urethral plate quality. The tubularized incised plate or onlay island flap technique can be used for mild to moderate chordee with a paper-thin hypoplastic urethra, and the outcome of the tubularized incised plate technique tends to be better than that of the onlay island flap technique. Duckett or staged urethroplasty is suitable for severe chordee with a paper-thin hypoplastic urethra, and the staged technique can improve the overall success rate.

**Key words:** hypospadias, penile curvature, postoperative complications, reconstructive surgery, urethroplasty.

**Introduction**

Chordees with hypoplastic urethra usually occurs in hypospadias, and is uncommon in children with the meatus located in the glans.<sup>1</sup> In 1973, Devine and Horton reported their experience of managing chordee with a hypoplastic urethra and they classified them.<sup>2</sup> In its most severe form, described as type I, all layers of the urethra (dartos fascia, Buck's fascia, and spongiosum) are deficient in the affected part of the urethra. In such cases, the urethral mucosa and skin are densely adherent to each other, this appears as a "PTHU."

The surgical correction of chordee with a PTHU may be difficult and may lead to intraoperative and postoperative complications, requiring the excision and reconstruction of the hypoplastic urethra.<sup>1</sup> Polat *et al.* considered chordee with a PTHU to be a variant of hypospadias and recommended that it should be managed in the same way.<sup>3</sup> However, there is a lack of clear agreement regarding its ideal surgical management. There is still controversy as to whether surgeons should: (i) preserve or resect a PTHU, and (ii) perform a one- or two-stage urethroplasty.

There are only few studies on chordee with a PTHU in children. In a small case series with a retrospective study, the postoperative complication rate of this disease was as high as 60%.<sup>4</sup> Here, we review our experience regarding the procedure and outcomes while treating chordee with a PTHU, and propose a systematic approach to the surgical management of this disorder. Our preliminary experience showed that this new algorithm has resulted in fewer complications compared to previous studies.<sup>2,4</sup>

## Methods

### Study design and population

This retrospective study was approved by the institutional review board of our institution. Written informed consent was obtained from the parents or guardians of all the patients prior to treatment.

We retrospectively reviewed all cases of patients with chordee with a PTHU who underwent urethroplasty at our institution between March 2006 and September 2020. Chordee with a PTHU was defined as a meatus located on the ventral side or tip of the glans with penile curvature, with the ventral urethral mucosa and skin densely adherent to each other and the absence of dartos fascia, Buck's fascia, and corpus spongiosum in the affected part of the urethra. In such patients, the PTHU was from the meatus to the midshaft of the penis, even proximal to it. Base on PTHU was difficult to separate from the skin, we chose to open the ventral side of urethra, and then the procedure was performed according to the curvature and urethral plate quality. For cases which had a curvature  $>30^\circ$  (defined as severe chordee), after the penile degloving was performed, a Duckett or staged urethroplasty was performed. The choice of Duckett or staged urethroplasty was based on surgeon's preference. On the other hand, for cases with a curvature  $<30^\circ$  (defined as mild-moderate chordee), after the degloving procedures were performed, a TIP or OIF urethroplasty was performed. Data on patient demographics, procedure details, results, complications, and uroflowmetry were reviewed. Patients with a history of penile surgery were excluded from this study.

### Surgical technique

#### TIP urethroplasty and OIF urethroplasty

The ventral side of the PTHU was opened from the meatus to the normal urethra, and then the penis was degloved (Fig. 1a,b). The tethered ventral tissue was excised and the degree of curvature was assessed. An additional dorsal midline plication procedure was performed in patients with a residual curvature  $<30^\circ$ . The dorsal urethral plate was usually sufficiently wide and viable, then either a TIP urethroplasty (as described for TIP repair,<sup>5</sup> Fig. 1c) or OIF urethroplasty (as described by Mohajerzadeh *et al.*<sup>6</sup>) was performed, depending on the surgeon's preference.

#### Duckett urethroplasty

The opening of the ventral side of the PTHU, degloving of the penis, and excision of the tethered ventral tissue, was performed as described above. If the curvature was  $>30^\circ$ , the urethra was transected at the point of maximum ventral curvature. Both ends of the transected urethra were released to lengthen and straighten the penis. An additional single dorsal plication procedure was performed if the urethral plate transection was inadequate to straighten the penis. Artificial erection was then performed to ensure penile straightening. The distal urethral plate of the penis was resected, the length of the urethral defect was measured, and the neourethra was created. Neourethra reconstruction was performed using a Duckett's tube and it was rotated ventrally. The proximal end of the neourethra was anastomosed with the proximal stoma of the transected urethra and the distal end of the neourethra was fixed at the glans. The mobilized glans wings were rotated medially to cover the neourethra. The time of indwelling catheter was 10–14 days after surgery.

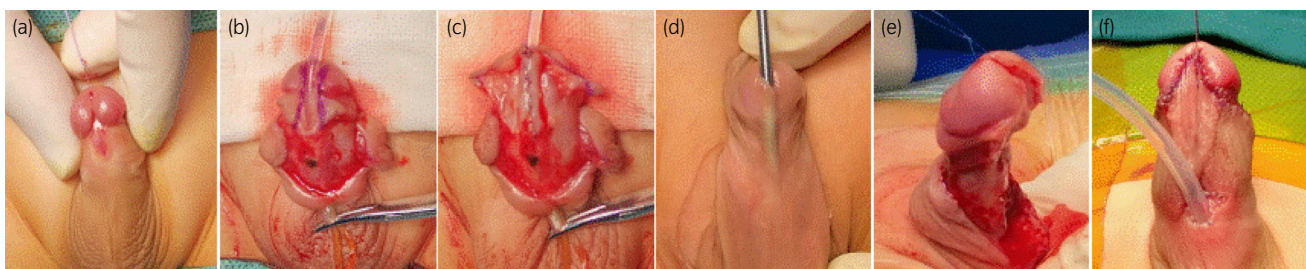
#### Staged urethroplasty

For the first stage of staged urethroplasty, which included opening the ventral part of the PTHU, penile degloving, excision of the tethered ventral tissue, transection of the urethral plate, and resection of the distal urethral plate, Duckett urethroplasty was performed. Byar's flaps were created, they were made to cover the residual ventral defect, and were closed along the midline (Fig. 1d–f).

The second stage of the procedure was carried out 6 months after the first stage, and the Duplay procedure was used to reconstruct the residual urethral defect. A 12- to 15-mm wide strip was designed that extended from the proximal meatus to the tip of the glans. The Buck's fascia was dissected and an 8–10-Fr silicone catheter was used for the tubularization of the neourethra. The time of indwelling catheter was 10–14 days after surgery.

#### Follow-up

All patients were reassessed at 1, 3, 6, and 12 months after urethroplasty. Subsequently, follow-up visits were conducted annually. The appearance of uroflowmetry and micturition were assessed during the follow-up period.



**Fig. 1** Preoperative and intraoperative images: (a) opening the ventral side of the paper-thin urethra from the meatus to the normal urethra; (b) penile degloving; (c) urethroplasty; (d) PTHU; (e) an artificial penile erection after urethral transection; (f) Byar's flaps were created and used to cover the residual ventral defect.

**Table 1** Demographic and clinical outcomes of different surgical repair groups

Observations	Staged group	Duckett group	P-value	TIP group	OIF group	P-value
No. of patients	29	11		13	5	
Age at first surgery (months)	37 (range 25–82)	38 (range 24–78)	>0.05	36 (range 24–89)	37 (range 23–75)	>0.05
Length of the urethral defect (cm)	4.6 (range 4.0–5.5)	4.6 (range 3.9–5.6)	>0.05	2.4 (range 2.0–3.3)	2.5 (range 2.3–3.3)	>0.05
Complications	3 (10.3%)	3 (27.3%)	>0.05	1 (7.7%)	1 (20%)	>0.05

## Statistical analysis

Statistical analysis was performed using SPSS version 21.0. Continuous variables that followed a normal distribution were presented as mean  $\pm$  standard deviation and compared using the Student's *t*-test. Categorical variables were presented as numbers and percentages and compared using the chi-squared test or Fisher's exact test. Statistical significance was set at  $P < 0.05$ .

## Results

A total of 58 children were included in this study: 40 children had severe chordee with a PTHU, they underwent the staged (29 cases) or Duckett urethroplasty (11 cases); 18 children had mild to moderate chordee with a PTHU, they underwent the TIP (13 cases) or OIF technique (five cases). The patients' demographic characteristics and outcomes are presented in Table 1.

The median age at the first surgery in the Duckett group (38 months, range 24–78) and in the staged group (37 months, range 25–82,  $P > 0.05$ ) were similar. The median length of the urethral defect in the Duckett group (4.6 cm, range 3.9–5.6) was similar to that in the staged group (4.6 cm, range 4.0–5.5,  $P > 0.05$ ). The median follow-up time was 60 months. The overall complications in the staged group were 10.3% (3/29), all of which were urethral fistulas; the overall complications in the Duckett group were 27.3% (3/11), which included one patient with urethral diverticulum, one with urethral fistula, and one with urethral stricture. All fistulas and diverticula were successfully repaired through reoperations, and the urethral strictures were cured after urethral dilatation. None of these patients had residual chordee. A total of five patients had persistent chordee after degloving and division of the plate, they underwent additional dorsal plication (two cases underwent simultaneous ventral corporotomies and dorsal plication).

The median age at the first surgery in the TIP group (36 months, range 24–89) and in the OIF group (37 months, range 23–75,  $P > 0.05$ ) were similar. The median length of urethral defect in the TIP group (2.4 cm, range 2.0–3.3) was similar to that in the OIF group (2.5 cm, range 2.3–3.3,  $P > 0.05$ ). The median follow-up duration was 64 months. Complications in the TIP and OIF groups were 7.7% (1/13) and 20% (1/5), respectively. There was one fistula in both groups, which were successfully treated by fistula repair procedures. Of these patients, none had residual chordee or diverticula.

The maximal urinary flow rate of the Duckett group was lower than that in the staged group ( $6.8 \pm 1.8$  mL/s vs

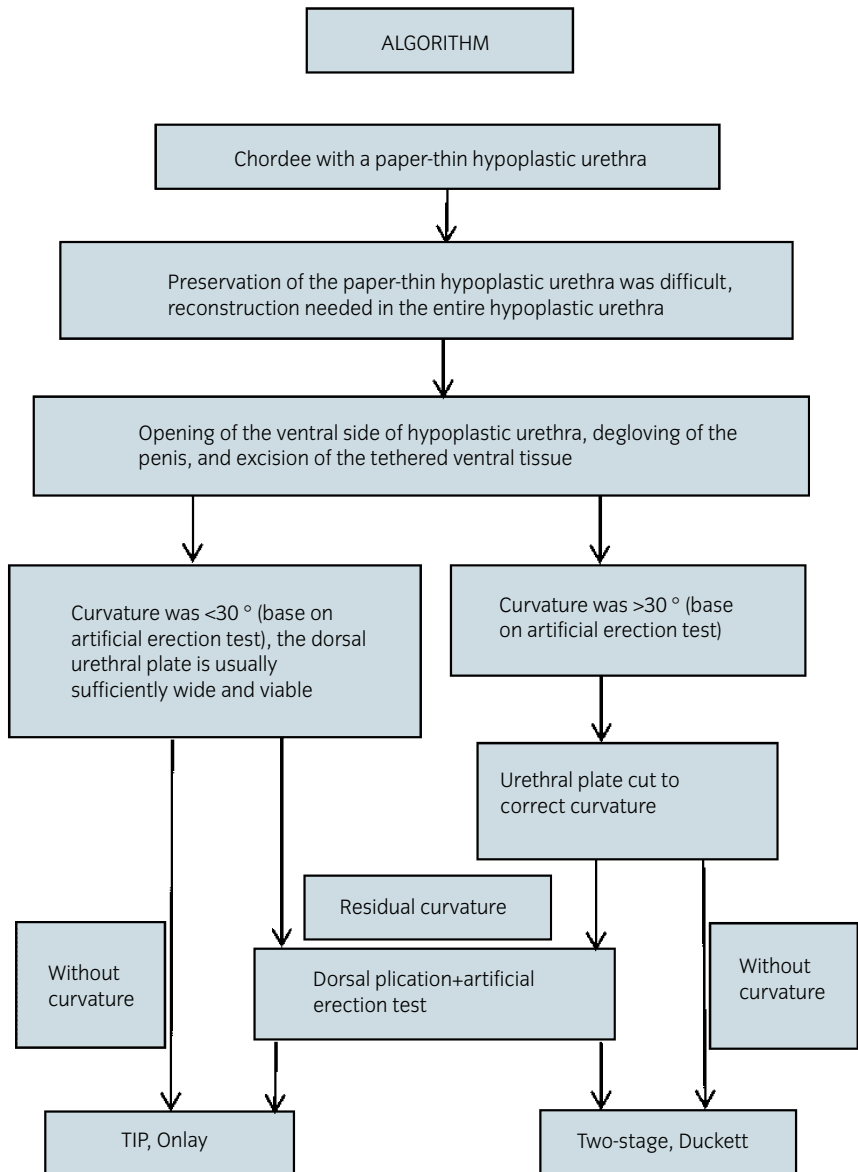
$8.0 \pm 2.0$  mL/s,  $P < 0.05$ ) at 1 month postoperatively. Interestingly, the maximal urinary flow rate of the Duckett group at 6 months and after 1 year was similar to that in the staged group ( $8.5 \pm 1.9$  mL/s vs  $8.8 \pm 2.1$  mL/s and  $10.5 \pm 2.4$  mL/s vs  $10.7 \pm 2.5$  mL/s, respectively) ( $P > 0.05$ ). The maximal urinary flow rate of the TIP group at 1 month, 6 months, and 1 year postoperatively was similar to that in the OIF group ( $P > 0.05$ ).

## Discussion

Hypospadias repair aims to achieve normal functional and cosmetic outcomes with low complication rates. The effects of chordee with a PTHU are related not only to the choice of corrective procedure and the surgeon's technique, but also to the quality of available penile tissue and the degree of chordee.<sup>7</sup> There is no universal agreement on the surgical management of chordee with a PTHU.

In 1973, Devine and Horton proposed chordee with a PTHU and reported significant complications in these patients, including inadvertent intraoperative urethrotomy and postoperative fistula, stricture, and repair breakdown.<sup>2</sup> Similarly, in 1987, Hurwitz *et al.* reported that they treated nine cases of this disorder by preserving or attempting to preserve the paper-thin hypoplastic urethral; however, intraoperative urethrotomy occurred in many cases, and the postoperative complication rate was 55.5% (5/9).<sup>1</sup> Dipaola *et al.* reported that this disease was treated with one-stage urethroplasty (Duckett or Mathieu urethroplasty) and the incidence of complications was as high as 50%, including a recurrent chordee rate of 50% and a fistula rate of 50%, and a reoperation rate of complications of 100%.<sup>8</sup> Similarly, in 2013, Singh *et al.* reported that 14 patients underwent one-stage urethroplasty (OIF or tubularized transverse inner preputial island flap or Asopa's tube urethroplasty) and the incidence of complications was as high as 64.3% (9/14), including a stricture rate of 44.4%, fistula rate of 55.6%, and reoperation rate of complications of 100%.<sup>4</sup>

Some previous studies have shown that the treatment of chordee with a PTHU may result in significant intraoperative and postoperative complications.<sup>1,2,4,8</sup> There are three possible reasons for this high complication rate. First, it may be related to an overzealous attempt to preserve the PTHU. Second, the severe chordee was corrected by shortening the penis rather than transecting the urethra. Third, one-stage urethroplasty was performed regardless of the length of the urethral defect. We reviewed our experience of treating chordee with a PTHU and proposed an algorithm (Fig. 2) for the surgical management of this disorder. Our treatment algorithm serves



**Fig. 2** Algorithm for the management of chordee with PTHU.

as a guideline for the management of this congenital anomaly, thus minimizing the inadvertent intraoperative urethrotomies, in turn reducing the incidence of postoperative complications. We began by opening the ventral part of the paper-thin urethra and degloving the penis, and then excising the tethered ventral tissue and assessing the curvature. An additional dorsal midline plication procedure was performed in patients with persistent mild-moderate curvature. The TIP or OIF urethroplasty was performed in these patients due to the viable of urethral plate. However, patients with a more severe degrees of curvature generally underwent urethral transection and urethroplasty (one or two stages) to achieve penile straightening and penile lengthening. In this study, this treatment algorithm provided a complication rate of only 13.8%. Therefore, we recommend opening the ventral portion of the hypoplastic urethra and choosing the surgical method based on the degree of curvature and urethral plate quality.

In this study, the TIP or OIF technique is effective in the treatment of mild to moderate cases of chordee with a

PTHU (the total complication rate was 11.1%), and the outcome of the TIP technique for these patients was better than that of the OIF technique. Mohajezadeh *et al.* considered that if the urethral plate is narrow, the risk of stricture and fistula in the TIP technique is relatively high.<sup>6</sup> The TIP technique requires an acceptable urethral plate width for urethroplasty.<sup>9</sup> Interestingly, none of the patients in our series had strictures in the TIP group. Based on our experience, the dorsal urethral plate is sufficiently wide and viable after opening the ventral of the paper-thin urethra, and can be used for the TIP technique. In addition, the TIP technique is simpler than the OIF technique.<sup>10</sup> Therefore, we prefer TIP technique for mild-moderate chordee with paper-thin hypoplastic. However, severe chordee with PTHU generally required urethral transection to achieve penile straightening and avoid unacceptable penile shortening. We found that the length of hypoplastic urethral is related to the severity of curvature, the longer the length of hypoplastic urethral, the more serious its curvature. Although in this

severe chordee patients the complication rate (15%) was increased, the outcome of staged urethroplasty seem to be better than that of one stage urethroplasty (10.3% vs 27.3%). Owing to the long learning curve and high complications rates for one stage urethroplasty, most cases choose staged repair in our series.

It is controversial whether to urethral reconstruction for chordee with a PTHU, if the location of the meatus is normal. Bhat *et al.* considered that when chordee with a PTHU is associated with an abnormal meatus, the entire dysplastic urethra should be reconstructed.<sup>11</sup> If the meatus is normal, the urethra may be preserved or reconstructed. However, we considered that in cases of chordee with a PTHU, it is difficult to straighten the penis and preserve the urethra irrespective of whether the location of the meatus is normal or not. If the urethra is preserved, painstaking mobilization of a paper-thin, easily injured urethra from the skin and corporeal bodies is usually required to remove all the chordee tissue laterally and under the urethra. This may lead to significant intraoperative and postoperative complications. In these patients, preservation of the PTHU may be impossible. In our study, we reconstructed the entire hypoplastic urethra after correcting the curvature to effectively avoid intraoperative complications and reduce postoperative complications. Therefore, it is necessary to open the ventral part of the entire hypoplastic urethra, irrespective of whether the location of the meatus is normal or not, and to reconstruct the urethra.

Uroflowmetry is an objective index for assessing lower urinary tract function.<sup>12</sup> Our data showed that maximal uroflowmetry gradually improved over time. This may be the common law of urethral function recovery after hypospadias repair.

Our study had some limitations. This was a retrospective study. In addition, patients need longer follow-up periods to obtain puberty outcomes.

Based on our experience, irrespective of whether chordee with a PTHU is associated with a normal or abnormal meatus location, the entire hypoplastic urethra should be reconstructed after correcting the curvature. The TIP or OIF technique can be used for mild to moderate chordee with a PTHU, the outcome of the TIP technique tends to be better than that of the OIF technique. One-stage or staged urethroplasty is suitable for severe chordee with a PTHU, and the staged technique can improve the overall success rate and reduce complications. A new algorithm is proposed for the management of chordees with a PTHU.

## Acknowledgments

This study is supported by Shenzhen Fund for Guangdong Provincial High-Level Clinical Key Specialties (SZXK035). We thank Jinjin Xie, Weiguang Zhao and Zhilin Yang for revising this manuscript.

## Author contributions

Guanglun Zhou: Data curation; Investigation; Methodology; Writing – original draft; Writing – review & editing. Jianchun Yin: Methodology; Resources; Software; Supervision; Validation.

Junjie Sun: Conceptualization; Data curation; Formal analysis; Project administration; Supervision. Xiaodong Liu: Data curation; Investigation; Methodology; Project administration. Jiahong Su: Data curation; Formal analysis; Project administration; Writing – original draft. Shoulin Li: Methodology; Project administration; Resources; Supervision; Writing – review & editing.

## Conflict of interest

None declared.

## Approval of the research protocol by an Institutional Reviewer Board

Shenzhen Children's Hospital ethics committee (2021033).

## Informed consent

Written informed consent was obtained from the guardians or parents before treatment.

## Registry and the Registration No. of the study/trial

N/A.

## Animal studies

N/A.

## References

- Hurwitz RS, Ozersky D, Kaplan HJ. Chordee without hypospadias: complications and management of the hypoplastic urethra. *J. Urol.* 1987; **138**: 372–5.
- Devine CJ, Horton CE. Chordee without hypospadias. *J. Urol.* 1973; **110**: 264–71.
- Polat EC, Erdem MR, Topakta R, Ersoz C, Onol SY. Our experience in chordee without hypospadias: results of 102 cases. *Urol. J.* 2014; **11**: 1783–7.
- Singh S, Rawat J, Kureel SN, Pandey A. Chordee without hypospadias: operative classification and its management. *Urol. Ann.* 2013; **5**: 93–8.
- Snodgrass WT. Snodgrass technique for hypospadias repair. *BJU Int.* 2005; **95**: 683–93.
- Mohajerzadeh L, Mirshemirani A, Rouzrokh M *et al.* Evaluation of onlay island flap technique in shallow urethral plate hypospadias. *Iran. J. Pediatr.* 2016; **26**: e660.
- Chen C, Yang TQ, Chen JB, Sun N, Zhang WP. The effect of staged transverse preputial island flap urethroplasty for proximal hypospadias with severe chordee. *J. Urol.* 2016; **196**: 1536–40.
- Dipaola G, Spalletta M, Balducci T *et al.* Surgical treatment of chordee without hypospadias. *Eur. Urol.* 2000; **38**: 758–61.
- Salle JLP, Sayed S, Salle A *et al.* Proximal hypospadias: a persistent challenge. Single institution outcome analysis of three surgical techniques over a 10-year period. *J. Pediatr. Urol.* 2016; **12**: 28.e1–7.
- Javid L, Pansota MS, Ahmad I, Tariq M, Tabassum SA. Comparison between tubularised incised plate urethroplasty and onlay island flap repair in mid and proximal penile hypospadias. *J. Pak. Med. Assoc.* 2014; **64**: 415–8.
- Bhat A, Saxena G, Abrol N. A new algorithm for management of chordee without hypospadias based on mobilization of urethra. *J. Pediatr. Urol.* 2008; **4**: 43–50.
- Faure A, Bouty A, Nyo YL, O'Brien M, Heloury Y. Two-stage graft urethroplasty for proximal and complicated hypospadias in children: a retrospective study. *J. Pediatr. Urol.* 2016; **12**: 286.e1–7.