

Oncology

Neoadjuvant chemotherapy and penile conservation in the management of Buschke – Lowenstein tumor, a case report

Anthony El Khoury^{a,b,*}, James C. Jensen, MD^{b,c}, Tony Pacioles, MD^{b,c}

^a St. George's, University of London, UK

^b Marshall University, Joan C. Edwards School of Medicine, USA

^c Edwards Comprehensive Cancer Center, USA



ARTICLE INFO

Keywords:

Buschke-Lowenstein tumor
Penile cancer
Penile surgery
Neoadjuvant chemotherapy
Quality of life

ABSTRACT

Buschke-Lowenstein tumor is a rare form of low-grade penile cancer. Its low prevalence amongst the population bars the establishment of a standardized treatment algorithm. We present a case of BLT that was managed with neoadjuvant chemotherapy followed by phallic sparing surgery.

Introduction

Buschke-Lowenstein Tumor, also known as Giant Condyloma Acuminatum is a rare form of sexually transmitted disease that affecting the anogenital region. BLT is an aggressive locally invading tumor that grows in a wart-like fashion.¹ This tumor is recognized as a form of ano-rectal cancer due to its heterogeneous but low grade, rapid local growth, and features that resemble squamous cell carcinoma.² The disease is more prevalent in men, and risk factors include smoking, having an uncircumcised penis, first sexual experience at the of 16 or less.³ Treatment of BLT varies based on size at presentation, local invasion, and patient preferences. In men, proposed treatments are local radiation therapy, topical chemotherapy with Imiquimod or 5-Fluorouracil, and lesion excision and radical penectomy. This strategy is consistent with the treatment strategy of carcinoma of the penis.⁴ Surgical resection, the preferred treatment modality. The rarity of the tumor prevents the establishment of a treatment algorithm.⁵ We present a case of BLT that was treated with neoadjuvant chemotherapy and multiple local excision with phallic preservation and skin grafting.

Case report

39-year-old white male with a history of tobacco smoking and polysubstance abuse presents to the clinic with a large lesion on the penis and scrotum, after being pulled over by a police officer who was

suspicious of a large bulge in his pants. Physical examination shows a large cauliflower-like mass that is consistent with a BLT (Fig. 1). Treatment options were explained to the patient and an excisional biopsy was scheduled for pathological diagnosis. CT-KUB shows bilateral lymphadenopathy.

Biopsy of the specimen was taken and found to be consistent with verrucous carcinoma of the penis. Surgical debulking vs primary chemotherapy was considered. Due to the complexity of the case, the patient was scheduled for neoadjuvant chemotherapy TIP (paclitaxel- ifosfamide-cisplatin) and surgical debulking. The mass was resected from the penis and the scrotum with roughly negative margins. Hemostasis was difficult to achieve due to the high vascularization of the tumor. A particularly challenging area was below the corona in the frenular area as the mass was tightly adherent to the urethra elevating the risk of urethral entry.

Patient was brought back for secondary debridement of the distal left and right coronal margins, the peripheral margin, and the deep scrotal margin. The operation was carried to conserve the shaft and reconstruct the penis with an autografted flap (Fig. 2). Patient is currently s/p 4 cycles of TIP therapy and 3 separate procedures for excision of recurrent lesions. Pathology of recurrent lesions is consistent with condyloma acuminata is negative for high-grade verrucous carcinoma. Patient complained of the following side effects while receiving chemotherapy: weight loss, anorexia, nausea, arthralgias, and neuropathy of the lower extremities.

* Corresponding author. St. George's, University of London, Marshall University, Joan C. Edwards School of Medicine, 607 22nd Street Apt. 1427, Huntington, WV, 25703, USA.

E-mail addresses: elkhoury@marshall.edu, anthonyelkhoury17@gmail.com (A. El Khoury).

<https://doi.org/10.1016/j.eucr.2019.101111>

Received 6 December 2019; Received in revised form 17 December 2019; Accepted 20 December 2019

Available online 23 December 2019

2214-4420/© 2019 Published by Elsevier Inc. This is an open access article under the CC BY-NC-ND license (<http://creativecommons.org/licenses/by-nc-nd/4.0/>).

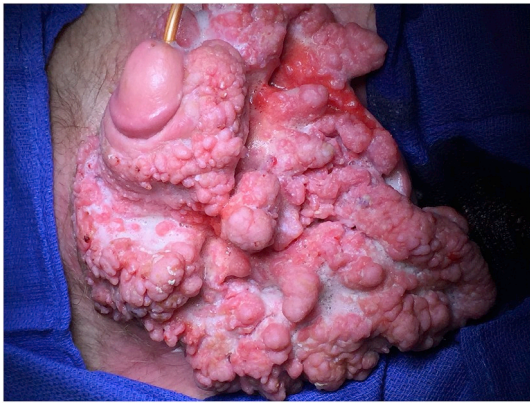


Fig. 1. Tumor on initial physical examination displaying cauliflower-like growth.

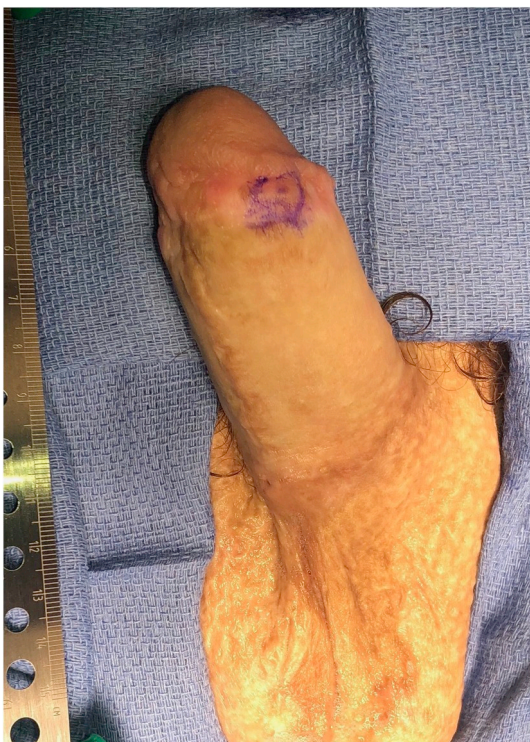

Fig. 2. Patient status post chemical debulking, resection, and skin grafting. Recurrent condyloma acuminatum excised (circled area).

Patient reports painful erections and is under a pain management program.

Discussion

Management of BLT is not a straightforward process. BLT is characterized by it being a low-grade tumor. That, coupled with the sensitivity of the subject of male genitalia, makes the “obvious” choice of a radical penectomy not always suitable as a management plan as it highly impacts quality of life. Although the rarity of the tumor does not allow for a generalized management guideline and algorithm, the delicacy and high-risk of tumor resection with penile conservation is not prevalent

practice. BLT is highly vascular and its erratic and rapid growth makes it difficult to manipulate intra-operatively and substantially increases surgical risks such as bleeding and urethral penetration.

Like most patients, our patient wanted to fight for penile preservation. Their quality of life had been heavily impacted by the tumor especially since they had not experienced intimacy with their partners for years, due to their medical condition. Patient preferences are an important consideration when it comes to management plans and that principle is widely recognized amongst healthcare practitioners. It is therefore important to explore management plans that although impose a higher risk, would yield outcomes that are satisfactory to the patient and that would not contribute to a deterioration of the patient’s quality of life.

The target of surgical resection is to resect a tumor with negative margins, in order to limit the possibilities of local invasion, recurrence, and distal spread. Neoadjuvant chemotherapy allowed us to achieve medical tumor shrinkage which lead to a safer debulking procedure. We therefore recommend neoadjuvant chemotherapy prior to tumor debulking when considering phallic-sparing surgery in the management of BLT. Consistent follow-up is required to ensure the absence of tumor recurrence.

Author contributions

Dr. James C. Jensen: urologist.

Dr. Toni Pacioles: lead medical oncologist.

Mr. Anthony El Khoury: 4th year medical student, data gathering and manuscript development.

Funding

No funding was allocated for the development of this care report.

Consent

The patient has provided consent to the authors for the publication of this case report.

Declaration of competing interest

The authors have no conflicts of interest to declare.

Appendix A. Supplementary data

Supplementary data to this article can be found online at <https://doi.org/10.1016/j.eucr.2019.101111>.

References

1. Talwar A, Puri N, Singh M. Giant condyloma acuminatum of Buschke and Löwenstein: successful surgical treatment. *Int J STD AIDS*. 2010;21(6):446–448. <https://doi.org/10.1258/ijsa.2009.009159>.
2. Chu QD, Vezeridis MP, Libbey NP, et al. Giant condyloma acuminatum (Buschke-Lowenstein tumor) of the anorectal and perianal regions. *Dis Colon Rectum*. 1994;37(950). <https://doi.org/10.1007/BF02052606>.
3. Venter F, et al. Giant condylomata acuminata of Buschke-Lowenstein associated with paraneoplastic hypercalcemia. *J Investig. Med. High Impact Case Rep*. 2018. <https://doi.org/10.1177/2324709618758348>.
4. Fishman MN. Clinical scenarios for neoadjuvant chemotherapy of squamous penile cancer that is clinically node positive. *Transl Androl Urol*. 2017;6(5):839–847, 24 July.
5. Nelson Montana, et al. Giant condyloma acuminatum (Buschke-Lowenstein tumor). Series of seven cases and review of the literature. *Rev Chil Radiol*. 2014;20(2):57–63.