

Available online at [www.sciencedirect.com](http://www.sciencedirect.com)

ScienceDirect

journal homepage: [www.elsevier.com/locate/ihj](http://www.elsevier.com/locate/ihj)

## Case Report

# A novel use of EP catheter in extraction of trapped intracardiac devices: Two case reports



Dilip Kumar<sup>a,\*</sup>, Sunip Banerjee<sup>b</sup>, Jaynarayan Naik<sup>c</sup>, Kinnari Gupta<sup>d</sup>,  
Rana Rathor Roy<sup>e</sup>, Arvind Kumar<sup>e</sup>

<sup>a</sup> Consultant Interventional Cardiologist and Electrophysiologist, Medica Superspecialty Hospital, Kolkata, India

<sup>b</sup> Director, Medica Institute of Cardiac Sciences, Medica Superspecialty Hospital, Kolkata, India

<sup>c</sup> Senior Consultant Interventional Cardiologist, Medica Superspecialty Hospital, Kolkata, India

<sup>d</sup> Registrar, Medica Institute of Cardiac Sciences, Medica Superspecialty Hospital, Kolkata, India

<sup>e</sup> Consultant Interventional Cardiologist, Medica Superspecialty Hospital, Kolkata, India

## ARTICLE INFO

## Article history:

Received 7 October 2014

Accepted 8 September 2015

Available online 18 December 2015

## Keywords:

EP catheter

Retrieval

Pacemaker leads

Permacatheter

Snare

## ABSTRACT

The decision to retrieve chronically implanted abandoned leads and trapped intracardiac devices percutaneously has been difficult and highly controversial. We present two case reports in which electrophysiological ablation catheter was used to retrieve infected abandoned pacemaker lead and trapped permacatheter (permacath) in right ventricle. We could avert major cardiovascular surgeries in both the patients by simply modifying the traditionally used techniques for extraction of intracardiac devices.

© 2015 Cardiological Society of India. Published by Elsevier B.V. All rights reserved.

## 1. Introduction

There was emergence of vascular and intracardiac interventions in the past decade.<sup>1–3</sup> As implant rate of Cardiovascular Implantable Electronic Devices (CIED) continues to rise in most countries, observed complications have increased in parallel.<sup>4</sup> The occurrence of more frequent device system revisions for complications,<sup>4</sup> system upgrades,<sup>5</sup> and/or lead malfunction<sup>6</sup> and longer patient life expectancies have mandated a paradigm shift toward premeditated lead management strategies from

implant to removal or replacement.<sup>7</sup> There has also been increase in incidence of left-out broken catheters or leads of previous CIED. Consequently, clinicians increasingly are faced with the challenging choice of extraction or abandonment of sterile, superfluous leads. Traditionally, forceps, snares, baskets, locking stylets or lead-transection devices and laser sheaths are used to extract leads and fragments. We present first two case reports of use of EP Catheter in retrieval of trapped intracardiac devices (abandoned permanent pacemaker lead and fragment of permacatheter) along with traditional methods.

\* Corresponding author.

E-mail address: [dilipcardio@gmail.com](mailto:dilipcardio@gmail.com) (D. Kumar).

<http://dx.doi.org/10.1016/j.ihj.2015.09.008>

0019-4832/© 2015 Cardiological Society of India. Published by Elsevier B.V. All rights reserved.

## 2. Case report 1

A 55-year-old, normal-built male patient, with permanent pacemaker, presented to the outpatient department with complaints of intermittent fever for the past six months. He had past medical history of type 2 diabetes mellitus and the pacemaker was implanted 8 years back. Pulse generator was removed and permanent pacemaker reimplantation was done with new leads 8 months back. Patient developed infected wound at PPI site with sinus cavity, which was operated after one month of pacemaker reimplantation. Patient was asymptomatic for one month, but later, he developed high-grade fever, and was treated by various physicians. Recent transeophageal echocardiography revealed multiple small vegetations attached to PPI leads, and two months back, blood culture grew *Staphylococcus aureus*, and the patient was advised open cardiotomy for chronically implanted leads removal. Patient was asymptomatic and his blood culture was sterile when he presented to us. Patient was admitted in cardiothoracic surgery department for cardiotomy. After discussion with cardiothoracic surgery department, endovascular approach was successfully tried and permanent device was safely reimplanted in the same sitting. As seen in Fig. 1, there was one pacemaker lead and another abandoned lead (two ventricular leads); we took out the lead connected with pulse generator (functional lead) using standard procedure of retrieval. After local dissection over the pacemaker, the lead was unscrewed and stylet was passed and lead could be brought out easily with gentle traction. The other old lead with implant duration of 84 months had one end into right ventricle (RV) and other end lying around superior vena cava (SVC) and subclavian junction. The 7-French (7F) EP ablation catheter was used as shown in Fig. 2 to hook the lead and pull into the Inferior vena cava (IVC), which was in turn caught with snare and taken out through right femoral vein. There was only TPI

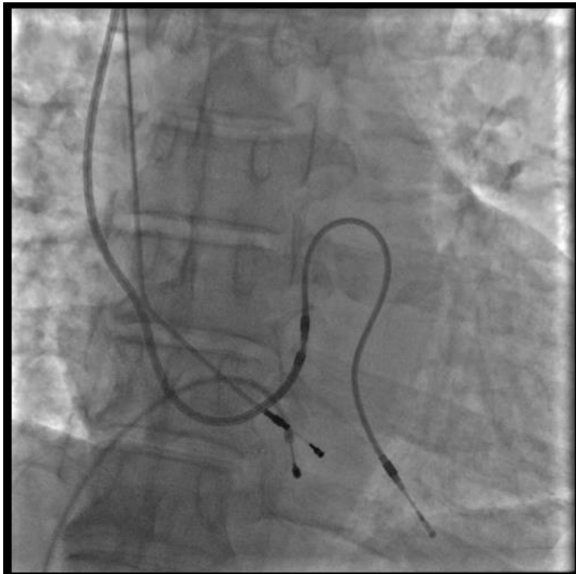


Fig. 1 – Two old ventricular leads with temporary pacemaker lead in place.

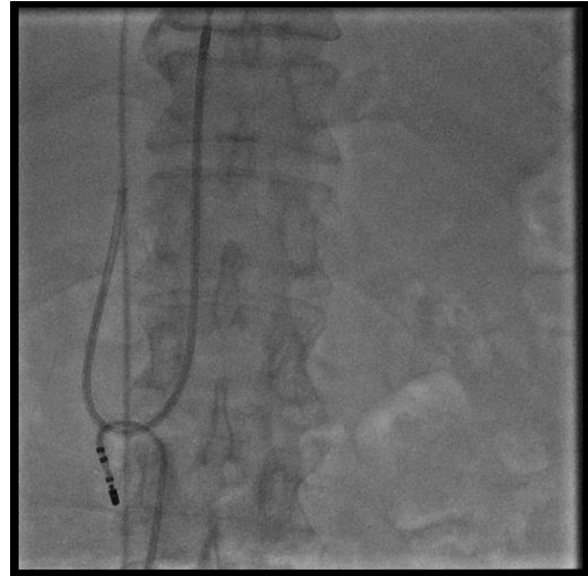

Fig. 2 – EP catheter hooking the old ventricular lead.

lead seen in Fig. 3. The extraction time for this lead was 10 min and fluorotime was 25 min. There was no periprocedural complication.

## 3. Case report 2

A 25-year-old female patient who was on regular hemodialysis, with permacath implanted three months back, presented with complaints of fever that was lasting for the past two weeks. Patient was a known case of systemic lupus erythematosus and membranoproliferative glomerulonephritis, and

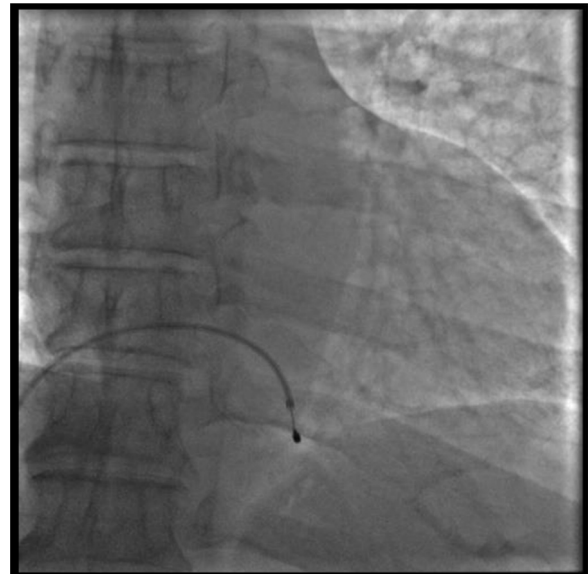


Fig. 3 – Old pacemaker leads removed and temporary pacemaker lead in place.

was on dialysis for the past 3 years. Patient had a past history of tuberculosis and aortic valve replacement surgery was done 5 years back. The decision to take out permacath was taken, as no other evident reason for fever was found. While taking out the permacath, a fragment of it was mistakenly left inside the venous system. After a failed attempt of local retrieval of the left out permacath by the surgeon, endovascular retrieval was tried. As seen in Fig. 4, one end of the permacath was in RV and other end was in Jugular vein. To facilitate snaring from femoral vein, we needed at least one free end hanging into IVC or Right Atrium. We tried diagnostic EP catheter but it failed to give much traction. Then we used 7F ablation catheter to hook the permacath (Fig. 5) and was pulled out into IVC following which the IVC end was caught with snare and brought out. EP catheter was used to hook the trapped permacath to bring it into the IVC because of its ability to change the curve distally. Total duration of the extraction was 18 min and fluorotime was only 4 min. Fig. 6 shows the extracted fragment of the permacath. There was no periprocedural complication.

## 4. Discussion

### 4.1. Review of contemporary extraction methods

Historically, there were no specialized tools for lead extraction. Pulling force in the form of simple traction or occasionally through weights and a pulley system was given to slowly break the lead free of its attachments. However, these techniques often failed, which resulted in broken leads with fragments left behind or damage to vital body structures and serious complications. As a modification, tools like standard stylets (nonlocking), snares, sutures, grasping or other devices, and fixation screws have been used to make lead extraction safer and more successful. Sheaths made of metal, Teflon, polypropylene, or other materials that require manual advancement

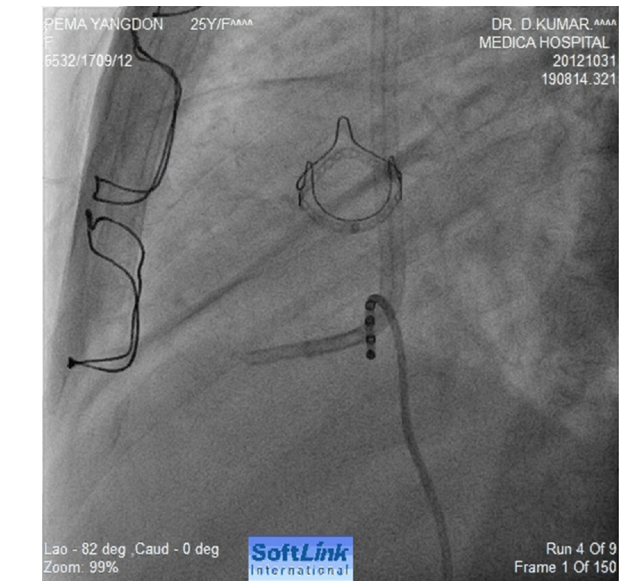


Fig. 5 – EP catheter hooking the permacatheter.

over the lead are also used relying on force to free the lead and are much more effective than simple traction. Laser Sheaths, which employ fiberoptics to transmit laser light, and Electro-surgical Sheaths that use radiofrequency energy to disrupt the fibrotic attachments are other modifications with reasonable success rate.<sup>8-13</sup> Rotating Threaded Tip Sheath and Telescoping Sheaths are also described. (These sheaths use mechanical (standard polypropylene or newer rotational Evolution™ sheaths), electrical (Electrosurgical Dissection Sheath, Perfecta®), or laser photoablative energy (Spectranetics, Inc.) to pass through the binding site. The goal is to safely advance the sheath through the binding sites and vasculature to the electrode–myocardial interface.)

The sheaths can be introduced either through the implant site (least chances of infection, single-site access), or where

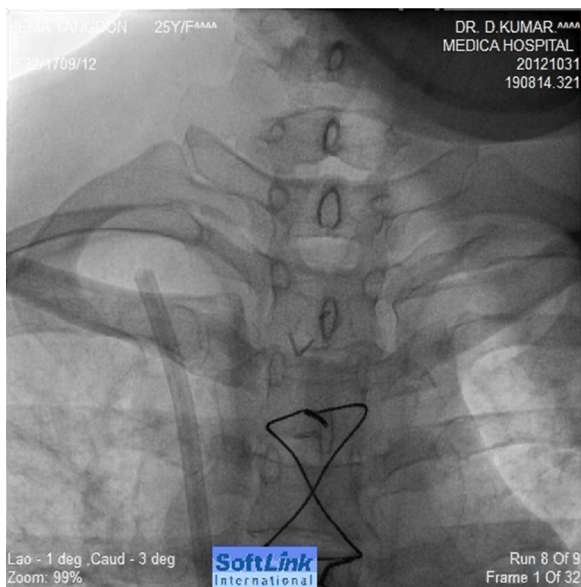


Fig. 4 – Trapped fragment of permacatheter into right ventricle and superior vena cava.




Fig. 6 – Retrieved fragment of permacatheter.



extensive lead adhesion with underline vasculature is suspected, and internal jugular and femoral routes can be used (more straight in approach: leads freed from access site, "snared" to IJV/femoral vein).

Extraction from the femoral route may be required if the lead has been completely severed, although some operators prefer the femoral approach as their primary method of extraction. Using one of a variety of snares and guidewires, the lead may be grasped and pulled down into the atrium or inferior vena cava. At this point, the free end of the lead can be grasped in a snare and pulled into the femoral sheath. The sheath is advanced to provide countertraction as necessary and the lead is removed. This approach is often best for attempting to grasp fragments of a lead that has fallen apart during an extraction attempt from above.

#### 4.2. Complications of contemporary extraction methods

Complications from lead extraction are primarily related to the possibility of damage to the venous system and myocardium. The death rate should be in the range of 0.3%, with other major complications <1.5%.<sup>14</sup> Major complications include death, cardiac avulsion or tear, vascular tear, and pulmonary embolism. Death is almost always due to rapid and massive blood loss. Pericardial tamponade and tears in the venous system that are above the pericardial reflection resulting in massive hemothorax are other known significant complications. It is for these reasons that preparation for such complications must be made.

Minor complications like venous thrombosis, pocket hematoma, vascular damage at the extraction site requiring repair, air embolism, migration of lead fragment, and minor hemothorax or pneumothorax require prompt treatment, but are usually not life threatening in most instances.

#### 4.3. Recent developments

With the development of the discipline and guidelines,<sup>15</sup> we have witnessed a growth in the community of transvenous lead extraction (TLE) experts coincident with a marked decline in the incidence of procedure-related morbidity and mortality, with more recent registries at high-volume centers reporting high success rates with exceedingly low complication rates.

Coming back to our cases, there was no periprocedural complication in any of them. Regarding the second case, pigtail could have been used but there is risk of entanglement with it while EP ablation catheter can be hooked and looped easily around the lead. Use of laser sheaths<sup>16</sup> has been documented but that option is not feasible and economical in developing countries where resources are limited and also it is possible only when at least one end is accessible from the subclavian, jugulars, or cephalic vein. Other techniques<sup>15</sup> used for extraction like snare, baskets, and counter pressure are possible only when free end is available for traction.

## 5. Conclusion

There are clear shortcomings between extraction guidelines and actual practice. Newer lead extraction technology has

always been a clinical requirement and technical expertise is required to match these rising proportions of need for extractions. Simple novel use of EP catheter to retrieve intracardiac devices along with standard technique can be an effective and safe method. This method can significantly reduce the number of major cardiovascular surgeries and related complications.

## Conflicts of interest

The authors have none to declare.

## Acknowledgement

The authors thank Mr. Arnab De.

## REFERENCES

- Hammill SC, Kremers MS, Kadish AH, et al. Review of the ICD Registry's third year, expansion to include lead data and pediatric ICD procedures, and role for measuring performance. *Heart Rhythm*. 2009;6:1397-1401.
- Maisel WH, Moynahan M, Zuckerman BD, et al. Pacemaker and ICD generator malfunctions: analysis of Food and Drug Administration annual reports. *J Am Med Assoc*. 2006;295:1901-1906.
- DeFrances CJ, Lucas CA, Buie VC, et al. National hospital discharge survey. *Natl Health Stat Report*. 2006;2008:1-20.
- Eckstein J, Koller MT, Zabel M, et al. Necessity for surgical revision of defibrillator leads implanted long-term: causes and management. *Circulation*. 2008;117:2727-2733.
- Vatankulu MA, Goktekin O, Kaya MG, et al. Effect of long-term resynchronization therapy on left ventricular remodeling in pacemaker patients upgraded to biventricular devices. *Am J Cardiol*. 2009;103:1280-1284.
- Haqqani HM, Mond HG. The implantable cardioverter-defibrillator lead: principles, progress, and promises. *Pacing Clin Electrophysiol*. 2009;32:1336-1353.
- Maytin M, Epstein LM, Henrikson CA, et al. Lead extraction is preferred for lead revisions and system upgrades: when less is more. *Circ Arrhythm Electrophysiol*. 2010;3:413-424.
- Anderson JM. Inflammatory response to implants. *ASAIO J*. 1988;11:101-107.
- Al-Khadra AS, Wilkoff BL. Extraction of transvenous pacemaker and defibrillator leads. In: Singer I, ed. *Interventional electrophysiology* 2nd ed. 2001; 819-841 [chapter 34, Implantable Cardioverter-Defibrillators and Pacemakers].
- Smith MC, Love CJ. Extraction of transvenous pacing and ICD leads. *Pacing Clin Electrophysiol*. 2008;31:736-752.
- Wilkoff BL, Byrd CL, Love CJ, et al. Pacemaker lead extraction with the laser sheath: results of the pacing lead extraction with the excimer sheath (PLEXES) trial. *J Am Coll Cardiol*. 1999;33:1671-1676.
- Epstein LM, Byrd CL, Wilkoff BL, et al. Initial experience with larger laser sheaths for the removal of transvenous pacemaker and implantable defibrillator leads. *Circulation*. 1999;100:516-525.
- Kennergren C, Bucknall CA, Butter C, et al. PLESSE investigators group. *Europace*. 2007;9:651-656.

14. Wazni O, Epstein LM, Carrillo RG, et al. Lead extraction in the contemporary setting: the LEXICON study an observational retrospective study of consecutive laser lead extractions. *J Am Coll Cardiol*. 2010;55:579-586.
15. Deharo JC, Bongiorni MG, Rozkovec A, et al. Pathways for training and accreditation for transvenous lead extraction: a European Heart Rhythm Association position paper. *Europace*. 2012;14:124-134.
16. Laurence M, Epstein. Charles L, et al. Initial experience with larger laser sheaths for the removal of transvenous pacemaker and implantable defibrillator leads. *Circulation*. 1999;100:516-525.