

CASE REPORT

Disseminated peritoneal leiomyomatosis as an incidental finding: A case report

Emmanuel D Morgan¹ | Mohamed Kahiye² | Isaiah Kule³ | James J Yahaya⁴  | Emmanuel Othieno¹

¹Faculty of Medicine, Department of Pathology, Soroti University, Soroti, Uganda

²Department of Pathology, College of Health Sciences, Simad University, Mogadishu, Somalia

³Bundibugyo District Hospital, Bundibugyo, Uganda

⁴Department of Histopathology and Morbid Anatomy, School of Medicine and Dentistry, University of Dodoma, Dodoma, Tanzania

Correspondence

James J Yahaya, Department of Histopathology and Morbid Anatomy, School of Medicine and Dentistry, University of Dodoma, 395, Dodoma, Tanzania.
Email: mashimba2009@yahoo.com

Funding information

This research did not receive any specific grant from funding agencies in the public, commercial, or not-for-profit sectors.

Abstract

We present the case of a 23-year-old female with multiple diffuse and nodular masses of different sizes involving predominantly the posterior wall of the uterus, omentum, and peritoneum which were histopathologically confirmed to be disseminated peritoneal leiomyomatosis. Meticulous investigation and accurate diagnosis are of utmost importance for the establishment of the correct diagnosis. Additionally, proper management of the patient while considering choice of the patients including close follow-up of the patients is mandatory for the reason of ensuring early detection of recurrence.

KEYWORDS

disseminated peritoneal leiomyomatosis, incidental finding, uterus

1 | INTRODUCTION

Disseminated peritoneal leiomyomatosis (DPL) also known as leiomyomatosis peritonealis disseminate is a rare benign disorder characterized by the presence of multiple smooth muscle nodules disseminated throughout the peritoneal cavity.¹ It was first described in 1952 by Wilson and Peale.² This rare disorder appears as multiple small nodules of different sizes on or beneath the peritoneal surface, mimicking a malignancy, though histologically

it demonstrates benign features.^{1,2} It occurs more commonly in younger women with a history of uterine leiomyomas.¹ Since 1952, over 100 cases have been described in the English literature, although the pathogenesis of this disorder remains unknown, a relationship with hormonal factors including pregnancy, oral contraceptives, and rarely, granulosa cell tumors of the ovary so far have been suggested.^{2,3}

Laparoscopic myomectomy for the treatment of uterine leiomyomas has also been implicated in the development

This is an open access article under the terms of the Creative Commons Attribution-NonCommercial License, which permits use, distribution and reproduction in any medium, provided the original work is properly cited and is not used for commercial purposes.

© 2022 The Authors. *Clinical Case Reports* published by John Wiley & Sons Ltd.

of DPL due to dissemination of the tumor cells along the laparoscopic tract.^{4,5} While younger premenopausal female patients are most commonly affected with DPL, the condition occurs rarely in both men and postmenopausal women in whom there is no excess of hormonal levels. Rare cases of malignant transformation have also been reported.⁶⁻⁸ Preoperative diagnosis of DPL is virtually impossible since most of the patients are asymptomatic, and it is usually incidentally diagnosed during surgery. Therefore, intraoperatively, it can easily be confused with disseminated intra-abdominal malignancies.⁹ Clinically and radiologically, the most important differential diagnoses include peritoneal carcinomatosis, which typically manifests with metastatic disease, weight loss, ascites, and rapid progression of disease. Others include malignant peritoneal mesothelioma, and primary peritoneal serous carcinoma.¹⁰

In this report, we present the case of a 23-year-old female patient with DPL who was diagnosed incidentally during an emergency Cesarean section. In addition, we reviewed the literature regarding clinical characteristics, diagnosis, management, and prognosis.

2 | CASE PRESENTATION

A 23-year-old female, gravida 3 para 2+0 patient with two previous scars which were due to Cesarean section caused by persistent occipito-posterior presentation and sizable of the unborn child. Her antenatal period was uncomplicated, and she had ultrasound done three times during the course of her present pregnancy. None of the three obstetric ultrasounds done during her pregnancy could detect the masses. In addition, she did not have any abdominal complaints prior to and during pregnancy.

During the 38th week of her gestational age, 1 week prior her expected date of delivery, she was rushed to a health center as an emergency patient where she was taken to the labor ward.

Immediately, she was transferred to the operation theater where emergency Caesarean section was performed. Intraoperatively, the placenta, both posterior and anterior aspects of the uterus, omental, and peritoneum were involved by nodular masses of different size which were noted to be arising predominantly from the posterior wall of the uterus, though a few of them were also seen to be arising from the anterior wall of the uterus. The exophytic nodular masses were gray whitish in color, rubbery, and they appeared to extend from the uterus over the bowel, and the peritoneum with finger-like projections grossly (Figure 1). Also, unilateral adhesions of the masses to the left adnexa were noted. Due to diffuse nature of the masses, their exact size could not be determined.

Due to lack of a pathologist at the health center where she was operated; therefore, this required part of the mass and peritoneal washings to be taken to a tertiary hospital for histopathological evaluation.

Gross examination of the specimens submitted showed grossly three small pieces of tissue. The largest and smallest pieces of tissue measured 2.5 cm and 1.0 in their greatest diameter, respectively. The masses were gray-white in color, firm, and nodular. Their cut surface showed homogenous white and fibrous. Neither hemorrhage nor necrosis was noted. Microscopically, the hematoxylin and eosin-stained sections showed low-grade proliferation of spindle-shaped cells with fascicular appearance and they were forming small and large nodules. The spindle cells showed no cytological atypia, mitoses, hemorrhage, and necrosis. There were focal areas of decidual reaction (Figure 2A,B). All the three specimens submitted showed similar features, and there was no evidence of malignancy. Histopathological diagnosis of disseminated peritoneal leiomyomatosis was made. Furthermore, the immune reactivity to SMA, estrogen, and low Ki67 of about 2% confirmed the diagnosis of DPL.

Seven days postoperatively, the patient had an uneventful recovery period and hospital course, and she was discharged home on 50 mg of diclofenac tabs and 650 mg

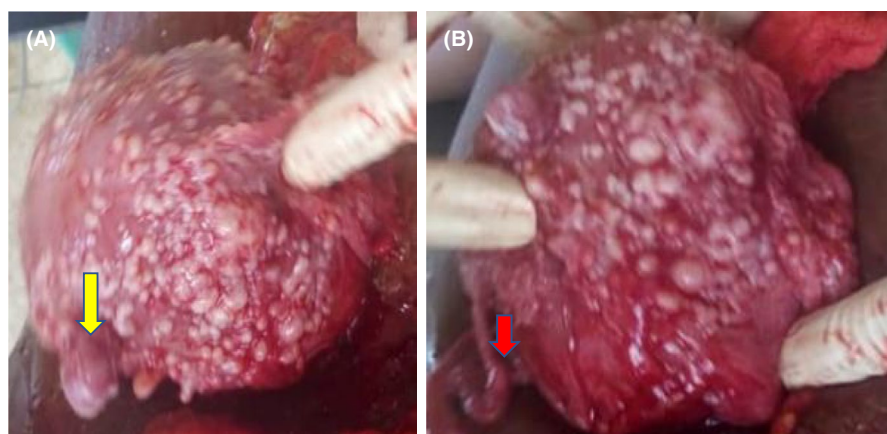


FIGURE 1 (A) Anterior wall of the uterus showing multiple nodular gray-white and rubbery masses of different sizes (yellow arrow). (B) Posterior wall of the uterus showing multiple nodular gray-white and rubbery masses of different sizes and the right fallopian tube (red arrow)

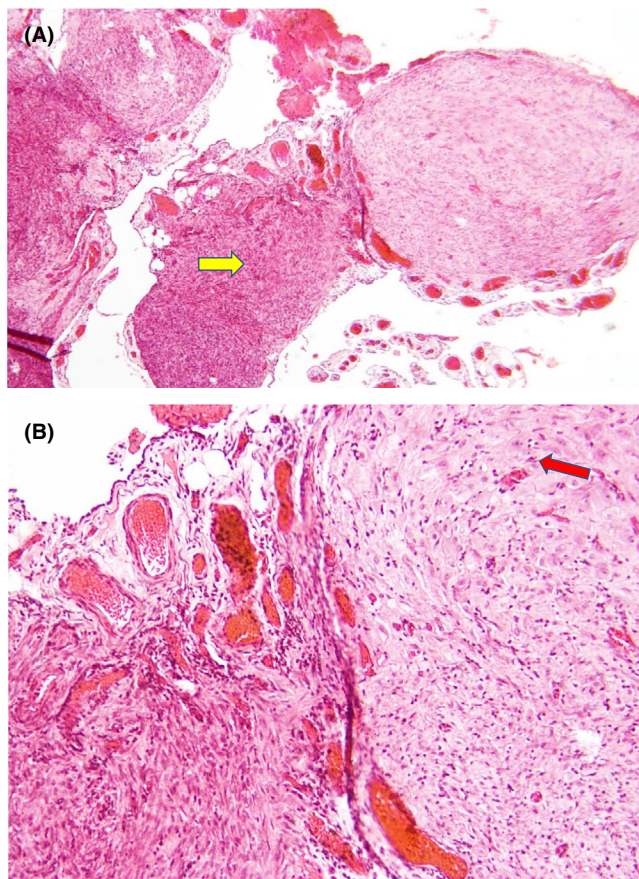


FIGURE 2 (A) Photomicrograph showing DPL composed of multiple nodules of smooth muscle cells (yellow arrow), stromal cells resembling decidua, and multiple congested blood vessels (red arrow; hematoxylin and eosin stain, $\times 100$). (B) Photomicrograph showing higher magnification of DPL composed of proliferation fascicles of bland spindle-shaped cells with no atypia or mitosis (yellow arrow) and stromal cells with decidua-like change (red arrow; hematoxylin and eosin stain, $\times 100$)

of amoxiclav for 3 and 7 days, respectively. She was followed up for 9 months, and her follow-up period was unremarkable.

3 | DISCUSSION

Disseminated peritoneal leiomyomatosis is a rare condition of smooth muscle which tends to disseminate throughout the abdomen and pelvis and it commonly affects women of child bearing age.¹¹ However, few number of cases of DPL in males have been reported, and some of them had malignant transformation.⁸ As it was highlighted previously, an increase in hormone levels especially estrogen and progesterone and the sensitivity of susceptible neoplastic smooth muscle cells, all these have been suggested as etiological factors for these lesions.¹² DPL is usually asymptomatic and it is normally

discovered as an incidental finding, and both tissue sections and peritoneal washings play an important role in establishing the diagnosis and of course ruling out for malignancy. This tumor is traditionally considered benign, but several cases of malignant transformation have been reported, and most of them are a result of recurrency following surgical treatment.¹³⁻¹⁶ The present case showed no recurrency even after a period of 9 months after surgery.

The histopathological findings in our case were consistent with benign smooth muscle proliferation, and malignancy was ruled out. Furthermore, the immune reactivity for SMA, estrogen, and low Ki67 of about 2% confirmed the diagnosis of DPL, and leiomyosarcoma was ruled out which is one of the differential diagnoses.¹⁷ Due to possible risk of malignant transformation for DPL lesions, close follow-up is crucial in patients with DPL. In this case, the patient reported no any complaints, and there were no complications 9 months postoperatively. Treatment may involve both hormonal therapy and surgical resection. In 2015, a case of estrogen and progesterone sensitive DPL was reported,¹⁸ supporting the etiological theory of hormonally responsive smooth muscle tumors. Conversely, a decrease in estrogen and progesterone has shown to decrease tumor size, further supporting hormonal responsiveness theory.¹⁸

Therefore, total abdominal hysterectomy, salpingo-oophorectomy, omentectomy, and debulking surgery have been reported to be the best options for women patients that do not plan to conceive.^{11,12} Alternatively, non-surgical options involve limiting hormonal exposure which have been shown to decrease tumor size.¹⁸ These include avoiding oral contraceptives and hormone replacement therapy.¹⁹ When DPL is not managed properly it can lead to complications such as bleeding, chronic constipation, and infertility.²⁰⁻²² Therefore, the management of DPL should be based on patient's preference and future plan for pregnancy. In this case, the patient wishes to have another child, hence alternative non-surgical option of limiting hormone exposure such as avoiding oral contraceptives, and hormone replacement therapy was advised.¹⁹

4 | CONCLUSION

Disseminated peritoneal leiomyomatosis is a rare and commonly a benign condition, however, with a high risk of recurrence, malignant transformation, and even metastasis. Meticulous investigation and accurate diagnosis are of utmost importance for the establishment of the correct diagnosis. Additionally, proper management of the patient while considering choice of the patients including close follow-up of the patients is mandatory for the reason of ensuring early detection of recurrence.

ACKNOWLEDGEMENT

We are grateful to a team of surgeons and gynecologists at Bundibugyo District Hospital for their support.

CONFLICT OF INTEREST

The authors have no conflict of interest to declare.

AUTHOR CONTRIBUTIONS

EMD performed histological and immunohistochemical testing, reviewed the literature critically, and wrote the first draft; KI performed the Cesarean section, obtained the consent for the publication of the case, and wrote the first draft; JJY designed the study, performed critical literature, and wrote the first draft; EO supervised the work and performed literature review. All authors revised the final version and they agreed for its intellectual content.

ETHICAL APPROVAL

We confirm that the publication of the case details did not require institutional approval.

CONSENT

We confirm that a written informed consent was provided by the parent to have the case details and any accompanying images to get published.

DATA AVAILABILITY STATEMENT

The data regarding the patient reported in this paper are available upon request from the corresponding author.

ORCID

James J Yahaya  <https://orcid.org/0000-0003-3647-5262>

REFERENCES

1. Tanaka YO, Tsunoda H, Sugano M. MR and CT findings of leiomyomatosis peritonealis disseminata with emphasis on assisted reproductive technology as a risk factor. *Br J Radiol*. 2009;82(975):e44-e47.
2. Willson JR, Peale AR. Multiple peritoneal leiomyomas associated with a granulosa-cell tumor of the ovary. *Am J Obstet Gynecol*. 1952;64(1):204-208.
3. Tavassoli FA, Norris HJ. Peritoneal leiomyomatosis (leiomyomatosis peritonealis disseminata): a clinicopathological study of 20 cases with ultrastructural observations. *Int J Gynecol Pathol*. 1982;1:59-74.
4. Fasih N, Shanhogoe A, Macdonald DB, et al. Leiomyomas beyond the uterus: unusual locations, rare manifestations. *Radiographics*. 2008;28(7):1931-1948.
5. Kumar S, Sharma JB, Verma D, et al. Disseminated peritoneal leiomyomatosis: an unusual complication of laparoscopic myomectomy. *Arch Gynecol Obstet*. 2008;278(1):93-95.
6. Fulcher AS, Szucs RA. Leiomyomatosis peritonealis disseminata complicated by sarcomatous transformation and ovarian torsion: presentation of two cases and review of the literature. *Abdom Imaging*. 1998;23:640-644.
7. Lausen I, Jensen OJ, Andersen E, Lindahl F. Disseminated peritoneal leiomyomatosis with malignant change, in a male. *Virchows Arch A Pathol Anat Histopathol*. 1998;417:173-175.
8. Yamaguchi T, Imaumra Y, Yamamoto T, Fukuda M. Leiomyomatosis peritonealis disseminate with malignant change in a man. *Pathol Int*. 2003;53:179-185.
9. Papadatos D, Taourel P, Bret PM. CT of leiomyomatosis peritonealis disseminata mimicking peritoneal carcinomatosis. *Am J Roentgenol*. 1996;167:475-476.
10. Levy AD, Arnáiz J, Shaw JC, Sobin LH. Primary peritoneal tumors: imaging features with pathologic correlation. *Radiographics*. 2008;28:583-586.
11. Ordulu Z, Dal Cin P, Chong WW, et al. Disseminated peritoneal leiomyomatosis after laparoscopic supracervical hysterectomy with characteristic molecular cytogenetic findings of uterine leiomyoma. *Genes Chromosomes Cancer*. 2010;49(12):1152-1160.
12. Toriyama A, Ishida M, Amano T, et al. Leiomyomatosis peritonealis disseminata coexisting with endometriosis within the same lesions: a case report with review of the literature. *Int J Clin Exp Pathol*. 2013;6(12):2949-2954.
13. Żyła MM, Dzieńiecka M, Kostrzewa M, et al. Leiomyomatosis peritonealis disseminata of unusual course with malignant transformation: case report. *Acta Obstet Gynecol Scand*. 2015;94(2):220-223.
14. Sharma P, Chaturvedi KU, Gupta R, Nigam S. Leiomyomatosis peritonealis disseminata with malignant change in a postmenopausal woman. *Gynecol Oncol*. 2004;95(3):742-745.
15. Morizaki A, Hayashi H, Ishikawa M. Leiomyomatosis peritonealis disseminata with malignant transformation. *Int J Gynaecol Obstet*. 1999;66(1):43-45.
16. Abulafia O, Angel C, Sherer DM, et al. Computed tomography of leiomyomatosis peritonealis disseminata with malignant transformation. *Am J Obstet Gynecol*. 1993;169(1):52-54.
17. Momtahan M, Nemati M, Safaei A. Disseminated peritoneal leiomyomatosis. *Iran J Med Sci*. 2011;36(1):57-59.
18. Wu C, Zhang X, Tao X, et al. Leiomyomatosis peritonealis disseminata: a case report and review of the literature. *Mol Clin Oncol*. 2016;4(6):957-958.
19. Heinig J, Neff A, Cirkel U, Klockenbusch W. Recurrent leiomyomatosis peritonealis disseminata after hysterectomy and bilateral salpingo-oophorectomy during combined hormone replacement therapy. *Eur J Obstet Gynecol Reprod Biol*. 2003;111(2):216-218.
20. Bayrak S, Pasaoglu E, Cakar E, et al. Disseminated peritoneal leiomyomatosis with chronic constipation: a case report. *J Med Case Rep*. 2014;3(8):114.
21. Klemi P, Alanen K, Hietanen S, et al. Response of estrogen receptor-positive intraabdominal fibromatosis to aromatase inhibitor therapy. *Obstet Gynecol*. 2003;102(5 Pt 2):1155-1158.
22. Hallock L, Mayer AR. Leiomyomatosis peritonealis disseminata after robotic myomectomy with power morcellation [10G]. *Obstet Gynecol*. 2016;127(5):61S.

How to cite this article: Morgan ED, Kahiye M, Kule I, Yahaya JJ, Othieno E. Disseminated peritoneal leiomyomatosis as an incidental finding: A case report. *Clin Case Rep*. 2022;10:e05541. doi:[10.1002/ccr3.5541](https://doi.org/10.1002/ccr3.5541)