



# Two case reports of preoperative selective artery embolization with robotic-assisted thoracoscopic lobectomy for chronic cavitary pulmonary aspergillosis: technology, safety and short-term outcomes

Xiaoting Tao<sup>#^</sup>, Qinlang Shi<sup>#</sup>, Zhaohua Xia, Qiang Fu, Shuo Zheng, Kun Qiao

Department of Thoracic Surgery, The Third People's Hospital of Shenzhen, Shenzhen, China

*Contributions:* (I) Conception and design: K Qiao; (II) Administrative support: K Qiao, Z Xia, S Zheng; (III) Provision of study materials or patients: K Qiao, Q Shi; (IV) Collection and assembly of data: X Tao, Z Xia; (V) Data analysis and interpretation: K Qiao, X Tao, Q Fu; (VI) Manuscript writing: All authors; (VII) Final approval of manuscript: All authors.

<sup>#</sup>These authors contributed equally to this work.

*Correspondence to:* Kun Qiao. Department of Thoracic Surgery, The Third People's Hospital of Shenzhen, No. 29 Bulan Road, Longgang District, Shenzhen, China. Email: szqiaokun@163.com.

**Background:** Minimally invasive surgical resection is a possible radical treatment for pulmonary aspergillosis; however, it is difficult and can be accompanied by a variety of complications, especially in chronic cavitary pulmonary aspergillosis (CCPA). Selective artery embolization is usually conducted as palliative management or emergent control of hemoptysis in CCPA. In this report, we share our experience of 2 CCPA patients who underwent preoperative selective artery embolization followed by robotic-assisted thoracoscopic lobectomy.

**Case Description:** Two male patients with post-tuberculosis CCPA had recurrent hemoptysis. They underwent preoperative selective artery embolization and robotic-assisted thoracoscopic lobectomy in July–August 2022. The intraoperative blood loss volumes for the 2 patients were 160 and 200 mL, respectively. Both patients had good short-term outcomes, and the post-operative stays for each patient were 15 and 9 days, respectively.

**Conclusions:** Robotic-assisted thoracoscopic lobectomy following selective artery embolization is a potential safe and effective treatment for CCPA. Robotic resection has a number of advantages, including the dexterity, the sharp, 3-dimensional, and magnified vision, and a minimally invasive procedure. Selective preoperative feeding artery embolization can reduce intraoperative bleeding and provide a clearer surgical vision, thus facilitating minimally invasive approaches. We expect further systematic clinical researches to validate the conclusion.

**Keywords:** Aspergillosis; robotic surgical procedures; embolization; case report

Submitted Oct 19, 2022. Accepted for publication Dec 19, 2022.

doi: 10.21037/atm-22-6040

View this article at: <https://dx.doi.org/10.21037/atm-22-6040>

<sup>^</sup> ORCID: 0000-0001-8280-9249.

## Introduction

The response of chronic pulmonary aspergillosis (CPA) patients to antifungal therapy is slow and incomplete (1). Surgical resection is considered the definitive treatment for CPA. Compared to single pulmonary aspergilloma (SPA), surgery for chronic cavitary pulmonary aspergillosis (CCPA) and chronic fibrosing pulmonary aspergillosis is much more difficult because of the abnormal vessels, adherent pleura, and indurated hilar structures. Minimally invasive surgical approaches, especially robotic-assisted thoracoscopic surgery (RATS), have shown their strengths of dexterity and sharp vision in surgeries of oncologic lung diseases. However, few articles have reported on RATS in the treatment of pulmonary aspergillosis (2,3). Selective artery embolization is usually conducted as palliative management or emergent control of hemoptysis in CCPA (1); meanwhile, it can also greatly reduce intraoperative hemorrhages in the dissection of vascular adhesions, thus providing safety and clear vision for the subsequent surgery (4). In this article, we report 2 CCPA cases who received selective artery embolization followed by RATS lobectomy. To our knowledge, it is the first report concerning this surgical strategy in the treatment of CCPA. We present the following article in accordance with the CARE reporting checklist (available at <https://atm.amegroups.com/article/view/10.21037/atm-22-6040/rc>).

### Highlight box

#### Key findings

- It is potentially safe and effective to conduct preoperative selective artery embolization with robotic-assisted thoracoscopic lobectomy for the treatment of chronic cavitary pulmonary aspergillosis (CCPA).

#### What is known and what is new?

- Robotic-assisted thoracoscopic resection (RATS) has a number of advantages in the treatment of CCPA. However, it is difficult to manage the dense vascular adhesions;
- Through our experience of these two CCPA cases, preoperative selective artery embolization can prevent severe intraoperative bleeding, thus providing a clearer surgical vision to facilitate robotic resections.

#### What is the implication, and what should change now?

- Preoperative selective artery embolization followed by RATS can be one of the treatment options for CCPA. And further systematic clinical researches are expected to validate that.

## Case presentation

### Ethics approval

All the procedures performed in this study were conducted in accordance with the ethical standards of The Medical Ethical Committee of The Third People's Hospital of Shenzhen (approval No. 2022-100-02) and with the Declaration of Helsinki (as revised in 2013). Written informed consent was obtained from the patients for publication of this case report and accompanying images. A copy of the written consent is available for review by the editorial office of this journal.

### Case 1

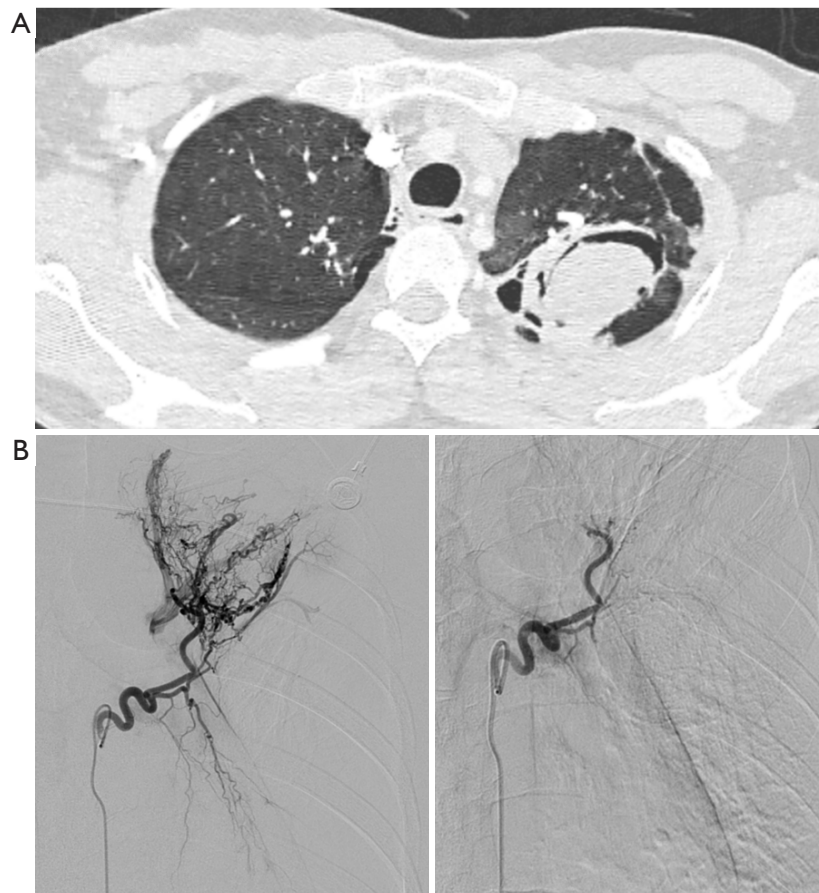
A 32-year-old male, who had suffered from lung tuberculosis and hemoptysis 10 years ago, had been diagnosed with pulmonary aspergillosis 2 years earlier based on an aspergilloma and fibrocavitary lesion in the left upper lobe, and microbiological evidence from bronchoalveolar lavage fluid. Against medical advice, the patient discontinued his oral voriconazole treatment, and the hemoptysis became aggravated by up to 200 mL at a time. On July 14, 2022, the patient attended the Department of Thoracic Surgery, Third People's Hospital, and immediately received tranexamic acid and oral voriconazole. On July 18, 2022, he underwent selective left bronchial artery embolization with 560- and 710- $\mu$ m polyvinyl alcohol (PVA) particles. On July 23, 2022, he underwent an RATS lobectomy of the left upper lobe (*Figure 1*).

### Case 2

A 21-year-old male with post-tubercular aspergillosis had suffered from recurrent hemoptysis for over 2 months. On July 28, 2022, he attended the Department of Thoracic Surgery, Third People's Hospital. Chest computed tomography (CT) showed multiple cavities with irregular edges, thick walls, and fungus balls in his right upper lobe. On July 29, 2022, the patient underwent preoperative embolization in his right bronchial artery and 2nd–4th right intercostal arteries (500- $\mu$ m PVA particles). On August 3, 2022, he received RATS right upper lobectomy.

### Operative technique

Vascular and interventional physicians conducted the



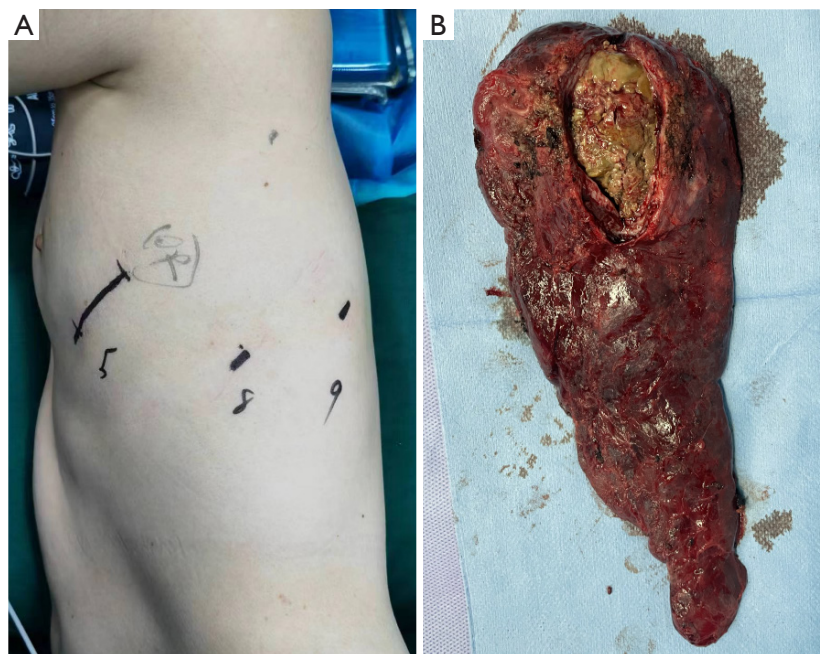
**Figure 1** CT and angiography of Case 1. (A) CT showed an aspergilloma and fibrocavitary lesions in the left upper lobe. (B) Angiography of left bronchial artery before (left column) and after (right column) embolization. CT, computed tomography.

selective artery embolization with PVA particles in both patients as described above. Angiograms confirmed the satisfactory occlusion of the arterial trunks that had been formerly hypertrophied and tortuous. In both cases, RATS was administered within 5 days of the preoperative embolization. Each patient was placed under general anesthesia with double-lumen intubation and single lung ventilation, and then placed in the lateral decubitus position with their flank elevated to open the intercostal spaces (ICSs). A first entry-port incision (2-cm long) was made in the 5th ICS on the anterior axillary line, and a regional adhesiolysis was performed to ensure the safety of the 2 subsequent entry-port incisions (in the 8th ICS on the mid-axillary line and the 9th ICS on the posterior axillary line, *Figure 2* left column). The trocars were then placed and the da Vinci Robot was docked to the ports.

In Case 1, we observed whole pleural adhesion during

the procedure. We first divided the dense adhesion, including the apex, and then dissected the hilar tissues. The interlobar fissure was divided with an endoscopic stapler. After the exposure of the anterior mediastinal pleura, we used Maryland forceps to free the superior pulmonary vein, pulled the upper lung back down, and continued to expand the proper segmental artery space. The superior pulmonary vein, all the upper pulmonary artery branches, and the superior lobar bronchus were dissected by endoscopic staplers (specimen shown in *Figure 2* right column).

The operative times were 407 and 427 min, and the blood loss volumes were 160 and 200 mL for Cases 1 and 2, respectively. Postoperative chest X-ray scans indicated different degrees of residual cavity in each patient. After rehabilitation exercises and suction by the digital drainage system, the patients' lungs were able to reopen. The postoperative stays were 15 and 9 days for Cases 1 and 2,



**Figure 2** Photos of incision marking and the specimen of Case 1. (A) Preoperative incision marking. (B) Cut section showing yellow aspergilloma in the left upper lobe.

respectively (a brief time line of the course of Case 1 shown in *Figure 3*).

## Discussion

During the last 3 decades, thoracic surgeons have made great advances in surgical approaches, such as video-assisted thoracoscopic surgery (VATS) and RATS, which have the advantages of being minimally invasive and providing sharp vision (5,6). In a previous study, Chen *et al.* reviewed 310 patients who underwent thoracotomy and 76 patients who underwent attempted VATS lobectomy for SPA and CPA, and concluded that the patients who underwent VATS had shorter hospital stays and fewer complications than those who underwent thoracotomy (7). VATS is an alternative to thoracotomy, especially for SPA and CPA without infiltration to the hilum (8-11).

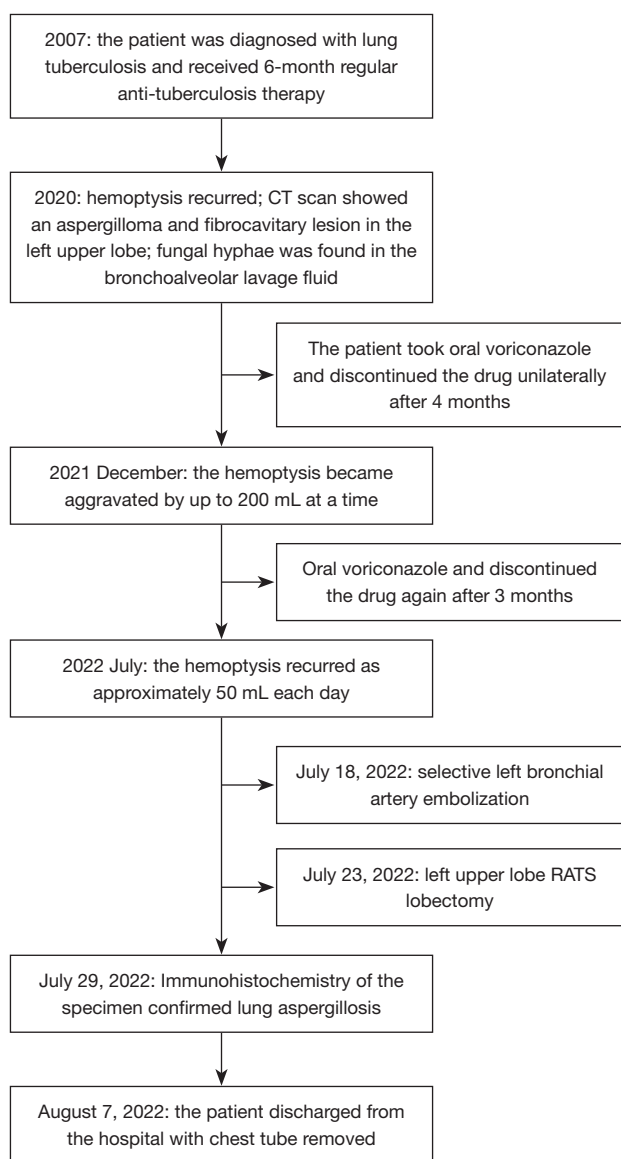
Research has shown the efficacy and safety of robotic lung cancer surgeries, including lobectomy, segmentectomy, and wedge resection (12-15); however, only a few studies have examined the use of RATS in pulmonary aspergilloma (2,3). Khan *et al.* reported a case of robotic resection for pulmonary aspergilloma. There were several differences between Khan *et al.*'s case and our 2 cases. Notably, our 2 patients had CCPA with multiple cavities and fibrosis of

the peripheral lung tissue, chest wall angiogenesis whole pleural adhesion, and bronchial artery dilation. To avoid massive intraoperative bleeding, poor surgical field of vision, and dissection difficulties. We applied selective artery embolization to the patients before surgery. As a consequence of the additional difficulties and preoperative embolization, the operative durations of our cases were longer than that in the case reported by Khan *et al.* (407 and 427 *vs.* 188 min), but the blood losses were less (160 and 200 *vs.* 560 mL) (3).

Based on our experiences, we can infer that CPA and complex pleural adhesion is not a contraindication for robotic resection. Indeed, the 3-dimensional visualization, the magnification ( $\times 10$ ) of the surgical area, and the 360-degree freedom of the Endowrist movement of the da Vinci system highlight the superiority of the procedure (2,14,16). Another rationale for using RATS in CPA resection is that the ergonomic design and vibratory feedback system of the da Vinci robot helps to meet the requirements for perseverance and operative stability required by the extra-long surgical time related to the adhesiolysis.

The robot has some disadvantages, including those related to the high cost of the surgery, the limited number of da Vinci robots available in hospitals, and the initial long learning period for surgeons, all of which restricts





**Figure 3** Course and treatment of Case 1 according to time line. CT, computed tomography; RATS, robotic-assisted thoracoscopic surgery.

the availability of RATS (17). Severe thoracic and hilar adhesions caused by long-term pulmonary infection, especially extensive feeding vascular formation from systemic circulation, lead to difficulties in dissection, increased bleeding, and unclear vision, which limit the use of minimally invasive approaches. In VATS and RATS, an emergency conversion to an open procedure is possible when bleeding increases, as is a supplementary incision for specimen removal (7,16).

To address these issues, we strongly suggest that adequate preoperative preparation be undertaken, including in-depth conversations with patients and their families, careful assessments of the disease extension and the severity of the fibrous adhesions based on CT images and bronchoscopy, and preoperative artery embolization if necessary. Preoperative arterial embolization not only reduces hemorrhages during adhesiolysis, but also the need to clean any bloody burned attachments on the forceps, thus promoting the fluency of the operation. Intraoperatively, the full washing of the surgical area and incisions (7) and the application of biogels to reduced postoperative air leak and bleeding is important. If massive bleeding occurs or calcified lymph nodes create dissection problems, a prompt conversion to thoracotomy is recommended.

This article only described the treatment and short-term outcomes of the two cases. Data regarding the long-term prognosis such as the relapse of CCPA should be involved according to the further follow-up.

## Conclusions

RATS following selective artery embolization can be a safe and effective treatment option for CCPA. As the number of cases in which RATS is used to treat pulmonary aspergillosis increases, we anticipate that systematic studies will be able to be conducted based on a large number of cases.

## Acknowledgments

Thanks to Dr. Kai Feng (a vascular and interventional physician in The Third People's Hospital of Shenzhen) for helpful information and support.

*Funding:* This work was supported by the Sanming Project of Medicine in Shenzhen (No. SZSM201812058) and In-hospital Project of Shenzhen Third People's Hospital (No. 2022042).

## Footnote

*Reporting Checklist:* The authors have completed the CARE reporting checklist. Available at <https://atm.amegroups.com/article/view/10.21037/atm-22-6040/rc>

*Conflicts of Interest:* All authors have completed the ICMJE uniform disclosure form (available at <https://atm.amegroups.com/article/view/10.21037/atm-22-6040/coif>). The authors have no conflicts of interest to declare.

**Ethical Statement:** The authors are accountable for all aspects of the work in ensuring that questions related to the accuracy or integrity of any part of the work are appropriately investigated and resolved. All the procedures performed in this study were conducted in accordance with the ethical standards of The Medical Ethical Committee of The Third People's Hospital of Shenzhen (approval No. 2022-100-02) and with the Declaration of Helsinki (as revised in 2013). Written informed consent was obtained from the patients for publication of this case report and accompanying images. A copy of the written consent is available for review by the editorial office of this journal.

**Open Access Statement:** This is an Open Access article distributed in accordance with the Creative Commons Attribution-NonCommercial-NoDerivs 4.0 International License (CC BY-NC-ND 4.0), which permits the non-commercial replication and distribution of the article with the strict proviso that no changes or edits are made and the original work is properly cited (including links to both the formal publication through the relevant DOI and the license). See: <https://creativecommons.org/licenses/by-nc-nd/4.0/>.

## References

- Denning DW, Cadranel J, Beigelman-Aubry C, et al. Chronic pulmonary aspergillosis: rationale and clinical guidelines for diagnosis and management. *Eur Respir J* 2016;47:45-68.
- Khan AZ, Khanna S, Agarwal N, et al. Robotic thoracic surgery in inflammatory and infective diseases. *Ann Cardiothorac Surg* 2019;8:241-9.
- Khan AZ, Ali K, Khandelwal S, et al. Robotic assisted thoracoscopic right upper lobectomy for post tuberculosis aspergilloma. *J Vis Surg* 2016;2:51.
- Goyal A, Khan IA, Kumar A, et al. Chest-Wall Collateral Embolization to Reduce Surgical Blood Loss in Peripheral Aspergillomas. *Thorac Cardiovasc Surg* 2022;70:589-95.
- Klapper J, D'Amico TA. VATS versus open surgery for lung cancer resection: moving toward a minimally invasive approach. *J Natl Compr Canc Netw* 2015;13:162-4.
- Bendixen M, Jørgensen OD, Kronborg C, et al. Postoperative pain and quality of life after lobectomy via video-assisted thoracoscopic surgery or anterolateral thoracotomy for early stage lung cancer: a randomised controlled trial. *Lancet Oncol* 2016;17:836-44.
- Chen QK, Chen C, Chen XF, et al. Video-assisted thoracic surgery for pulmonary aspergilloma: a safe and effective procedure. *Ann Thorac Surg* 2014;97:218-23.
- Patel DC, Bhandari P, Epstein DJ, et al. Surgical resection for patients with pulmonary aspergillosis in the national inpatient sample. *J Thorac Dis* 2021;13:4977-87.
- Ichinose J, Kohno T, Fujimori S. Video-assisted thoracic surgery for pulmonary aspergilloma. *Interact Cardiovasc Thorac Surg* 2010;10:927-30.
- Yuan P, Wang Z, Bao F, et al. Is video-assisted thoracic surgery a versatile treatment for both simple and complex pulmonary aspergilloma? *J Thorac Dis* 2014;6:86-90.
- Ocakcioglu I, Ermerak NO, Yildizeli B. Uniportal Video-assisted Thoracoscopic Surgery for Pulmonary Aspergilloma: A Report of 5 Cases. *Surg Laparosc Endosc Percutan Tech* 2019;29:e37-40.
- Kent MS, Hartwig MG, Vallières E, et al. Pulmonary Open, Robotic and Thoracoscopic Lobectomy (PORTaL) Study: An Analysis of 5,721 Cases. *Ann Surg* 2021. [Epub ahead of print]. doi: 10.1097/SLA.0000000000005115.
- Jin R, Zheng Y, Yuan Y, et al. Robotic-assisted Versus Video-assisted Thoracoscopic Lobectomy: Short-term Results of a Randomized Clinical Trial (RVlob Trial). *Ann Surg* 2022;275:295-302.
- Liang H, Liang W, Zhao L, et al. Robotic Versus Video-assisted Lobectomy/Segmentectomy for Lung Cancer: A Meta-analysis. *Ann Surg* 2018;268:254-9.
- Radkani P, Joshi D, Barot T, et al. Robotic video-assisted thoracoscopic lung resection for lung tumors: a community tertiary care center experience over four years. *Surg Endosc* 2016;30:619-24.
- Li C, Hu Y, Huang J, et al. Comparison of robotic-assisted lobectomy with video-assisted thoracic surgery for stage IIB-IIIa non-small cell lung cancer. *Transl Lung Cancer Res* 2019;8:820-8.
- Yang MZ, Lai RC, Abbas AE, et al. Learning curve of robotic portal lobectomy for pulmonary neoplasms: A prospective observational study. *Thorac Cancer* 2021;12:1431-40.

(English Language Editor: L. Huleatt)

**Cite this article as:** Tao X, Shi Q, Xia Z, Fu Q, Zheng S, Qiao K. Two case reports of preoperative selective artery embolization with robotic-assisted thoracoscopic lobectomy for chronic cavitary pulmonary aspergillosis: technology, safety and short-term outcomes. *Ann Transl Med* 2022;10(24):1409. doi: 10.21037/atm-22-6040