

Case Report

Suprasellar and third ventricular cavernous malformation: Lessons learned in differential diagnosis and surgical planning

Kay O. Kulason, Julia R. Schneider, Ralph Rahme, Fanni Ratzon¹, Todd A. Anderson¹, Deborah R. Shatzkes^{2,3}, Christopher G. Filippi², Peter D. Costantino³, David J. Langer, John A. Boockvar

Departments of Neurosurgery, ¹Pathology, ²Radiology, ³Otolaryngology, Lenox Hill Hospital, Hofstra Northwell School of Medicine, New York, NY, USA

E-mail: Kay O. Kulason - kulasonk@gmail.com; Julia R. Schneider - jschne10@nyit.edu; Ralph Rahme - rrahme@northwell.edu; Fanni Ratzon - fratzon@northwell.edu; Todd A. Anderson - tanderson4@northwell.edu; Deborah R. Shatzkes - DShatzkes@northwell.edu; Christopher G. Filippi - Cfilippi@northwell.edu; Peter D. Costantino - Pcostantino@northwell.edu; David J. Langer - Dlanger@northwell.edu; *John A. Boockvar - Jboockvar@northwell.edu
*Corresponding author

Received: 23 June 17 Accepted: 26 July 17 Published: 13 October 17


Abstract

Background: While craniopharyngiomas (CPs) are the most common cystic suprasellar lesions in adults, cavernous malformations (CMs) only exceptionally occur in this location and are seldom considered in the differential diagnosis of such lesions. However, unlike CPs, suprasellar CMs are not typically approached via an endoscopic endonasal approach.

Case Description: We present a unique clinical case of suprasellar and third ventricular CM mimicking a CP, posing a major decision-making dilemma at the levels of both preoperative diagnosis and surgical planning.

Conclusion: This case highlights the importance of carefully considering all the differential diagnoses of sellar pathology to select the most appropriate management strategy and surgical approach.

Key Words: Cavernous malformation, craniopharyngioma, endoscopic endonasal surgery, interhemispheric transcallosal approach, third ventricle

Access this article online
Website: www.surgicalneurologyint.com
DOI: 10.4103/sni.sni_229_17
Quick Response Code:


INTRODUCTION

The sellar region is anatomically complex and a common site of neoplastic, infectious, inflammatory, developmental, and vascular pathologies.^[1] Among cystic lesions of the sella turcica, parasellar, and suprasellar space, craniopharyngioma (CP) and Rathke's cleft cyst (RCC) are, by far, the most common. However, the differential diagnosis also includes a variety of disease processes, for which treatment can vary widely. These include colloid cyst, arachnoid cyst, cystic pituitary adenoma, xanthogranuloma, epidermoid cyst, and dermoid cyst.^[4,7,9,15] While craniotomy remains a first-line treatment option for many of these lesions, a significant

proportion can be resected safely and effectively via an endoscopic endonasal approach.^[12,14]

This is an open access article distributed under the terms of the Creative Commons Attribution-NonCommercial-ShareAlike 3.0 License, which allows others to remix, tweak, and build upon the work non-commercially, as long as the author is credited and the new creations are licensed under the identical terms.

For reprints contact: reprints@medknow.com

How to cite this article: Kulason KO, Schneider JR, Rahme R, Ratzon F, Anderson TA, Shatzkes DR, et al. Suprasellar and third ventricular cavernous malformation: Lessons learned in differential diagnosis and surgical planning. *Surg Neurol Int* 2017;8:251.

<http://surgicalneurologyint.com/Suprasellar-and-third-ventricular-cavernous-malformation:-Lessons-learned-in-differential-diagnosis-and-surgical-planning/>

In contrast to other cystic lesions, cavernous malformations (CMs) rarely occur in the sellar region and/or third ventricle, and thus are not typically considered in the differential diagnosis of cystic sellar lesions.^[6,8,12] Moreover, CMs have not been previously resected via the endoscopic endonasal approach. We present a unique clinical case of suprasellar and third ventricular CM mimicking a CP and posing a major decision-making dilemma at the levels of both preoperative diagnosis and surgical planning. While we believe this case could have been better approached, our findings underscore the importance of carefully considering all differential diagnoses of sellar pathology as a critical step in devising the most appropriate management strategy and surgical approach.

CASE DESCRIPTION

A 52-year-old woman presented with several months of progressive anterograde amnesia noticed by her colleagues at work. Neurologic exam was otherwise unremarkable. Noncontrast head computed tomography (CT) revealed a hyperdense, suprasellar, and third ventricular lesion, consistent with either intralesional microcalcifications or hemorrhage [Figure 1a]. Magnetic resonance imaging (MRI) of the brain demonstrated a large, partially cystic, minimally enhancing suprasellar lesion extending into the third ventricle, with compression of the bilateral fornices at the foramina of Monro. A small intrasellar component of the lesion was also suspected [Figure 1b-d]. Based on its location and radiologic appearance, this lesion was thought to represent most likely a CP. Surgical resection was thus indicated for tissue diagnosis and to

decompress the fornices. Given the likely presence of an intrasellar component of this lesion, a decision was made to first attempt endoscopic endonasal resection rather than craniotomy.

Following lumbar drain placement, a standard endoscopic endonasal transsphenoidal approach was undertaken using intraoperative neuronavigation (Stryker, Kalamazoo, MI, USA). After opening the sellar dura, the small lesion in the posterior portion of the pituitary gland was easily identified and excised. Intraoperative frozen section examination was suggestive of CP. However, this intrasellar portion did not appear to be in direct continuity with the suprasellar lesion. An attempt to access the suprasellar space was then made. Unfortunately, however, a surgical corridor could not be safely developed. Anteriorly, the optic chiasm and anterior communicating artery complex completely obstructed the line of sight. Posteriorly, the neurohypophysis and dorsum sellae impeded access to the suprasellar compartment. Thus, a decision was made to abort the endoscopic procedure and plan a transcranial approach. Pathologic examination of the permanent intrasellar specimen showed a cystic lesion with clusters of simple squamoid epithelium and a rare strip of nonciliated columnar epithelium and proteinaceous contents. This was most consistent with the diagnosis of RCC, although a colloid or pars intermedia cyst or even a CP could not be ruled out [Figure 2a]. The patient's postoperative course was marked by diabetes insipidus requiring desmopressin therapy.

Five days later, the patient underwent bifrontal craniotomy and gross total resection of the suprasellar and third

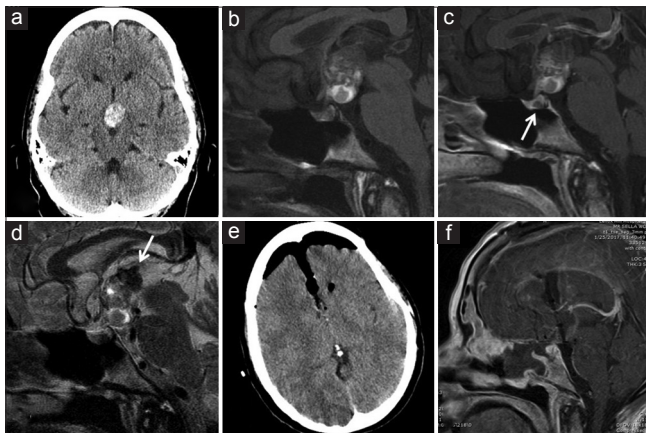


Figure 1: (a) Noncontrast head CT shows a heterogeneously hyperdense mass in the suprasellar cistern. (b) Sagittal T1-weighted brain MRI shows a large, partially cystic lesion without contrast, and (c) no enhancement with contrast. A small cystic lesion is seen in the pituitary gland (arrow). (d) Sagittal T2-weighted brain MRI demonstrates heterogeneous signal in the lesion. Areas of low signal superiorly (arrow) are consistent with susceptibility effects suggesting hemorrhagic products. (e, f) Postoperative noncontrast head CT (e) and brain MRI (f) demonstrate gross total resection of the lesion

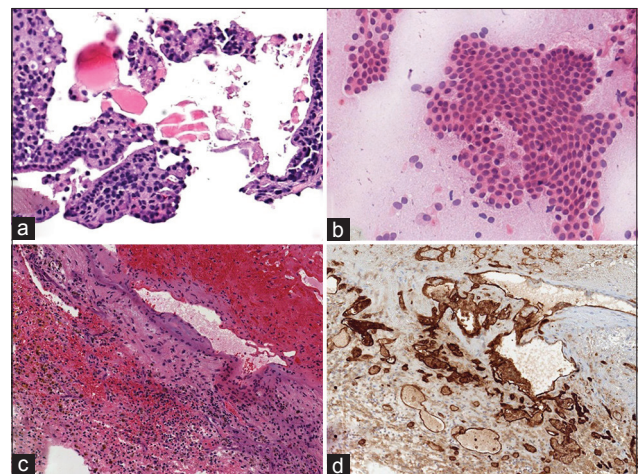


Figure 2: (a) Microphotograph of sellar lesion shows fibrotic adenohypophyseal tissue with scant strip of benign nonciliated columnar epithelium (hematoxylin-eosin, $\times 130$). (b) Intraoperative smear of specimen shows numerous cohesive clusters of benign squamoid epithelium with macrophages (hematoxylin-eosin, $\times 120$). (c) Microphotograph demonstrates hemorrhage and fibrin with hemosiderin-laden macrophages and fragments of benign tissue (hematoxylin-eosin, $\times 50$). (d) Immunohistochemical staining highlights abnormal vascular channels, consistent with a vascular malformation (CD31 stain, $\times 50$)

ventricular lesion via an interhemispheric transcallosal interforaminal approach [Figure 1e and f]. Intraoperatively, the lesion was noted to be mulberry-shaped and filled with blood products of various ages, which was consistent with a diagnosis of CM. The lesion was completely resected and the bilateral fornices were successfully preserved intact. Pathologic examination of the specimen revealed abnormal ectatic vascular channels in a hemorrhagic background, consistent with a vascular malformation [Figure 2b-d].

On the second postoperative day, the patient suffered sudden acute deterioration of her level of consciousness with right nonreactive mydriasis. Head CT revealed a new right hemispheric subdural fluid collection with mass effect and midline shift to the left [Figure 3a and b]. The patient was thus taken to the operating room and underwent emergent evacuation of the subdural collection and placement of a left frontal external ventricular drain (EVD) [Figure 3c]. Postoperatively, the patient exhibited significant improvement with gradual return to her normal level of consciousness. She was ultimately discharged to a rehabilitation facility after the EVD was successfully weaned and removed.

Three weeks later, the patient exhibited worsening mental status and increasing lethargy. Head CT demonstrated external hydrocephalus [Figure 3d and e]. She was taken back to the operating room and underwent EVD placement, which was subsequently converted to a ventriculoperitoneal shunt a few days later [Figure 3f].

Following cerebrospinal fluid (CSF) diversion, she improved significantly to her baseline neurological status, and was ultimately discharged back to the rehabilitation facility. At her last follow-up 4 months later, she was functionally independent without focal neurologic deficits, despite persistent anterograde amnesia and desmopressin-dependent diabetes insipidus.

DISCUSSION

This case report illustrates the importance of carefully studying the differential diagnosis of lesions arising from the suprasellar space given the significant impact of histopathologic diagnosis on the overall management strategy and surgical approach. In fact, suprasellar and third ventricular lesions can be approached through a wide variety of endoscopic transfacial and open transcranial approaches. The decision-making process is often complex and depends on multiple factors, ranging from the nature, size, and extent of the lesion to the local anatomy, surgeon experience, and patient preference.^[1,6,12] In fact, we have identified two levels at which the present case could have been better approached, potentially sparing the patient transsphenoidal surgery.

First, the differential diagnosis of suprasellar and third ventricular lesions is broad and all possibilities should be considered. The fact that this lesion was hyperdense on CT, suggesting possible microcalcifications, partially cystic and minimally enhancing on MRI, made us

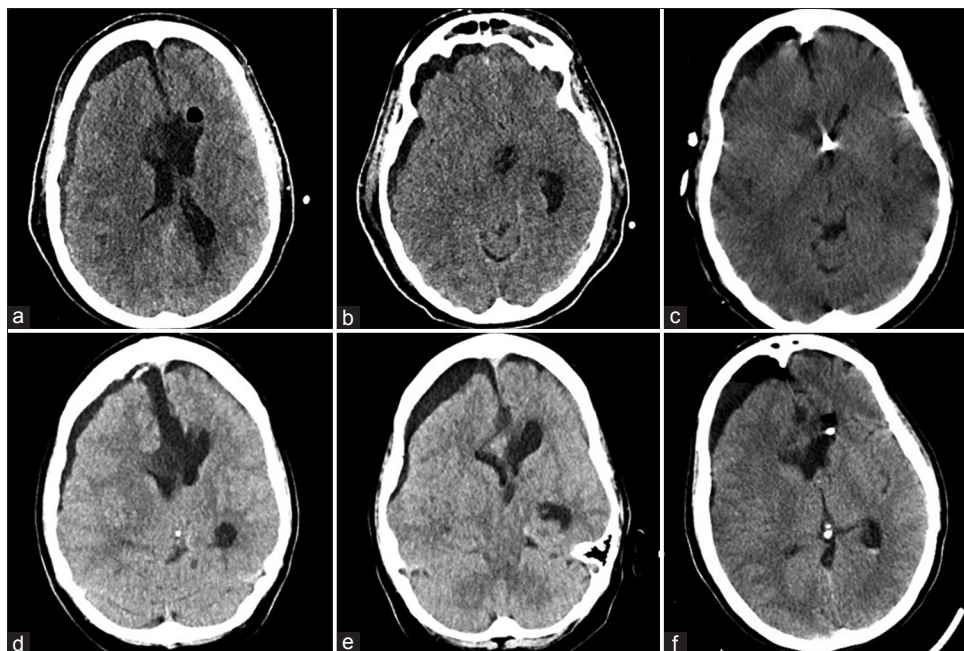


Figure 3: (a and b) Noncontrast head CT following postoperative neurological worsening shows a right hemispheric subdural fluid collection with mass effect and midline shift. (c) Noncontrast head CT after evacuation of the subdural collection and right frontal EVD placement shows improvement in mass effect and midline shift. (d and e) Non-contrast head CT, 3 weeks later, shows recurrence of the right subdural hygroma with concomitant ventriculomegaly, consistent with external hydrocephalus. (f) Non-contrast head CT after permanent CSF diversion shows reduction in subdural collection size and mass effect

overly confident of the diagnosis of CP. This was further compounded by the fact that CP is, by far, the most common suprasellar cystic lesion in adults.^[5] Nonetheless, we should have considered the remote possibility of an alternative diagnosis, specifically that of CM. In fact, growing CMs may have very similar hyperdense appearance on CT and similar signal characteristics on MRI, as a result of recurrent intrasellar hemorrhages.^[3,5] Furthermore, though rare, suprasellar and third ventricular CMs have been previously reported and well documented, and often present with short-term memory loss.^[8,12]

Second, the indication for surgery and the choice of approach largely depend on the suspected histopathologic diagnosis. There is general consensus that CMs involving the third ventricle should be aggressively surgically managed, given that these lesions tend to grow more rapidly and cause more mass effect than CMs arising in other locations.^[8,10] However, had the lesion been thought to be a CM rather than a CP, an endoscopic endonasal approach would not have been undertaken. In fact, while the vast majority (75%) of CPs involve both suprasellar and intrasellar spaces, intrasellar extension of a CM is not usual.^[2,13] Therefore, the lack of an intrasellar extension that is readily accessible via the transsphenoidal approach and, hence, the lack of a natural sellar-suprasellar tumoral surgical corridor would have discouraged us from undertaking the endoscopic endonasal approach, had the possibility of a suprasellar CM been raised preoperatively. Finally, although it could be argued that a transventricular, rather than interhemispheric approach might be associated with a low risk of injury to the fornices, a transventricular transparenchymal approach would have been particularly difficult in this patient, given the very small size of her lateral ventricles and foramina of Monro.

CONCLUSIONS

Neurosurgeons should keep an open mind when considering the differential diagnosis of sellar pathology because the optimal management strategy and surgical approach may vary considerably depending on the suspected underlying histopathologic diagnosis. Specifically, a CM should be routinely considered, along

with CP, in the differential diagnosis of suprasellar and/or third ventricular, cystic-appearing lesions. While the endoscopic endonasal approach is often a good choice for suprasellar CPs, it is less so for CMs which are best approached transcranially.

Financial support and sponsorship

Nil.

Conflicts of interest

There are no conflicts of interest.

REFERENCES

1. Barber SM, Rangel-Castilla L, Baskin D. Neuroendoscopic Resection of Intraventricular Tumors: A Systematic Outcomes Analysis. *Minim Invasive Surg* 2013;2013:898753.
2. Bernstein M. *Neuro-oncology, the essentials*. Thieme; 2007. ISBN: 1588904970.
3. Blitsstein MK, Tung GA. MRI of cerebral microhemorrhages. *AJR Am J Roentgenol* 2007;189:720-5.
4. Cavallo LM, Prevedello D, Esposito F, Laws ER Jr, Dusick JR, Messina A. The role of the endoscope in the transsphenoidal management of cystic lesions of the sellar region. *Neurosurg Rev* 2008;31:55-64.
5. Eldevik OP, Blaivas M, Gabrielsen TO, Hald JK, Chandler WF. Craniopharyngioma: Radiologic and histologic findings and recurrence. *AJNR. Am J Neuroradiol* 1996;17:1427-39.
6. Giannetti AV. Purely neuroendoscopic resection of an intraventricular cavernous angioma: Case report. *J Neurol Surg* 2013;74:47-50.
7. Ginat DT, Meyers SP. Intracranial lesions with high signal intensity on T1-weighted MR images: Differential diagnosis. *Radiographics* 2012;32:499-516.
8. Katayama Y, Tsubokawa T, Maeda T, Yamamoto T. Surgical management of cavernous malformations of the third ventricle. *J Neurosurg* 1994;80:64-72.
9. Laws ER. Endoscopic surgery for cystic lesions of the pituitary region. *Nat Clin Pract Endocrinol Metab* 2008;4:662-3.
10. Patibandla MR, Thotakura AK, Panigrahi MK. Third ventricular cavernous malformation: An unusual lesion. *Br J Neurosurg* 2014;28:110-2.
11. Rennert J, Doerfler A. Imaging of sellar and parasellar lesions. *Clin Neurol Neurosurg* 2007;109:111-24.
12. Shirvani M, Hajimirzabeigi A. Intraventricular Cavernous Malformation: Review of the Literature and Report of Three Cases with Neuroendoscopic Resection. *J Neurol Surg* 2017 [Epub ahead of print].
13. Thapar K. *Diagnosis and management of pituitary tumors*. Humana Pr Inc; 2001. ISBN: 0896034038.
14. Wannemuehler TJ, Rubel KE, Hendricks BK, Ting JY, Payner TD, Shah MV, et al. Outcomes in transcranial microsurgery versus extended endoscopic endonasal approach for primary resection of adult craniopharyngiomas. *Neurosurg Focus* 2016;41:E6.
15. Zada G, Lin N, Ojerholm E, Ramkissoon S, Laws ER. Craniopharyngioma and other cystic epithelial lesions of the sellar region: A review of clinical, imaging, and histopathological relationships. *Neurosurg Focus* 2010;28: E4.