



Contents lists available at ScienceDirect

JPRAS Open

journal homepage: www.elsevier.com/locate/jpra



Minimally invasive nerve and artery sparing surgical approach for temporal migraines

Giorgio Pietramaggiore^{a,*}, Alessandro Bastin^b, Federico Ricci^b, Franco Bassetto^b, Saja Scherer^a

^a Global Medical Institute, Division of Aesthetic and Migraine Surgery, Avenue Jomini 8, 1004 Lausanne, Switzerland

^b University of Padua, Department of Neurosciences, Division of plastic Surgery, Via Giustiniani 2, 35128 Padova, Italy

ARTICLE INFO

Article history:

Received 6 November 2023

Accepted 10 November 2023

Available online 24 November 2023

Keywords:

Temporal migraines

Superficial temporal artery (STA)

Auriculotemporal nerve (ATN)

Minimally invasive surgery

Migraine surgery

ABSTRACT

Background: Temporal migraines (TM) present with throbbing, pulsating headaches in the temporal area. Different surgical techniques ranging from resecting the auriculotemporal nerve (ATN) and/or ligating the superficial temporal artery (STA) have shown similar good results to decrease TM symptoms. No conclusive data supports a specific disease of the STA in TM patients. A minimally invasive technique is proposed to preserve both vascular and nerve structures.

Methods: Patients with drug resistant TM were selected and treated with two techniques: nerve sparing and nerve and artery sparing. The study included 57 patients with TM, with an average age of 47.5 years. TM improvement was quantified after at least one year of follow up time. STA biopsies were sent for histological analysis.

Results: Forty-two patients underwent nerve-sparing decompression, with a therapeutic success rate of 78.6%, corresponding to 22.1 days with migraine per month decreasing to 6.2. Histological analysis of the STA showed varying degrees of endofibrosis in 75% of the samples. Histological results do not correlate with the intensity of symptoms before or after surgery. Fifteen patients underwent nerve and artery sparing arteriolysis, with an overall therapeutic success rate of 86.6% of which 80% had >90% improvement.

* Corresponding author.

E-mail address: dr.pietramaggiore@global.surgery (G. Pietramaggiore).

The average migraine days dropped from 24 to 2.5 days per month in this group.

Conclusion: Minimally invasive nerve sparing approaches are an effective and safe treatment to improve drug resistant TM symptoms. Endofibrosis of the STA was present in 75% of the cases, but it was found to be unrelated to pre-operative symptoms and outcome. Results are promising, but the limited numbers of patients treated with artery and nerve sparing technique needs further investigations.

© 2023 The Author(s). Published by Elsevier Ltd on behalf of British Association of Plastic, Reconstructive and Aesthetic Surgeons.

This is an open access article under the CC BY-NC-ND license (<http://creativecommons.org/licenses/by-nc-nd/4.0/>)

Introduction

Temporal migraines (TM) are defined as headaches that occur in the temporal region of the head. The throbbing pain felt by the patients is pulsatile and centered along the course of the superficial temporal artery: for this reason, TM were previously classified as vascular migraines by the international headache association.¹⁻³

Likely due to lack of evidence pointing to the role of blood vessels in the etiopathogenesis of TM, the latest ICDH classification published in 2018 does not include vascular headaches.⁴⁻⁶ In our experience, several types of chronic headaches share the features of TM, such as chronic migraines with and without aura and cluster headaches.^{2,3}

Several anatomical and clinical studies have shown the relationship between the superficial temporal artery and the auriculotemporal nerve and targeted these two structures to improve TM. These studies investigate the possible compression sites along the course of the auriculotemporal nerve (ATN) and neurovascular conflicts between this sensitive nerve and the superficial temporal artery (STA) as main causative triggers of TM.^{7,8}

Taken together, results from these studies seem to recall the original theory from dr. Wolff hypothesizing that pain during a migraine traveled along the trigemino-vascular structures and on the surface of the blood vessels.⁹ This highly debated hypothesis is still partially validated as extracranial (but not intracranial) blood vessels, such as the superficial temporal artery, dilate during a crisis.^{5,6,10-12}

To date, there are two main schools of thought regarding the surgical treatment of temporal headaches: on one hand the vascular theory, already described in the middle age from Al Zahrawi and later by Ambroise Paré, and on the other the nerve compression theory as described by Guyuron.^{13,14}

Following the first theory, surgeons have coagulated, ligated and interrupted the STA, while for the latter surgeons have been practicing ATN decompressions, neurectomies and arteriectomies.^{13,15,16}

Interestingly, both surgical techniques seem to yield similar outcomes, with more than 50% improvement of TM symptoms in about 80% of the operated patients.¹⁵⁻¹⁸

Taking into consideration the complex anatomy of this region,¹⁹ and the absence of a conclusive clue about the pathophysiology of TM, we present here the results of minimally invasive approaches to preserve both vascular and nerve structures.

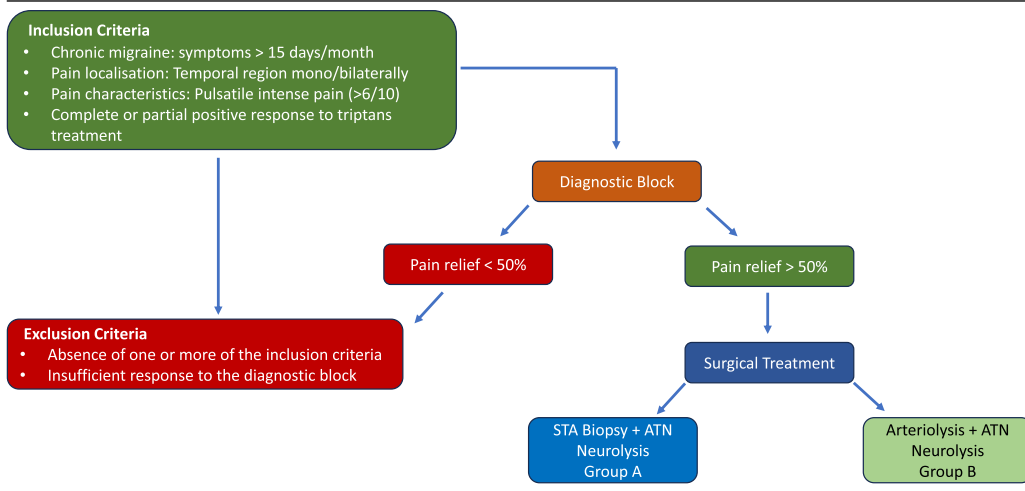
Materials and methods

Selection of the candidates

Patients were either self-referred, referred by a neurologist, pain specialist, other specialist, or general practitioner after failing to respond in a satisfactory manner to abortive (triptans) and disease-modifying medications for at least 1 year. Temporal migraine patients are among the best responders

Table 1

Selection of the candidates for the study. Patients meeting the criteria for temporal migraines (TM) were tested with a diagnostic block with local anesthesia in the point of maximum pain (along the trajectory of the superficial temporal artery, STA). After positive response to the diagnostic block (>50% pain relief), patients were considered eligible for surgery, which consisted of STA biopsy and auriculotemporal nerve (ATN) neurolysis (Group A) or arteriolyis and ATN neurolysis (Group B).



to triptans when taken early at the onset of a migraine. Failure to respond to Triptans signifies either drug overuse (more than 10–12 per month), non-significant (less than 50%) improvement 2 h after intake, and/or multiple triptans taken to overcome one pain crisis (Table 1). Patients with TM symptoms with difficulties tolerating the side effect of at least two different Triptans were also included.

Diagnosis was confirmed by a constellation of symptoms consistent with chronic TM including unilateral or bilateral pulsatile pain centered along the course of the superficial temporal artery for more than 15 days per month. Inclusion criteria included mean pain evaluation >6/10. (Table 1)

Before being considered eligible for surgery, at least one anesthesia block was performed. To perform the block, patients were asked to come to the office during a migraine. The block (1 cc of 1% lidocaine) was administered through a 30-gauge needle in the point of maximum pain, along the course of the superficial temporal artery (the location was confirmed by palpation or the artery, visual inspection and/or positive doppler signal).^{20,21} Positive response was considered when symptoms temporarily improved (at least >50% improvement). (Table 1)

Patients were divided into two groups (nerve sparing and nerve and artery sparing group, see below). Patients under 60 years old, whose age made it unlikely the diagnosis of Horton vasculitis, or other STA anomaly (aneurysm or malformation) or suffering from bilateral TM were allocated in the nerve and artery sparing group.²² (Table 1)

Surgical techniques

Common preparation step

All procedures were performed by doctors Pietramaggiori and Scherer. Patients were asked to point with a finger to the epicenter (point where pain starts during a crisis) of their migraines. The correspondence of this point with the trajectory of the superficial temporal artery was confirmed by a positive doppler signal. Under local anesthesia, an approximately 1–2 cm linear or “W” shaped incision was marked in the temporal region that varied between the localization of common STA trunk or the temporal or parietal branch. 2–3 cc of 1% lidocaine with 1:100,000 epinephrine was injected. Ten minutes after the infiltration, following the cutaneous incision, subcutaneous dissection was carried out. A breach in the superficial temporal fascia was created to access the neurovascular bundle.

(Video 1) At this point, depending on the need to perform a biopsy of the STA, two different techniques were employed.

Nerve sparing auriculo-temporal decompression and biopsy of a branch of the artery (Group A). The auriculotemporal nerve (ATN) is identified and decompressed along its trajectory from the incision site in a proximal and distal direction. The superficial temporal artery (STA) is isolated and divided in the point of contact with the ATN. Nerve fibers along the course and on the surface of the ATN are dissected and carefully preserved before interrupting the artery.²³ The segment (1 cm) of the artery is sent to pathology, carefully avoiding excessive stretching to prevent artifacts on the endothelium or elastic lamina. Histologic analysis included Hematoxylin and Eosin (H&E, for general morphologic evaluation) and Van Gieson's staining (for internal elastic lamina). The evaluation of the tissues was performed by two pathologists independent from the study.

Nerve and artery sparing technique (Group B). The ATN and STA are identified. Neurolysis is carried out from the incision line (point of maximum pain) in a proximal and distal direction. The artery is separated from the perivascular tissue containing visible fine nerve fibers under magnifying loops. (Video 1)

Common closure step

After careful hemostasis, closure is performed by single 6–0 nylon sutures (Prolene, Ethicon). Dressing is made with steri-strips. Suture removal is planned 7 days after surgery.

Outcome measures

We performed a retrospective review of the charts from 100 consecutive patients treated in our institution for TM. 57 patients were included, average age 47.5 years (range 17–83 years-old), female to male ratio 1.5:1.

Forty-three patients were excluded from the study, when the main cause of TM was nerve injuries such as post-neurosurgery, post-neurectomy, post-traumatic with previous direct or indirect nerve lesions. Patients with occipital neuralgia, as main source of headaches contributing to temporal pain were excluded as well.

The minimum follow-up time was 12 months (range 12–60 and average 36 months). The overall improvement was quantified from 0 to 100% and classified as follows: 0–50% no significant improvement; 51–90% significant improvement; >90% significant - major improvement.

The analysis of the results was approved by an internal review board.

Two-tailed paired t tests were used to compare days with migraine, migraine outcome before surgery (baseline) and at the last visit. A p value less than 0.05 was considered significant.

Surgical complications were noted.

Results

Forty-two patients underwent a nerve sparing ATN decompression and STA biopsy, 15 patients underwent nerve and artery sparing treatment. The average migraine days per month and migraine headaches index, pre-surgery in the two groups had no significant difference.

Clinical outcome

Out of the 42 patients who benefited from nerve sparing ATN decompression and resection of a branch of the STA, 24 were females and 18 males (ratio of 1.3:1). The average age was 50.7 years. The overall therapeutic success rate, defined as significant >50% improvement of TM symptoms was 78.6% (Figure 1). The average of 22.1 days per month with TM before treatment decreased to 6.2 days per month after surgical treatment, representing an overall reduction of 72% days of pain (3.5-fold, $p < 0.01$). A significant major improvement defined by over 90% reduction of TM symptoms was reached in 50%

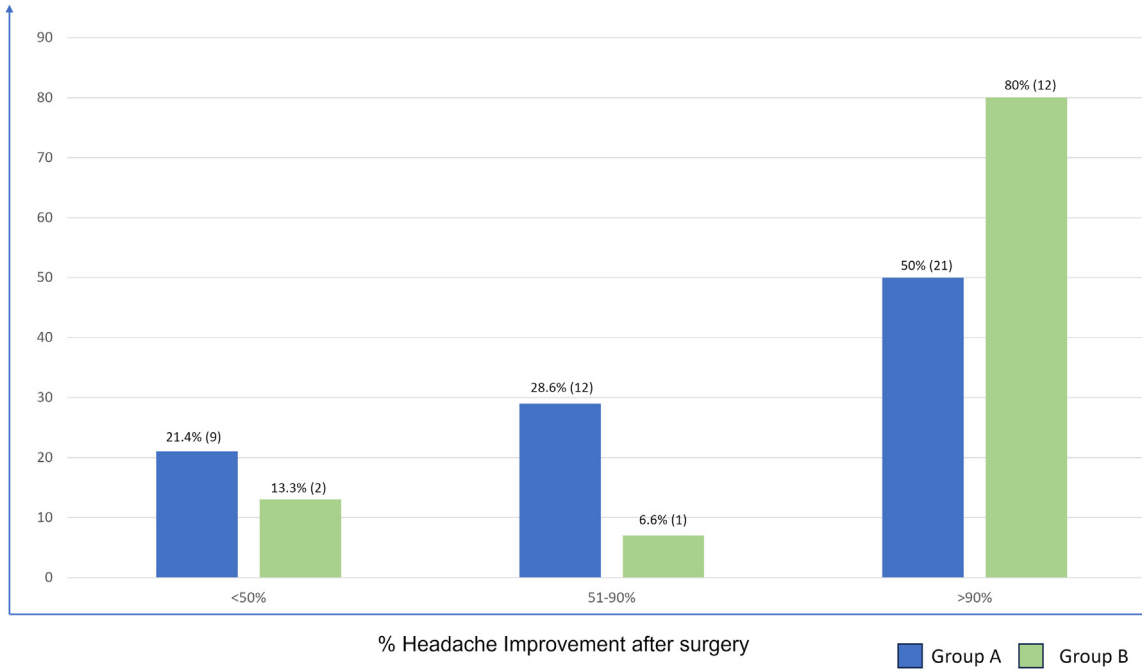


Figure 1. Headache improvement after surgery. Forty-two patients underwent STA biopsy and ATN neurolysis (group A, blue bars), of which 50% showed >90% and 28.6% a 50–90% improvement, while 21.4% did not show significant amelioration after surgery. Fifteen patients benefited from nerve and artery sparing arteriolytic (Group B, green bars), of which 80% experienced >90% and 6.6% experienced 50–90% improvement, while 13.3% did not improve significantly.

of all patients ($n = 21$) and 28.6% patients ($n = 12$) showed a reduction of 51–90%. 21.4% patients ($n = 9$) showed no improvement. (Figure 1)

The 15 patients who underwent nerve and artery sparing technique included 10 females and 5 males, with a female-to-male ratio of 2:1. Their average age was 38.6 years. After surgical treatment, 80% of the patients ($n = 12$) experienced significant major improvement (>90%), 6.6% ($n = 1$) experienced significant improvement (50–90%), and 13.3% ($n = 2$) did not experience significant improvement. (Figure 1) With this procedure, the global therapeutic success rate (>50% improvement) was 86.6% ($n = 13$, Figure 1). Before treatment, these patients had an average of 24 days per month with TM symptoms, which decreased to 2.5 days per month after treatment, representing a significant overall reduction of 89.6% days of pain (9.6-fold, $p < 0.01$).

No surgical complications were reported.

Histology results

Among the 42 patients who underwent ATN decompression and STA biopsy, 20 arterial samples were analyzed. The study sub-population consisted of 11 females and 9 males, with a female-to-male ratio of 1.2:1. The average age was 51.5 years (range of 22–83).

The samples of the STA were analyzed and classified based on the level of changes in the intima layer, identifying conditions of normality or endofibrosis. Endofibrosis is defined as a non obstructive proliferation of the intimal layer of the arterial wall. It was categorized as focal, moderate, or advanced; with the former two not showing a significant lumen reduction (<50%) and the latter displaying 50–90% lumen reduction. No occlusive endofibrosis (>90% lumen reduction) was observed.

In 25% of the samples (5 patients) the biopsy report indicated normal histology. These patients included 2 males, 3 females (average age 30.8 years old). (Figure 2)

In 75% of the samples (15 patients) varying degrees of endofibrosis were found: 10% had focal or mild endofibrosis (2 patients, 1 male and 1 female, average age 52 years old), (Figure 2 and Figure 3 left upper row) 45% had moderate endofibrosis (9 patients, 5 males and 4 females, average age of 54.3 years old), (Figure 2 and Figure 3 center upper row) and 20% had advanced endofibrosis (4 patients, including 1 male and 3 females, average age of 68.5 years old). (Figure 2 and Figure 3 right upper row) Among the 15 cases of endofibrosis (average age of 51 years old), 13.3% were mild, 60% were moderate, and 26.7% were advanced. A trend was noted in a more advanced endofibrosis with increased age, without reaching significant values.

In all cases analyzed, no signs of acute or chronic inflammatory processes were identified within the arterial wall. (Figure 3 upper row) Despite the thickening of the intima layer typical of endofibrosis, the internal elastic lamina and the media layer appeared normal in all analyzed samples. (Figure 3 upper and lower row) In cases of advanced endofibrosis characterized by significant lumen reduction, the presence of thrombotic material contributing to wall thickening or lumen narrowing was not found. The main contributing factor to arterial wall thickening and fibrosis appeared to be the increase in smooth muscle cells and extracellular matrix deposition between the endothelium and the internal elastic lamina. (Figure 3 upper and lower row)

Discussion

Isolated TM are rather rare, as multiple types of headaches, including occipital neuralgia, may co-exist in the same patient leading to temporal pain.^{3,21,24} This paper describes novel, minimally invasive techniques, to address isolated TM. Results are comparable to the ones reported in the literature achieved with more invasive techniques.

In our practice, we initially adopted the techniques described by Guyuron, and rapidly moved toward nerve conserving surgery in order to reduce minor consequences such as loss of sensation of the temporal area or, more rarely, painful neuromas.

One of the reasons that made us reflect on the opportunity to preserve the ATN was treating a patient referred after a diagnostic arterial biopsy in which the surgeon inadvertently transected the sensory nerve causing a neuroma. The complex management of this situation led us to adopt a nerve sparing technique since then to avoid iatrogenic complications²⁵ that fortunately remain quite rare.

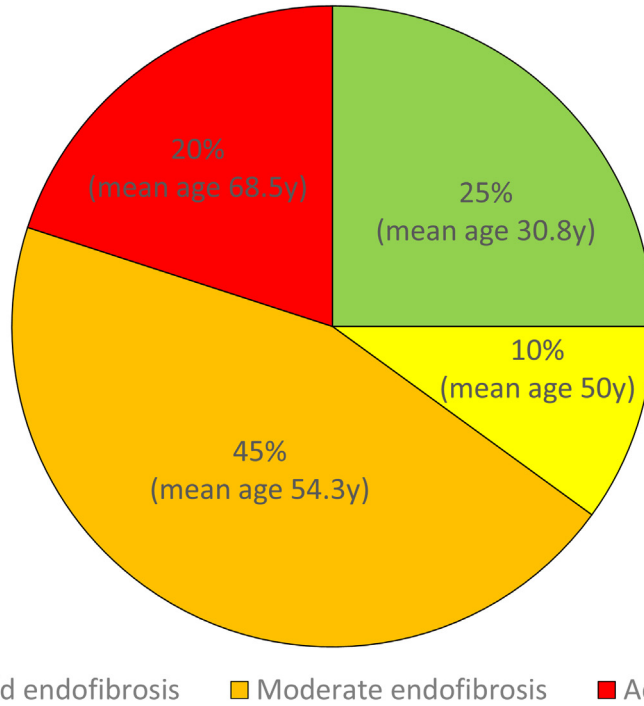


Figure 2. Results from the STA biopsies. 25% of the artery showed a normal microscopic anatomy (green, average age 30.8 years old). Among the 75% of the samples showing endofibrosis, 10% were mild (yellow, average age 54.3 years old), 45% were moderate (orange, average age 50 years old), and 20% were advanced (red, average age 68.5 years old).

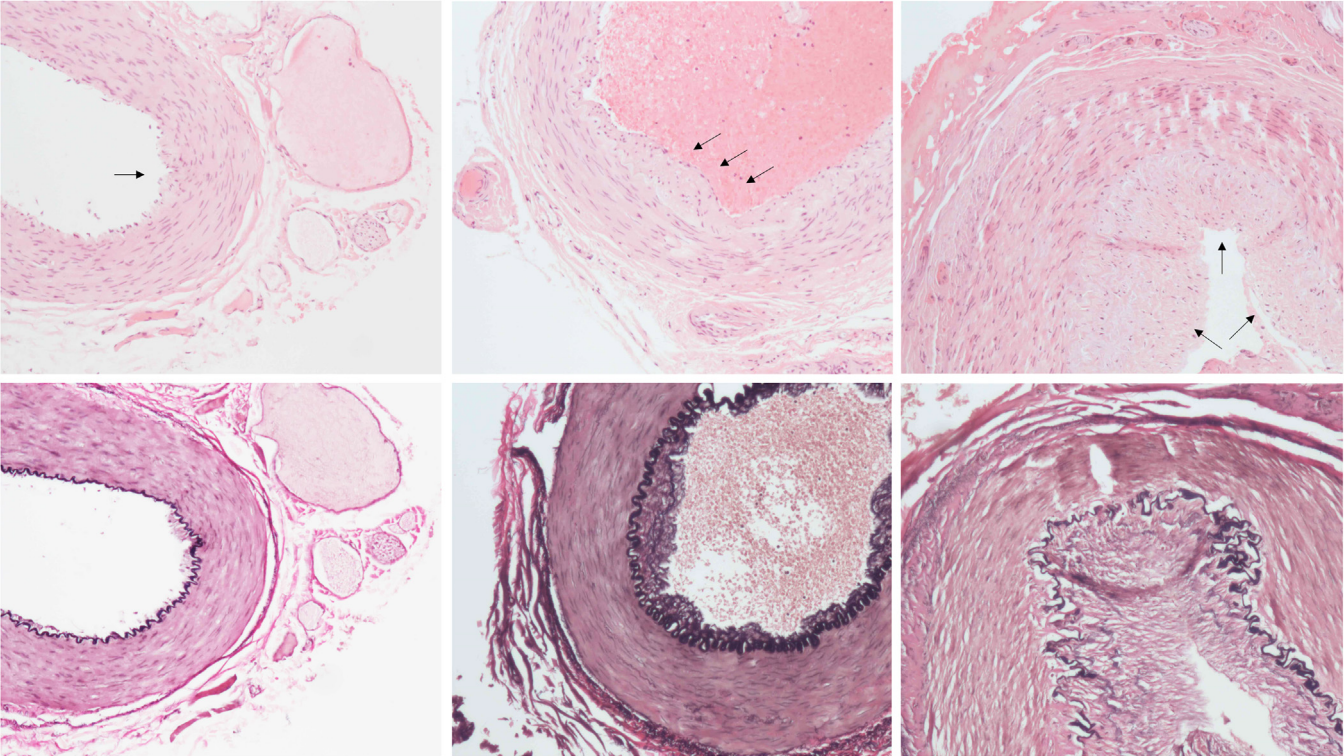


Figure 3. Histology of the STA biopsies. Upper row, H&E staining, lower row, Van Gieson's staining, 10x magnification. The lumen of the arteries displayed varying degrees of endofibrosis (arrows), ranging from focal and mild (upper row, left), moderate, with <50% lumen reduction (upper row, center) and advanced, 50–90% lumen reduction, (upper row, right). All samples showed intact internal elastic lamina and media layers (lower row). The main contributors to artery wall thickening were found to be increased smooth muscle cells and extracellular matrix deposition between the endothelium and the internal elastic lamina.

In this study, we did not find correlations between the severity of the endofibrosis and the symptoms, nor endofibrosis was present in all cases. As we biopsied arteries of patients only complaining of temporal headaches, we performed three histological analysis of superficial temporal arteries from cadaver specimens (average age 75) and found endofibrosis in all biopsies (not shown) confirming the trend observed of a rather age related phenomenon. It seems that endofibrosis may only be an epiphenomenon of TM, possibly resulting from mechanical stimulation (glasses, telephone, turbulent flow, digital compression by the patients in the attempt to relief pain) or biochemical stimulation (hyperactivation of the parasympathetic nervous system, neuro-vascular reaction among other hypothesis), in or around the vessels.²⁶ It is possible that in the future we will be able to better understand this observation and link it to TM.

After showing an age-related, rather than headaches related presence of endofibrosis, we moved toward an artery preserving technique, which showed early promising results. While the preservation of the artery still requires further investigations due to the limited number of patients studied, preservation of the nerve appears to be a reliable alternative with comparable outcomes to previously described techniques.

Conclusion

TM appear to be triggered along the temporal neuro-vascular bundle, compatibly to Wolff's original hypothesis. The resection of the auriculotemporal nerve and superficial temporal artery has shown significant pain relief in several publications. To reduce complications, we describe here a minimally invasive nerve sparing surgical techniques yielding similar positive outcome. Endofibrosis of the auriculotemporal artery cannot be identified as a disease specific pathology at this stage.

Declaration of Competing Interest

None.

Acknowledgments

Authors thanks the member of the pathology institute of Lausanne for useful discussion and analysis of the samples. We thank Alexandra Curchod and Yuliethe Martin for the contribution on the collection of the data.

Funding

None.

Ethics

The study conforms to the World Medical Association Declaration of Helsinki (June 1964) and subsequent amendments (<https://www.wma.net/what-we-do/medical-ethics/declaration-of-helsinki/>) and was approved by the local Ethical Committee.

Supplementary materials

Supplementary material associated with this article can be found, in the online version, at doi:[10.1016/j.jpra.2023.11.005](https://doi.org/10.1016/j.jpra.2023.11.005).

References

1. Lempert T, Olesen J, Furman J, et al. Vestibular migraine: Diagnostic criteria. *J Vestib Res.* 2012;22(4):167–172. doi:[10.3233/VES-2012-0453](https://doi.org/10.3233/VES-2012-0453).
2. Olla D, Sawyer J, Sommer N, Moore JB. Migraine treatment. *Clin Plast Surg.* 2020;47(2):295–303. doi:[10.1016/j.cps.2020.01.003](https://doi.org/10.1016/j.cps.2020.01.003).

3. Barmherzig R, Kingston W. Occipital neuralgia and cervicogenic headache: Diagnosis and management. *Curr Neurol Neurosci Rep.* 2019;19(5):20. doi:[10.1007/s11910-019-0937-8](https://doi.org/10.1007/s11910-019-0937-8).
4. The International Classification of Headache Disorders 3rd edition. Cephalalgia. 2018;38:1–211. Headache classification committee of the International Headache Society (IHS) Cephalalgia. 2018;Cephalalgia:1-211.
5. Sacco S, Ripa P, Grassi D, et al. Peripheral vascular dysfunction in migraine: A review. *J Headache Pain.* 2013;14(1):80. doi:[10.1186/1129-2377-14-80](https://doi.org/10.1186/1129-2377-14-80).
6. Brennan K, Charles A. An update on the blood vessel in migraine. *Curr Opin Neurol.* 2010;23(3):266–274. doi:[10.1097/WCO.0b013e32833821c1](https://doi.org/10.1097/WCO.0b013e32833821c1).
7. Janis JE, Hatfield DA, Ducic I, et al. Anatomy of the auriculotemporal nerve: Variations in its relationship to the superficial temporal artery and implications for the treatment of migraine headaches. *Plast Reconstr Surg.* 2010;125(5):1422–1428. doi:[10.1097/PRS.0b013e3181d4fb05](https://doi.org/10.1097/PRS.0b013e3181d4fb05).
8. Chim H, Okada HC, Brown MS, et al. The auriculotemporal nerve in etiology of migraine headaches. *Plast Reconstr Surg.* 2012;130(2):336–341. doi:[10.1097/PRS.0b013e3182589dd5](https://doi.org/10.1097/PRS.0b013e3182589dd5).
9. Blau J, Harold G Wolff: The man and his migraine. *Cephalalgia.* 2004;24(3):215–222. doi:[10.1111/j.1468-2982.2003.00642.x](https://doi.org/10.1111/j.1468-2982.2003.00642.x).
10. Shevel E. The extracranial vascular theory of migraine—A great story confirmed by the facts. *Headache: J Head Face Pain.* 2011;51(3):409–417. doi:[10.1111/j.1526-4610.2011.01844.x](https://doi.org/10.1111/j.1526-4610.2011.01844.x).
11. Shevel E, Spierings EH. Role of the extracranial arteries in migraine headache: A review. *CRANIO®.* 2004;22(2):132–136. doi:[10.1179/crn.2004.017](https://doi.org/10.1179/crn.2004.017).
12. Hamed SA, Hamed EA, Ezz Eldin AM, Mahmoud NM. Vascular risk factors, endothelial function, and carotid thickness in patients with migraine: Relationship to atherosclerosis. *J Stroke Cerebrovasc Dis.* 2010;19(2):92–103. doi:[10.1016/j.jstrokecerebrovasdis.2009.04.007](https://doi.org/10.1016/j.jstrokecerebrovasdis.2009.04.007).
13. Gfrerer L, Guyuron B. Surgical treatment of migraine headaches. *Acta Neurol Belg.* 2017;117(1):27–32. doi:[10.1007/s13760-016-0731-1](https://doi.org/10.1007/s13760-016-0731-1).
14. Gfrerer L, Raposio E, Ortiz R, Austen WG. Surgical treatment of migraine headache: Back to the future. *Plast Reconstr Surg.* 2018;142(4):1036–1045. doi:[10.1097/PRS.0000000000004795](https://doi.org/10.1097/PRS.0000000000004795).
15. Bertozzi N, Simonacci F, Lago G, Bordin C, Raposio E. Surgical therapy of temporal triggered migraine headache. *Plast Reconstr Surg Glob Open.* 2018;6(12):e1980. doi:[10.1097/GOX.0000000000001980](https://doi.org/10.1097/GOX.0000000000001980).
16. Baldelli I, Mangialardi ML, Raposio E. Site V surgery for temporal migraine headaches. *Plast Reconstr Surg Glob Open.* 2020;8(6):e2886. doi:[10.1097/GOX.0000000000002886](https://doi.org/10.1097/GOX.0000000000002886).
17. Long T, Ascha M, Guyuron B. Efficacy of surgical treatment of migraine headaches involving the auriculotemporal nerve (Site V). *Plast Reconstr Surg.* 2019;143(2):557–563. doi:[10.1097/PRS.0000000000005261](https://doi.org/10.1097/PRS.0000000000005261).
18. Chang B, Zhu W, Zhu J, Li S. Long-term efficacy of superficial temporal artery ligation and auriculotemporal nerve transection for temporal cluster headache in adolescent. *Child's Nervous Syst.* 2019;35(12):2385–2389. doi:[10.1007/s00381-019-04277-y](https://doi.org/10.1007/s00381-019-04277-y).
19. Iwanaga J, Watanabe K, Saga T, Fisahn C, Oskouian RJ, Tubbs RS. Anatomical study of the superficial temporal branches of the auriculotemporal nerve: Application to surgery and other invasive treatments to the temporal region. *J Plast, Reconstruct Aesthet Surg.* 2017;70(3):370–374. doi:[10.1016/j.bjps.2016.10.025](https://doi.org/10.1016/j.bjps.2016.10.025).
20. Guyuron B, Riazi H, Long T, Wirtz E. Use of a doppler signal to confirm migraine headache trigger sites. *Plast Reconstr Surg.* 2015;135(4):1109–1112. doi:[10.1097/PRS.0000000000001102](https://doi.org/10.1097/PRS.0000000000001102).
21. Pietramaggiore G, Scherer S. Minimally invasive nerve- and muscle-sparing surgical decompression for occipital neuralgia. *Plast Reconstr Surg.* 2023;151(1):169–177. doi:[10.1097/PRS.0000000000009777](https://doi.org/10.1097/PRS.0000000000009777).
22. Ling ML, Yosar J, Lee BW, et al. The diagnosis and management of temporal arteritis. *Clin Exp Optim.* 2020;103(5):572–582. doi:[10.1111/cxo.12975](https://doi.org/10.1111/cxo.12975).
23. Pietramaggiore G, Scherer S. *Minimally Invasive Surgery for Chronic Pain Management.* Springer International Publishing; 2020.
24. Pan W, Peng J, Elmofly D. Occipital neuralgia. *Curr Pain Headache Rep.* 2021;25(9):61. doi:[10.1007/s11916-021-00972-1](https://doi.org/10.1007/s11916-021-00972-1).
25. Langeveld M, Hundepool CA, Duraku LS, Power DM, Rajaratnam V, Zuidam JM. Surgical treatment of peripheral nerve neuromas: A systematic review and meta-analysis. *Plast Reconstr Surg.* 2022;150(4):823e. doi:[10.1097/PRS.0000000000009545](https://doi.org/10.1097/PRS.0000000000009545).
26. Harvey A, Montezano AC, Lopes RA, Rios F, Touyz RM. Vascular fibrosis in aging and hypertension: Molecular mechanisms and clinical implications. *Can J Cardiol.* 2016;32(5):659–668. doi:[10.1016/j.cjca.2016.02.070](https://doi.org/10.1016/j.cjca.2016.02.070).