

A foreign body in the cephalic vein

A case report

Mingzhi Song, MD, PhD^{a,b}, Maohua Wei, MD^{c,d}, Ze Song, MD^c, Liang Li, MD^{c,d}, Jifeng Fan, MD^{a,*},
Mozhen Liu, MD, PhD^{a,*}

Abstract

Rationale: Foreign bodies in the vasculature usually cause numerous problems for clinical physicians. Physician experience with diagnosing and treating non-iatrogenic foreign body migration in the venous system is insufficient.

Patient concerns: Here, we reported a 41-year-old male who had a foreign body in his left forearm following a work-related injury.

Diagnoses: X-ray films indicated a 3-mm high-density shadow in the superficial soft tissue of the left forearm. During the operation, the foreign body was imaged by a C-arm fluoroscope to provide a more accurate location.

Interventions: The foreign body was removed completely following a microsuture of the cephalic vein.

Outcomes: The procedure was uneventful, and the patient remained asymptomatic after 6 months of clinical follow-up.

Lessons: This case indicated that the foreign body in the superficial tissue needed to be accurately diagnosed and located. X-ray and C-arm fluoroscope imaging should be combined with the patient's medical history to ensure sufficient preoperative preparation.

Abbreviations: CT = computed tomography, FB = foreign body, IVC = inferior vena cava.

Keywords: cephalic vein, foreign body, microsuture, surgery

1. Introduction

A foreign body (FB) in the vasculature usually causes numerous concerns for clinical physicians, including vascular lesions, infection, bleeding, arrhythmia, and embolism. While most of these consequences are generally caused by migration, FBs in the veins are different from those in the arteries. Due to the direction of blood flow, intravenous FBs can more easily cause lethal pulmonary embolisms, while arterial FBs can cause limb necrosis.^[1,2] The former has a low incidence and is often

associated with iatrogenic factors such as catheters, cannulas, and needles.^[3–5] Non-iatrogenic intravenous FBs, including shrapnel and metallic fragments, are relatively rare emergencies.^[6,7] To prevent adverse consequences, rapid tests, accurate diagnosis, and effective extraction of the FB via an operation are particularly important. This uncommon condition can be worrisome for surgeons. Here, aiming to lay a foundation for future clinical work, we comprehensively report one rare case of a non-iatrogenic intravenous FB and a complete review of the related literature.

2. Case report

This study was approved by the Ethical Committee of the First Affiliated Hospital of Dalian Medical University. Written informed consent was obtained from the patient.

A 41-year-old male was admitted to the emergency department with a puncture wound on the palm-side of his left forearm on September 14, 2016. The patient brought 2 X-ray films that indicated that there was a 3-mm high-density shadow in the superficial soft tissue and an existing fracture of the left ulnar styloid process (Fig. 1). His narrative revealed he was injured accidentally by a shard that was flung by a hammer striking a metal nail. The patient immediately applied pressure to the bleeding wound and immediately went to a nearby hospital. Thirty minutes later, the patient came to our center for better treatment.

Clinically, the patient had no signs of a peripheral nerve lesion or hemodynamic disorder. There was no appreciable swelling or hematoma above the forearm. No apparent bleeding could be found around the wound. The patient denied having any other physical discomfort but required surgery to remove the FB. Preoperative examinations were conducted and only the electrocardiographic report produced an unexpected result (sinus bradycardia). The patient had no previous medical history except for an injury in the left wrist injury from an accidental fall.

Editor: N/A.

MS and MW contributed equally to this work.

This case report is recorded in the Ethics Committee of the First Affiliated Hospital of Dalian Medical University (approval number: YJ-FB-2016-45).

Written informed consent was obtained from the patient for publication of this case report and any accompanying images. A copy of the written consent form is available for review by the Editor-in-Chief of this journal.

The authors have no funding and conflicts of interest to disclose.

Supplemental Digital Content is available for this article.

^a Department of Orthopaedics, The First Affiliated Hospital of Dalian Medical University, Dalian, ^b Department of Orthopaedics, The Third Affiliated Hospital of Dalian Medical University, Jinpu New Area, ^c Department of General Surgery, The First Affiliated Hospital of Dalian Medical University, Dalian, ^d Department of General Surgery, The Third Affiliated Hospital of Dalian Medical University, Jinpu New Area, Liaoning, China.

* Correspondence: Jifeng Fan and Mozhen Liu, Department of Orthopaedics, The First Affiliated Hospital of Dalian Medical University, 222 Zhong Shan Road, 116011 Dalian, Liaoning, China (e-mails: fanjifeng_dmu@163.com, liumozhen_dmu@163.com).

Copyright © 2018 the Author(s). Published by Wolters Kluwer Health, Inc. This is an open access article distributed under the Creative Commons Attribution License 4.0 (CCBY), which permits unrestricted use, distribution, and reproduction in any medium, provided the original work is properly cited.

Medicine (2018) 97:25(e11144)

Received: 28 February 2018 / Accepted: 23 May 2018

<http://dx.doi.org/10.1097/MD.0000000000001144>

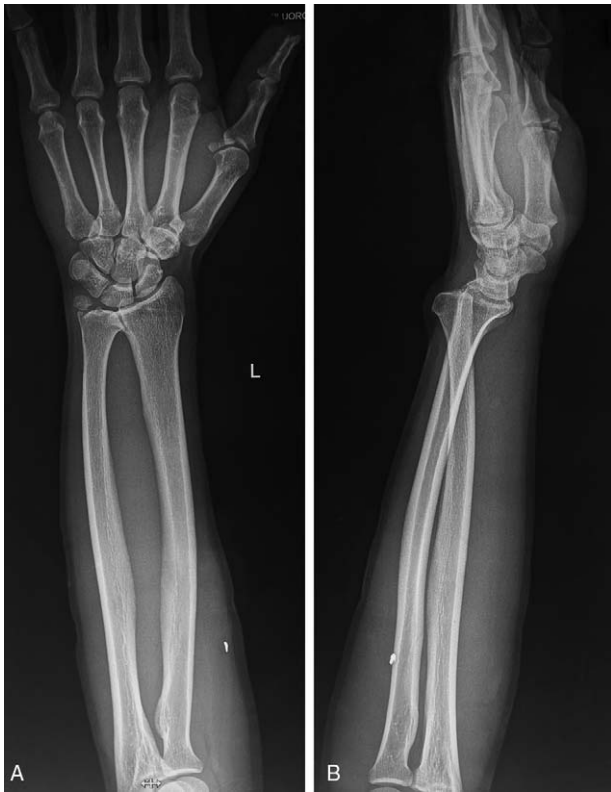

Figure 1. X-ray films of the foreign body. There was a 3-mm high-density shadow in the superficial soft tissue. Additionally, an old fracture of the left ulnar styloid process was found.

After preoperative preparation, the patient was placed under general anesthesia. A sterile tourniquet was placed for surgical treatment. Extending the left upper limb, the original wound was approximately 5 mm and was enlarged using a No 11 blade. The surgeons then probed the wound and traced the FB layer by layer.

Although there was some hematoma surrounding a thicker cephalic vein in the superficial fascia, the deep fascia was still intact. The FB was then imaged using a C-arm fluoroscope, which indicated that the approximate location was closer to the elbow joint than the original wound (Fig. 2A). Based on these results, a new 3-cm incision was made. The superficial tissues were gradually separated by the surgeons until an abnormal vein attracted attention. Though the vessel wall was intact, an unexpected ectogenic substance that seemed not to belong to a vessel was found within the vein. After re-examination with the C-arm fluoroscope, we confirmed that this lesion was the FB. Two sutures were placed to limit the movement of the FB, and a microincision was gently made along the long axis of the vessel (Fig. 3A–C). The FB was removed completely following the trimming of the intima using microscissors and microsutures on venous opening with a 10-0 suture (Ethicon, Inc., Johnson & Johnson, San Lorenzo, Puerto Rico) (Fig. 3D–F). C-arm fluoroscopy was used to examine the region for remnants of the FB, which were not found (Fig. 2B). Therefore, the incisions were closed after washing. The full process lasted 1 hour, and the FB was $3 \times 3 \times 1$ mm in size.

The patient was in good condition after the operation and did not have any cardiopulmonary dysfunction. Radiographic examination of the chest and left forearm on the following day showed no abnormalities. The patient stayed in the hospital for another 5 days and was then discharged. He was recovered well in the 6-month follow-up period.

3. Discussion

The FBs in the human body are a common surgical emergency, with an acute onset and rapid progression, usually with severe and complicated clinical symptoms. Commonly, the etiology of these injuries is traumatic or iatrogenic. Trauma usually triggers a complex pathogenesis that can easily result in misdiagnosis or no diagnosis. Gschwind reported a similar case where the FB was initially considered to be lodged in the soft tissues.^[7] In fact, the FB had migrated to one of the larger subcutaneous veins. In

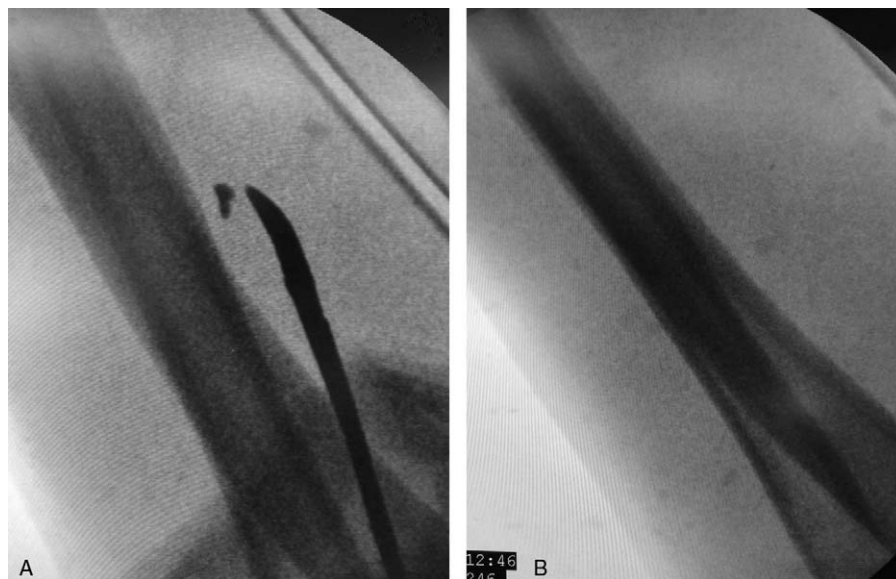


Figure 2. C-arm fluoroscope imaging during the operation. (A) At the beginning of the operation, the location of the foreign body was close to the elbow joint. (B) At the end of the operation, there was no obvious residue remaining.

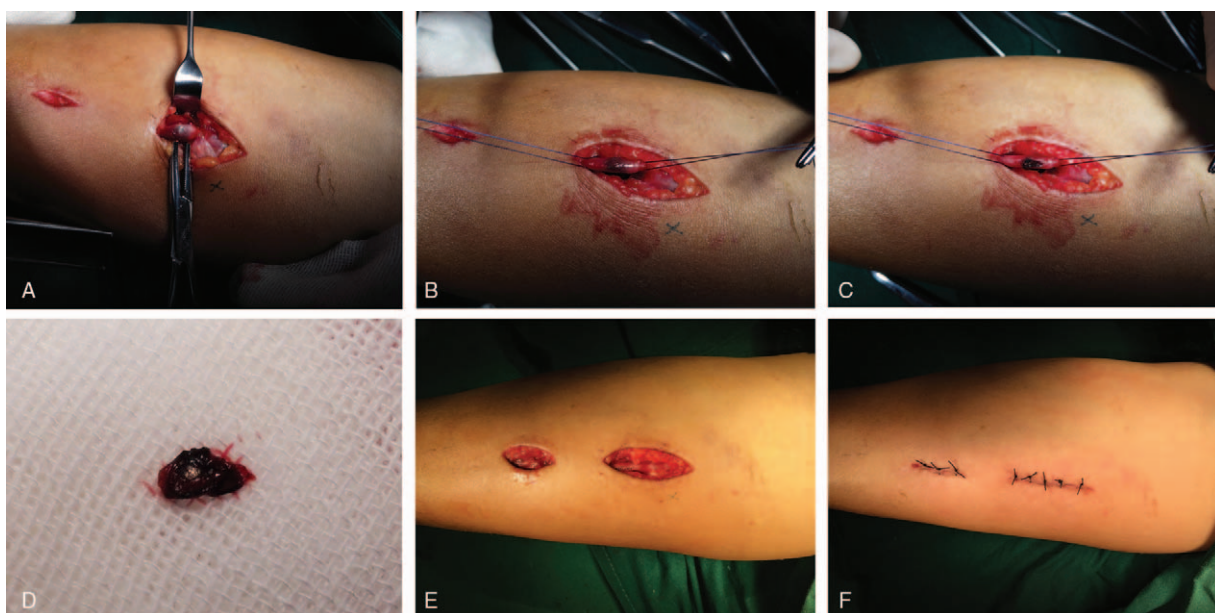


Figure 3. The operation procedure. (A–C) The foreign body (FB) was found and removed from the cephalic vein. (D) The FB was completely displayed. (E,F) The incision of the cephalic vein was repaired by microsuture.

general, FBs are difficult to find in the narrow passages of organs such as the esophagus, pharynx, bronchus vasculature, and heart. Most intractable types of FBs are those that appear in the vasculature, especially in the venous system. These cases may lead to embolization, infection, cardiac damage, or even death.^[8–11] The common types of these FB are needles,^[5] intravenous cannulas,^[4] guidewires,^[12] stents,^[13] inferior vena cava filter struts,^[14] and other objects (see Table 1).^[6,7,15,16,17–19] However, being a rare pathogenic factor, the more unconventional non-iatrogenic FB often requires more extensive treatment and diagnosis.

In terms of symptomatology, patients suffering from different intravascular FBs present various symptoms, according to the position of the FB. However, patients are usually asymptomatic,^[10,18] as was seen in the patient in this case report. Among symptomatic patients with FBs, local pain and discomfort are the

most common clinical manifestations. Shock arising from losing a large amount of blood may also occur in combat trauma patients.^[6]

The diagnostic method for an FB in a vein is relatively simple. X-ray photography, computed tomography, and angiography are commonly performed. Nevertheless, the diagnostic validity of these methods depends on the properties and density of the FB. There are 2 main types of FB: high-density FBs and low-density FBs. Metal fragments can be found by more-sensitive imagologic examinations.^[7,8,19] Contrastingly, low-density FBs rely more on angiography. If none of the above-mentioned methods are successful, directly retrieving the FB by operation or vascular intervention is the last choice.

There are 3 main aims of treatment: saving lives, removing the FB(s), and reducing relative complications. Therapeutic types fall into 2 categories: invasive treatments (such as operations and

Table 1

Cases of traumatic intravenous foreign body.

Author	Foreign body	Pathogenesis	Symptom	Diagnostic method	Final location	Retrieval method	Prognosis
Davey and Parker (1947) ^[6]	Shell fragment	War injury	Wound, hemorrhagic shock	X-ray	Upper anterior mediastinum, IVC, right internal iliac vein	Open operation	Palpitation with running
Gschwind ^a (2002) ^[7]	Piece of metal	Work injury	Wound, bleeding, altered sensibility in the ulnar 2 digits, weakness of the intrinsic	X-ray, cardiac ultrasound	The cephalic vein near the right cubital fossa, the right ventricle	Open operation, ligation of the vein	Occasional chest pain at rest, shortness of breath
Gschwind ^b (2002) ^[7]	Piece of metal	Work injury	Wound, bleeding	X-ray	The cephalic vein of the distal forearm	Open operation, ligation of the vein	Complete recovery
Nesargikar et al (2009) ^[15]	Piece of metal	Hammer injury	Wound, bleeding	X-ray, CT	Lower branch of the left renal vein	Angiography, stenting	Complete recovery
Bahçivan et al (2012) ^[16]	Piece of metal	Work injury	—	X-ray, echocardiography	Right ventricle	Open operation	—
Koirala et al (2012) ^[17]	Piece of metal	Hammer injury	Wound, slight bleeding	X-ray, CT	The azygous vein	Open operation, ligation of the azygous vein	—
Liu et al (2014) ^[18]	Piece of metal	—	—	X-ray, CT	The right ventricular cavity	—	Asymptomatic
Chen et al (2015) ^[19]	Piece of metal	Industrial accident	Wound	X-ray, CT, echocardiography	The IVC near the phrenic nerve	Open operation, magnet sucking	—

CT=computed tomography, IVC=inferior vena cava.

There are two cases in this reference. To distinguish these two cases clearly, we use “a” and “b” to stand for the different case.

vascular interventions) and conservative treatments (based on patient requirements). Combining the previous report with our experience, we created an animation that depicts the pathogenesis of this rare FB (see Video 1, <http://links.lww.com/MD/C294>). In general, open operations have commonly been performed to remove FBs lodged in superficial veins.^[7,19] For vascular interventions, minimally invasive surgical technology seems more proficient for interventional radiologists. This method of retrieval is particularly useful for FBs in the heart.^[8] In a previous report, surgeons were inclined to ligate the damaged veins.^[6,7] However, in this case, we used a microscopic suture technique to repair the cephalic vein and minimized the damage to the patient. Additionally, anti-infection treatment and anticoagulation are both equally important to ensure the success of the therapy.^[7,8] Follow-up can evaluate the patient's status and detect the outcome of the treatment.^[18]

4. Conclusion

Intravenous FB migration in the venous system is rare. These cases are commonly triggered by traumatic and iatrogenic factors. For traumatic cases, both the cause of the injury and the radiographic results should be considered to make a correct diagnosis. More attention should be given to monitoring the vital signs of patients. The key preconditions for treatment are respecting the patient's attitude, removing the FB and protecting the function of the affected area. Postoperative anticoagulation and anti-infection therapy are essential. The patient should receive follow-up care to observe their prognosis. This case report indicated that an FB in the superficial tissue required diagnosis and accurate location. X-ray and C-arm fluoroscope imaging should be combined with the patient's medical history to ensure that sufficient preoperative preparations are made.

Author contributions

MS contributed to diagnosing the case, performing the operation, seeking references and manuscript writing. JF and ML were responsible for our manuscript. MW contributed to the critical revision of the manuscript for intellectual content. ZS and LL helped to write and to revise the manuscript. All authors read and approved the final manuscript.

Conceptualization: Mingzhi Song.

Methodology: Mingzhi Song, Mozhen Liu.

Supervision: Jifeng Fan, Mozhen Liu.

Writing – original draft: Mingzhi Song.

Writing – review & editing: Mingzhi Song, Maohua Wei, Ze Song, Liang Li.

References

- [1] Dell'Amore A, Ammari C, Campisi A, et al. Peripheral venous catheter fracture with embolism into the pulmonary artery. *J Thorac Dis* 2016;8:E1581–4.
- [2] Wendt JR, Ackley SM. Vascular complications of a foreign body in the hand of an asymptomatic patient. *Ann Plast Surg* 1995;34:92–4.
- [3] Glassberg E, Lending G, Abbou B, et al. Something's missing: peripheral intravenous catheter fracture. *J Am Board Fam Med* 2013;26:805–6.
- [4] Singh A, Kaur A, Singh M, et al. CT guided removal of iatrogenic foreign body: a broken intravenous cannula. *J Clin Diagn Res* 2015;9:D28–9.
- [5] Low GS, Jenkins NP, Prendergast BD. Needle embolism in an intravenous drug user. *Heart* 2006;92:315.
- [6] Davey WW, Parker GE. The surgical pursuit and removal of a metallic foreign body from the systemic. *Br J Surg* 1947;34:392–5.
- [7] Gschwind CR. The intravenous foreign body: a report of 2 cases. *J Hand Surg Am* 2002;27:350–4.
- [8] Suarez-Penaranda JM, Guitian-Barreiro D, Concheiro-Carro L. Long-standing intracardiac catheter embolism. An unusual autopsy finding. *Am J Forensic Med Pathol* 1995;16:124–6.
- [9] Balbi M, Bertero G, Bellotti S, et al. Right-sided valvular endocarditis supported by an unexpected intracardiac foreign body. *Chest* 1990;97:1486–8.
- [10] Denny MA, Frank LR. Ventricular tachycardia secondary to Port-a-Cath fracture and embolization. *J Emerg Med* 2003;24:29–34.
- [11] Gabelmann A, Kramer S, Gorich J. Percutaneous retrieval of lost or misplaced intravascular objects. *AJR Am J Roentgenol* 2001;176:1509–13.
- [12] Cat BG, Guler S, Soyuduru M, et al. Complete guidewire retention after femoral vein catheterization. *Ann Saudi Med* 2015;35:479–81.
- [13] Ho JM, Kahan J, Supariwala A, et al. Vascular stent fracture and migration to pulmonary artery during arteriovenous shunt thrombectomy. *J Vasc Access* 2013;14:175–9.
- [14] Shennib H, Bowles B, Hickie K. Migration of a fractured inferior vena cava filter strut to the right ventricle of the heart: a case report. *J Cardiothorac Surg* 2014;9:183.
- [15] Nesargikar PN, Grannell M, Hinwood D, et al. Newton's Law to the rescue: therapeutic effects of gravity aiding the management of a migratory venous foreign body - a case report. *Vasc Endovascular Surg* 2009;43:406–9.
- [16] Baçıvan M, Duran L, Çelik S, et al. Migration of a foreign body to the right ventricle following traumatic penetration to the right subclavian vein. *Anadolu Kardiyol Derg* 2012;12:531–2.
- [17] Koirala B, Shrestha KR, Thapa B, et al. Migration of a piece of shrapnel femoral vein to superior vena cava-azygous junction. *Eur J Cardiothorac Surg* 2012;42:584–6.
- [18] Liu H, Juan YH, Wang Q, et al. Foreign body venous transmigration to the heart. *QJM* 2014;107:743–5.
- [19] Chen Y, Sun C, Wang J, et al. Migration of a metallic foreign body into the heart. *J Card Surg* 2015;30:891–3.