




NSTEMI with total left circumflex occlusion: how the N-wave might help (case report)

Mochamad Yusuf Alsagaff ^{1,2,*}, Louisa Fadjri Kusuma Wardhani ¹, Iswanto Pratanu¹,
Dian Paramita Kartikasari^{1,2} and Pieter A. Doevendans ³

¹Department of Cardiology and Vascular Medicine, Faculty of Medicine, Airlangga University-Dr Soetomo General Hospital Surabaya, Surabaya, Indonesia

²Cardiology Department, Universitas Airlangga Hospital, Surabaya, Indonesia

³Department of Cardiology, University Medical Center Utrecht, Utrecht, Netherland

*Correspondence address: Department of Cardiology and Vascular Medicine, Faculty of Medicine, Airlangga University-Dr Soetomo General Hospital Surabaya, Jalan Mayjen Prof. Dr. Moestopo No. 6-8, Surabaya 60286, Indonesia. Tel: +62 8123543388; E-mail: yusuf_505@fk.unair.ac.id

Abstract

A rise and/or fall in troponin level is an indication of type 1 or 2 myocardial infarct. A 62-year-old male physician presented to emergency room with chest discomfort followed by thought to be normal electrocardiogram (ECG) and normal echocardiography results. His serial hs-troponin test showed remarkable escalation three hours from the initial (107 ng/l into 4.978 ng/l), suggesting a high-risk non-ST-segment myocardial infarction (NSTEMI). An early invasive procedure was performed, showing acute total occlusion (TO) in the obtuse marginal 1 branch. We retrospectively reviewed our examination to diagnose better the presence of TO in NSTEMI patients presented with non-diagnostic examination. Our evaluation showed a minor change in the form of an 'N-wave' pattern on the ECG, which was not yet an established guideline criterion for prompt angiography. Although ECG pattern is often normal in LCx occlusion, recent study shows the presence of 'N-wave' ECG pattern in 10% of NSTEMI cases following TO at LCx.

INTRODUCTION

The electrocardiogram (ECG) is an essential diagnostic tool in acute coronary syndrome (ACS), as its availability and usability in determining the involvement of ST-segment myocardial infarction (STEMI). Unfortunately, over 25.5% of total occlusions (TO) present without classic ST-T changes on the surface ECG [1–4]. These subgroups of patients are identified as STEMI-equivalent, one of whom was characterized by the presence of an N-wave. N-waves are present in 10% of non-ST-segment myocardial infarction (NSTEMI) patients and associated with an equivalent risk with STEMI patients. The recognition of N-waves can be helpful to determine urgent revascularization. The study conducted by Meyers *et al.* stated that ECG findings other than ST-elevation criteria could identify TO sooner and more accurately [5–8].

CASE REPORT

A 62-year-old male physician presented to the emergency room with a 2-hour history of migratory discomfort involving epigastric, back and central chest. The pain was episodic, non-radiating and migrated from place to place. He initially had a one-month history of non-steroidal anti-inflammatory drug consumption due to toothache.

He used self-prescribed intravenous anti-dyspepsia, anti-spasmodic, sublingual nitrates and even a Fentanyl patch to relieve his symptoms. The treatment obscured the major complaint, with a 7/10 score on the pain scale. As he seemed anxious, 2 mg of morphine was given to relieve symptoms.

The patient was alert and had no history of hypertension, diabetes mellitus, smoking and previous chest pain. His physical examination was within the normal limits, with blood pressure 130/84 mmHg, heart rate 74 bpm, oxygen saturation 94% (room air) and respiratory rate 20 per minute.

ECG revealed normal sinus rhythm without signs of ischemia (Fig. 1A). Blood samples showed an increase in troponin (107 ng/l), which drove suspicion of ACS. Further cardiac examination was planned with the re-evaluation of possible ECG changes, 3-hour cardiac troponin (cTn) samples and echocardiogram.

The ECG re-examination with additional right and posterior segments appeared normal, without significant changes (Fig. 1B–D). The echocardiogram (Fig. 2) showed normal cardiac chambers with no regional wall motion abnormalities.

Clinical, ECG and echocardiography examinations weren't diagnostic for Myocardial Infarction (MI) as

Received: August 9, 2021. Revised: December 13, 2021. Accepted: January 11, 2022

© The Author(s) 2022. Published by Oxford University Press. All rights reserved. For Permissions, please email: journals.permissions@oup.com

This is an Open Access article distributed under the terms of the Creative Commons Attribution-NonCommercial License (<http://creativecommons.org/licenses/by-nc/4.0/>), which permits non-commercial re-use, distribution, and reproduction in any medium, provided the original work is properly cited. For commercial re-use, please contact journals.permissions@oup.com

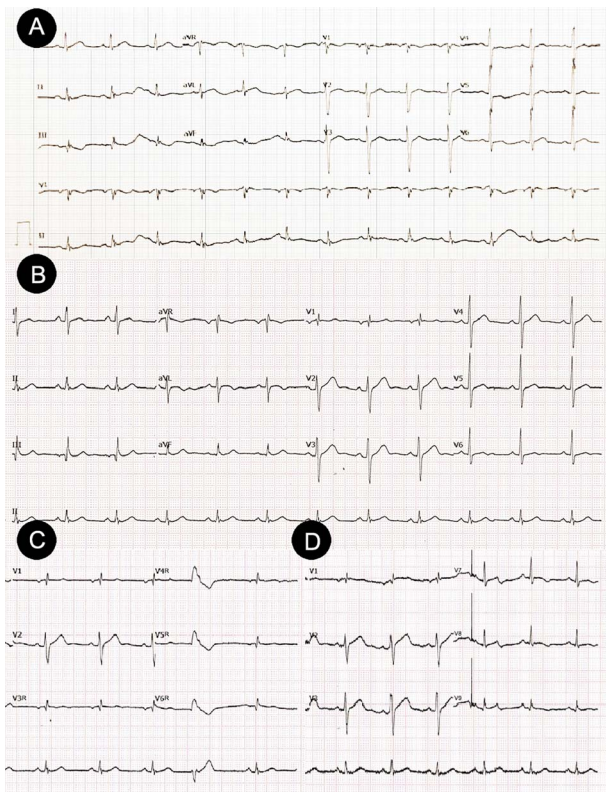


Figure 1. electrocardiogram performed during examination in ED. (A) ECG during the first 10 minutes patient arrived in emergency department (ED) showed sinus rhythm without sign of ischemia. (B) ECG performed 3 hours after initial examination showed no significant changes. (C) Re-evaluation ECG showing right ventricular (RV) segments showed normal sinus rhythm with occasional premature ventricular contraction. (D) Re-evaluation ECG showing posterior segments showed normal sinus rhythm.

HEART score classified him as low risk (Risk of MACE 0.9–1.7%). However, there was a remarkable escalation of repeated hs-Troponin (4978 ng/l), which is associated with high-risk NSTEMI. According to our laboratory protocol, the repeated hs-Troponin measurement was performed within 3-hour intervals. Due to the pronounced hs-troponin spike, widespread, ongoing ischemia was suspected, and an immediate invasive strategy was preferred.

An initial 300 mg aspirin and 180 mg of ticagrelor were given. Inpatient diagnostic coronary angiography (CAG) was carried out via femoral approach (Fig. 3A–C), revealing multiple stenoses and ectasis. Driven by high hs-troponin following an atypical presentation of ACS, careful observation of the CAG resulted in recognizing an ostial TO of the obtuse marginal 1 (OM1) branch. A late contrast-filled vessel at the anterolateral region of the myocardiogram (Fig. 3D–E) was believed to be a hidden culprit lesion.

Due to the tortuosity, a Hi-Torque Versaturn Abbott Guiding Wire was used unsuccessfully (Fig. 3F). Next, a GW Fielder XT was used and managed to enter the total lost OM1 branch (Fig. 3G). Further procedures were routine, with predilatation balloon and implantation of a sirolimus-eluting stent at the proximal LCx to the OM1

branch (Fig. 3H). An immediate invasive strategy was performed with an established TIMI-3 flow through IRA, and the symptoms were immediately resolved after the procedure (Fig. 3I).

DISCUSSION

We present a case of patient with migratory discomfort and history of initial self-prescribed drugs, which probably masked unstable angina and clinical presentation. Routine evaluations of ACS were performed, which showed thought to be normal serial ECG, normal echocardiography findings and the spike in high sensitivity cardiac troponin (hs-cTn). Driven solely by the astounding elevation of hs-cTn, CAG was carried out and showed TO of OM1 branch. An immediate invasive strategy was performed with good results.

The presence of TO showed a gap between ECG pattern and spike of the hs-cTn result. The possible reason is due to the LCx occlusion, which is known as the 'blind area'. Around 30% of patients with LCx occlusion might show a non-diagnostic ECG since the standard 12-leads are not applied facing the inferolateral wall, mainly supplying the basal part of the left ventricle [6, 9]. There has been a shift in the literature toward finding ECG patterns highly suggestive of TO. Niu et al., were the first to report the presence of the so-called 'N-wave' and the involvement of the QRS complex in LCx occlusion. N-waves is defined as (i) a notch or deflection in the terminal QRS complex on the surface ECG; (ii) the height of the notch or deflection of > 2 mm; (iii) a continuous change of the notch in 24 hours, even disappearance or transition into the s wave and (iv) prolongation of QRS duration in these leads marks the delayed activation of the ischemic zone. The presence of N-wave in the lead II, III, AVF is associated with 77% sensitivity and 89% specificity of LCx lesion, respectively [5, 6, 9, 10].

Right after the Percutaneous Coronary Intervention (PCI) procedure, a comprehensive re-assessment was made. We realized the decision to perform an immediate invasive strategy was based on vague symptoms, 'normal ECG' and spike Delta/changes hs-Troponin with an interval of 3 hours. However, after noticing the inferior leads N-wave (Fig. 4), we believe it could have shortened the ischemic time by much faster decision and investigation focusing on the LCx. It is estimated that 27% of NSTEMI patients have an occluded infarct artery, more frequently found in an artery supplying the inferolateral wall. The simple bedside N-wave pattern could be an additional diagnostic tool to unmask the TO, which certainly needs prompt reperfusion (STEMI-Equivalent) [5, 6, 9].

The diagnostic work-up in our patient was driven by a surge in hs-troponin since serial ECG and echocardiogram were non-diagnostic for AMI. A re-evaluation of ECG after immediate invasive strategy showed the presence of N-wave and delayed activation of QRS complex, which is consistent with LCx occlusion. We found a pitfall in recognizing this pattern as it hasn't been

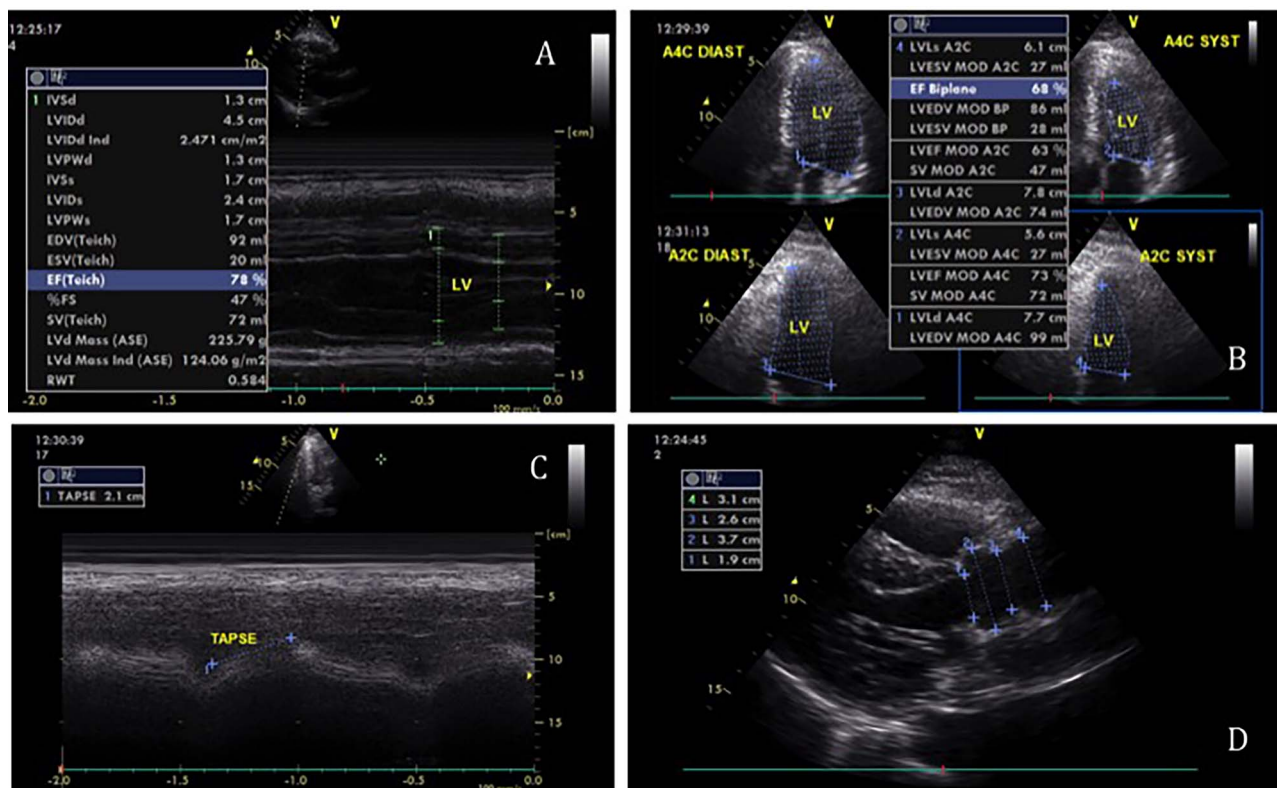


Figure 2. echocardiogram showed (A) normal cardiac chamber, normal LVEF, concentric LVH; (B) normal biplane LVEF; (C) normal RV systolic function; (D) no dilatation of aortic root. LVEF = left ventricular ejection fraction; LVH = left ventricular hypertrophy; RV = right ventricular.

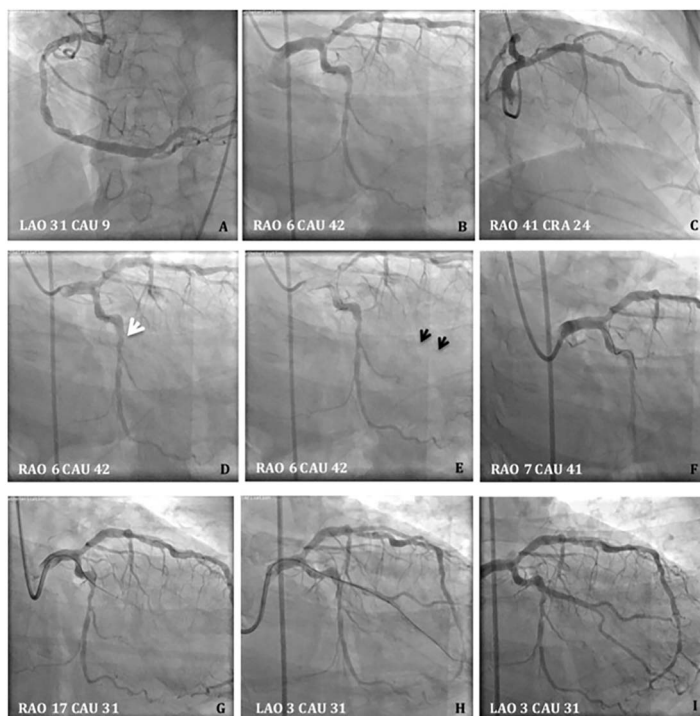


Figure 3. diagnostic CAG was performed (A–C). It showed CAD SVD with multiple stenosis and ectasis. percutaneous coronary intervention performed in total occlusion of OM1 branch left circumflex artery. (D) Total occlusion of OM1 branch (a clean cut of OM1 branch as shown by white arrow); (E) slow contrast filling at the anterolateral region of the myocardium (showed by black arrow); (F) trial penetrating culprit lesion using Hi-torque versaturn GW due to the tortuosity. Unfortunately, it was bent and couldn't pass through a small bump; (G) another trial penetrating lesion using GW Fielder XT. It managed to get through a belief TO of OM1 branch; (H) stenting using 3.0 x 24 mm Sirolimus-Eluting stent from the proximal part of LCx into OM1 branch. Stent was then inflated to 12 atmospheres; (I) the final result of PCI showing TIMI Flow 3 of OM1 branch. The symptoms were immediately resolved after PCI procedure.

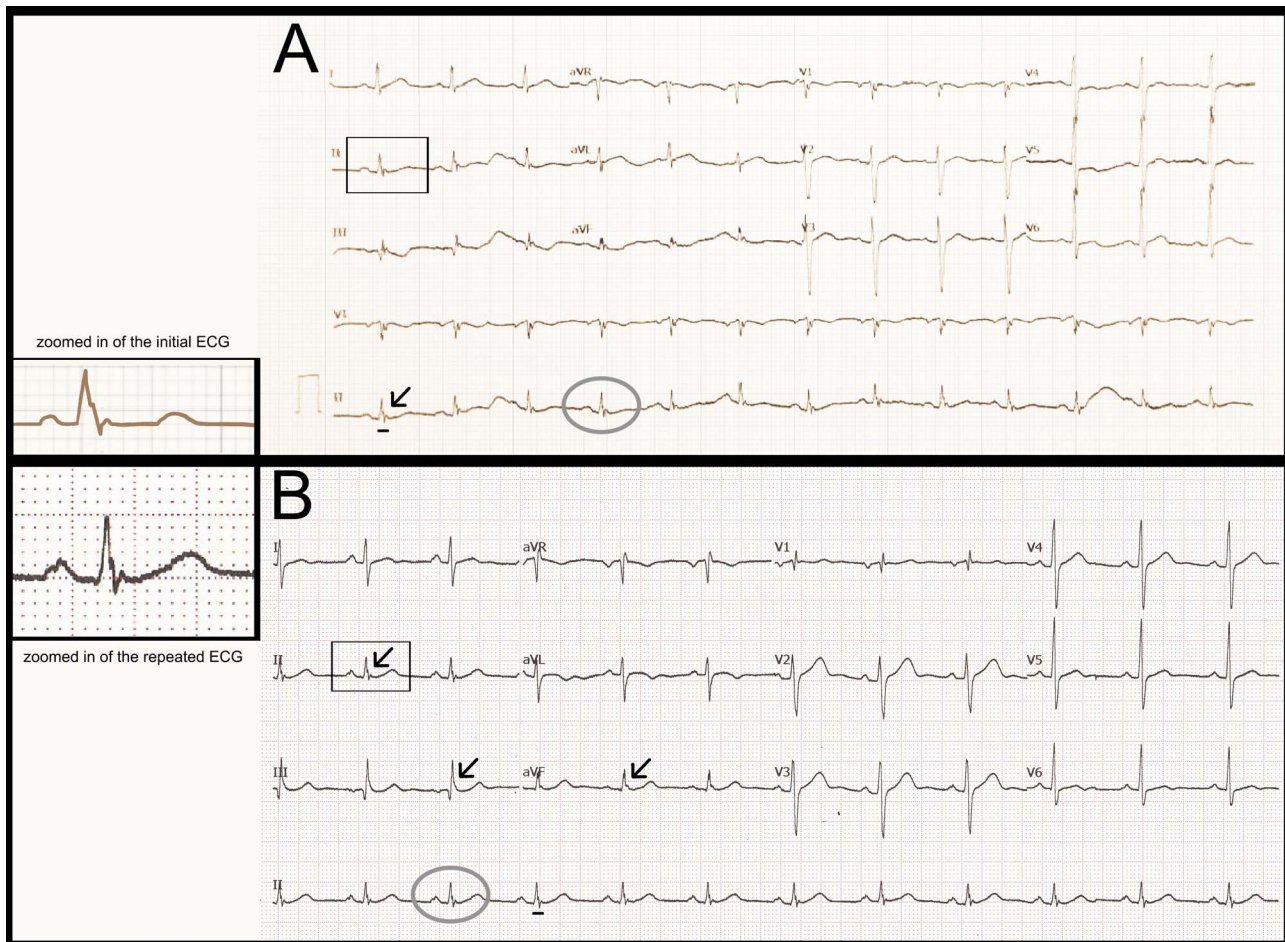


Figure 4. an electrocardiogram showing the so-called 'N-wave' in the inferior leads is consistent with left circumflex occlusion (OM1 branch). Noted the presence of N-waves in the initial ECG (A) and repeated ECG (B). The presence of N-waves in our cases is consisted of (i) a notch or deflection in the terminal QRS complex on the surface ECG (black arrows in the inferior lead); (ii) the height of the notch or deflection of 3 mm (oval box) and (iii) prolongation of QRS duration in inferior leads (black lines)

listed in recent guidelines. A thorough evaluation of STEMI-equivalent pattern ECG might be helpful for a clinician in determining the revascularization timing.

DATA AVAILABILITY

Not applicable.

AUTHORS' CONTRIBUTIONS

M.Y.A., L.F.K. and D.P.K. designed the conceptualization of the case report. M.Y.A. and D.P.K. collect patients' data. M.Y.A. lead case analysis. M.Y.A. and L.F.K. wrote the first draft. M.Y.A., L.F.K., D.P.K., I.P. and P.A.D. revised and approved the final version of the manuscript.

ACKNOWLEDGEMENTS

We thank all Departement of Cardiology and Vascular Medicine Airlangga University colleagues for their support.

CONFLICT OF INTEREST STATEMENT

None declared.

ETHICS APPROVAL AND CONSENT TO PARTICIPATE

Not applicable.

CONSENT FOR PUBLICATION

Written informed consent was obtained from the patient to publish this case report and any accompanying images. A copy of the written consent is available for review by the Editor-in-Chief of this journal.

REFERENCES

1. Chase M, Brown AM, Robey JL, Pollack CV, Shofer FS, Hollander JE. Prognostic value of symptoms during a normal or nonspecific electrocardiogram in emergency department patients with potential acute coronary syndrome. *Acad Emerg Med* 2006;**13**: 1034-9. <https://doi.org/10.1197/j.aem.2006.06.051>.

2. Halpern EJ. Triple-rule-out CT angiography for evaluation of acute chest pain and possible acute coronary syndrome. *Radiology* 2009;**252**:332–45. <https://doi.org/10.1148/radiol.2522082335>.
3. Authors/Task Force Members, Hamm CW, Bassand JP, Agewall S, Bax J, Boersma E, et al. ESC guidelines for the management of acute coronary syndromes in patients presenting without persistent ST-segment elevation. *Eur Heart J* 2011;**32**:2999–3054. <https://doi.org/10.1093/eurheartj/ehr236>.
4. Khan AR, Golwala H, Tripathi A, Bin Abdulhak AA, Bavishi C, Riaz H, et al. Impact of total occlusion of culprit artery in acute non-ST elevation myocardial infarction: a systematic review and meta-analysis. *Eur Heart J* 2017;**38**:3082–9. <https://doi.org/10.1093/eurheartj/ehx418>.
5. Niu T, Fu P, Jia C, Dong Y, Liang C, Cao Q, et al. The delayed activation wave in non-ST-elevation myocardial infarction. *Int J Cardiol* 2013;**162**:107–11. <https://doi.org/10.1016/j.ijcard.2011.05.063>.
6. Yang T, Chen J, Liu X, Xu C, Niu T, Fu X, et al. Non-ST-elevated myocardial infarction with “N” wave onelectrocardiogram and culprit vessel in left circumflex has a risk equivalent to ST-elevated myocardial infarction. *Clin Cardiol* 2019;**43**:491–49.
7. Wall J, White LD, Lee A. Novel ECG changes in acute coronary syndromes. Would improvement in the recognition of ‘STEMI-equivalents’ affect time until reperfusion? *Intern Emerg Med* 2018;**13**:243–9. <https://doi.org/10.1007/s11739-016-1595-3>.
8. Pendell Meyers H, Bracey A, Lee D, Lichtenheld A, Li WJ, Singer DD, et al. Accuracy of OMI ECG findings versus STEMI criteria for diagnosis of acute coronary occlusion myocardial infarction. *IJC Heart Vasc* 2021;**33**:1–9. <https://doi.org/10.1016/j.ijcha.2021.100767>.
9. Wang TY, Zhang M, Fu Y, Armstrong PW, Newby LK, Gibson CM, et al. Incidence, distribution, and prognostic impact of occluded culprit arteries among patients with non – ST-elevation acute coronary syndromes undergoing diagnostic angiography. *Am Heart J* 2009;**157**:716–23. <https://doi.org/10.1016/j.ahj.2009.01.004>.
10. Moustafa A, Abi-Saleh B, El-Baba M, Hamoui O, AlJaroudi W. Anatomic distribution of culprit lesions in patients with non-ST-segment elevation myocardial infarction and normal ECG. *Cardiovasc Diagn Ther* 2016;**6**:25–33. <https://doi.org/10.3978/j.issn.2223-3652.2015.10.05>.