



# Treating Acne in Transgender Persons Receiving Testosterone: A Practical Guide

Rakan Radi<sup>1</sup> · Sarah Gold<sup>1</sup> · Juan P. Acosta<sup>2</sup> · Jason Barron<sup>1</sup> · Howa Yeung<sup>1,3</sup>

Accepted: 7 December 2021 / Published online: 11 January 2022

This is a U.S. government work and not under copyright protection in the U.S.; foreign copyright protection may apply 2022

## Abstract

Transgender persons who undergo masculinizing hormone therapy experience a wide array of dermatologic effects as they initiate and maintain testosterone therapy. Acne is one of the most common adverse effects for many transmasculine patients receiving testosterone. Acne can worsen body image and mental health, with significant impact on quality of life in transgender patients. Specific training and awareness are needed for a clinically and culturally competent encounter while providing care for the transgender patient. This article provides a practical guide for the treatment of testosterone-induced acne in transmasculine patients. Recommendations on creating a welcoming clinical setting, taking a gender-inclusive history, and conducting a patient-centered physical examination relevant to acne care are provided. Assessment of reproductive potential and the appropriate contraceptive methods before prescribing acne treatment with teratogenic potential in transmasculine patients are examined. Interactions between acne treatments with gender-affirming therapies are explored. For patients with severe or treatment-refractory acne, indications, contraindications, and barriers to isotretinoin prescription, such as the US iPLEDGE program, are examined. Multidisciplinary approaches to acne care, involving mental health, reproductive health, gender-affirming hormone therapy and surgeries, are adopted to guide isotretinoin treatment.

## Key Points

Acne is a common and distressing adverse effect of gender-affirming testosterone therapy faced by transgender and non-binary patients.

Dermatologists should address acne and its specific multidisciplinary considerations in the context of testosterone therapy in an inclusive environment.

Recent iPLEDGE changes may reduce barriers to isotretinoin treatment for severe acne for transgender patients.

## 1 Introduction

Acne vulgaris is a common skin condition affecting 9.4% of the global population [1], representing the second highest cause of disability from skin diseases globally [2]. Acne has multifactorial etiologies that include hormones, inflammation, stress, and medications [3, 4]. Hormonal acne is caused in part by sebum overproduction due to endogenous androgens such as dehydroepiandrosterone, dehydroepiandrosterone-sulfate, androstenedione, testosterone, and dihydrotestosterone [3]. Estrogen, on the other hand, reduces sebum production [3]. Hormonal acne tends to cluster in areas that exhibit higher dihydrotestosterone selectivity, such as the lower face, chin, and jawline [3, 5]. Hormonal acne can be more pronounced in patients receiving exogenous androgens, affecting the chest, upper arms, and back [6]. Exogenous testosterone therapy is indicated for cisgender men for hypogonadism, cisgender women for hypoactive sexual desire disorder, and transgender persons as part of gender-affirming masculinizing hormone therapy [3, 7–10]. The aim of this article was to review the epidemiology and impact of acne, overall approach to acne care and terminologies, and management for mild to severe acne and specific considerations for isotretinoin.

Rakan Radi and Sarah Gold contributed equally to this work.

✉ Howa Yeung  
howa.yeung@emory.edu

<sup>1</sup> Department of Dermatology, Emory University School of Medicine, Atlanta, GA, USA

<sup>2</sup> State University of New York Upstate Medical University, Syracuse, NY, USA

<sup>3</sup> Clinical Resource Hub, Veterans Affairs Southeast Network Veterans Integrated Service Network 7, Decatur, GA, USA

## 1.1 Terminology and Definitions

Transgender persons are persons whose gender identity or expression diverges from their sex assigned at birth [11]. The adjective ‘trans’ is also commonly used to refer to transgender among transgender community members. Gender identity is defined as the internal sense of being a man, a woman, or some other gender. For example, a transgender man is a person whose sex assigned at birth was female and identifies as a man. Since gender identity expands beyond binary constructs of male and female, the term ‘transmasculine persons’ is used inclusively to refer to transgender persons who were assigned female at birth who do not identify as women, such as transgender men and gender non-binary persons. Many transgender persons seek gender-affirming therapies aimed to alleviate gender dysphoria and to improve mental and overall well-being [12]. These treatments may include gender-affirming hormone therapy, surgical procedures, social transitions in gender expression, and/or psychotherapy. This paper focuses on understanding and treating acne that develops in transmasculine patients who receive gender-affirming testosterone therapy (often known as ‘T’) to achieve masculinization as congruent with their gender identity.

## 2 Epidemiology and the Impact of Acne in Transgender Persons

Transmasculine persons who receive testosterone tend to develop hormonal acne in similar locations to other forms of androgen-dependent acne, affecting the lower third of the face, chest, upper arms, and back [5, 6]. Epidemiologic studies of acne in transmasculine persons have mostly relied on limited data from single-center retrospective cohort or self-reported survey studies. In a large, single-center, retrospective cohort of 988 transmasculine patients in Boston, the prevalence of acne increased from 6.3% before testosterone therapy to 31.1% after initiating testosterone for an average of 3.4 years [13]. Younger age at the time of testosterone initiation was associated with a higher incidence of acne diagnosis [13]. In a small cohort study of 20 transmasculine patients in New York, facial and truncal acne diagnoses increased over 4 months of treatment from 35 to 82% and from 15 to 88%, respectively [14]. Acne severity increased over the first 6 months of testosterone therapy, but started to decrease by 12 months [14]. As to the timing of onset for testosterone-induced acne, most patients developed acne within 2 years of testosterone treatment [15]. Serum testosterone has been inconsistently linked with acne development. In a single-center study of 55 transgender men, serum testosterone above the study median ( $> 630$  ng/mL) was associated

with higher odds of acne diagnosis after 2 years [15]. On the other hand, in a study of 138 transmasculine patients in Okayama, Japan, no acne of ‘troublesome degrees’ was noted after testosterone treatment for 6 months; however, acne severity was not well defined in this study [16].

Testosterone-induced acne can be severe and persistent in transmasculine persons. For example, 28% of transmasculine persons have reported a history of moderate to severe acne and 14% reported current moderate-to-severe acne in a survey of 346 transmasculine persons across Kaiser Permanente health systems [17]. Moreover, 66% of transmasculine persons diagnosed with moderate-to-severe acne associated their acne with testosterone therapy [17]. Regarding long-term acne, after an average of 10 years of testosterone treatment, 63% of patients still had mild acne while 6% had moderate acne in a small survey of 50 transgender men in Belgium [14]. Nonetheless, transmasculine persons were significantly less likely to see dermatologists than transfeminine persons [17], suggesting access barriers to dermatologic care for transmasculine patients with acne.

Chest binders are sometimes used by transmasculine patients to achieve a more masculine contour and to reduce gender dysphoria. However, excessive skin occlusion, physical compression, and overheating may increase the risks of acne, skin swelling, itching, skin infection, and scarring over the chest and back [18]. A large community-engaged online survey of 1800 transmasculine persons found that acne developed in 33.3 and 48.6% of patients after chest binding for 1 year and 10 years, respectively [18].

In contrast, for transfeminine patients, who were assigned male at birth, feminizing hormone therapy commonly includes estrogen and/or anti-androgens such as spironolactone [7]. Corollary to the use of estrogen-containing contraceptives and spironolactone for the treatment of moderate-to-severe acne in cisgender women, these treatments often improve acne for transfeminine persons [4, 7]. In a large survey of 350 transfeminine persons, transfeminine persons rarely reported current moderate-to-severe acne [17].

Acne negatively impacts mental health and quality of life in transgender persons receiving testosterone. Transgender and gender non-binary persons are more likely to have mental health comorbidities, such as anxiety or depression [19]. While gender-affirming hormone therapy has been shown to improve quality of life and reduce anxiety and depression symptoms [20], it should not be assumed that their adverse cutaneous effects, such as acne, are transient or innocuous. Subjective severity of acne has correlated directly with symptoms of anxiety and depression [21]. Visible acne lesions or acne scars can be stigmatizing, especially for patients who struggle with body image disorders. For transmasculine patients, acne and acne scars resulting from gender-affirming testosterone therapy might trigger self-image insecurity and body dysmorphia [22]. Notably, some

transmasculine adolescents have viewed acne as a concrete sign for physical transition, which required more aggressive treatment, but also acknowledged that topical acne care may trigger dysphoria for some patients due to associated feminine connotations [23]. Recent data showed that transmasculine individuals diagnosed with moderate-to-severe acne were more likely to report clinically significant depression and anxiety symptoms compared with transmasculine persons without moderate-to-severe acne [24]. Notably, 71 and 39% of transmasculine persons with moderate-to-severe acne reported clinically significant depression and anxiety, respectively [24]. Dermatologists, primary care and hormone providers, and mental health providers should be aware of the epidemiology of acne and its associated negative mental health and psychosocial impact to provide timely and comprehensive acne care for transmasculine patients receiving testosterone therapy.

### 3 Clinical Guidance and Overall Approach to Care

Before acne assessment and treatment planning can even begin, it is critical to engender a welcoming clinical environment that prepares for a successful visit. Many transgender patients have had negative healthcare experiences—being misgendered, denied care, or frank harassment within healthcare settings [25]. Transgender men are more likely than transgender women to avoid health care due to anticipated discrimination [25]. Lack of providers knowledgeable in transgender health care, inadequate insurance coverage, socioeconomic barriers, and healthcare system barriers impose additional obstacles for transgender persons in accessing healthcare [26]. Having inclusive intake forms that do not assume cisgender identity or heteronormativity, having gender-neutral or all-gender restrooms available or allowing patients to use the restroom of their choice, posting welcoming signs or non-discrimination policies are all part of important efforts to create an inclusive environment that cultivates therapeutic relationships [11].

Familiarity with common and gender-inclusive terminology can facilitate discussion, but it is important for providers and staff members to use patient-centered language, including using the patient's name and pronouns, as well as their terms for sexual orientation, gender identity, sexual behavior, or anatomy [11, 27, 28]. Some patients may use a name that differs from the name listed in medical records or legal documents [29]. Pronouns should not be assumed based on a person's gender expression. Ideally, demographic information such as name, pronouns, sexual orientation, and gender identity should be routinely collected upon intake and documented in the medical records prior to the patients' visit to facilitate care. Routine collection of sexual orientation and

gender identity is highly acceptable to patients and has been advocated in outpatient dermatology care [30, 31]. If not already available on the intake form, asking about and documenting name and pronouns as well as taking an inclusive history will be important [32]. When the provider introduces themselves, they may consider offering the names and pronouns they use or employ non-verbal cues (such as pronoun pins) to signal a gender-inclusive care environment.

While taking history, using gender-inclusive language for all patients can help facilitate open and non-judgmental discussion about relevant history, particularly those related to sex and gender [33]. That way, providers would be more considerate and play an essential role in promoting sexual awareness and inclusivity. Examples of some questions that may come up in an encounter in a gender-neutral manner are listed in Table 1 [33]. When conducting a physical examination, providers should explicitly ask for patient permission and focus on body parts relevant to the chief complaint [34]. Truncal examinations may be unexpected by some patients, especially for those who wear chest binders [18].

Accordingly, both the provider and the patient should discuss the reasoning behind the skin examination, discuss mutual expectations for current and future encounters, and empower the patient to take the lead in showing the provider what is comfortable and relevant for their acne care [32].

### 4 Anatomic Inventory, Sexual History Taking, and Reproductive Potential Assessment

Many acne treatments have teratogenic potential and warrant a comprehensive sexual health and contraception discussion before prescription [35]. When conducting an organ inventory, it is important to check in with the patient to ensure that they are comfortable with the words used. Providers should refrain from using the words 'breast' and 'vagina' or 'penis' and instead use 'chest', and 'genitalia', respectively, to avoid triggering gender dysphoria in patients who are not comfortable with the aforementioned words [33]. As gender identity is distinct from sexual orientation or behavior, transgender patients' sexual orientation and sexual behaviors should not be assumed [8]. Of note, transmasculine patients with retained functional uterus and ovaries have become pregnant, whether during and after testosterone therapy [36]. Transmasculine persons assigned female at birth who have a functional uterus and ovary should be considered as being of reproductive potential and would still need to consider contraceptive needs, even if they currently receive testosterone therapy and are currently amenorrheic [37]. On the other hand, transmasculine patients who have

**Table 1** Example language for history taking for acne encounters with transmasculine patients

## Provider question checklist for transmasculine patients

## Introduction

Tell the patient your name and pronouns

## Name and pronouns

“How would you prefer to be addressed?”

“What are your pronouns?”

## Sex and gender

“What sex were you assigned at birth?”

“How would you describe your gender identity?”

## Hormone therapy and gender affirmation surgery

“Have you ever or are you currently taking hormones or any other medications related to gender?”

“Have you ever had or thought about having any gender-affirming surgeries (e.g., top or bottom surgeries)?”

If so, “then when?”

“Can you tell me what organs you have or what you have had removed as part of your transition?”

“Do you still have a uterus/ovary? Are these words you are comfortable with?”

“Have you pursued any other changes in your appearance or body to bring it closer to your sense of self?”

## Sexual history

“Are you currently sexually active?”

“By choice or circumstance?”

“What are the genders and bodies of your sexual partners?”

“How do you have sex with them?”

“What body parts do you use?”

“Do you have sex with men or people who produce sperm?”

## Pregnancy

“Do you desire pregnancy now or in the future? Do you use anything for pregnancy prevention?”

“Do you use condoms for prevention of pregnancy and sexually transmitted infections? How often do you use condoms?”

undergone hysterectomy and/or bilateral oophorectomy would not have reproductive potential [33]. An adapted flow chart to determine the productive potential and contraceptive needs for transgender patients initiating potentially teratogenic acne treatment (e.g., isotretinoin) is shown in Fig. 1.

## 5 Treatment Plan

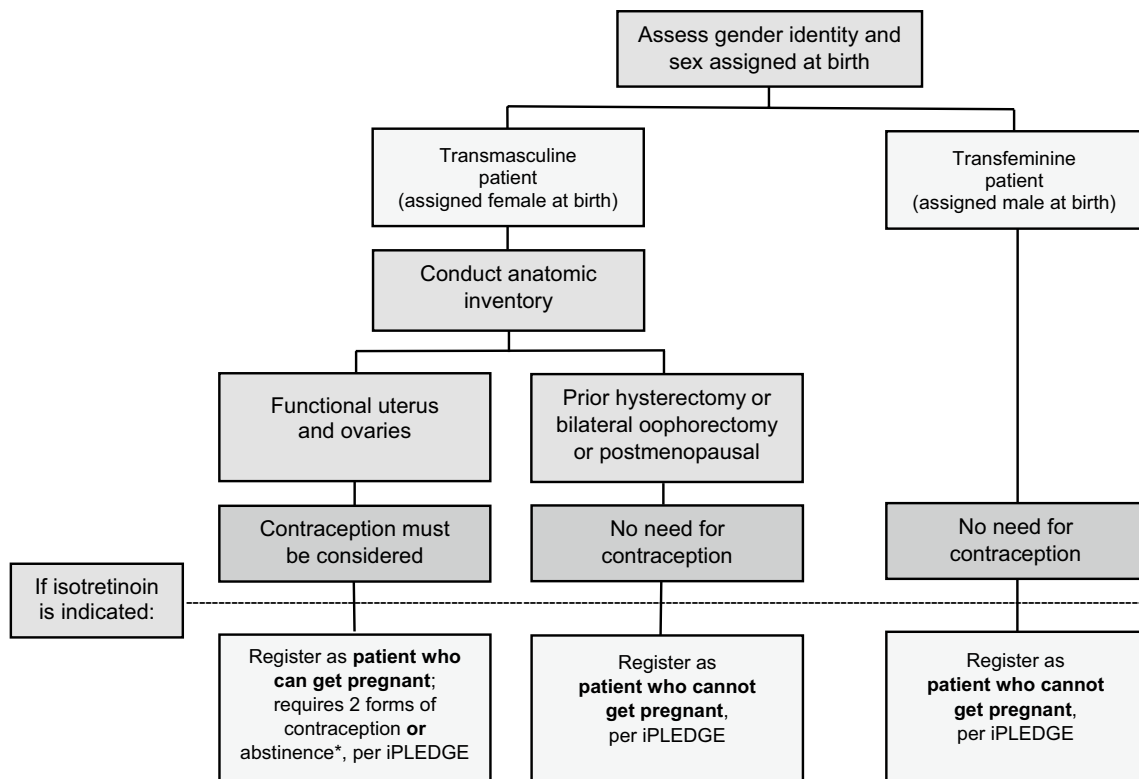
There is no current evidence-based guideline on the best practices for treating hormonal acne in the context of testosterone therapy. Current treatment regimens for hormonal acne have been extrapolated from acne treatment guidelines designed for cisgender persons not receiving testosterone [7]. Acne treatment planning depends on multiple factors such as the predominant acne lesion type, physician- and patient-assessed severity, presence of post-inflammatory erythema, dyspigmentation or scarring, and psychological distress. Potential triggers such as the use of comedogenic skin or hair care products and medications should be assessed. The investigator global assessment is one of several commonly used physician assessments to

grade acne severity and guide treatment selection. In brief, mild acne consists of some comedones and no more than a few papules/pustules; moderate acne has some papules/pustules and no more than one nodule; and severe acne encompasses having more than one nodule [38]. In the following sections, we discuss specific considerations of mild acne requiring only topical treatments, moderate acne requiring oral antibiotics or other treatments, and severe acne requiring isotretinoin.

### 5.1 Mild Acne Treatments

#### 5.1.1 Topical Retinoids

Topical retinoids, such as adapalene, tretinoin, tazarotene, and trifarotene, are indicated for the treatment of both mild to moderate comedonal and inflammatory acne. Trifarotene is the only topical retinoid that is approved for the treatment of truncal acne [39], which may be more prominent in patients with testosterone-induced acne. While all topical retinoids have potential risks for teratogenicity, known teratogenic effects of tazarotene should be emphasized and the importance of contraception should be discussed in



**Fig. 1** Contraceptive needs assessment when prescribing teratogenic acne treatments for transgender patients. \*Abstinence: any sexual contact with male (sperm-producing partner)

transmasculine patients (Table 2) [40]. Patient education on topical retinoid use and prevention and treatment of expected mild skin irritation is paramount to ensure treatment adherence. Patients should be advised to apply topical retinoid every other day for the first 2–4 weeks, apply gentle skin cleansing and avoid over-cleansing, and apply a non-comedogenic moisturizer. In case irritation persists, patients can use the short contact method in which topical retinoid is applied for 30–60 min then washed off for the first several

weeks [41]. Most patients will be able to tolerate topical retinoids using these methods for long-term acne treatment.

### 5.1.2 Topical Benzoyl Peroxide and Topical Antibiotics

Topical benzoyl peroxide and topical antibiotics, such as clindamycin and erythromycin, are often used for the treatment of mild to moderate acne. To reduce the risk of resistance, it is recommended to limit the use of topical antibiotics to 12 weeks and they should not be used

**Table 2** Specific considerations on acne prescriptions for transmasculine patients

Medication	Special considerations
Tazarotene	Teratogenic; advise patients of childbearing potential to consider contraception
Isotretinoin	Teratogenic; transmasculine patients of childbearing potential must use two forms of contraception Consider delayed wound healing effects in patients aiming to undergo gender-affirming surgical procedures Possible hepatotoxicity worsened with testosterone therapy Possible symptoms of depression
Doxycycline	Teratogenic; advise patients of childbearing potential to consider contraception
Trimethoprim-sulfamethoxazole	Potentially teratogenic; advise patients of childbearing potential to consider contraception
Spironolactone	Teratogenic; advise patients of childbearing potential to consider contraception; discuss possible feminizing effects
Clascoterone	Targets the action of testosterone in the skin; may be a good option to consider in transmasculine patients
Oral contraceptive pills	Discuss possible feminizing effects as they relate to transition goals



as monotherapy [42]. Combining topical antibiotics with topical benzoyl peroxide is critical to reduce the risk of resistance and enhance effectiveness [38].

### 5.1.3 Topical Antiandrogen

Topical antiandrogen, such as clascoterone, is a topical androgen receptor inhibitor approved for acne in both males and females [43]. It inhibits sebum production and reduces inflammation in acne lesions [43]. Clascoterone reduces inflammatory and non-inflammatory facial acne with minimal adverse effects or safety concerns [44]. While clinical trials for clascoterone, like most acne clinical trials [45], did not specifically include any transgender participants or document hormone therapy use of its participants, the use of topical antiandrogens in transmasculine patients has been proposed as a targeted treatment for reducing the unwanted testosterone action in the skin [46]. Future research should examine the safety of topical androgens, including the potential systemic effects of clascoterone on serum testosterone level, as well as their acceptability by transmasculine patients and hormone providers.

## 5.2 Moderate to Severe Acne Treatments and Contraceptive Considerations

### 5.2.1 Oral Antibiotics

Oral antibiotics are indicated for moderate-to-severe acne or acne affecting a large body surface area [47, 48]. Oral doxycycline and minocycline are usually used as the first-line option, while oral erythromycin, azithromycin, amoxicillin, and trimethoprim-sulfamethoxazole can serve as possible alternatives [49]. For transmasculine patients with reproductive potential, possible teratogenicity due to oral antibiotics should be discussed (Table 2) [50]. A current acne practice guideline from the American Academy of Dermatology recommends limiting oral antibiotics as an induction therapy for no more than 3 months [51]. Therefore, maintenance topical therapy should be prescribed concurrently to enable oral antibiotic tapering after 3 months. Isotretinoin eligibility should also be re-considered if longer-term oral antibiotics are required.

### 5.2.2 Spironolactone

Spironolactone, a mineralocorticoid receptor antagonist, has a moderate affinity for androgen receptors and is effective in treating acne in cisgender women [52, 53]. Potential teratogenicity should be discussed in all patients of reproductive potential [54]. Many transfeminine patients receiving spironolactone often notice improvement in their acne and may help patients with their transition goals via its

feminizing effects [55]. However, for transmasculine patients receiving testosterone, spironolactone may not be acceptable since it systemically blocks the masculinizing effects of testosterone and may cause adverse effects such as irregular bleeding, breast tenderness, and gynecomastia [56].

### 5.2.3 Hormonal Contraceptives

Hormonal contraceptives such as combined oral contraceptive (COC) pills contain estrogens and progestins and can both treat acne and provide contraception [57]. Many transfeminine patients receiving estradiol notice acne improvement [55]. For transmasculine persons, contraception is an important part of moderate-to-severe acne treatment if the patient is eligible for oral antibiotics and/or oral isotretinoin. It is important to note that testosterone use is not a contraindication per se for any form of hormonal or non-hormonal contraception. Current guidelines recommend highly effective birth control for transmasculine persons at risk of being pregnant. Nevertheless, some transmasculine patients may avoid COCs due to concerns of potential feminizing effects, risk of spontaneous bleeding if not consistently adherent, and potential adverse effects such as nausea, weight gain, and breast tenderness [58, 59]. Progestin-only contraceptives, such as norethindrone, may be used by hormone providers to cease uterine bleeding, but may exacerbate acne due to their androgenic property and, unlike other hormonal contraceptive options, would not be considered as a primary contraceptive method if isotretinoin is ultimately required [60]. Common primary contraceptive options that may prepare transmasculine persons for isotretinoin are listed in Table 3 [33]. Of note, long-acting reversible contraception—depot medroxyprogesterone, hormonal implants, or hormonal intrauterine device—as well as monophasic (continuous) oral contraceptives may induce amenorrhea, an often-desirable effect in transmasculine patients who have not achieved amenorrhea from testosterone therapy alone [33]. Discussion with a reproductive health specialist knowledgeable in transgender health care will be important to tailor contraceptive methods to the patients' needs.

## 5.3 Isotretinoin and Multidisciplinary Considerations

Oral isotretinoin is indicated for the treatment of severe recalcitrant acne, treatment-refractory moderate acne, or acne that causes significant scarring or psychosocial distress [38]. Clinical trials of isotretinoin formulations have demonstrated an 87–90% decrease in inflammatory acne lesion counts, and 69–75% either became clear or had excellent response after 20 weeks [61]. Isotretinoin has been reported to be effective in treating severe testosterone-associated acne in two case series of transmasculine adults and adolescents

**Table 3** Primary methods of contraception appropriate for iPLEDGE in transmasculine patients

Method of contraception <sup>a</sup>	Efficacy	Spontaneous bleeding and spotting risk <sup>b</sup>	Effect on menstrual bleeding <sup>b</sup>	Effect on cramping <sup>b</sup>	Chest tenderness	Duration/dosage
Hormonal implant	> 99%	High	Reduced/stopped	Decreased	May be reported	3 years
Hormonal IUD	> 99%	High	Reduced/stopped	Variable	May be reported	5 years
Copper IUD	> 99%	Low	Increased bleeding	Increased	None	10 years
Tubal sterilization	> 99%	None	None	None	None	Permanent
Hormonal injection	> 97%	High	Reduced/stopped	Decreased	Occasional	3 months
Vaginal ring	> 92%	Low	Reduced/stopped	Decreased	During the initial stages	Monthly
Hormonal patch	> 92%	Low	Reduced/stopped	Decreased	During the initial stages	Weekly
Combined oral contraceptives	> 92%	Low	Reduced/stopped	Decreased	May be reported	Daily

IUD intrauterine device

<sup>a</sup>Contraceptives containing female sex hormones may not be acceptable to some transmasculine patients due to their connection with a discordant gender and potential concerns for feminizing effects

<sup>b</sup>Amenorrhea may be a desirable effect for some transmasculine patients who continue to have bleeding while taking testosterone, while spotting, increased bleeding and cramping may be undesirable effects and may trigger gender dysphoria

[62]. In our experience, isotretinoin is feasible, acceptable, and highly effective in providing remission of moderate-to-severe acne in our transmasculine patients receiving testosterone (Fig. 2).

Teratogenic effects of isotretinoin exposure during pregnancy can lead to fetal death and severe birth defects [63]. In the US, registration in the US FDA iPLEDGE program is required for isotretinoin prescription. For transgender patients eligible for isotretinoin treatment, navigating the iPLEDGE program was a major barrier to treatment access. Prior to December 2021, iPLEDGE used a gender binary categorization to register patients based on their sex assigned at birth, which led to ethical dilemmas when caring for transgender patients [37]. For some patients, signing the iPLEDGE consent was psychologically traumatic, leading them to forgo acne treatment [64]. iPLEDGE required transmasculine patients assigned female at birth who had not undergone a hysterectomy, a bilateral oophorectomy, and were not postmenopausal to be registered as ‘females of reproductive potential’. The FDA announced that effective 13 December 2021, iPLEDGE will start using a gender-neutral assignment for patients, categorizing them into ‘patients who can become pregnant (PWCBP)’ and ‘patients who cannot get pregnant (PWCNBP)’ [65]. Per new iPLEDGE categories, PWCBP are defined as cisgender females (born a female with a uterus and at least one ovary) and transgender males (born female with a uterus and at least one ovary, transitioned to a man), and PWCNBP are defined as cisgender male (born a male), cisgender females and transgender males that have undergone a hysterectomy, cisgender females and

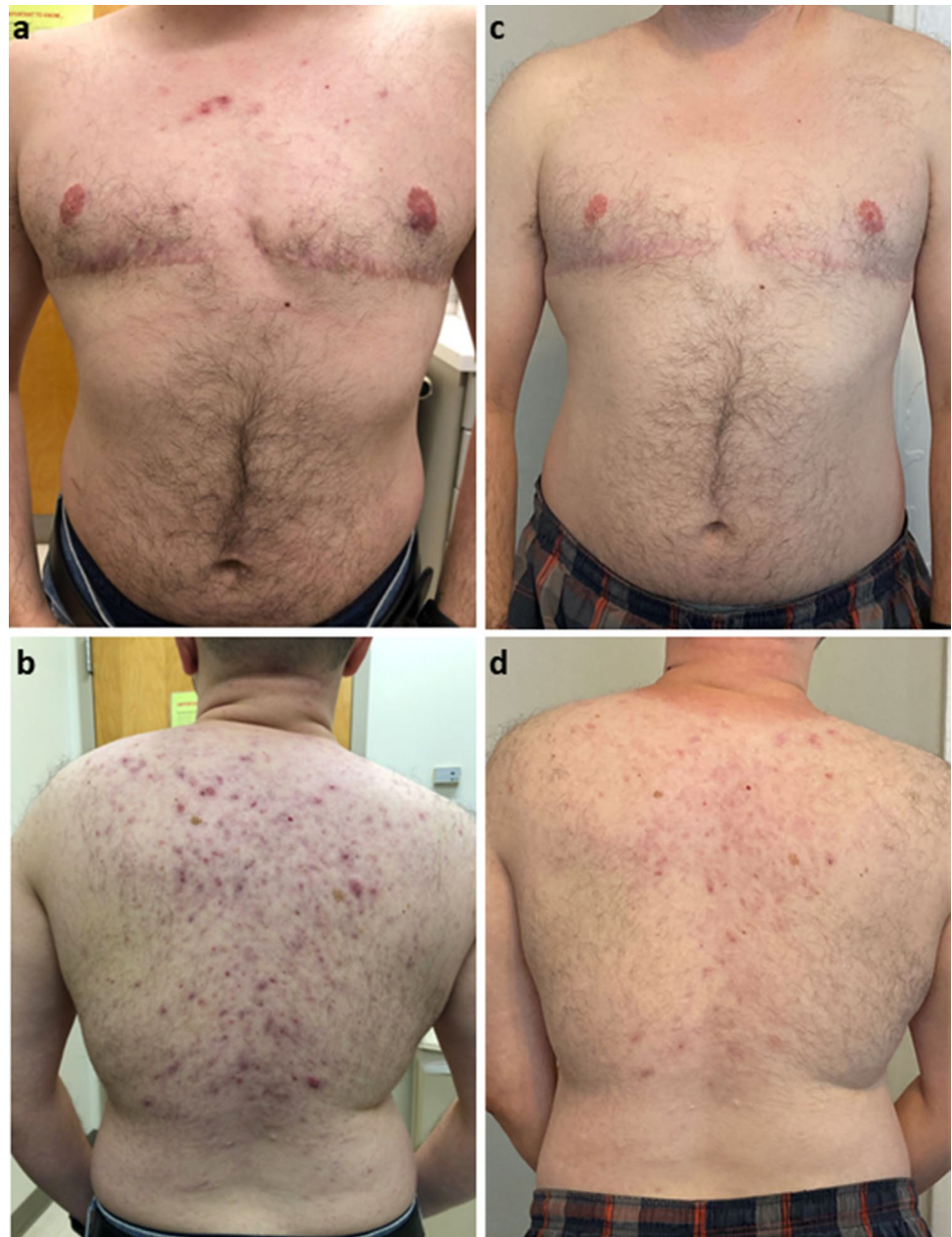transgender males that have undergone bilateral oophorectomy, cisgender females and transgender males who are postmenopausal, and transgender females (born male and transitioned to female) [66]. While these definitions still use gender binary classification that may not apply to non-binary patients, it is a first step forward from the FDA to create a more inclusive environment for iPLEDGE.

Patients who can get pregnant must receive monthly contraceptive counseling, conduct monthly pregnancy monitoring, and commit to either complete abstinence with men (sperm-producing partners) or consistent use of two forms of contraception [63]. A thorough and gender-affirming discussion of the aims and requirements of iPLEDGE is critical to develop therapeutic alliances that enable access for transgender patients who may benefit from isotretinoin treatment [37].

Taking an inclusive sexual history is also essential in understanding contraceptive needs, as sexual behaviors cannot be assumed from sexual orientation or gender identity alone. iPLEDGE allows ‘complete abstinence from men’ as a primary contraceptive method. In other words, transmasculine patients of reproductive potential who never engage in penis–vagina sexual intercourse with sperm-producing partners would be employing abstinence as a primary contraceptive method [37, 63]. For transgender patients with reproductive potential who have penis–vagina receptive sexual intercourse with a sperm-producing partner, consistent use of two forms of contraception will still be required.

Isotretinoin may be associated with delayed wound healing that can persist for up to 6–12 months after

**Fig. 2** Clinical appearance of acne in a transmasculine patient **a, b** before and **c, d** after isotretinoin treatment



discontinuation [38]. Therefore, dermatologists considering isotretinoin for a transgender patient should inquire about patient plans for gender-affirming surgeries [7]. Transmasculine patients often use the terms ‘top’ surgery to refer to chest reconstruction such as mastectomy, and ‘bottom’ surgery to refer to genital reconstruction such as metoidioplasty, phalloplasty, hysterectomy, and/or oophorectomy. Delay of isotretinoin treatment should be considered to avoid delays in gender-affirming surgical plans. Nevertheless, aggressive treatment of moderate-to-severe truncal acne, such as with oral antibiotics, may be required to reduce inflammation, reduce scarring, and optimize top surgery outcomes.

Monthly pregnancy tests at certified laboratories are required for all patients of reproductive potential. During the coronavirus disease 2019 (COVID-19) outbreak, home urine pregnancy tests became acceptable for iPLEDGE pregnancy monitoring [67], which may provide better privacy, comfort, and convenience to transmasculine patients. For transmasculine patients who are not comfortable with urine pregnancy tests, a qualitative serum b-HCG may be offered [63].

Monitoring of the liver function test and lipid panel should also be conducted, especially due to the theoretically amplified risk of isotretinoin hepatotoxicity in the context of testosterone therapy [8].



Isotretinoin has been controversially associated with depression, mood alterations, anxiety, and suicidality, but causality remains poorly established [68]. Conversely, some studies suggested that isotretinoin improved depressive symptoms and enhanced quality-of-life impact from moderate-to-severe acne [69]. Notably, transgender persons face substantially higher prevalence of depression, anxiety, and suicidality compared with cisgender persons [70, 71]. In a case series of four transgender adolescents receiving isotretinoin for severe acne, two stopped treatment due to depression, anxiety, and self-harm [72]. Providers should screen and monitor for signs of depression and mental health comorbidity for transgender patients receiving isotretinoin, such as using the Patient Health Questionnaire-9 (PHQ-9) depression screening tool to monitor depression symptoms [73]. Fortunately, many transgender patients receive care from mental health providers as part of their multidisciplinary gender-affirming care. Multidisciplinary management between the dermatologist, primary care or hormone provider, gender-affirming surgeon, reproductive health specialist, and mental health provider are essential for successful treatment of severe acne using isotretinoin in transmasculine patients receiving testosterone. Given the high level of barriers to isotretinoin care, there is an ongoing call for increases in the number of isotretinoin prescribers for transgender patients [74]. As such, dermatologists have an important and under-recognized role in providing isotretinoin treatment for the effective and safe treatment of severe acne in transgender patients.

## 6 Conclusion

Acne is common and imposes high social and quality-of-life impacts on transgender patients receiving testosterone. Transgender patients deserve equitable acne care as for their cisgender peers. Culturally competent and comprehensive acne encounters involve inclusive history taking, routine collection of sexual orientation and gender identity data, and patient-centered physical examination. As multiple acne medications may be teratogenic, providers should conduct a thorough assessment of reproductive potential and provide counseling accordingly. While discussing the different contraception options, providers should keep in mind that testosterone therapy is neither a reliable contraception nor a contraindication to all other forms of contraception. Acne treatment regimen selection should also consider the patients' transition goals. When isotretinoin is indicated, providers should discuss iPLEDGE requirements with the patient while building a therapeutic alliance. The clinical encounter should discuss the effects of isotretinoin in a multidisciplinary approach and plans to monitor and alleviate potential adverse effects. Dermatologists should continue

to learn with their patients on how to optimize skin, mental health, and quality-of-life outcomes of gender-affirming testosterone therapy. Dermatologists have an important role in advocating for comprehensive and culturally competent healthcare that the transgender population deserve.

## Declarations

**Funding** This manuscript is supported in part by grants from the National Institute of Arthritis and Musculoskeletal and Skin Diseases L30 AR076081 (HY) and K23 AR075888 (JB, HY). The content is solely the responsibility of the authors and does not necessarily represent the official views of the National Institutes of Health.

**Conflict of interest** Howa Yeung received honorarium from Syneos Health and the American Academy of Dermatology. Rakan Radi, Sarah Gold, Juan Acosta, and Jason Barron have no conflicts of interest to declare.

**Author contributions** HY originated the idea for this article. All authors performed the literature search and data analysis. RR, SG, and JA drafted the manuscript and all authors commented on previous versions of the manuscript. All authors read and approved the final manuscript.

**Availability of data and material** Not applicable.

**Code availability** Not applicable.

**Ethics approval** Not applicable.

**Consent to participate** Not applicable.

**Consent for publication** Signed patient consent for publication of the photos in Fig. 2 has been obtained.

## References

1. Tan JK, Bhate K. A global perspective on the epidemiology of acne. *Br J Dermatol.* 2015;172(Suppl 1):3–12.
2. Karimkhani C, Dellavalle RP, Coffeng LE, Flohr C, Hay RJ, Langan SM, et al. Global skin disease morbidity and mortality: an update from the global burden of disease study 2013. *JAMA Dermatol.* 2017;153(5):406–12.
3. Elsaie ML. Hormonal treatment of acne vulgaris: an update. *Clin Cosmet Investig Dermatol.* 2016;9:241–8.
4. Yeung H, Kahn B, Ly BC, Tangpricha V. Dermatologic conditions in transgender populations. *Endocrinol Metab Clin North Am.* 2019;48(2):429–40.
5. Lucky AW. Hormonal correlates of acne and hirsutism. *Am J Med.* 1995;98(1a):89s–94s.
6. Melnik B, Jansen T, Grabbe S. Abuse of anabolic-androgenic steroids and bodybuilding acne: an underestimated health problem. *J Dtsch Dermatol Ges.* 2007;5(2):110–7.
7. Ragmanauskaite L, Kahn B, Ly B, Yeung H. Acne and the lesbian, gay, bisexual, or transgender teenager. *Dermatol Clin.* 2020;38(2):219–26.
8. Motosko CC, Zakhem GA, Pomeranz MK, Hazen A. Acne: a side-effect of masculinizing hormonal therapy in transgender patients. *Br J Dermatol.* 2019;180(1):26–30.

9. Khera M. Testosterone therapies. *Urol Clin North Am*. 2016;43(2):185–93.
10. Davis SR, Braunstein GD. Efficacy and safety of testosterone in the management of hypoactive sexual desire disorder in postmenopausal women. *J Sex Med*. 2012;9(4):1134–48.
11. Yeung H, Luk KM, Chen SC, Ginsberg BA, Katz KA. Dermatologic care for lesbian, gay, bisexual, and transgender persons: terminology, demographics, health disparities, and approaches to care. *J Am Acad Dermatol*. 2019;80(3):581–9.
12. Coleman E, Bockting W, Botzer M, Cohen-Kettenis P, DeCuypere G, Feldman J, et al. Standards of care for the health of transsexual, transgender, and gender-nonconforming people, version 7. *Int J Transgend*. 2012;165–232.
13. Thoreson N, Park JA, Grasso C, Potter J, King DS, Marc LG, et al. Incidence and factors associated with acne among transgender patients receiving masculinizing hormone therapy. *JAMA Dermatol*. 2021;157(3):290–5.
14. Wierckx K, Van de Peer F, Verhaeghe E, Dedekerckx D, Van Caenegem E, Toye K, et al. Short- and long-term clinical skin effects of testosterone treatment in trans men. *J Sex Med*. 2014;11(1):222–9.
15. Park JA, Carter EE, Larson AR. Risk factors for acne development in the first 2 years after initiating masculinizing testosterone therapy among transgender men. *J Am Acad Dermatol*. 2019;81(2):617–8.
16. Nakamura A, Watanabe M, Sugimoto M, Sako T, Mahmood S, Kaku H, et al. Dose-response analysis of testosterone replacement therapy in patients with female to male gender identity disorder. *Endocr J*. 2013;60(3):275–81.
17. Yeung H, Ragmanauskaite L, Zhang Q, Kim J, Tangpricha V, Getahun D, et al. Prevalence of moderate to severe acne in transgender adults: a cross-sectional survey. *J Am Acad Dermatol*. 2020;83(5):1450–2.
18. Peitzmeier SM, Silberholz J, Gardner IH, Weinand J, Acevedo K. Time to first onset of chest binding-related symptoms in transgender youth. *Pediatrics*. 2021;147(3):e20200728.
19. Becerra-Culqui TA, Liu Y, Nash R, Cromwell L, Flanders WD, Getahun D, et al. Mental health of transgender and gender nonconforming youth compared with their peers. *Pediatrics*. 2018;141(5):e20173845.
20. Rowiak S, Bolt L, Sharifi C. Effect of cross-sex hormones on the quality of life, depression and anxiety of transgender individuals: a quantitative systematic review. *JBI Database Syst Rev Implement Rep*. 2019;17(9):1826–54.
21. Dunn LK, O'Neill JL, Feldman SR. Acne in adolescents: quality of life, self-esteem, mood, and psychological disorders. *Dermatol Online J*. 2011;17(1):1.
22. Owen-Smith AA, Gerth J, Sineath RC, Barzilay J, Becerra-Culqui TA, Getahun D, et al. Association between gender confirmation treatments and perceived gender congruence, body image satisfaction, and mental health in a cohort of transgender individuals. *J Sex Med*. 2018;15(4):591–600.
23. Covelli I, Ahrens K, Onchiri FM, Inwards-Breland D, Boos MD. Influence of gender and sexual identity on adolescent skin health. *Pediatr Dermatol*. 2021;38(Suppl 2):65–72.
24. Braun H, Zhang Q, Getahun D, Silverberg MJ, Tangpricha V, Goodman M, et al. Moderate-to-severe acne and mental health symptoms in transmasculine persons who have received testosterone. *JAMA Dermatol*. 2021;157(3):344–6.
25. Kcomt L, Gorey KM, Barrett BJ, McCabe SE. Healthcare avoidance due to anticipated discrimination among transgender people: a call to create trans-affirmative environments. *SSM Popul Health*. 2020;11:100608.
26. Safer JD, Coleman E, Feldman J, Garofalo R, Hembree W, Radix A, et al. Barriers to healthcare for transgender individuals. *Curr Opin Endocrinol Diabetes Obes*. 2016;23(2):168–71.
27. Rafferty J, Committee On Psychosocial Aspects of Child and Family Health, Committee On Adolescence, Section On Lesbian Gay, Bisexual, and Transgender Health and Wellness. Ensuring comprehensive care and support for transgender and gender-diverse children and adolescents. *Pediatrics*. 2018;142(4):e20182162.
28. Yeung H, Luk KM, Chen SC, Ginsberg BA, Katz KA. Dermatologic care for lesbian, gay, bisexual, and transgender persons: epidemiology, screening, and disease prevention. *J Am Acad Dermatol*. 2019;80(3):591–602.
29. Safer JD, Tangpricha V. Care of the transgender patient. *Ann Intern Med*. 2019;171(1):ITC1–16.
30. Haider A, Adler RR, Schneider E, Uribe Leitz T, Ranjit A, Ta C, et al. Assessment of patient-centered approaches to collect sexual orientation and gender identity information in the emergency department: the EQUALITY study. *JAMA Netw Open*. 2018;1(8):e186506.
31. Mansh MD, Nguyen A, Katz KA. Improving dermatologic care for sexual and gender minority patients through routine sexual orientation and gender identity data collection. *JAMA Dermatol*. 2019;155(2):145–6.
32. Hashemi L, Weinreb J, Weimer AK, Weiss RL. Transgender care in the primary care setting: a review of guidelines and literature. *Fed Pract*. 2018;35(7):30–7.
33. Krempasky C, Harris M, Abern L, Grimstad F. Contraception across the transmasculine spectrum. *Am J Obstet Gynecol*. 2020;222(2):134–43.
34. Deutsch MB. Guidelines for the primary and gender-affirming care of transgender and gender nonbinary people. 2nd edition. 2016 [cited 19 Aug 2021]. Available at: <https://transcare.ucsf.edu/guidelines>.
35. Marks DH, Awosika O, Rengifo-Pardo M, Ehrlich A. Dermatologic surgical care for transgender individuals. *Dermatol Surg*. 2019;45(3):446–57.
36. Light AD, Obedin-Maliver J, Sevelius JM, Kerns JL. Transgender men who experienced pregnancy after female-to-male gender transition. *Obstet Gynecol*. 2014;124(6):1120–7.
37. Yeung H, Chen SC, Katz KA, Stoff BK. Prescribing isotretinoin in the United States for transgender individuals: ethical considerations. *J Am Acad Dermatol*. 2016;75(3):648–51.
38. Zaenglein AL, Pathy AL, Schlosser BJ, Alikhan A, Baldwin HE, Berson DS, et al. Guidelines of care for the management of acne vulgaris. *J Am Acad Dermatol*. 2016;74(5):945–73.e33.
39. Tan J, Thiboutot D, Popp G, Gooderham M, Lynde C, Del Rosso J, et al. Randomized phase 3 evaluation of trifarotene 50 µg/g cream treatment of moderate facial and truncal acne. *J Am Acad Dermatol*. 2019;80(6):1691–9.
40. Chien AL, Qi J, Rainer B, Sachs DL, Helfrich YR. Treatment of acne in pregnancy. *J Am Board Fam Med*. 2016;29(2):254–62.
41. Leyden J, Stein-Gold L, Weiss J. Why topical retinoids are mainstay of therapy for acne. *Dermatol Ther (Heidelb)*. 2017;7(3):293–304.
42. Gamble R, Dunn J, Dawson A, Petersen B, McLaughlin L, Small A, et al. Topical antimicrobial treatment of acne vulgaris: an evidence-based review. *Am J Clin Dermatol*. 2012;13(3):141–52.
43. Rosette C, Agan FJ, Mazzetti A, Moro L, Gerloni M. Cortaxolone 17 $\alpha$ -propionate (clascoterone) is a novel androgen receptor antagonist that inhibits production of lipids and inflammatory cytokines from sebocytes in vitro. *J Drugs Dermatol*. 2019;18(5):412–8.
44. Hebert A, Thiboutot D, Stein Gold L, Cartwright M, Gerloni M, Fragasso E, et al. Efficacy and safety of topical clascoterone cream, 1%, for treatment in patients with facial acne: two phase 3 randomized clinical trials. *JAMA Dermatol*. 2020;156(6):621–30.
45. DeGrazia TM, Rolader R, Thiboutot DM, Yeung H. Eligibility criteria related to hormone therapy in acne clinical trials: a systematic review. *J Invest Dermatol*. 2021;141(1):189–91.

46. Marks DH, Mansh MD. Potential role for topical antiandrogens in the management of acne among patients receiving masculinizing hormone therapy. *JAMA Dermatol.* 2020;156(12):1380–1.
47. Webster GF, Graber EM. Antibiotic treatment for acne vulgaris. *Semin Cutan Med Surg.* 2008;27(3):183–7.
48. Katsambas A, Papakonstantinou A. Acne: systemic treatment. *Clin Dermatol.* 2004;22(5):412–8.
49. Garner SE, Eady A, Bennett C, Newton JN, Thomas K, Popescu CM. Minocycline for acne vulgaris: efficacy and safety. *Cochrane Database Syst Rev.* 2012;2012(8):CD002086.
50. Cross R, Ling C, Day NP, McGready R, Paris DH. Revisiting doxycycline in pregnancy and early childhood—time to rebuild its reputation? *Expert Opin Drug Saf.* 2016;15(3):367–82.
51. Farrah G, Tan E. The use of oral antibiotics in treating acne vulgaris: a new approach. *Dermatol Ther.* 2016;29(5):377–84.
52. Garthwaite SM, McMahan EG. The evolution of aldosterone antagonists. *Mol Cell Endocrinol.* 2004;217(1–2):27–31.
53. Grandhi R, Alikhan A. Spironolactone for the treatment of acne: a 4-year retrospective study. *Dermatology.* 2017;233(2–3):141–4.
54. Oge LK, Broussard A, Marshall MD. Acne vulgaris: diagnosis and treatment. *Am Fam Physician.* 2019;100(8):475–84.
55. Giltay EJ, Gooren LJ. Effects of sex steroid deprivation/administration on hair growth and skin sebum production in transsexual males and females. *J Clin Endocrinol Metab.* 2000;85(8):2913–21.
56. Layton AM, Eady EA, Whitehouse H, Del Rosso JQ, Fedorowicz Z, van Zuuren EJ. Oral spironolactone for acne vulgaris in adult females: a hybrid systematic review. *Am J Clin Dermatol.* 2017;18(2):169–91.
57. Fox L, Csongradi C, Aucamp M, du Plessis J, Gerber M. Treatment modalities for acne. *Molecules.* 2016;21(8):1063.
58. Carswell JM, Roberts SA. Induction and maintenance of amenorrhea in transmasculine and nonbinary adolescents. *Transgend Health.* 2017;2(1):195–201.
59. Barbieri JS, Spaccarelli N, Margolis DJ, James WD. Approaches to limit systemic antibiotic use in acne: systemic alternatives, emerging topical therapies, dietary modification, and laser and light-based treatments. *J Am Acad Dermatol.* 2019;80(2):538–49.
60. Gollnick H, Cunliffe W, Berson D, Dreno B, Finlay A, Leyden JJ, et al. Management of acne: a report from a global alliance to improve outcomes in acne. *J Am Acad Dermatol.* 2003;49(1 Suppl):S1–37.
61. Strauss JS, Leyden JJ, Lucky AW, Lookingbill DP, Drake LA, Hanifin JM, et al. A randomized trial of the efficacy of a new micronized formulation versus a standard formulation of isotretinoin in patients with severe recalcitrant nodular acne. *J Am Acad Dermatol.* 2001;45(2):187–95.
62. Turrión-Merino L, Urech-García-de-la-Vega M, Miguel-Gómez L, Harto-Castano A, Jaen-Olasolo P. Severe acne in female-to-male transgender patients. *JAMA Dermatol.* 2015;151(11):1260–1.
63. iPLEDGE. Prescriber isotretinoin educational kit. 2017. Available at: <https://www.ipledgeprogram.com/iPledgeUI/remss/pdf/resources/Prescriber%20Isotretinoin%20Educational%20Kit.pdf>.
64. Katz KA. Transgender patients, isotretinoin, and US Food and Drug Administration-mandated risk evaluation and mitigation strategies: a prescription for inclusion. *JAMA Dermatol.* 2016;152(5):513–4.
65. US Food and Drug Administration. iPLEDGE risk evaluation and mitigation strategy (REMS). [cited 17 Nov 2021]. Available at: <https://www.fda.gov/drugs/postmarket-drug-safety-information-patients-and-providers/ipledge-risk-evaluation-and-mitigation-strategy-rems>.
66. iPLEDGE 2021 Prescriber information session [cited 17 Nov 2021]. Available at: <https://www.ipledge.syneoshealthlearning.com/copy-of-video-page>.
67. Kane S, Admani S. COVID-19 pandemic leading to the accelerated development of a virtual health model for isotretinoin. *J Dermatol Nurses Assoc.* 2021;13(1):54–7.
68. Marqueling AL, Zane LT. Depression and suicidal behavior in acne patients treated with isotretinoin: a systematic review. *Semin Cutan Med Surg.* 2005;24(2):92–102.
69. Huang YC, Cheng YC. Isotretinoin treatment for acne and risk of depression: a systematic review and meta-analysis. *J Am Acad Dermatol.* 2017;76(6):1068–76 e9.
70. Johnson B, Leibowitz S, Chavez A, Herbert SE. Risk versus resiliency: addressing depression in lesbian, gay, bisexual, and transgender youth. *Child Adolesc Psychiatr Clin N Am.* 2019;28(3):509–21.
71. Budge SL, Adelson JL, Howard KA. Anxiety and depression in transgender individuals: the roles of transition status, loss, social support, and coping. *J Consult Clin Psychol.* 2013;81(3):545–57.
72. Campos-Munoz L, Lopez-De Lara D, Conde-Taboada A, Fueyo Casado A, Lopez-Bran E. Depression in transgender adolescents under treatment with isotretinoin. *Clin Exp Dermatol.* 2020;45(5):615–6.
73. Peng T, Li ZM, Liu J, Zhang Y. Evaluation of reliability and validity of the Patient Health Questionnaire-9 in patients with acne. *Dermatol Ther.* 2020;33(4):e13584.
74. Singer S, Keuroghlian AS. A call for gender identity data collection in iPLEDGE and increasing the number of isotretinoin prescribers among transgender health providers. *LGBT Health.* 2020;7(5):216–9.