

## Mycetoma in Timor-Leste and first report of nocardiosis

Nicola Townell,<sup>1</sup> Thomas Locke,<sup>2</sup> Margaret Gibbons,<sup>3</sup> Dan Murphy,<sup>3</sup> Joshua Francis,<sup>4,6</sup> Clare Nourse<sup>5,7</sup>

<sup>1</sup>Infectious Disease Department, Sunshine Coast University Hospital, Queensland, Australia; <sup>2</sup>Department of Infection, Sheffield Teaching Hospitals, United Kingdom; <sup>3</sup>Bairo-Pite Clinic, Bairo-Pite, Timor-Leste; <sup>4</sup>Infectious Disease Department, Royal Darwin Hospital, Northern Territories, Australia; <sup>5</sup>Maluk Timor, Dili, Timor-Leste; <sup>6</sup>Menzies School of Health Research (Global & Tropical Health Division), Australia; <sup>7</sup>Lady Cilento Children's Hospital, Brisbane, Australia

### Abstract

Mycetoma is a neglected tropical disease with an unknown global burden. Although considered endemic to South-east Asia, it has not previously been reported from Timor-Lest. We describe two cases in Timor-Leste, highlighting the challenges surrounding microbiological diagnosis and management shared by many low to middle-income countries. As characteristically described, both patients lived rurally and presented late with marked soft tissue involvement and multiple draining sinuses following a prolonged period of high morbidity. *Nocardia brasiliensis*, a beaded-branched, modified acid-fast, gram-positive bacilli, was isolated and confirmed by molecular testing in the first case. The causative organism in the second case could not be confirmed due to limited microbiological capabilities. Due to limited local laboratory capabilities, *Nocardia* spp. infection cannot be routinely confirmed in Timor-Leste. However, the microbiology laboratory is essential for the successful diagnosis and management of Mycetoma. In both cases, medical therapy alone resulted in cure and favorable outcomes, although supply of antibiotic remains an ongoing resource issue.

### Introduction

Mycetoma is a neglected tropical disease with an unknown global burden.<sup>1</sup> Although considered endemic to South-east Asia, it has not previously been reported from Timor-Leste.<sup>2</sup>

Mycetoma is a chronic granulomatous destructive soft tissue infection caused by either aerobic actinomycetes or fungi.<sup>3</sup> Two-

thirds are bacterial, with over half caused by *Nocardia* spp (majority due to *Nocardia brasiliensis*).<sup>4</sup> Mycetoma characteristically presents with tumor like swelling and multiple sinuses discharging pus and grains.<sup>5</sup> Without appropriate therapy, contiguous spread of infection occurs leading to bone involvement with significant morbidity for the patient and results in a detrimental economic impact on the patient's community.<sup>3</sup> The burden of disease is greatest in rural persons of lower socio-economic status living in the tropical and subtropical regions of the world.<sup>3</sup>

Timor-Leste is a small country in South East Asia with a population of 1.2 million people and an approximate Gross Domestic Product per capita of \$2279 US dollars. Despite significant economic progress, following a long history of devastating conflict and subsequent independence in 2002, nearly 50% of the population remains in poverty.<sup>6</sup> The majority of these families reside in rural areas and are primarily engaged in subsistence farming.

We report the first two cases of mycetoma in Timor-Leste in patients attending Bairo Pite Clinic (BPC) in the capital, Dili. BPC is a non-government organization providing free primary and inpatient care, funded by international donors.

### Case Report #1

A 34-year-old previously fit and well farmer presented with a two-year history of progressive left foot swelling and worsening mobility. There was no history of trauma, but he frequently walked barefoot. Examination revealed a swollen left foot with multiple discharging sinuses (Figure 1). Plain radiographs showed no evidence of bony involvement. Empirical trimethoprim-sulfamethoxazole was commenced for suspected nocardiosis. Fresh tissue was brought (by a volunteer) to a laboratory in Australia for histology and culture. Histology examination revealed a mixed inflammatory response with evidence of Splendore-Hoeppli phenomenon. Microorganisms were not visualised on special stains (Gram, Ziehl-Neelsen, Wade Fite, Periodic Acid-Schiff and Grocott).

Bacterial microscopy revealed occasional leucocytes and numerous gram-negative bacilli. Initial cultures grew mixed enteric flora including *Pseudomonas aeruginosa* and *Candida parapsilosis* complex. After 5 days, typical white dry pitted colonies were isolated. Gram stain of these colonies revealed a gram-positive, branching filamentous bacilli that were acid-fast stain negative and modified acid-fast stain positive. Subsequent 16s polymerase chain

Correspondence: Nicola Townell, Infectious Disease Department, Sunshine Coast University Hospital, Queensland, Australia. Tel.: +61407485716 E-mail: nikki.microsi@gmail.com

Key words: nocardia; mycetoma; Timor-Leste.

Contributions: all authors provided information in respect to the case details. NT drafted the first version of the manuscript. All authors reviewed and approved the manuscript.

Conflict of interest: the authors declare no potential conflict of interest.

Funding: none.

Received for publication: 29 July 2018.  
Revision received: 10 October 2018.  
Accepted for publication: 19 October 2018.

This work is licensed under a Creative Commons Attribution-NonCommercial 4.0 International License (CC BY-NC 4.0).

©Copyright N. Townell, et al., 2018  
Licensee PAGEPress, Italy  
*Infectious Disease Reports* 2018; 10:7804  
doi:10.4081/idr.2018.7804

reaction sequencing was performed on the isolate which confirmed *Nocardia brasiliensis*. The isolate tested in vitro susceptible to trimethoprim-sulfamethoxazole (MIC 0.25/4.8), tobramycin (MIC ≤1), amikacin (MIC ≤1) and linezolid (MIC 2), intermediate to amoxicillin-clavulanic acid (MIC 16:8) and minocycline (MIC 4), and resistant to ciprofloxacin (MIC >4), clarithromycin (MIC >16), ceftriaxone (MIC >64) and imipenem (MIC >64) (Sensititre broth microdilution, CLSI M24-A2). Mycobacterial and fungal cultures were negative. After 2 months of first line treatment targeting *Nocardia*, the lesions had healed and the patient was able to return to work.

### Case Report #2

A 45-year-old rural woman presented with a 7 year history of severe pain in her left leg and multiple sinuses draining copious pus (Figure 1). The lesion initially appeared on her foot and over time had slowly progressed caudally to include most of her leg. Due to pain, she was unable to weight bear and she described a very poor quality of life. Surgery had been performed twice without resolution of her symptoms.

There was no significant past medical history or evidence of immune deficiency (Human Immunodeficiency Virus negative, no diabetes or malignancy). Plain radiographs confirmed osteomyelitis. Due to the high incidence of tuberculosis in Timor-Leste (498 cases per 100,000 population), a presumptive diagnosis of tuberculosis osteomyelitis was made and she was commenced on standard quadruple TB therapy.<sup>7</sup> She experienced ongoing intermittent fevers with increased pus draining from the sinuses. A visiting medical scientist detected branching beaded gram-positive bacilli on a Gram stain of the pus (Figure 2). After 5 days of aerobic incubation (at a private laboratory), chalky colonies with an earthy odor were isolated. The laboratory did not have capabilities to further identify the organism. The isolate was suspected to be *Nocardia* sp. based on the clinical presentation, characteristic initial gram stain and typical phenotypic appearance. Susceptibility testing was not performed due to limited microbiological capabilities. Initially the patient failed to respond to oral trimethoprim-sulfamethoxazole (7.5mg/kg/day trimethoprim) alone. Subsequently intravenous ceftriaxone (1g daily) was added to therapy with rapid clinical improvement. Ceftriaxone was administered for three months (courtesy of an international donor). She subsequently completed a further 9 months of oral trimethoprim-sulfamethoxazole therapy. On discontinuation of therapy, her lesions had completely healed and she could stand and walk without assistance. Two years after completion of therapy, she was well with no evidence of relapsed infection.

## Discussion

Although Mycetoma is considered endemic in South East Asia, these are the

first two reported cases from Timor-Leste.<sup>2</sup> Clinically the condition is underappreciated and the global burden remains unknown.<sup>4</sup> In recognition of its global importance the World Health Organization (WHO) added Mycetoma to its list of neglected tropical diseases in 2016.

Case 1 was typical of the chronic clinical syndrome known as Madura foot. *Nocardia* is considered to be a common causative pathogen of this clinical syndrome.<sup>5</sup> *Nocardia* spp. when isolated is generally considered a pathogen.<sup>8</sup> *Nocardia brasiliensis* was confirmed by isolation and subsequent molecular identification. Molecular testing is useful for confirmation of identification and is considered necessary for accurate species identification. In this case, 16s sequencing was performed due to local availability although sequencing of other housekeeping targets such as *sec1*, *gyrB* and *hsp65* can also be used.<sup>9</sup> The mixed enteric flora that was isolated is representative of colonization of open wounds. The patient responded to treatment that did not include activity against the other two pathogens, *Pseudomonas aeruginosa* or *Candida parapsilosis*, that were isolated. The patient symptoms improved rapidly with complete resolution of infection following the introduction of co-trimoxazole, first line therapy for treatment of *Nocardia* infection. The clinical presentation, positive culture result, confirmation of pathogen identification by molecular techniques and response to therapy all support the diagnosis of *Nocardia* infection. This is the first case of microbiologically confirmed *Nocardia* mycetoma in Timor-Leste.

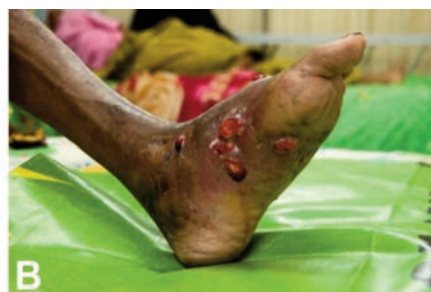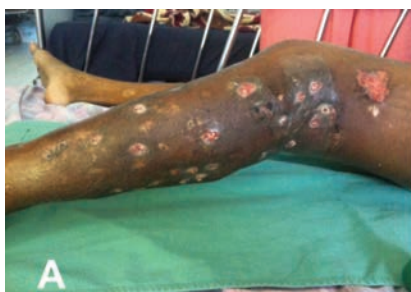Patient 2 had many of the clinical signs of *Nocardia* spp. osteomyelitis with marked soft tissue involvement, multiple sinuses with profuse pus, lytic areas in bone with proliferative periosteal reaction that progresses to sclerosis and the absence of sequestra.<sup>10</sup> The initial gram stain revealed a

branching beaded gram positive bacilli, which is characteristic of *Nocardia* spp.<sup>11</sup> When *Nocardia* spp. infection is suspected, it is important that the laboratory extends incubation of the plates, recommended minimum of 2 weeks, to allow this slower growing organism adequate time to culture.<sup>9</sup> It is also recommended, particularly for non-sterile sites, that selective media e.g. buffered charcoal yeast extract agar, is used to suppress the growth of other organisms that may mask the presence of this important pathogen.<sup>12</sup> Although the organism isolated in Case 2 could not be definitively identified due to limited laboratory capabilities, both the initial gram stain and the typical appearance on plates are suggestive of *Nocardia* sp. A positive modified acid-fast stain (and negative acid-fast stain) would provide further support to the identification of *Nocardia* (excluding mycobacteria and actinomycetes).<sup>9</sup> Many laboratories in the resource limited setting currently do not have molecular capabilities and so would have to make a presumptive diagnosis of *Nocardia* based on the above criteria.

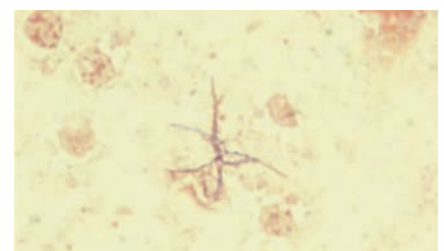
Other atypical pathogens, including actinomycetes, mycobacterium and fungus, should be considered in patients with chronic soft tissue infection and appropriate investigations include tissue biopsy for histological and microbiological examination. These investigations require access to microbiology laboratories with the ability to perform microscopy, culture and susceptibility testing.

Despite global improvements in laboratory capacity, many countries like Timor-Leste will require significant assistance to strengthen their laboratories. The World Health Organization has identified laboratory strengthening as a priority.<sup>13</sup>

Although the burden of mycetoma in Timor-Leste is unknown, it is likely to be high as much of the population is impoverished, reside in a rural setting and have lim-



**Figure 1.** Extensive multiple draining sinuses of the lower limb typical of findings consistent with a diagnosis of Mycetoma. A) patient 2; B) patient 1.



**Figure 2.** Branching beaded gram-positive filamentous bacteria consistent with the diagnosis of *Nocardia* spp. infection.

ited access to health care. Strategies to prevent mycetoma in this region need to be further explored.

## Conclusions

These cases highlight many features common to low to middle-income countries: Mycetoma is clinically underappreciated; it is a chronic illness that is associated with significant patient morbidity; diagnosis is difficult in regions of the world where laboratory capacity is limited and resource limitations compromise optimal medical management.

## References

1. van de Sande WW, Fahal AH, Goodfellow M, et al. The mycetoma knowledge gap: identification of research priorities. *PLoS Negl Trop Dis* 2014;8:e2667.
2. Rattanavong S, Vongthongchit S, Bounphamala K, et al. Actinomycetoma in SE Asia: the first case from Laos and a review of the literature. *BMC Infect Dis* 2012;12:349.
3. World Health Organization. Mycetoma - Report by the Secretariat. Geneva: WHO; 2015.
4. Van de Sande WW. Global burden of human mycetoma: a systematic review and meta-analysis. *PLoS Negl Trop Dis* 2013;7:e2550.
5. Bonifaz A, Tirado-Sánchez A, Calderón L, et al. Mycetoma: experience of 482 cases in a single center in Mexico. *PLoS Negl Trop Dis* 2014;8:e3102.
6. Timor-Leste. Data [Internet]. *Data.worldbank.org*. 2018 [cited 1 October 2018]. Available from: <http://data.worldbank.org/country/timor-leste>
7. World Health Organization. Global Tuberculosis Report. Geneva: WHO; 2016.
8. Wilson J. Nocardiosis: Updates and Clinical Overview. *Mayo Clin Proc* 2012;87:403-7.
9. Baio P, Ramos JN, Santos LS, et al. Molecular Identification of Nocardia isolates from Clinical Samples and an Overview of human Nocardiosis in Brazil. *PLoS Negl Trop Dis* 2013;7:e2573
10. Palmer P, Reeder M. *Imaging of tropical diseases*. Heidelberg Germany: Springer-Verlag; 2001.
11. Sullivan DC, Chapman SW. Bacteria that masquerade as fungi: actinomycosis /nocardia. *Proc Am Thorac Soc* 2010;7:216-21.
12. Jorgensen J. *Manual of clinical microbiology*. Washington, DC: ASM Press; 2015.
13. World Health Organization. *Global Action Plan on Antimicrobial Resistance*. Geneva: WHO; 2015.