

This is an Open Access article licensed under the terms of the Creative Commons Attribution-NonCommercial-NoDerivs 3.0 License (www.karger.com/OA-license), applicable to the online version of the article only. Distribution for non-commercial purposes only.

Subtle Hepatocellular Carcinoma: A Persisting Role for Alpha-Fetoprotein Monitoring in High-Risk Patients with Cirrhosis

Barry Schlansky^a Nora Dobos^b Atif Zaman^a

^aDivision of Gastroenterology and Hepatology, Department of Medicine, and

^bDepartment of Diagnostic Radiology, Oregon Health & Science University, Portland, Oreg., USA

Key Words

Hepatocellular carcinoma · Alpha-fetoprotein monitoring · Cirrhosis · Hepatitis B · HIV

Abstract

Hepatocellular carcinoma (HCC) is a common, aggressive malignancy that usually develops in a background of liver cirrhosis. Practice guidelines recommend screening of cirrhotic patients with ultrasound and more detailed imaging (computed tomography or magnetic resonance imaging) if abnormalities are detected. The utility of alpha-fetoprotein levels in HCC surveillance is controversial. Although HCC risk differs by etiology of cirrhosis, screening and surveillance guidelines are uniform after cirrhosis is established. We report a case of rapidly progressive HCC occurring in a cirrhotic patient with multiple unique risk factors for neoplasia, detected by a rising alpha-fetoprotein level without imaging features of liver cancer.

Introduction

Hepatocellular carcinoma (HCC) is common in patients with cirrhosis. Practice guidelines issued by the American Association for the Study of Liver Diseases (AASLD) recommend screening for HCC with abdominal ultrasound every 6 months, with abnormalities prompting additional imaging with triple-phase helical computed tomography (CT) or contrast-enhanced magnetic resonance imaging (MRI) [1]. If a small nodule is detected (less than 1 cm in diameter), the imaging study that first detected the lesion is repeated every 3–6 months, with monitoring of the serum alpha-fetoprotein (AFP) level discouraged due to poor specificity. Although the risk of HCC varies with different etiologies of cirrhosis, HCC screening and surveillance recommendations are uniform once cirrhosis is established.

We report a case of advanced HCC, undetected during routine surveillance imaging of a small liver nodule, occurring in a cirrhotic patient with multiple unique risk factors for neoplasia.

Case Report

A 41-year-old man with human immunodeficiency virus (HIV) and hepatitis B virus (HBV) co-infection and cirrhosis was evaluated. With tenofovir and emtricitabine, viral copies of HIV and HBV were undetectable. Although cirrhosis was classified as decompensated due to the identification of large esophageal varices, he had no ascites or encephalopathy and fulfilled the criteria for Child-Pugh class A cirrhosis with Model for End-Stage Liver Disease score 9. CT obtained 2 years before presentation showed an 8-mm nodule in the hepatic dome with arterial enhancement but without portal venous phase washout, and monitoring with CT or MRI every 6 months did not show enlargement or a change in the pattern of contrast enhancement. AFP ranged from 11 to 16 ng/ml. The liver nodule was thought to be of benign etiology.

At presentation the patient reported 1 week of malaise, headache, and nausea. On examination, he was alert and afebrile, with a heart rate of 94 bpm and a blood pressure of 149/89 mm Hg. Cardiopulmonary, neurologic, and abdominal examinations were unremarkable; he had no jaundice, ascites, or asterixis. CT was obtained and demonstrated no change in the hepatic dome nodule and no new lesions (fig. 1a). Laboratory studies revealed white blood cells 5,300/ml, platelets 107,000/ml, bilirubin 1.1 mg/dl, international normalized ratio 1.2, and AFP 24,437 ng/ml. The elevated AFP level prompted a second imaging study, contrast-enhanced MRI, which demonstrated a 10-cm infiltrative mass in the right hepatic lobe with arterial phase enhancement and portal venous phase washout, consistent with HCC (fig. 1b). Tumor thrombus was identified in the right portal vein. Based on this vascular invasion, Barcelona Clinic Liver Cancer stage C HCC was diagnosed. The patient was deemed to have good performance status (Eastern Cooperative Oncology Group score 1), and treatment for advanced HCC was initiated with sorafenib [2, 3].

Discussion

The ability to diagnose HCC without a need for biopsy is unique among cancers, and is facilitated by distinct radiographic features and, more controversially, elevated AFP levels [1]. A minority of patients demonstrate robust AFP production, but when present, AFP levels >200 ng/ml are specific for HCC, and levels >500 ng/ml correlate with tumor size [4]. The sensitivity of CT for HCC detection is 61–74%, versus 76–85% for magnetic resonance angiography or MRI using gadoxetate disodium contrast [5, 6]. Recognizing this limited sensitivity, the AASLD practice guidelines recommend liver biopsy or a second dynamic imaging study when a first study shows a suspicious mass >1 cm in diameter. A lesion <1 cm, if stable over time, is deemed a cirrhotic nodule, and multimodality imaging or histologic evaluation is discouraged. HCC risk varies with the underlying etiology of liver disease, but recommendations for screening and surveillance in cirrhosis do not.

HIV/HBV co-infection is associated with development of advanced liver disease, elevated liver-related mortality, and high rates of hepatocarcinogenesis [7]. HCC is more frequent in co-infected than HBV mono-infected patients with cirrhosis, and progresses more rapidly after it develops [8]. HIV-positive patients with HCC are younger, more apt to have advanced or multiple tumors, and more frequently symptomatic at presentation. Since the efficacy of surveillance is inversely proportional to the rate of tumor growth, accelerated growth of HCC in HIV/HBV co-infection may undermine the benefit of routine surveillance [1, 9]. In this high-risk group, the efficacy and cost-effectiveness of

more frequent surveillance, or combined surveillance with multimodality imaging or the addition of AFP monitoring, has not been evaluated. Elevated HBV viral copies ($>2,000$ IU/ml), low CD4+ count ($<100/\text{mm}^3$), and family history of HCC have been postulated as risk stratification criteria to identify HIV/HBV co-infected patients who may warrant intensive surveillance [9].

Conclusion

Our case illustrates an alarming scenario in which practice guidelines for liver cancer detection would have missed a diagnosis of advanced HCC, delaying treatment. HIV/HBV co-infection portends a poor prognosis in chronic liver disease and an increased risk of rapidly progressive HCC. Though the optimal HCC surveillance strategy in the HIV/HBV co-infected patient remains undefined, clinicians must be aware that among patients with cirrhosis, co-infection is the apex of HCC risk. Despite persistent stable size of a small nodule on a first dynamic imaging study, patients with especially high-risk etiologies of liver disease warrant heightened concern for a malignant process.

Disclosure Statement

Dr. Zaman is the guarantor of this paper. Authors' roles: drafting of the manuscript (B.S.), critical revision and editing of the manuscript (B.S., N.D., A.Z.). All authors approved the final draft submission. None of the authors reports any competing or financial interests in any aspect of the paper. No editorial assistance was provided. The work contained in this paper was not supported by any external funding source.

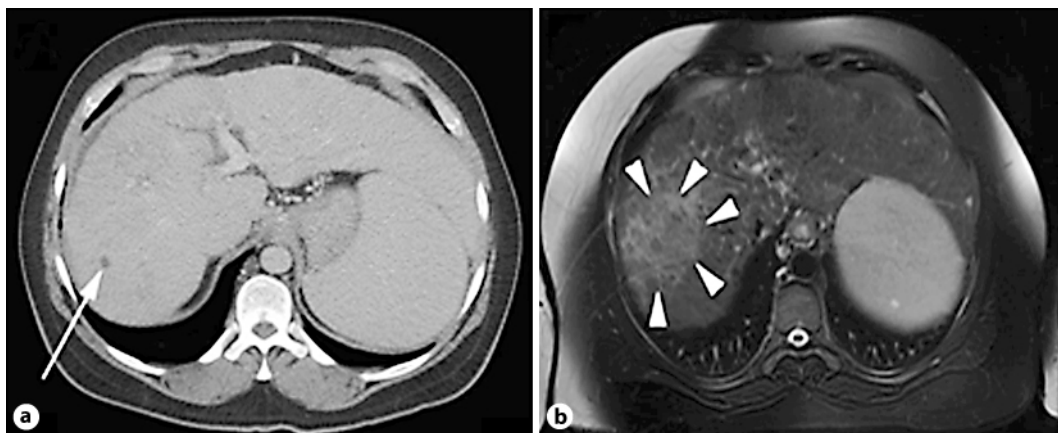


Fig. 1. **a** CT revealing an 8-mm liver nodule (arrow). **b** Contrast-enhanced MRI showing a 10×8 cm enhancing mass in the right hepatic lobe, not seen with CT (arrowheads).

References

- 1 Bruix J, Sherman S: Management of hepatocellular carcinoma: an update. *Hepatology* 2011;53:1020–1022. Available at <http://aasld.org/practiceguidelines/Documents/Bookmarked%20Practice%20Guidelines/HCCUpdate2010.pdf> (accessed August 20, 2011).
- 2 Llovet JM, Ricci S, Mazzaferro V, Hilgard P, Gane E, Blanc JF, de Oliveira AC, Santoro A, Raoul JL, Forner A, Schwartz M, Porta C, Zeuzem S, Bolondi L, Greten TF, Galle PR, Seitz JF, Borbath I, Haussinger D, Giannaris T, Shan M, Moscovici M, Voliotis D, Bruix J; SHARP Investigators Study Group: Sorafenib in advanced hepatocellular carcinoma. *N Engl J Med* 2008;359:378–390.
- 3 Llovet JM, Bru C, Bruix J: Prognosis of hepatocellular carcinoma: the BCLC staging classification. *Semin Liver Dis* 1999;19:329–338.
- 4 Malaguarnera G, Giordano M, Paladina I, Berretta M, Cappellani A, Malaguarnera M: Serum markers of hepatocellular carcinoma. *Dig Dis Sci* 2010;55:2744–2755.
- 5 DiMartino M, Marin D, Guerrisi A, Baski M, Galati F, Rossi M, Brozzetti S, Masciangelo R, Passariello R, Catalano C: Intraindividual comparison of gadoxetate disodium-enhanced MR imaging and 64-section multidetector CT in the detection of hepatocellular carcinoma in patients with cirrhosis. *Radiology* 2010;256:806–816.
- 6 Burrel M, Llovet JM, Ayuso C, Iglesias C, Sala M, Miquel R, Caralt T, Ayuso JR, Sole M, Sanchez M, Bru C, Bruix J; Barcelona Clinic Liver Cancer Group: MRI angiography is superior to helical CT for detection of HCC prior to liver transplantation: an explant correlation. *Hepatology* 2003;38:1034–1042.
- 7 Lok ASF, McMahon BJ: Chronic hepatitis B: update 2009. *Hepatology* 2009;50:661–662. Available at http://aasld.org/practiceguidelines/Documents/Bookmarked%20Practice%20Guidelines/Chronic_Hep_B_Update_2009%208_24_2009.pdf (accessed August 20, 2011).
- 8 Brau N, Fox RK, Xiao P, Marks K, Naqvi Z, Taylor LE, Trikha A, Sherman M, Sulkowski MS, Dieterich DT, Ribsgy MO, Wright TL, Hernandez MD, Jain MK, Khatri GK, Sterling RK, Bonacini M, Martyn CA, Aytaman A, Llovet JM, Brown ST, Bini EJ; North American Liver Cancer in HIV Study Group: Presentation and outcome of hepatocellular carcinoma in HIV-infected patients: a U.S.-Canadian multicenter study. *J Hepatol* 2007;47:527–537.
- 9 Joshi D, O'Grady J, Taylor C, Heaton N, Agarwal K: Liver transplantation in human immunodeficiency virus-positive patients. *Liver Transpl* 2011;17:881–890.