

## Central retinal artery occlusion after vaccination with whole virion inactivated SARSCoV- 2 vaccine Covaxin

Meenakshi Thakar, Shruti Bhattacharya

Coronavirus disease 2019 (COVID-19) vaccinations have been associated with a higher risk of thromboembolic events. There have been no reports of central retinal artery occlusion (CRAO) after vaccination with the indigenously developed Covaxin, and worldwide, there has been only one such isolated case after administration of the AstraZeneca vaccine. We report a case of a 44-year-old healthy man who presented with sudden painless vision loss in his left eye 10 days after receiving Covaxin. His best-corrected visual acuity was minimal perception of light, with a relative afferent pupillary defect. Fundus examination revealed arterial attenuation and macular cherry red spot, suggesting an acute CRAO. Optical coherence tomography showed macular swelling and disorganization of the inner layers due to ischemic sequelae. Blood work was normal and cardiovascular examination was unremarkable. The patient was kept on follow-up. To our knowledge, this is the first case of an isolated CRAO after Covaxin administration, but further studies are needed to evaluate this potential association.

**Key words:** Covaxin, COVID vaccination, CRAO

Vaccinations<sup>[1]</sup> to prevent coronavirus disease 2019 (COVID-19) have been linked to a higher risk of thromboembolic events like cerebral venous thrombosis. But till date, no such adverse events have been reported after administration of the indigenously developed Covaxin (Bharat Biotech, BBV152), a whole virion-inactivated vaccine,<sup>[2]</sup> and worldwide, there are only three case reports of central retinal artery occlusion (CRAO) post-vaccination – one CRAO after administration of the vector-based AstraZeneca vaccine<sup>[3]</sup> and two reports of a CRAO combined with central retinal vein occlusion (CRVO) after administration of the mRNA vaccine.<sup>[4,5]</sup> We report a case of a patient who developed isolated CRAO 10 days after administration of Covaxin.

Access this article online	
Quick Response Code:	Website: www.ijjo.in
	DOI: 10.4103/ijjo.IJO_1148_22

Department of Ophthalmology, Guru Nanak Eye Centre, Maulana Azad Medical College, New Delhi, Delhi, India

**Correspondence to:** Dr. Shruti Bhattacharya, Retina Clinic, Guru Nanak Eye Centre, Maharaja Ranjit Singh Marg, New Delhi - 110002, India. E-mail: shrutibhattacharya1993@gmail.com

Received: 20-May-2022

Revision: 25-Jun-2022

Accepted: 05-Aug-2022

Published: 30-Sep-2022

## Case Report

A 44-year-old male presented 15 days after vaccination with the second dose of Covaxin (Bharat Biotech, BBV152) with a 5-day history of loss of vision in the left eye. He had no previous history of cardiovascular disease, hypercoagulable state, smoking, malignancy, or diabetes, and was on no medications.

A nasopharyngeal swab test ruled out an ongoing COVID-19 infection. The best-corrected visual acuity was 6/6 in the right eye and in the left eye, it was light perception without projection. Ophthalmologic examination of the right eye (OD) was within normal limits, but the left eye (OS) showed a relative afferent pupillary defect with an otherwise normal anterior segment. Dilated fundus examination of the affected eye revealed retinal whitening, disk edema and pallor, retinal arterial narrowing, and a cherry red spot at the macula, suggestive of CRAO [Fig. 1]. Optical coherence tomography showed an intact foveal depression, a central macular thickness of 300 µm, along with disorganization of the inner retinal layers and distortion of the photoreceptor integrity line, likely secondary to ischemic sequelae [Fig. 2].

Complete blood count and other blood tests were within normal limits, apart from a mildly raised erythrocyte sedimentation rate (ESR) of 28, and there was no thrombocytopenia [Table 1]. The cardiovascular referral was unremarkable with a normal chest X-ray, electrocardiogram, and echocardiogram.

Giant cell arteritis could be ruled out by almost normal values of ESR. Also, patient did not have headache or temporal artery tenderness, and the temporal artery pulse was not diminished.

The patient was unwilling for a fundus fluorescein angiography (FFA) and considering the poor prognosis, he was kept on follow-up.

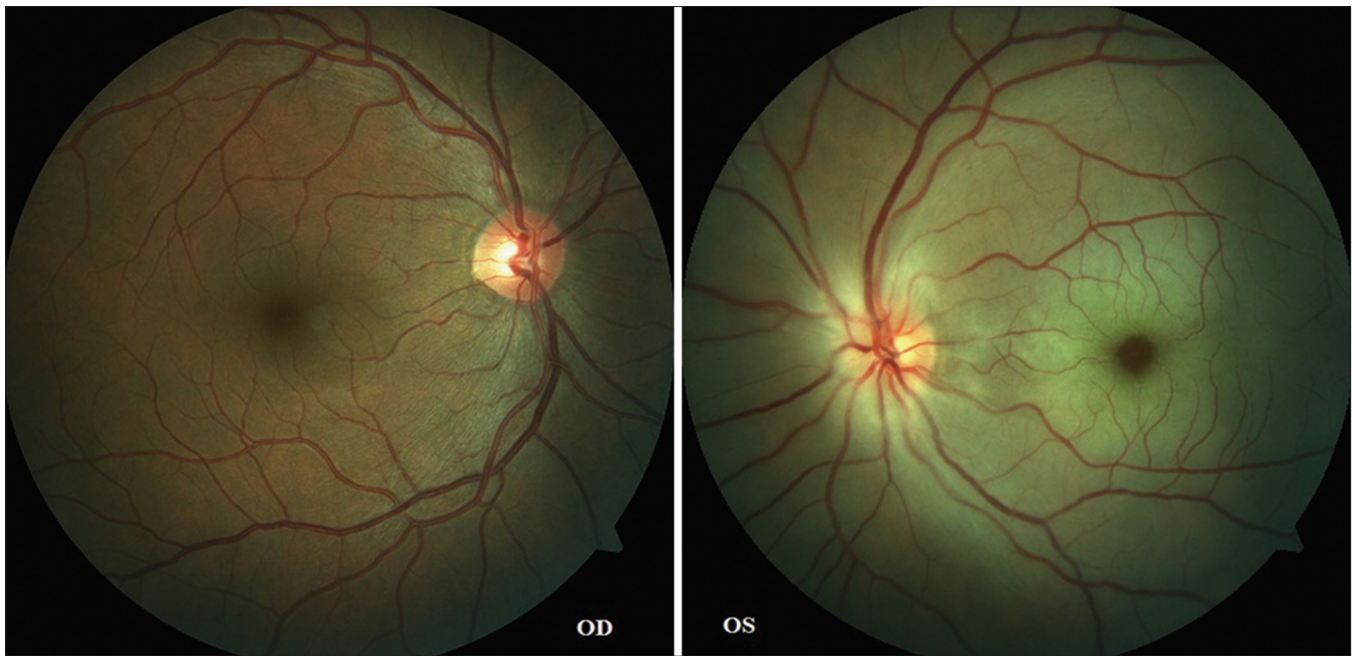## Discussion

The COVID-19 pandemic has necessitated a worldwide vaccination program to prevent the disease and lessen its severity. However, this has not been without its risks. By March 2021, 30 cases of predominantly venous thromboembolic events had been reported following administration of the Oxford–AstraZeneca COVID-19 vaccine in Europe. This included sinus or cerebral venous thrombosis and heparin-induced thrombocytopenia (HIT)-like syndrome.<sup>[6]</sup> Another study reported 169 cases of potentially life-threatening cerebral venous sinus thrombosis (CVST) in individuals vaccinated with AstraZeneca.<sup>[7]</sup>

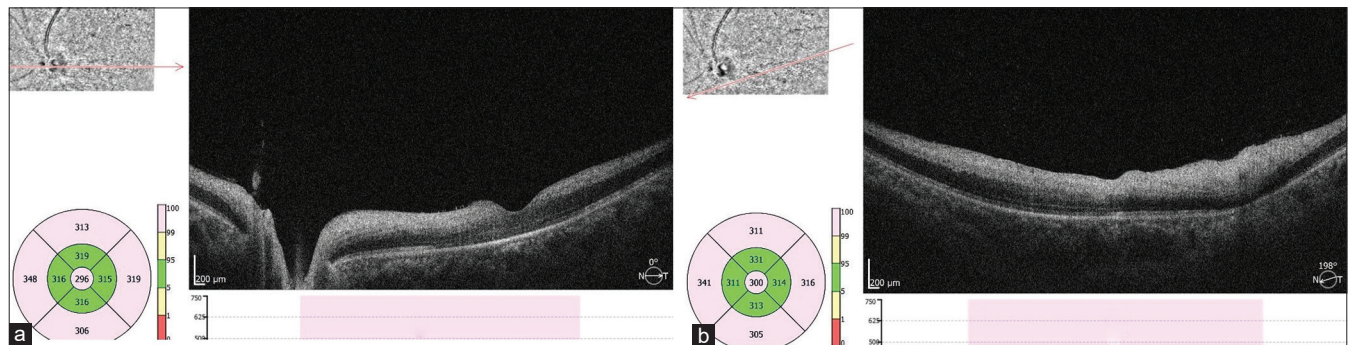
This is an open access journal, and articles are distributed under the terms of the Creative Commons Attribution-NonCommercial-ShareAlike 4.0 License, which allows others to remix, tweak, and build upon the work non-commercially, as long as appropriate credit is given and the new creations are licensed under the identical terms.

**For reprints contact:** WKHLRPMedknow\_reprints@wolterskluwer.com

**Cite this article as:** Thakar M, Bhattacharya S. Central retinal artery occlusion after vaccination with whole virion inactivated SARSCoV- 2 vaccine Covaxin. Indian J Ophthalmol 2022;70:3716-8.



**Figure 1:** Fundus photo of a normal right eye and left eye with Disc edema, attenuated arteries, retinal whitening, and a macular cherry red spot



**Figure 2:** Left OCT of the macula through two different areas showing (a) preserved central foveal pit with parafoveal mild edema (Central Macular Thickness [CMT] 296 μm) with hyperreflectivity and disorganization of the inner retinal layers and hyporeflective outer retinal layers with retinal pigment epithelium and photoreceptor layer disruption and (b) distorted contour with similar inner layer hyperreflectivity and outer layer hyporeflectivity, with disorganization of all the layers. Both of these suggest an acute ischemic insult to the macula. OCT = optical coherence tomography

Ocular adverse events following vaccination include episcleritis, anterior scleritis, acute macular neuroretinopathy, paracentral acute middle maculopathy, and subretinal fluid after vaccination with inactivated COVID-19 vaccine (Sinopharm).<sup>[8]</sup> Other reported side effects include venous stasis retinopathy, non-arteritic anterior ischemic optic neuropathy, and nerve fiber infarction.<sup>[4]</sup>

Research so far has been focused on the three big vaccines – AstraZeneca and the two mRNA vaccines manufactured by Pfizer and Moderna, with almost no reports on the indigenous Covaxin. India is currently running the world’s largest vaccination campaign with mainly AstraZeneca/Covishield (AZD1222) and Covaxin (BBV152). Till now, two cases of CRVO have been reported in India after the second dose of the Covishield vaccine.<sup>[9]</sup> Covaxin is a whole virion-inactivated severe acute respiratory syndrome-coronavirus 2 (SARS-CoV-2) vaccine formulated with a toll-like receptor 7/8 agonist molecule adsorbed to

alum, and it concluded its Phase 3 clinical trial in December 2021, with no reported clinically significant serious adverse events.<sup>[2]</sup>

Hypotheses about the pathogenesis of thromboembolic events after inactivated vaccines include interactions between the vaccine and platelets or between the vaccine and platelet factor 4 (PF4). The proposed mechanisms include the formation of autoantibodies against PF4, antibodies induced by the free deoxyribonucleic acid (DNA) in the vaccine that cross react with PF4, and adenovirus binding to the platelets, which causes platelet activation leading to thrombus and emboli.<sup>[9]</sup> Another theory is that the coding sequence S-immunogen in the AstraZeneca vaccine has not been changed to minimize shedding of the expressed S protein. Thus, it is possible this S protein in the circulation after vaccination can induce a procoagulant response or direct disturbance of endothelial cell integrity, causing adverse events.<sup>[7]</sup>

**Table 1: Blood test values**

Test	Value	Unit	Reference
Hemoglobin	14.0	g/dl	12.0-16.0
Hematocrit	34.8	%	36-46
MCHC	40.2	g/dl	31-35
MCH	32	pg	27-32
MCV	79.6	fl	76-96
Erythrocytes	4.37	1012/l	4.00-6.5
ESR	28	mm/first hour	0-15
INR	1.00		0.85-1.15
Platelet count	243	109/l	150-450
Prothrombin	20	s	21-34
Thrombin time	17	s	14-21
Leukocytes	8.9	109/l	4.0-11
Creatinine	8.9	mg/dl	0.50-0.90
CRP	4.9	mg/l	0.0-5.0
Total cholesterol	164.6	mg/dl	150-200
Triglycerides	65.02	mg/dl	25-150
HDL	45.4	mg/dl	30-60
LDL	106.2	mg/dl	50-150
RBS	107	mg/dl	<140

CRP=C-reactive protein, ESR=erythrocyte sedimentation rate, HDL=high-density lipoprotein, INR=international normalized ratio, LDL=low-density lipoprotein, MCH=mean corpuscular hemoglobin, MCHC=mean corpuscular hemoglobin concentration, MCV=mean corpuscular volume, RBS=random blood sugar

Smadja *et al.*<sup>[6]</sup> reported that there was a difference in the incidence time of the venous thrombotic events between AstraZeneca (median 6 days) and the mRNA vaccines (median 4 days). This may be extrapolated to our patient who had his arterial thrombotic event 10 days after vaccination, considering that Covaxin is also an inactivated vaccine like AstraZeneca.

## Conclusion

To the best of our knowledge, this is the first case of an isolated CRAO following the administration of the Covaxin COVID-19 vaccine and the second case overall of isolated CRAO post COVID-19 vaccination. Further studies are needed to evaluate this potential association and identify the causative factors between COVID-19 vaccines and CRAO, but these adverse effects need to be interpreted with caution when weighed against the benefits of vaccination.

## Declaration of patient consent

The authors certify that they have obtained all appropriate patient consent forms. In the form the patient(s) has/have given his/her/their consent for his/her/their images and other clinical information to be reported in the journal. The patients understand that their names and initials will not be published and due efforts will be made to conceal their identity, but anonymity cannot be guaranteed.

## Financial support and sponsorship

Nil.

## Conflicts of interest

There are no conflicts of interest.

## References

- Pottegård A, Lund LC, Karlstad Ø, Dahl D, Andersen M, Hallas J, *et al.* Arterial events, venous thromboembolism, thrombocytopenia, and bleeding after vaccination with Oxford-AstraZeneca ChAdOx1-S in Denmark and Norway: Population based cohort study. *BMJ* 2021; 373:n1114.
- Ella R, Reddy S, Blackwelder W, Potdar V, Yadav P, Sarangi V, *et al.* COVAXIN Study Group. Efficacy, safety, and lot-to-lot immunogenicity of an inactivated SARS-CoV-2 vaccine (BBV152): Interim results of a randomised, double-blind, controlled, phase 3 trial. *Lancet* 2021; 398:2173-84.
- Abdin AD, Gärtner B, Seitz B. Central retinal artery occlusion following COVID-19 vaccine administration. *Am J Ophthalmol Case Rep* 2022;26:101430.
- Girbardt C, Busch C, Al-Sheikh M, Gunzinger JM, Invernizzi A, Biswas J, *et al.* Retinal vascular events after mRNA and adenoviral-vectored COVID-19 vaccines—A case series. *Vaccines* 2021;9:1349.
- Ikegami Y, Numaga J, Okano N, Fukuda S, Yamamoto H, Terada Y. Combined central retinal artery and vein occlusion shortly after mRNA-SARS-CoV-2 vaccination. *QJM* 2022;114:884-5.
- Smadja DM, Yue QY, Chocron R, Sanchez O, Lillo-Le Louet A. Vaccination against COVID-19: Insight from arterial and venous thrombosis occurrence using data from VigiBase. *Eur Respir J* 2021;58:2100956.
- Jampol LM, Tauscher R, Schwarz HP. COVID-19, COVID-19 vaccinations, and subsequent abnormalities in the retina: Causation or coincidence? *JAMA Ophthalmol* 2021;139:1135-6.
- Pichi F, Aljneibi S, Neri P, Hay S, Dackiw C, Ghazi NG. Association of ocular adverse events with inactivated COVID-19 vaccination in patients in Abu Dhabi. *JAMA Ophthalmol* 2021;139:1131-5.
- Sonawane NJ, Yadav D, Kota AR, Singh HV. Central retinal vein occlusion post-COVID-19 vaccination. *Indian J Ophthalmol* 2022;70:308-9.