

Refractory Status Epilepticus in a Patient with SARS-CoV2 Infection: Possible Mechanisms

During the pandemic of SARS-CoV2 infection (COVID-19), several neurological complications have been documented. However, the direct causality is uncertain.^[1,2] Seizures or status epilepticus (SE) are very rare complications of SARS-CoV2 infection. In a recent study in Iran, seizure was the presenting symptom in 0.8% of all patients with severe illness. Four of these patients (9%) had a history of epilepsy.^[3] A recent systematic review identified SE in 47 patients with COVID-19. The reported types of SE included generalized convulsive SE (GCSE); GCSE evolving to nonconvulsive SE (NCSE); focal motor SE (FMSE); FMSE evolving to NCSE; motor SE evolving to NCS; and NCSE.^[4] In a meta-analysis of electroencephalogram (EEG) findings in 308 patients with COVID-19, the proportion of patients with SE on EEG was 2.05%.^[5] This report describes refractory SE (RSE) in a patient with COVID-19 and a history of frontal focal epilepsy and reviews the literature.

A 21-year-old male, a known case of right frontal focal-onset epilepsy secondary to left frontal focus, [Figure 1] was brought to the Emergency Medicine Department (EMD) for high-grade fever and chills, dry cough, and breathlessness of a duration of 2 days. At EMD, he was febrile, dyspneic, and hemodynamically stable. He was intubated and put on

mechanical ventilation for hypoxia (SpO₂ 88%). High-resolution CT (HRCT) thorax showed multiple areas of ground-glass opacities and consolidations and fibro-atelectatic lesions in the left lung (CORAD 5). SARS-CoV2 nasopharyngeal swab RT-PCR was positive. White blood counts ranged between 3,900 and 23,600/cu mm with lymphopenia. He was put on injection azithromycin and injection cefoperazone and sulbactam combination. The antiseizure medications (ASM) which he was taking – levetiracetam 750 mg q12h, lacosamide 200 mg q12h, and clobazam 15 mg q24 – were continued. He had not missed any of the ASM before this admission. He required continuous sedation for ventilator dyssynchrony. Initially, he was started on fentanyl (max infusion rate 100 ug/kg/h), as he continued to fight the ventilator, he was started on midazolam (maximum infusion rate 0.5 mg/kg/h). On day-2, he had prolonged right focal, facio-brachial onset to bilateral tonic-clonic seizure. Proper neurological assessment could not be done as he was sedated. The pupils were of equal size and reactive to light. Midazolam infusion was increased to 1 mg/kg/h and was given IV levetiracetam 3000 mg load, and the oral dose was increased to 1500 mg q12h. Continuous EEG (cEEG) monitoring could not be started due to constraints

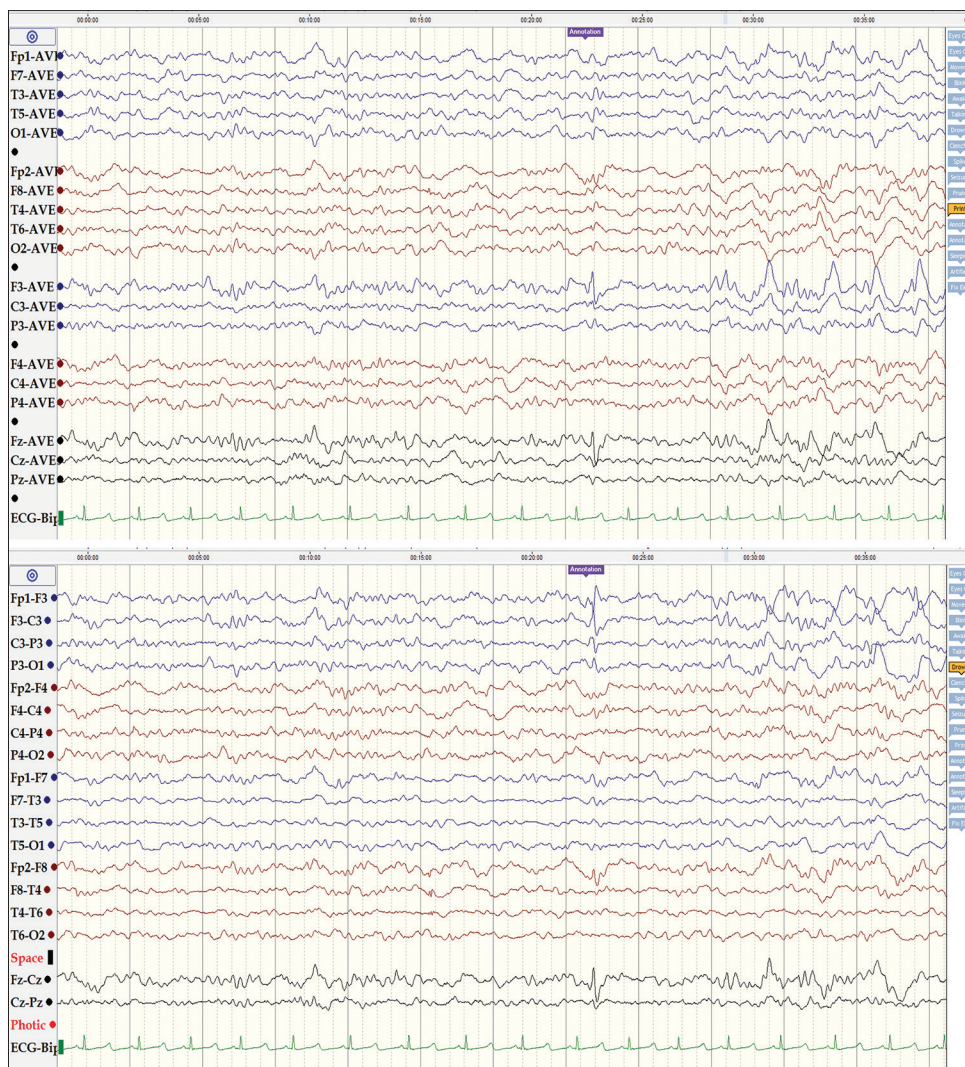


Figure 1: Awake EEG showing normal background activity. (Bottom) longitudinal anterior-posterior bipolar montage showing a transient of spikes in the left anterior frontal and central with negative phase reversal at F3; (Top) common average reference montage showing voltage maximum at F3

of pandemic and also nonavailability of subdural single-use needle electrodes. During this event, he was hemodynamically stable. He was started on low molecular weight heparin in view of elevated levels of D-dimer (3–68 pg/mL). On day-3, he had multiple episodes of right focal, facio-brachial onset seizures while on midazolam infusion, breakthrough seizures. CT brain showed features suggestive of small vessel disease and no acute pathology or any chronic pathology for epilepsy. On day-4, he had recurrent episodes of right focal, facio-brachial onset to bilateral tonic-clonic seizures, while on midazolam infusion, breakthrough seizures. Proper neurological evaluation could not be done as he was on midazolam infusion. The pupils were bilaterally equal and reactive to light. He was started on ketamine infusion 2 mg/kg/h in addition to midazolam infusion. In view of fluctuations in arterial oxygen partial pressure (PaO_2)/fractional inspired oxygen (FiO_2) ratios, he was put on prone ventilation. Blood and urine cultures were negative, and serum procalcitonin (PCT-Q) was 3.03. The antibiotic was escalated to injection meropenem. He was

hemodynamically stable. On day-6, he had recurrent right focal onset to bilateral tonic-clonic seizures, the dose of ketamine was increased (maximum infusion rate 4 mg/kg/h), and perampanel 4 mg oral was added, and the dose was increased to 12 mg over the next 6 days. He had no observable clinical seizures from day-11. Infusion of midazolam and ketamine were slowly tapered over the next 3 days. On day-14, ECG showed bradycardia, lacosamide was stopped. On day-18, EEG showed diffuse slowing. He was discharged on day-23 in a stable condition on ASM. In the follow-up, he is seizure free and back to his previous occupation.

Our patient, a known case of right frontal focal-onset epilepsy was admitted for COVID-19 and refractory CSE (RSE). In this patient, probably the RSE was precipitated by the SARS-CoV2 infection. There was no change in the seizure semiology, and it was the same before and during RSE. RSE was terminated with intravenous anesthetic agents (midazolam and ketamine) and oral perampanel. Withdrawal of therapeutic coma was based solely on the absence of clinical seizures.

The standard of care of patients with RSE includes cEEG monitoring during therapeutic coma. We could not do so as our hospital EEG triage policy is to limit exposure of EEG technologists to patients with COVID-19. We do not have subdural single-use needle electrodes. Because of this limitation, it is possible that we would have exposed the patient to anesthetic agents for a longer time than required before withdrawing therapeutic coma.

The possible mechanism for seizures/SE in patients with COVID-19 is unknown. Two possible mechanisms have been suggested virus infection mechanisms and autoimmune mechanisms. The neuropathological features in the brains of patients with COVID-19 showed astrogliosis and no evidence to suggest fulminant virus-induced encephalitis nor direct evidence for SARS-CoV2 caused CNS damage.^[6] Activation of microglia and infiltration by cytotoxic T lymphocytes was most pronounced in the brainstem and cerebellum. Meninges showed cytotoxic T lymphocyte infiltration. SARS-CoV-2 was detected by quantitative real time (qRT)-PCR predominantly in the brainstem, but small amounts were also detected in frontal lobe tissue and activation of microglia and infiltration of cytotoxic T lymphocytes in small amounts (up to 49 cells per HPF) in the frontal cortex.^[6] In patients with COVID-19, a high frequency of frontal EEG abnormalities has been reported.^[7-9] Nearly about a half of reported EEG focal slowing (49%) and SE (45%) involved the frontal regions.^[7] All these observations suggest that in nearly half of the patients with COVID-19 and SE, the SE is probably due to a frontal epileptogenic focus. This may be due to virus infection mechanisms. Access for the virus to CNS is via the neuroepithelium of the olfactory bulb. This hypothesis is supported by the frequent initial presentation of hyposmia/anosmia and the pathological changes in the olfactory bulb.^[1,2,8]

It is possible that acute systemic factors may precipitate SE in patients with SARS-CoV2 infection. However, the published literature does not support this possibility.^[3,4,10] In a retrospective multicenter study in China, neither acute symptomatic seizures nor SE was observed in a cohort of 304 people hospitalized during the acute phase of COVID-19. This was despite a substantial proportion of the cohort having risk factors for acute symptomatic seizures.^[10] In our patient, there were no acute systemic causes to explain SE at the onset. Moreover, he presented with SE on day-2 of SARS-CoV2 infection. The seizure semiology was similar to habitual seizures. We feel that in this patient the SARS-CoV2 infection associated frontal lobe pathological changes might have lowered the seizure threshold of the existing epileptogenic focus and thus triggered RSE. Vollono *et al.*^[11] reported a known patient with focal-onset epilepsy with SARS-CoV2 infection and SE, in whom ictal EEG showed left fronto-centro-temporal ictal rhythms consistent with SE. EEG performed 10 days before the present admission was normal.

Highlights

- Acute symptomatic seizures and status epilepticus (SE) are rare in active COVID-19

- SE can be convulsive or nonconvulsive,
- A review of the literature suggests in nearly a half of the patients, SE is due to frontal epileptogenic focus
- Epileptogenesis is probably due to virus infection mechanisms

Financial support and sponsorship

Nil.

Conflicts of interest

There are no conflicts of interest.

Shyam K. Jaiswal, Jagarlapudi M. K. Murthy, Lalitha Pidaparathi, Muralidhar R. Yerasu, Srikanth R. Yeduguri

Department of Neurology, CARE Institute of Neurosciences, CARE Hospitals, Hyderabad, Telangana, India

Address for correspondence: Dr. Shyam K. Jaiswal, Consultant Neurologist, CARE Institute of Neurosciences, CARE Hospitals, Road No. 10, Banjara Hills, Hyderabad, Telangana, India. E-mail: shyamjais80@gmail.com

REFERENCES

1. Paterson RW, Brown RL, Benjamin L, Nortley R, Wiethoff S, Barucha T, *et al.* The emerging spectrum of COVID-19 neurology: Clinical, radiological and laboratory findings. *Brain* 2020;143:3104-20.
2. Ellul MA, Benjamin L, Singh B, Lant S, Michael BD, Easton A, *et al.* Neurological associations of COVID-19. *Lancet Neurol* 2020;19:767-83.
3. Keshavarzi A, Janbabaie G, Kheyrati L, Ghavamabad LH, Asadi-Pooya AA. Seizure is a rare presenting manifestation of COVID-19. *Seizure* 2021;86:16-8.
4. Dono F, Nucera B, Lanzone J, Evangelista G, Rinaldi F, Speranza R, *et al.* Status epilepticus and COVID-19: A systematic review. *Epilepsy Behav* 2021;118:107887.
5. Kubota T, Gajera PK, Kuroda N. Meta-analysis of EEG findings in patients with COVID-19. *Epilepsy Behav* 2021;115:107682.
6. Matschke J, Lütgehetmann M, Hagel C, Spherhake JP, Schröder AS, Edler C, *et al.* Neuropathology of patients with COVID-19 in Germany: A post-mortem case series. *Lancet Neurol* 2020;19:918-29.
7. Antony A, Haneef Z. Systematic review of EEG findings in 617 patients diagnosed with COVID-19. *Seizure* 2020;83:234-41.
8. Vellieux G, Sonnevill R, Vledouts S, Jaquest P, Rouvel-Talleg M, d'Ortho M. COVID-19-associated neurological manifestations: An emerging electroencephalographic literature. *Front Physiol* 2021;11:622466.
9. Pellinen J, Carroll E, Friedman D, Boff M, Dugan P, Friedman DE, *et al.* Continuous EEG findings in patients with COVID-19 infection admitted to a New York academic hospital system. *Epilepsia* 2020;61:2097-105.
10. Lu L, Xiong W, Liu D, Liu J, Yang D, Li N, *et al.* New onset acute symptomatic seizures and risk factors in coronavirus disease 2019: A retrospective study. *Epilepsia* 2020;61:e49-53.
11. Vollono C, Rollo E, Romozzi M, Frisullo G, Servidei S, Borghetti A, *et al.* Focal status epilepticus as unique clinical feature of COVID-19: A case report. *Seizure* 2020;78:109-12.

Received: 18-May-2021 Accepted: 10-Jun-2021 Published: 15-Feb-2022

This is an open access journal, and articles are distributed under the terms of the Creative Commons Attribution-NonCommercial-ShareAlike 4.0 License, which allows others to remix, tweak, and build upon the work non-commercially, as long as appropriate credit is given and the new creations are licensed under the identical terms.

For reprints contact: WKHLRPMedknow_reprints@wolterskluwer.com

DOI: 10.4103/aian.aian_440_21