



## Case report

## Moraxella atlantae keratitis presenting with an infectious ring ulcer



Alexander Barash, Timothy Y. Chou\*

New York Eye and Ear Infirmary of Mount Sinai, New York, NY 10003, USA

## ARTICLE INFO

## Article history:

Received 2 August 2016

Received in revised form

10 January 2017

Accepted 3 June 2017

Available online 12 June 2017

## Keywords:

Moraxella atlantae

Ring ulcer

Wessely ring

Ring infiltrate

Annular infiltrate

Keratitis

## ABSTRACT

**Purpose:** *Moraxella atlantae* is a rare pathogen. Keratitis from this organism has never been specifically reported or described. In this report we provide the first clinical description and photograph of *Moraxella atlantae* infectious keratitis.

**Observations:** A 41 year-old man presented with a three day history of left eye pain. He was found to have a corneal ring ulcer and infiltrate from which *Moraxella atlantae* was cultured. The patient was successfully treated with intensive topical gatifloxacin (0.5%) and fortified tobramycin (1.5%); oral doxycycline was added to reduce corneal thinning. The patient's infection resolved with a residual scar and final best corrected visual acuity of 20/200 OS.

**Conclusions and importance:** *Moraxella atlantae* can present as a ring-shaped infectious corneal infiltrate and ulcer. Ring infiltrates have been observed with other microorganisms, including several other gram negative bacteria and classically, acanthamoeba. Frequently presumed to be purely immunologic, corneal ring infiltrates can have a number of other etiologies, including infectious and toxic. There are different types of immunologic rings as well, making differentiation of corneal rings sometimes difficult for the ophthalmologic generalist and subspecialist alike. In this paper we discuss characteristics of various corneal ring infiltrates, along with their immune pathophysiology. Infectious rings are distinguished from immunologic Wessely rings.

Published by Elsevier Inc. This is an open access article under the CC BY-NC-ND license (<http://creativecommons.org/licenses/by-nc-nd/4.0/>).

## 1. Introduction

*Moraxella* is a gram negative, oxidase positive diplobacillus that grows in pairs and chains. While it can be cultured elsewhere, *Moraxella* is predominantly an ear, nose, and throat, or ocular pathogen.<sup>1</sup> Ocular infections can range from angular blepharconjunctivitis to severe keratitis.<sup>2</sup> Once associated with malnourished alcoholics and debilitated elderly individuals, *Moraxella* infections have since been reported in healthy patients with abnormalities of the eyelids, conjunctiva, and corneal epithelium.<sup>3</sup> Risk factors for *Moraxella* keratitis include systemic disease such as diabetes and leprosy, and ocular factors such as blepharitis, dry eye, contact lens wear, herpes infection, glaucoma, thyroid eye disease, lagophthalmos, scleritis, trauma, penetrating keratoplasty, bullous keratopathy, and blind eye.<sup>2,4</sup>

Several *Moraxella* species are known to infect the human eye including *M. nonliquefaciens*, *M. lacunata*, *M. osloensis*, and

*M. atlantae*.<sup>1</sup> *M. liquifaciens*, a common cause of corneal ulcers in the past, has now been grouped with *M. lacunata*.<sup>5</sup> *M. catarrhalis*, previously categorized under genera Neisseria and later Branhamella, has occasionally been implicated in conjunctivitis, ulcerative keratitis, pseudomembrane, and endophthalmitis.<sup>6,7</sup> *Moraxella atlantae* is an uncommon opportunistic pathogen<sup>8</sup> – of all *Moraxella* eye infections cultured and sent to the CDC from 1953 to 1980, only one percent were due to *M. atlantae*.<sup>1</sup> To date, this species has been described in only two other patients, both bacteremic: one with lupus<sup>9</sup> and one with metastatic rectal adenocarcinoma.<sup>8</sup> Neither had ocular involvement. Since *Moraxella* isolates are often considered non-pathogenic or contaminants,<sup>1</sup> there is the possibility that microbiology labs may not always speciate *Moraxella* infections. Additionally, *Moraxella* can be difficult to grow, due to wide sensitivity to antibiotics and fastidious growth requirements.<sup>3,8</sup> These factors may lead to a potential under-reporting of certain *Moraxella* species.<sup>8</sup> Regardless, *M. atlantae* ocular infections are rare, and their typical presentation is unknown. In this paper we present the first clinical description of *Moraxella atlantae* keratitis, manifesting as an ulcerative ring infiltrate.

\* Corresponding author. Department of Ophthalmology, State University of New York at Stony Brook Health Sciences Center L2, Rm 152 Stony Brook, NY 11794-8223, USA.

E-mail address: [Timothy.Chou@stonybrookmedicine.edu](mailto:Timothy.Chou@stonybrookmedicine.edu) (T.Y. Chou).

## 2. Case report

A 41 year-old man presented with 3 days of worsening pain and blurred vision in the left eye. He denied recent trauma or contact lens use, but had a remote history of flash burn from welding OU and metallic corneal foreign body OS. He smoked a pack per day and consumed alcohol to an unspecified degree.

On examination vision was 20/30 OD and hand motion OS. Slit lamp exam of the left eye showed a corneal ulcer with a 4mm epithelial defect, an underlying circular infiltrate of the same size, 85–90% stromal thinning, and no hypopyon (Fig. 1). Based on clinical appearance, a gram-negative infection was initially suspected; the patient was prescribed intensive topical gatifloxacin (0.5%) and fortified tobramycin (1.5%). Oral doxycycline was added to reduce collagenolysis and corneal thinning. Corneal scrapings were taken, and cultures eventually grew *Moraxella atlantae*. In the course of his care, the patient displayed indications of alcohol abuse including unreliability following instructions and the smell of alcohol on his breath. He was followed closely for the first 2 weeks, and showed a positive clinical response to antibiotic therapy. However, he was then lost to follow-up for the next three months. When he returned, the ulcer had resolved with a residual scar and mild corneal thinning. Best corrected visual acuity had improved to 20/200.

## 3. Discussion

*Moraxella* keratitis typically presents as a painless and indolent localized oval-shaped ulcer with an undermined necrotic edge and gray infiltrate.<sup>2,10</sup> Infections are usually located in the inferocentral cornea, or may be marginal in association with angular blepharitis.<sup>2,10</sup> Ulcers, however, can also develop severe inflammation, frequently associated with hypopyon; occasionally hyperacute inflammation causes a hyphema to form within the hypopyon.<sup>2,7</sup> Untreated infections slowly progress to deeper corneal layers, accompanied by tissue destruction and possible perforation.<sup>3,10</sup> Ring infiltrate is an unusual finding in *Moraxella* corneal infections. In the largest review of 95 cases of *Moraxella* keratitis, there was no mention of ring infiltrate.<sup>2</sup> There is one passing mention of ring infiltrate with *Moraxella* in the literature,<sup>11</sup> without an accompanying citation, case description, or photograph. Our case report contains the first detailed description and clinical

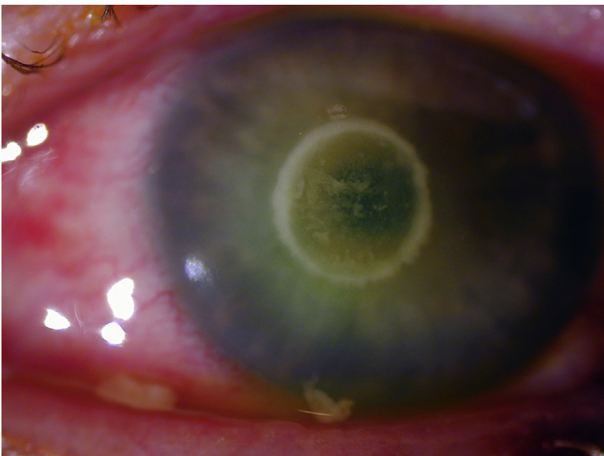


Fig. 1. *Moraxella atlantae* Ring Ulcer: Slit lamp photograph showing central corneal ring abscess.

photograph of an infectious corneal ring caused by *Moraxella atlantae*.

We recently saw an additional case of ring-shaped keratitis involving *Moraxella* in our clinic. An elderly patient with rheumatoid arthritis recently presented after 3 days of eye irritation with an infectious ring ulcer and infiltrate due to *Moraxella catarrhalis* (clinical observation, unpublished). On day 7 as the infiltrate was fading with topical fortified antibiotic treatment, she exhibited a new ring, presumed to be immunologic, peripheral to the original infection. Her musculoskeletal ailments unfortunately precluded satisfactory positioning for slit lamp photos. This additional case indicates that different *Moraxella* species can cause ring infiltrates.

Once considered pathognomonic of *Acanthamoeba* infection,<sup>10,12–15</sup> ring-shaped corneal infections have now been observed with a number of other microorganisms. An annular herpetic ulcer appeared five days after implantation of intracorneal ring segments for keratoconus,<sup>16</sup> and ring infiltrate has been reported as well.<sup>17</sup> Both keratomycoses<sup>11,12,14,16–19</sup> and atypical mycobacterial keratitis<sup>20,21</sup> can have various clinical appearances, including a circular shape. Nevertheless, acanthamoebae remain nine to eleven times more likely to form ring infiltrates than bacteria or fungi.<sup>12</sup> Rings may be incomplete or even double, and their size, density, and shape may vary.<sup>10,13,22–25</sup> A ring infiltrate is often a later finding in *Acanthamoeba* keratitis,<sup>11,28</sup> especially when untreated, and has been considered immunologic.<sup>12,15,22,24</sup> Pathologic examination of the ring, however, reveals that the stroma contains not only polymorphonuclear leukocytes (PMN) but also amebic cysts.<sup>13</sup>

Bacterial ring infiltrates, as in our patient, have been observed most commonly with gram negative organisms such as *Neisseria*, *Serratia*, *Escherichia*, *Klebsiella*, *Proteus*, *Capnocytophaga*, and *Pseudomonas*.<sup>10,17,21,23,26</sup> Infectious rings from gram negative organisms such as *P. aeruginosa* and *E. coli* may appear 24–48 hours after experimental corneal inoculation,<sup>27</sup> and clinically within 2–3 days.<sup>28</sup> Bacterial toxins, damaged host cells, complement, and immune complexes chemotactically attract inflammatory cells.<sup>11,27–30</sup> On histopathologic analysis, gram negative rings show heavy aggregation and concentration of PMNs, especially at the ulcer periphery.<sup>21,27–31</sup> Bacterial proteases such as elastase, however, act to inhibit further centripetal PMN migration.<sup>28,29</sup> They concurrently promote the breakdown of collagen and proteoglycan with the help of bacterial exo- and endotoxins.<sup>32</sup> These processes result in liquefactive necrosis and central tissue loss that accentuate the ring-like appearance.<sup>29,31,32,33</sup>

Gram positive bacteria such as *Staphylococcus*,<sup>11</sup> *Streptococcus*,<sup>15,34</sup> *Bacillus cereus*,<sup>15,21</sup> and *Listeria monocytogenes*<sup>30</sup> have also been implicated in forming corneal rings. Though staphylococcal rings are often immunologic, an actively infectious ring infiltrate from resistant *Staphylococcus* species has been reported with positive cultures and rapid progression.<sup>11</sup> A ring opacity was additionally observed in association with *Streptococcus mitis* infectious crystalline keratopathy, after 3 months of incomplete recognition and treatment.<sup>14</sup> Corneal infection with *Nocardia* classically assumes a beaded wreath appearance,<sup>10,17</sup> although a confluent ring infiltrate is also possible.

It is important to differentiate infectious ring infiltrates from non-infectious immune rings, as both can form in the course of microbial keratitis.<sup>17,19,35</sup> Signs such as pain, purulence, anterior chamber reaction, response to antibiotics over merely steroids alone, epithelial defect greater than 2mm, and necrosis are suggestive of infection, compared to the milder findings of an infiltrate outside the ulcer borders and response to topical steroids as seen with purely immunologic rings.<sup>10–12,19,30,35,36</sup> Infectious ring infiltrates contain viable microorganisms invading host tissue,<sup>29,30</sup> and directly admixed within the host immunologic response. We

suggest that such infiltrates be referred to as “infectious” rings, in contrast to sterile ring infiltrates, which are usually referred to as “immune” rings. This suggestion is to simplify terminology, and not to imply that infectious rings do not include an active immunologic component. Some have also used the term “ring abscess” to describe an infectious ring, particularly suppurative ones.<sup>13,21,23,28,34</sup> An untreated infectious corneal ring may intensify and expand centrifugally,<sup>10,34</sup> whereas immunologic rings slowly migrate centripetally and ultimately fade.<sup>24,28</sup> Even immune rings can, however, also cause tissue damage and corneal scarring through delayed hypersensitivity.<sup>28</sup>

Non-infectious immunologic rings ensue from complement activation by either of two mechanisms: A type 3 hypersensitivity response marked by antibodies interacting with antigens diffusing outward from an inflammatory source (a true “Wessely Ring”<sup>37</sup>), or an antibody-independent mechanism.<sup>15,23,27,35,38–40</sup> Immunologic components required for complement activation are present in the cornea itself.<sup>40</sup> In the classical pathway, as described by Wessely, antibodies diffuse toward antigenic stimuli from the infection. Antibody-antigen complexes form and activate complement in a circular zone.<sup>36,38,39,41</sup> PMN are chemotactically attracted from the periphery and concentrate where complexes have precipitated.<sup>10,24,35,36,39,41</sup> The resultant inflammatory reaction creates a visible ring, typically separated from the central nidus of infection by clear space.<sup>2,5,21,24,35,39</sup> Wessely rings commonly appear at 10–14 days.<sup>23,24,28,36,39</sup> They have been reported following many corneal infections including *S. aureus*,<sup>21</sup> *Herpes simplex*,<sup>38,41</sup> *Vari-cella Zoster*,<sup>11,42</sup> *Microsporidium*,<sup>43</sup> and nontuberculous *Mycobacter-ia*.<sup>10</sup> Ring responses may appear early (1–5 days) if there has been previous exposure to the same bacterial antigen.<sup>27,36,39</sup> In the setting of chronic non-bacterial infectious keratitis, rings have been observed after a longer delay—16 or more days in some *Acantha-moeba*<sup>44</sup> and 2 months in a case of *Microsporidium* keratitis.<sup>43</sup> These infiltrates also contain infectious microorganisms, and occur after protracted periods of no or incomplete therapy.<sup>13,43</sup> Although also referred to as “Wessely rings” by some authors,<sup>24</sup> these annular infiltrates differ in ways from the classic Wessely ring, and their exact immunologic pathophysiology has not yet been fully elucidated.<sup>15</sup>

An antibody-independent, alternative complement activation pathway underlies other corneal immune reactions.<sup>15,23,27,35,39,40</sup> Ring formation was observed 43 hours after irritation in a contact lens user with culture-proven *P. aeruginosa*.<sup>36,39</sup> The authors espoused a bacterial endotoxin-initiated, properdin-mediated complement pathway, independent of antibody and immuno-globulin, consistent with immune ring appearance before 8 days.<sup>36,39,40</sup> Gram negative cell wall endotoxins activate proper-in, leading to antibody-independent complement activation and chemotactic attraction of neutrophils.<sup>27,39</sup> Properdin-mediated rings, like Wessely rings, are distinct from the actual infectious infiltrate and ulcer, and are located between the infiltrate and limbus with an intervening clear zone.<sup>36</sup> Properdin appears to also play a role in early ring formation when *Pseu-domonas* endotoxin is present even absent bacterial tissue invasion.<sup>39,40</sup>

Sterile corneal rings have been observed with the antineoplastic drug Perifosine,<sup>45</sup> topical anesthetic abuse,<sup>10,24,46</sup> Behcet's Disease,<sup>47</sup> contact lens overwear,<sup>48</sup> recurrent corneal erosions,<sup>35,49</sup> post-refractive surgery<sup>50</sup> and corneal crosslinking,<sup>51</sup> lipid keratop-athy,<sup>52,53</sup> posterior polymorphous dystrophy,<sup>54</sup> corneal foreign bodies,<sup>14,24</sup> corneal burns,<sup>14,24</sup> and exposure to aquarium coral toxin.<sup>55</sup> The pathophysiology behind these rings likely differs despite a superficially similar shape. However, disruption of the corneal epithelium and corneal exposure to microbial antigens presumably factors in some instances.<sup>35</sup>

#### 4. Conclusions

Ring infiltrates in the setting of infectious keratitis have been classically associated with acanthamoeba, but now observed with a number of other microorganisms. In this report we provide the first clinical description and photograph of *M. atlantae* ulcerative kera-titis, presenting as a ring-shaped infiltrate. *Moraxella atlantae* is an extremely rare eye pathogen. Potential predisposing risk factors may include a history of ocular trauma and suspected alcohol abuse. The early ring appearance at presentation prior to antibiotic therapy, with full symptoms and findings of infectious keratitis, and positive cultures all point to an infectious corneal ring, rather than a purely immunologic process. Differentiation of corneal rings can sometimes be difficult,<sup>10,15,27</sup> for both the ophthalmologic gener-alist and subspecialist alike. Frequently presumed to be immuno-logic Wessely-like rings, corneal ring infiltrates can have other etiologies, including infectious and toxic. In this paper we expand discussion beyond our case report to review characteristics of various corneal ring infiltrates, along with their immune pathophysiology.

#### Patient consent

The patient and next of kin could not be located or contacted to sign consent to publish this report. The report does not contain any personal information that could lead to identification of the patient.

#### Funding

No funding or grant support.

#### Conflict of interest

The following authors have no financial disclosures: AB, TC.

#### Authors

All authors attest that they meet the current ICMJE criteria for Authorship.

#### Acknowledgements

Pranav Patel, MD assisted in literature search.

#### References

- Graham DR, Band JD, Thornsberry C, Hollis DG, Weaver RE. Infections caused by *Moraxella*, *Moraxella urethralis*, *Moraxella*-like groups M-5 and M-6, and *Kingella kingae* in the United States, 1953–1980. *Rev Infect Dis*. 1990;12:423–431.
- Das S, Constantinou M, Daniell M, Taylor HR. *Moraxella* keratitis: predisposing factors and clinical review of 95 cases. *Br J Ophthalmol*. 2006;90:1236–1238.
- Cobo LM, Coster DJ, Peacock J. *Moraxella* keratitis in a nonalcoholic population. *Br J Ophthalmol*. 1981;65:683–686.
- Mian SI, Malta JB. *Moraxella* keratitis: risk factors, presentation, and manage-ment. *Acta Ophthalmol*. 2011;89:e208–209.
- Tonjum T, Caugand DA, Bovre K. Differentiation of *Moraxella nonliquefaciens*, *M. lacunata*, and *M. bovis* by using multilocus enzyme electrophoresis and hybridization with pilin-specific DNA probes. *J Clin Microbiol*. 1992;30:3099–3107.
- Bergren RL, Tasman WS, Wallace RT, Katz LJ. *Branhamella* (*Moraxella*) catar-rhalis endophthalmitis. *Arch Ophthalmol*. 1993;111:1169–1170.
- Whitcher JP, Cevallos V. *Moraxella*, down but not out—the eye bug that won't go away. *Br J Ophthalmol*. 2006;90:1215–1216.
- De Baere T, Muylaert A, Everaert E, et al. Bacteremia due to *Moraxella atlantae* in a cancer patient. *J Clin Microbiol*. 2002;40:2693–2695.
- Buchman AL, Pickett MJ. *Moraxella atlantae* bacteraemia in a patient with systemic lupus erythematosus. *J Infect*. 1991;23:197–199.
- Keenan JD, McLeod SD. Bacterial keratitis. In: Yanoff M, Duker JS, eds. *Ophthalmology*. fourth ed. Philadelphia: Saunders; 2013:217–224.

11. Wallang BS, Das S, Sharma S, Sahu SK, Mittal R. Ring infiltrate in staphylococcal keratitis. *J Clin Microbiol.* 2013;51:354–355.
12. Mascarenhas J, Lalitha P, Prajna NV, et al. Acanthamoeba, fungal, and bacterial keratitis: a comparison of risk factors and clinical features. *Am J Ophthalmol.* 2014;157:56–62.
13. Theodore FH, Jakobiec FA, Juechter KB, et al. The diagnostic value of a ring infiltrate in acanthamoebic keratitis. *Ophthalmology.* 1985;92:1471–1479.
14. McDonnell JM, Gritz DC, Hwang D, McDonnell PJ. Infectious crystalline keratopathy with ring opacity. *Cornea.* 1992;11:479–483.
15. Kent C. Common wisdom: science or myth? *Rev Ophthalmol.* 2012;19:46–57.
16. Rayward O, Arriola-Villalobos P, Cuiña-Sardiña R, Diaz-Valle D, Benítez-Del-Castillo JM, García-Feijoo J. Annular herpetic keratitis after intracorneal ring segment implantation. *Cornea.* 2011;30:1286. <http://dx.doi.org/10.1097/ICO.0b013e31821c9bb8>.
17. Garg P, Rao GN. Corneal ulcer: diagnosis and management. *Community Eye Health.* 1999;12:21–23.
18. Biser SA1, Perry HD, Donnenfeld ED, Doshi SJ, Chaturvedi V. Arthrographies keratitis mimicking acanthamoeba keratitis. *Cornea.* 2004;23:314–317.
19. Stein RM, Clinch TE, Cohen EJ, Genvert GI, Arentsen JJ, Laibson PR. Infected vs sterile corneal infiltrates in contact lens wearers. *Am J Ophthalmol.* 1988;105:632–636.
20. Moore MD, Newton C, Kaufman HE. Chronic keratitis caused by *Mycobacterium gordonae*. *Am J Ophthalmol.* 1986;102:516–521.
21. Hong AR, Shute TS, Huang A. Bacterial Keratitis. In: Mannis MJ, Holland EJ, eds. *Cornea: Fundamentals, Diagnosis, and Management.* fourth ed. Edinburgh: Elsevier; 2017:875–901.
22. Illingworth CD1, Cook SD. Acanthamoeba keratitis. *Surv Ophthalmol.* 1998;42:493–508.
23. Shovlin J. Ring infiltrates and the contact lens patient: are they pathognomonic? *Int Contact Lens Clin.* 1989;16:25–27.
24. Arffa RC, Grayson M. *Grayson's Diseases of the Cornea.* fourth ed. St. Louis, Mo: Mosby; 1997:675–676, 50–51,271–272.
25. Frangie JM, Moore MB. Parasitic keratitis, including acanthamoeba. In: Leibowitz HM, Waring GO, eds. *Corneal Disorders: Clinical Diagnosis and Management.* second ed. Philadelphia: Saunders; 1998:719–733.
26. Heidemann DG, Pflugfelder SC, Kronish J, Alfonso EC, Dunn SP, Ullman S. Necrotizing keratitis caused by *Capnocytophaga ochracea*. *Am J Ophthalmol.* 1988;105:655–660.
27. Mondino BJ, Rabin BS, Kessler E, Gallo J, Brown SI. Corneal rings with gram-negative bacteria. *Arch Ophthalmol.* 1977;95:2222–2225.
28. Ijiri Y, Yamamoto T, Kamata R, et al. The role of *Pseudomonas aeruginosa* elastase in corneal ring abscess formation in pseudomonal keratitis. *Graefes Arch Clin Exp Ophthalmol.* 1993;231:521–528.
29. Van Horn DL, Davis SD, Hyndiuk RA, Alpren TV. Pathogenesis of experimental *Pseudomonas* keratitis in the Guinea pig: bacteriologic, clinical, and microscopic observations. *Invest Ophthalmol Vis Sci.* 1978;17:1076–1086.
30. Holbach LM, Bialasiewicz AA, Boltze HJ. Necrotizing ring ulcer of the cornea caused by exogenous *Listeria monocytogenes* serotype IV b infection. *Am J Ophthalmol.* 1988;106:105–106.
31. Rapuano C, Luchs J, Kim T. Corneal infections, inflammations, and infectious disorders. In: Krachmer J, ed. *Anterior Segment: The Requisites in Ophthalmology.* 1 ed. St. Louis: Mosby; 2000:108.
32. Chusid MJ, Davis SD. Pathogenesis of corneal and conjunctival infections. In: Tabbara KF, Hyndiuk RA, eds. *Infections of the Eye: Basic Principles and Clinical Management.* Boston: Little Brown & Co Inc; 1986:45–62.
33. Kreger AS, Gray LD. Purification of *Pseudomonas aeruginosa* proteases and microscopic characterization of pseudomonal protease-induced rabbit corneal damage. *Infect Immun.* 1978;19:630–648.
34. Liesegang TJ, Samples JR, Waller RR. Suppurative interstitial ring keratitis due to streptococcus. *Ann Ophthalmol.* 1984;16:392–396.
35. Ionides AC, Tuft SJ, Ferguson VM, Matheson MM, Hykin PG. Corneal infiltration after recurrent corneal epithelial erosion. *Br J Ophthalmol.* 1997;81:537–540.
36. Rabinowitz SM, Starr MB, Gorman BD, Kezirian GM. Properdin-mediated immune ring formation associated with *Pseudomonas* keratitis. *Arch Ophthalmol.* 1987;105:173–174.
37. Sery TW, Pinkes AH, Nagy RM. Immune corneal rings. *Invest Ophthalmol.* 1962;1:672–685.
38. Meyers-Elliott RH, Pettit TH, Maxwell WA. Viral antigens in the immune ring of Herpes simplex stromal keratitis. *Arch Ophthalmol.* 1980;98:897–904.
39. Belmont JB, Ostler HB, Dawson CR, Schwab I, Dulay D. Noninfectious ring-shaped keratitis associated with *Pseudomonas aeruginosa*. *Am J Ophthalmol.* 1982;93:338–341.
40. Mondino BJ, Ratajczak HV, Goldberg DB, Schanzlin DJ, Brown SI. Alternate and classical pathway components of complement in the normal cornea. *Arch Ophthalmol.* 1980;98:346–349.
41. O'Day DM, Jones BR. Herpes simplex keratitis. In: Tasman W, Jaeger EA, eds. *Duane's Clinical Ophthalmology.* vol. 4. Philadelphia: J.B. Lippincott Co; 1991:1–27 (Chapter 19).
42. Khan AO1, Al-Assiri A, Wagoner MD. Ring corneal infiltrate and progressive ring thinning following primary varicella infection. *J Pediatr Ophthalmol Strabismus.* 2008;45:116–117.
43. Thomas KE, Purcell TL, Tanzer DJ, Schanzlin DJ. Delayed diagnosis of microsporidial stromal keratitis: unusual Wessely ring presentation and partial treatment with medications against *Acanthamoeba*. *BMJ Case Rep.* 2011:2011.
44. Zhao G, Sun S, Zhao J, Xie L. Genotyping of *Acanthamoeba* isolates and clinical characteristics of patients with *Acanthamoeba* keratitis in China. *J Med Microbiol.* 2010;59:462–466.
45. Keenan JD, Fram NR, McLeod SD, Strauss EC, Margolis TP. Perifosine-related rapidly progressive corneal ring infiltrate. *Cornea.* 2010;29:583–585.
46. Penna EP, Tabbara KF. Oxybuprocaine keratopathy: a preventable disease. *Br J Ophthalmol.* 1986;70:202–204.
47. Cohen S, Kremer I. Bilateral corneal immune ring opacity in Behcet's syndrome. *Arch Ophthalmol.* 1991;109:324–325.
48. Klein P. Corneal immune ring as a complication of soft extended wear contact lens use. *Optom Vis Sci.* 1991;68:853–857.
49. Papanthassiou M, Gartry D. Sterile corneal ulcer with ring infiltrate and hypopyon after recurrent erosions. *Eye (Lond).* 2007;21:124–126.
50. Teichmann KD, Cameron J, Huaman A, Rahi AH, Badr I. Wessely-type immune ring following phototherapeutic keratectomy. *J Cataract Refract Surg.* 1996;22:142–146.
51. Ghanem RC, Netto MV, Ghanem VC, Santhiago MR, Wilson SE. Peripheral sterile corneal ring infiltrate after riboflavin-UVA collagen cross-linking in keratoconus. *Cornea.* 2012;31:702–705.
52. Waring III GO, Mbekeani JN. Corneal degenerations. In: Leibowitz HM, Waring III GO, eds. *Corneal Disorders: Clinical Diagnosis and Management.* second ed. Philadelphia: WB Saunders Co.; 1998:287–338.
53. Kenyon KR, Navon SE, Haritoglou C. Corneal manifestations of metabolic diseases. In: Krachmer JH, Mannis MJ, Holland EJ, eds. *Cornea.* second ed. vol. 1. Philadelphia: Elsevier Mosby; 2005:749–776. *Fundamentals, Diagnosis and Management.*
54. Witschel H, Sundmacher R, Theopold H, Jaeger W. Posterior polymorphous dystrophy of the cornea (Schlichting). An unusual clinical variant. *Albr Von Graefes Arch Klin Exp Ophthalmol.* 1980;214:15–25.
55. Moshirfar M, Khalifa YM, Espandar L, Mifflin MD. Aquarium coral keratoconjunctivitis. *Arch Ophthalmol.* 2010;128:1360–1362.