



Original Article

Outcome of surgical treatment for displaced acetabular fractures: a prospective study[☆]



Sahu Ramji Lal

Department of Orthopaedics, Sharda University, Greater Noida, India

ARTICLE INFO

Article history:

Received 3 June 2017

Accepted 3 July 2017

Available online 29 December 2017

Keywords:

Acetabulum

Arthroplasty, replacement, hip

Fractures, bone

Hip joint

ABSTRACT

Objective: The aim of this study was to evaluate the functional outcome of surgically treated acetabular fractures.

Methods: A prospective longitudinal study was undertaken in this hospital during the period from December 2010 to December 2014. A total number of 46 patients with the diagnosis of acetabular fracture were included in the study. The main cause of the acetabular injury was a road traffic accident. All the patients were treated surgically with plates and screws. Outcome was assessed radiologically and functionally, employing the Harris Hip Score. The mean follow-up period of the patients in the postoperative period was 30 months (24–36 months).

Results: The results were excellent in 60.86%, good in 21.73%, fair in 8.69%, and poor in 8.69%. Post-operative complications of acetabular fracture such as heterotopic ossification were found in 2.17%, osteoarthritis in 6.52%, skin infections in 4.34%, nerve lesions in 2.17%, and vascular necrosis in 4.34% of patients. More than 80% of patients were satisfied with the results of acetabular surgeries.

Conclusion: These results show that internal fixation of acetabular fractures leads to a good outcome in the majority of patients.

© 2017 Sociedade Brasileira de Ortopedia e Traumatologia. Published by Elsevier Editora Ltda. This is an open access article under the CC BY-NC-ND license (<http://creativecommons.org/licenses/by-nc-nd/4.0/>).

Resultado do tratamento cirúrgico de fraturas acetabulares desviadas: estudo prospectivo

RESUMO

Objetivo: Avaliar o resultado funcional das fraturas acetabulares tratadas cirurgicamente.

Métodos: Um estudo longitudinal prospectivo foi realizado neste hospital entre dezembro de 2010 e dezembro de 2014. Foram incluídos 46 pacientes com diagnóstico de fratura acetabular. A principal causa da lesão acetabular foi acidente de trânsito. Todos os pacientes foram tratados cirurgicamente com placas e parafusos. O resultado foi avaliado radiologicamente e funcionalmente pela escala de avaliação do quadril (Harris Hip Score). O período médio de seguimento dos pacientes no pós-operatório foi de 30 meses (24-36 meses).

Palavras-chave:

Acetábulo

Artroplastia, substituição, quadril

Fraturas, osso

Articulação do quadril

[☆] Study conducted at Department of Orthopedics, Sharda University, Greater Noida, India.

E-mail: drrlsahu@gmail.com

<https://doi.org/10.1016/j.rboe.2017.12.007>

2255-4971/© 2017 Sociedade Brasileira de Ortopedia e Traumatologia. Published by Elsevier Editora Ltda. This is an open access article under the CC BY-NC-ND license (<http://creativecommons.org/licenses/by-nc-nd/4.0/>).

Resultados: Os resultados foram excelentes em 60,86%, bons em 21,73%, razoáveis em 8,69% e ruins em 8,69% dos casos. Complicações pós-operatórias da fratura acetabular, tais como ossificação heterotópica, foram encontradas em 2,17% dos casos; osteoartrite, em 6,52%; infecções da pele, em 4,34%; lesões nervosas, em 2,17% e necrose vascular, em 4,34% dos pacientes. Mais de 80% dos pacientes estavam satisfeitos com os resultados da cirurgia.

Conclusão: Os presentes resultados indicam que a fixação interna das fraturas acetabulares conduz a um bom resultado na maioria dos pacientes.

© 2017 Sociedade Brasileira de Ortopedia e Traumatologia. Publicado por Elsevier Editora Ltda. Este é um artigo Open Access sob uma licença CC BY-NC-ND (<http://creativecommons.org/licenses/by-nc-nd/4.0/>).

Introduction

Acetabular fractures are among the most serious injuries treated by orthopedic surgeons. Unfortunately, patients with fractures of the pelvis and/or acetabulum, almost always also experience serious injury to surrounding soft tissue (skin and muscles) and neurovascular structures (nerves, arteries and veins).¹ High-energy trauma is the main cause in younger patients and generally associated with other fractures. Over the age of 35, fractures occur with minimal trauma because of osteoporosis.¹

Majority of acetabular fractures are associated with lower limb fractures due to falls, particularly in older individuals.^{1,2} Incident of posterior wall fractures are 24% of acetabular fractures.³ Acetabular fractures generally occur in conjunction with other fractures which influence management options, surgical approach and clinical outcomes.⁴ There are other factors which may influence treatment options like patient's age, fracture stability, osteoporosis, co morbidity and surgeon's experience. Treatment options are conservative methods (skeletal traction, partial weight bearing), percutaneous fixation, total hip arthroplasty.^{1,2} Surgical fixation is the main treatment.^{1,2} There are certain surgical approaches used for operative management are Iliioinguinal, Kocher-Langenbeck, extended iliofemoral and triradiate approaches or combination of them.^{1,4}

The aim of this study was to evaluate the functional outcome of surgically treated acetabular fractures.

Methods

This prospective study was carried out at Orthopedics department from December 2010 to December 2014. It was approved by institutional medical ethics committee. A total of 46 patients (30 males and 16 females) with acetabulum fracture admitted to our institute were included in the present study. Thirty patients (65.21%) were male and sixteen patients (34.78%) were female (Table 1). 28 cases of acetabular fracture were found on the right side and eighteen cases were seen on the left side. The mean age of patients was 44 years (range: 20–80 years). A written informed consent was obtained from all the patients. Complications were discussed with the patients. They were treated with open reduction and internal fixation with reconstruction plate and screws under general anesthesia. All patients were followed for thirty months.

Table 1 – Age and sex variations in study group (n = 46).

Age (years)	Male	R	L	Female	R	L	Total
20–40	4	2	2	2	1	1	6
41–60	8	5	3	4	3	1	12
>61	18	11	7	10	6	4	28
Total	30	18	12	16	10	6	46

Inclusion criteria

- Age more than 20 years and less than 80 years
- Close fractures
- Posterior wall fractures
- Posterior column fractures
- Anterior column fractures
- Transverse fractures
- Both column fractures.

Exclusion criteria

- Simple fractures
- Open fractures
- Fracture older than 3 weeks.

Following hemodynamic stabilization of the patients, a detailed clinical examination and radiological assessment was done. Patients were kept on upper tibial skeletal pin traction. Patients were operated between three to seven days based on principles of Damage Control Orthopedics. Demographic profiles were recorded. Radiographs (pelvic AP and Judet views) and CT scan with 3D reconstruction were carried out according to the clinical findings. Fractures were classified according to Judet-letournel.⁵ Traumatic hip dislocation was found in 28 patients in total and central dislocation in four. Closed reduction was carried out in patients with posterior dislocation in the emergency room, and then skeletal traction was applied till the operation with a Steinman screw passing through the supracondylar area of the femur. Reduction was performed under general anesthesia in one patient with central dislocation, and then skeletal traction was applied till the operation. The surgical approach was determined according to the fracture type. Iliioinguinal incision was used in 12 patients, iliofemoral incision was used in two patients, and Kocher-Langenbeck was used in 32 patients. Iliioinguinal incision was preferred in anterior column, two-column, and posterior hemi transverse+ anterior column fractures. The indirect method was used to reduce the posterior column in

two-column fractures. The Kocher–Langenbeck incision was used in the posterior wall, posterior wall + posterior column, selected transverse, T-shaped and transverse + posterior column fractures. Triradiate incision was needed for placement in none of the patients. Iliofemoral incision was preferred in 2 transverse fractures. Rigid internal fixation was ensured with plates + screws in 42 patients, and with only screws in 4 patients. The presence of intra-articular free bodies, placement and screws within the joint were evaluated by direct inspection, palpation and intra-operative C-arm fluoroscopy. Placement and quality of the internal fixation was evaluated using the standard anteroposterior and Judet X-rays taken postoperatively. Separation up to 1 mm was accepted as anatomic, between 1 and 3 mm as successful, and separation exceeding 3 mm was accepted as poor reduction. Skeletal traction was applied in two patients during the postoperative two weeks. The other patients were instructed by a physiotherapist during the passive range-of-motion exercises. The patients were instructed to walk using double crutches or walkers without giving weight to the related side, and the weight allowed was increased gradually after the week six. Low molecular-weight heparin was used in the pre- and postoperative periods as a routine prophylaxis against deep venous thrombosis and was continued till the postoperative week six. No prophylaxis for heterotypic ossification was used. Clinical examination and radiological assessment were done and data recorded at admission, 1st post-op day, two weeks, six weeks, three months, six months, 12 months, 18 months, 24 months and 30 months. Later, these were continued with two-year intervals in patients without problems, and with six-month intervals in patients with late complications including osteoarthritis and similar. The mean follow-up period of the patients in the postoperative period was 30 months (24–36 months). Clinical and radiological assessments were made using the criteria of Harris⁶ and Ruesch et al.⁷

Results

There were forty-six patients in this study, 65.21% (30/46) patients were male and 34.78% (16/46) patients were females. 60.86% (28/46) patients had right sided acetabular fractures and 39.13% (18/46) left sided acetabular fractures. The patients were divided in three groups according to their age for simplicity. Young age group included those patients whose age was 20–40 years. In this group there were 4.34% (2/46) females and 8.69% (4/46) males. Middle age group included patients, who were between the ages of 41–60 years. This group included 8.69% (4/46) females and 17.39% (8/46) males. Old age group included patients older than sixty years. This group consisted of 21.73% (10/46) females and 39.13% (Table 1). In 30 (65.21%) patients, mode of injury was road traffic accident and 16 (34.78%) patients had fall from height. On the basis of fracture configuration, posterior wall and posterior column fractures were 73.91%, anterior column fractures 13.04%, transverse 8.69% and both column fractures were 8.69% (Table 2). Table 3 shows the type of acetabular fractures which were dealt with in this study. Twenty-eight patients had dislocation along with posterior wall fracture and four patients had central dislocation. The average time to surgery was 4.15

Table 2 – Frequency distribution of fracture types among study patients (n = 46).

Fracture types	Side involved (%)	
	Right	Left
<i>Elementary fracture</i>		
Posterior wall	12 (21.73)	8 (17.39)
Posterior column	8 (17.39)	4 (8.69)
Anterior column	4 (8.69)	2 (4.34)
Transverse	2 (4.34)	2 (4.34)
<i>Associated fracture</i>		
Both column	2 (4.34)	2 (4.34)

Table 3 – Associated fractures in study patients (n = 46).

Associated fractures	Number (%)
Head	2 (4.34)
Thorax	3 (6.52)
Intraabdominal	3 (6.52)
Genitourinary	4 (8.69)
Vertebra	2 (4.34)
Post-pelvic ring	4 (8.69)
Major vascular	0 (0)
Extremity	8 (17.39)
Neurological	0 (0)

Table 4 – Evaluation of patients' scores according to the Harris criteria (n = 46).

Score	Frequency (%)
Excellent (90–100 points)	28 (60.86)
Good (80–89 points)	10 (21.73)
Fair (70–79 points)	4 (8.69)
Poor (less than 70 points)	4 (8.69)

days. The average post-operative stay was 3.60 days. On the basis of fracture configuration and according to recommendations of Letournel and Judet, different approaches were used: Kocher–Langenbeck 32 (69.56%), ilio-inguinal 12 (26.08%) and Ilio-femoral two (4.34%). Forty-two (91.30%) patients achieved anatomical reduction and four (8.69%) ended up with imperfect reduction. Imperfect reduction at surgery was observed in one posterior wall fracture, one posterior column fracture and two both column fractures. Rigid internal fixation was ensured with plates + screws in 42 (91.30%) patients, and with only screws in 4 (8.69%) patients. The mean follow-up period of the patients in the postoperative period was 30 months (24–36 months). Clinical and radiological assessments were made using the criteria of Harris⁶ and Ruesch et al.⁷ receiving scores from 0 to 100. Their range of motion, pain levels and functional abilities were evaluated, and these results are shown in Table 4. Regarding the patients' degree of satisfaction, it was observed that 60.86% were very satisfied, 30.43% were satisfied and 8.69% were dissatisfied but would still undergo the surgery again. The mean duration of operation was three hours with a range from two hours to five hours. Post-operative complication of acetabular fracture like heterotopic ossification was found in one (2.17%), osteoarthritis three (6.52%), skin infection two (4.34%) nerve lesion one (2.17%) and vascular necrosis in two (4.34%) patients (Table 5). The results were excellent

Table 5 – Post-operative complications of acetabular fractures (n = 46).

Type of complication	Frequency (%)
Vascular lesion	0 (0)
Nerve lesion	1(2.17)
Deep infection	0 (0)
Deep vein thrombosis	0 (0)
Urological complications	0 (0)
Vascular necrosis	2 (4.34)
Osteoarthritis	3 (6.52)
Heterotopic ossification	1 (2.17)
Skin infection	2 (4.34)
Loss of reduction	1 (2.17)

in 60.86% (28/46), good in 21.73% (10/46) patients fair in four (8.69%) and poor in 8.69% (4/46). (Table 4) (Figs. 1–4).

Discussion

Acetabular fractures are challenge for treating surgeons. They need more skills to be handled. They are more complex injuries as compared to other parts of body.⁸ Most acetabular fractures are treated with surgery. Because acetabular fractures damage the cartilage surface of the bone, an important goal of surgery is to restore a smooth, gliding hip surface. The result of the fixation is dependent on many variables such as energy level of the injury, radiographic fracture pattern, surgeon's knowledge of pelvic anatomy, timing of open reduction and internal fixation (ORIF) and appropriate choice of surgical approach.^{9,10} Because of the complex acetabular anatomy, various classification schemes have been suggested, but the Judet-Letournel classification system remains the most widely accepted.¹¹ The main cause of the acetabular injury is a road traffic accident. In 65.21% patients of acetabular fracture,

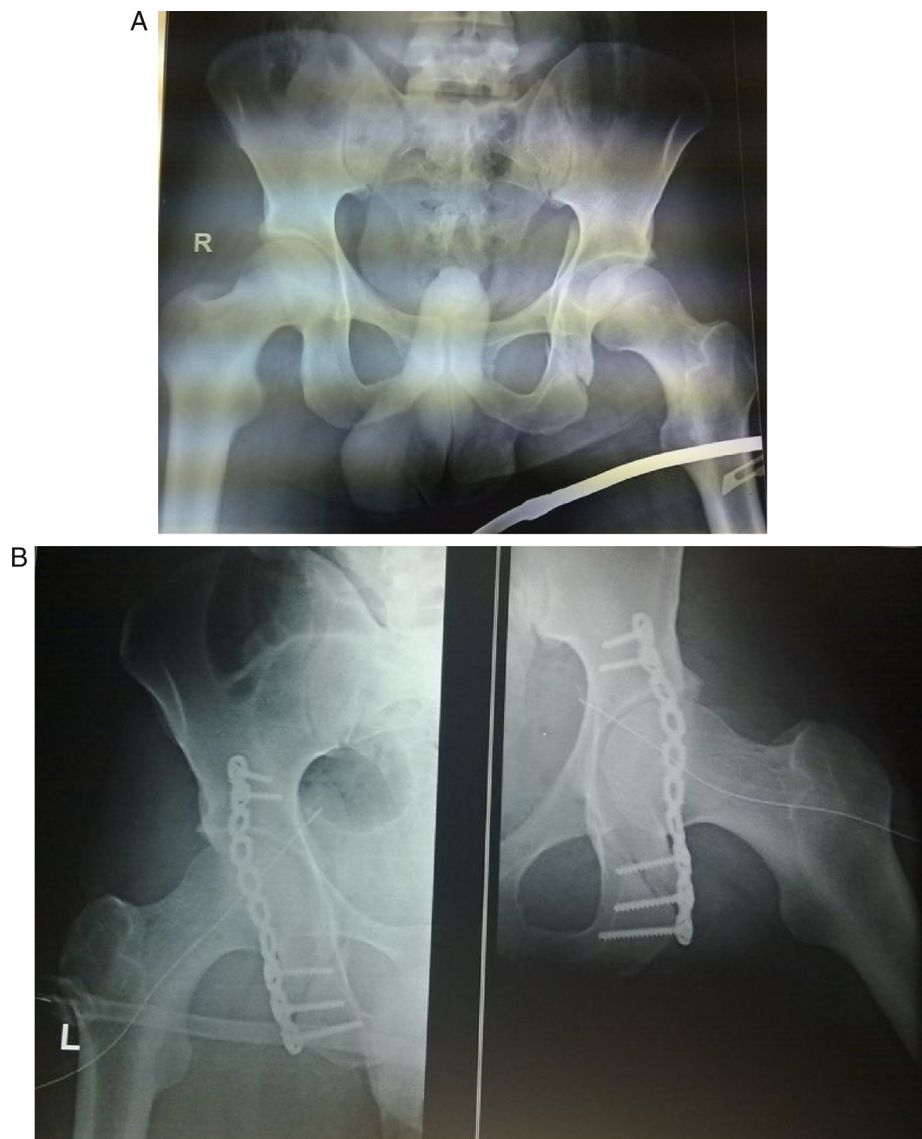


Fig. 1 – (A) Pre-operative AP view of pelvis with both hip showing posterior column/wall fracture of left acetabulum. (B) Post-operative AP view of left hip showing acetabulum fracture fixation with recon plate.

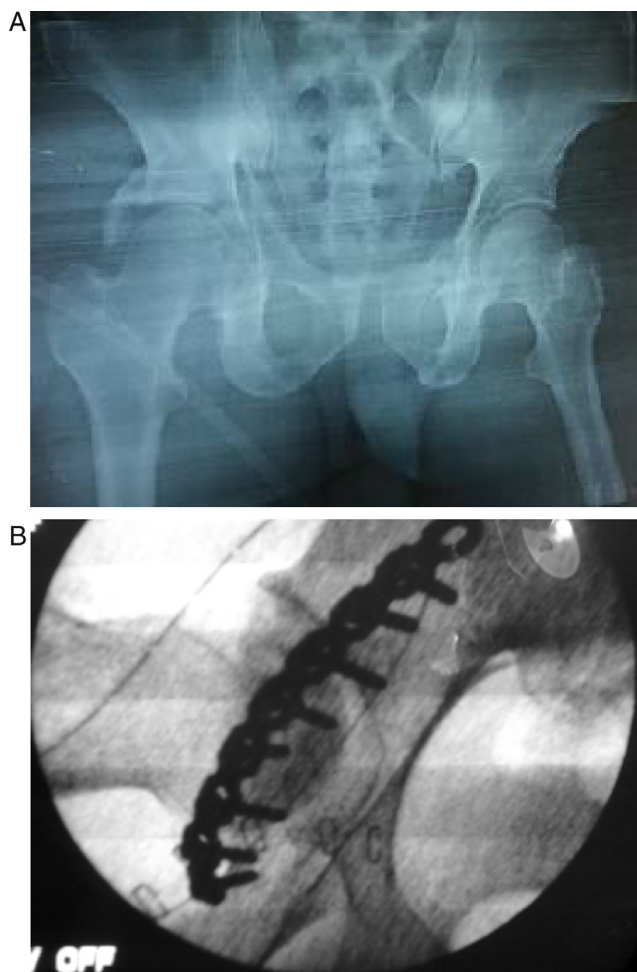


Fig. 2 – (A) Pre-operative AP view of pelvis with both hip showing anterior and posterior hemi transverse fracture of right acetabulum. (B) Post-operative AP view of right hip showing acetabulum fracture fixation with recon plate.

mode of injury was road traffic accident and 34.78% acetabular fracture patients had fall from height. Acetabular injuries happen more frequently to young patients, considerably more to patients of male gender. Giannoudis et al.¹² stated that the average age of patients is 38.6 ± 4.6 years, and 69.4% of patients are of male gender. The average age of patient in our series was 44 years, and there were 65.21% patients of male gender. The most of authors use Judet and Letournel classification of acetabular fractures in their publications. Giannoudis et al.¹² stated that the posterior wall fractures of the acetabulum are most common fractures; they occur in 23.6% cases, based on the meta-analysis of 34 publications, which included 3670 patients. In our series of patients, we had 43.47% fractures of the posterior wall of the acetabulum. The operation should be performed in the first week after injury (from 4 to 6 days). According to Giannoudis et al.¹² 14 publications (1496 patients), the average time of surgery was 8.9 ± 2.9 days. All our patients were operated on between three to seven days after injury (4.15 days on the average). The standard procedure of the preoperative evaluation of the patient includes a clinical examination and Radiographs (pelvic AP and Judet views)

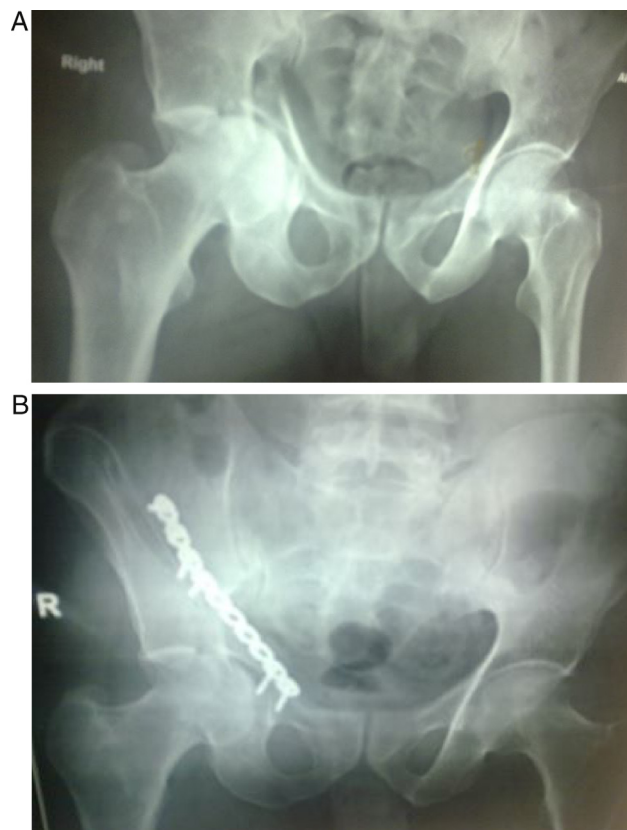

Fig. 3 – (A) Pre-operative AP view of pelvis with both hip showing anterior column/wall fracture of right acetabulum. (B) Post-operative AP view of right hip showing acetabulum fracture fixation with recon plate.

and CT scan with 3D reconstruction. The Kocher–Langenbeck approach is most commonly used, in 48.7% cases, ilio-inguinal in 21.9%, and the iliofemoral in 12.4% cases. In 17% of the patients, other surgical approaches are used including direct lateral, the triradiate, extensive and combined approaches.¹² As regards our series, 69.56% patients were operated on using the Kocher–Langenbeck approach. Most complications following acetabular injury are osteoarthritis, avascular necrosis, non-union and shortening of affected extremity, which may require further reconstructive procedures.¹² The goal of surgery is to achieve a functional and painless hip that would continue to function for the rest of patient's life. This may not always be possible as the high energy trauma may lead to a non-viable articular cartilage. But even if the articular cartilage remains viable after the trauma, altered pressure distribution of femoral head articulating with improperly reduced acetabular fracture will ultimately lead to osteoarthritis. Giannoudis et al.¹² in a 2005 meta-analysis. The metaanalysis showed that following accurate reduction, osteoarthritis incidence was about 10%, which increased to >30% if accurate reduction could not be achieved. We observe that the length of follow-up is critical, and with a longer follow-up arthritis is more likely to develop even in perfectly reduced fractures. In present study, more than 80% had excellent to good radiographic outcome at final follow-up. These results compare favorably with other published outcomes (Table 6).^{7,10,13-20} In our study, 6.52%

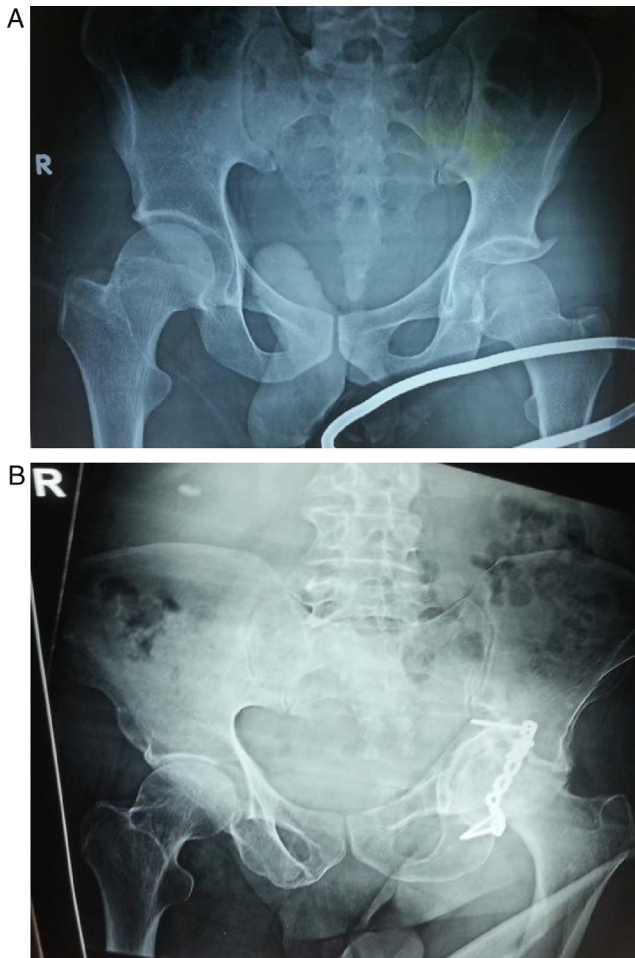


Fig. 4 – (A) Pre-operative AP view of pelvis with both hip showing posterior wall fracture of left acetabulum. (B) Post-operative AP view of left hip showing acetabulum fracture fixation with recon plate.

Table 6 – Comparison of results.

Author(s)	Cases	Mean follow-up	Excellent/good
Bucher ¹³	161	11.3	73
Madhu et al. ¹⁴	237	2.9	76
Deo et al. ¹⁵	74	2.6	74
Fica et al. ¹⁶	84	5.5	68
Rommens et al. ¹⁷	175	2	76
Matta et al. ¹⁸	255	6	76
Mayo ¹⁹	163	3.7	75
Ruesch et al. ²⁰	53	1	83
Brueton ²¹	26	2	61
Qadir Ri et al. ²²	19	1	84
Present study	46	2.5	82.60

patients had osteoarthritis, 4.34% avascular necrosis, 4.34% skin infection, 2.17% heterotopic ossification and 2.17% had loss of reduction. That is more comparable to the other study, because we did not delay in operation and proper post-op care. In our study results showed that more than 80% patients had satisfactory results following acetabular fracture surgery. This finding was within the range that reported in various studies in different countries.²¹ We described the relation

between some demographic and clinical factors with surgical result. Women had significantly lower Harris Hip Score (HHS) after surgery in comparison with men. Although we had few female patients, however, their HHS was obviously lower than men. This inferiority can be partially explained by lower pain threshold in women, which can influence their function and HHS.^{22,23}

Conclusion

Early open anatomical reduction and rigid internal fixation with recon plates in acetabular fractures gives excellent and good results even in delayed and aged patients with osteoporotic bones and the chances of avascular necrosis and osteoarthritis of hip are minimized.

Conflict of interest

The authors declare no conflicts of interest.

REFERENCES

- Kandasamy MS, Duraisamy M, Ganeshsankar K, Kurup VG, Radhakrishnan S. Acetabular fractures: an analysis on clinical outcomes of surgical treatment. *Int J Res Orthop.* 2017;3(1):122-6.
- Munde SL, Bhatti MJ, Siwach RC, Gulia A, Kundu ZS, Bansal S, et al. Double tension band osteosynthesis in inter-condylar humeral fractures. *J Clin Diagn Res.* 2015;9(12):RC08-11.
- Hussain KS, Kancherla NR, Kanugula SK, Patnala C. Analysis of displaced acetabular fractures in adults treated with open reduction and internal fixation. *Int J Res Orthop.* 2016;2(3):99-103.
- Schreiner AJ, de Zwart PM, Stuby FM, Ochs BG. Fraktürendoprothetik des Azetabulums. *Open J.* 2016;32(3):196-205.
- Judet R, Judet J, Letournel E. Fractures of the acetabulum: classification and surgical approaches for open reduction. Preliminary report. *J Bone Joint Surg Am.* 1964;46:1615-46.
- Harris WH. Traumatic arthritis of the hip after dislocation and acetabular fractures: treatment by mold arthroplasty. An end-result study using a new method of result evaluation. *J Bone Joint Surg Am.* 1969;51(4):737-55.
- Ruesch PD, Holdener H, Ciaramitaro M, Mast JW. A prospective study of surgically treated acetabular fractures. *Clin Orthop Relat Res.* 1994;(305):38-46.
- Iqbal F, Taufiq I, Najjad MK, Khan N, Zia OB. Functional and radiological outcome of surgical management of acetabular fractures in tertiary care hospital. *Hip Pelvis.* 2016;28(4):217-24.
- Anizar-Faizi A, Hisam A, Sudhagar KP, Moganadass M, Suresh C. Outcome of surgical treatment for displaced acetabular fractures. *Malays Orthop J.* 2014;8(3):1-6.
- Qadir RI, Bukhari SI. Outcome of operative treatment of acetabular fractures: short term follow-up. *J Ayub Med Coll Abbottabad.* 2015;27(2):287-91.
- Peter RE. Open reduction and internal fixation of osteoporotic acetabular fractures through the ilio-inguinal approach: use of buttress plates to control medial displacement of the quadrilateral surface. *Injury.* 2015;46 Suppl. 1:S2-7.
- Giannoudis PV, Grotz MR, Papakostidis C, Dinopoulos H. Operative treatment of displaced fractures of the acetabulum. A meta-analysis. *J Bone Joint Surg Br.* 2005;87(1):2-9.

13. Briffa N, Pearce R, Hill AM, Bircher M. Outcomes of acetabular fracture fixation with ten years' follow-up. *J Bone Joint Surg Br.* 2011;93(2):229-36.
14. Madhu R, Kotnis R, Al-Mousawi A, Barlow N, Deo S, Worlock P, Willett K. Outcome of surgery for reconstruction of fractures of the acetabulum. The time dependent effect of delay. *J Bone Joint Surg Br.* 2006;88(9):1197-203.
15. Deo SD, Tavares SP, Pandey RK, El-Saied G, Willett KM, Worlock PH. Operative management of acetabular fractures in Oxford. *Injury.* 2001;32(7):581-6.
16. Fica G, Cordova M, Guzman L, Schweitzer D. Open reduction and internal fixation of acetabular fractures. *Int Orthop.* 1998;22(6):348-51.
17. Rommens PM, Broos PL, Vanderschot P. Preparation and technique for surgical treatment of 225 acetabulum fractures 2 year results of 175 cases. *Unfallchirurg.* 1997;100(5):338-48.
18. Matta JM, Mehne DK, Roffi R. Fractures of the acetabulum. Early results of a prospective study. *Clin Orthop Relat Res.* 1986;(205):241-50.
19. Mayo KA. Open reduction and internal fixation of fractures of the acetabulum. Results in 163 fractures. *Clin Orthop Relat Res.* 1994;(305):31-7.
20. Brueton RN. A review of 40 acetabular fractures: the importance of early surgery. *Injury.* 1993;24(3):171-4.
21. Magill P, McGarry J, Queally JM, Morris SF, McElwain JP. Minimum ten-year follow-up of acetabular fracture fixation from the Irish tertiary referral centre. *Injury.* 2012;43(4):500-4.
22. Traub RJ, Ji Y. Sex differences and hormonal modulation of deep tissue pain. *Front Neuroendocrinol.* 2013;34(4):350-66.
23. Etemadifar M, Nemati A, Chinigarzade M. Operative management of acetabular fracture: a 10-year experience in Isfahan Iran. *Adv Biomed Res.* 2016;5:169.