

# Non-Meckel's Small Bowel Diverticular Bleeding: Two Case Reports and a Review of the Literature

Gabriel Mansouraty, MD, and Daniel Wild, MD

*Division of Gastroenterology, Duke University Medical Center*

## ABSTRACT

Gastrointestinal bleeding from non-Meckel's small bowel diverticulosis is uncommon. Depending on the diverticulum's location, a patient's presentation can suggest either an upper or lower gastrointestinal source. We present two cases of bleeding from non-Meckel's small bowel diverticula. One patient was managed successfully with endoscopic therapy, and the second required surgical resection after two failed attempts at achieving hemostasis endoscopically.

## INTRODUCTION

Non-Meckel's small bowel diverticulosis is uncommon and usually asymptomatic; however, hemorrhage is a recognized complication. When bleeding occurs, the management can be challenging depending on the location of the bleeding diverticulum; therefore a multi-modality approach is often required.

## CASE REPORT

**Case 1:** A 92-year-old woman was transferred for management of overt gastrointestinal (GI) bleeding. She was admitted to her local hospital for syncope and hematochezia. She was not on anticoagulation or antiplatelet agents. Her hemoglobin decreased from a baseline of 12 g/dL to 9.5 g/dL. Esophagogastroduodenoscopy (EGD) was unremarkable, showing neither bleeding nor a bleeding source. Colonoscopy showed old blood in the colon and sigmoid diverticulosis, which was thought to be the source. No therapeutic interventions were performed. She remained clinically stable until hospital day 3, when she had recurrent hematochezia. Red blood cell scintigraphy suggested possible bleeding in the left upper quadrant and left lower quadrant, prompting transfer to our hospital for further management.

On arrival, she was tachycardic with a stable blood pressure. Rectal exam showed maroon stool. Her initial hemoglobin was 9.2 g/dL, and blood urea nitrogen was 36 mg/dL. She had hematochezia associated with hemodynamic compromise on the evening of transfer. Emergent angiography demonstrated no active bleeding from the inferior or superior mesenteric artery distributions. She stabilized and remained monitored.

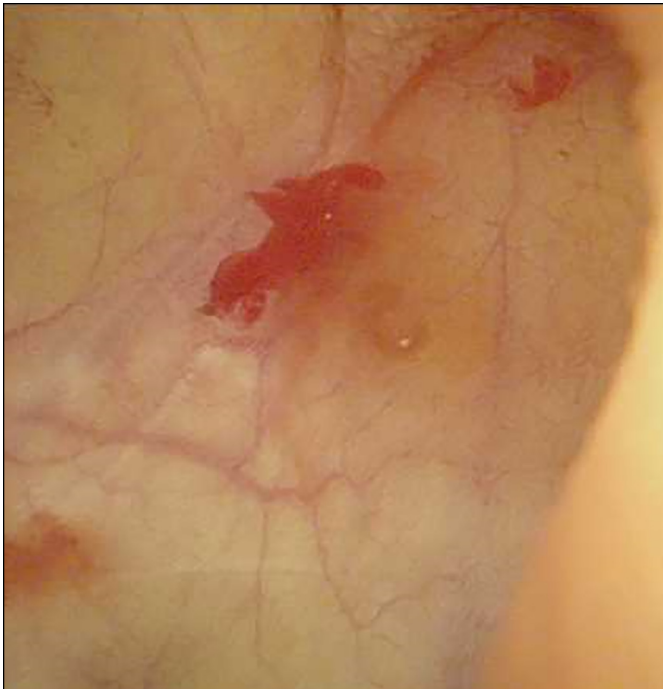On hospital day 4, she had hematemesis with maroon-colored clots associated with hemodynamic compromise. Repeat upper endoscopy revealed a small amount of fresh red blood and clot in the gastric body, a non-bleeding superficial clean-based duodenal ulcer without stigmata, and fresh red blood with clot in the third part of the duodenum. Push enteroscopy revealed several diverticula in the proximal jejunum, one of which was actively bleeding (Figure 1). We achieved hemostasis by placing two hemostatic clips across the base of the diverticulum (Figure 2). As an additional precaution, the base of the diverticulum was injected with 5 mL 1:10,000 solution of epinephrine, and a tattoo was placed to mark the site. She did not bleed again and was successfully discharged on hospital day 7.

ACG Case Rep J 2016;3(4):e177. doi:10.14309/crj.2016.150. Published online: December 7, 2016.

**Correspondence:** Gabriel Mansouraty, Division of Gastroenterology, Duke University Medical Center, Box 3913, Durham, NC 27710 (gabriel.mansouraty@dm.duke.edu)

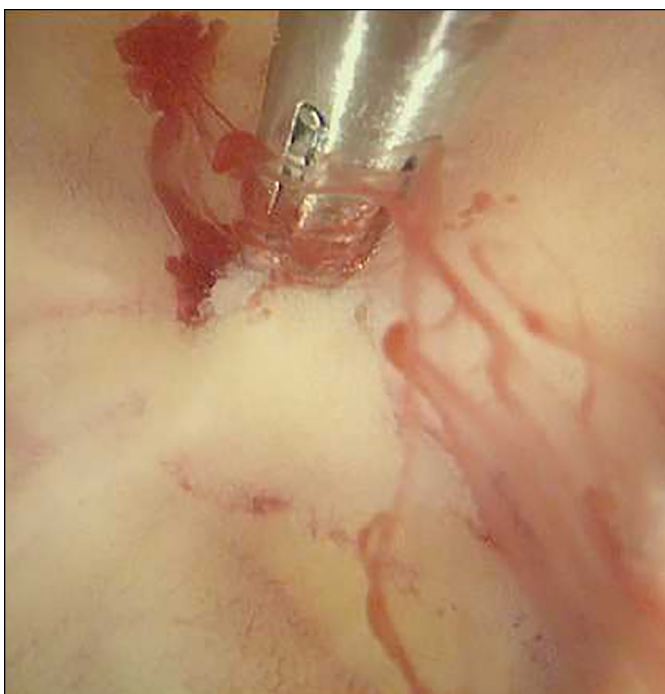

Copyright: © 2016 Mansouraty et al. This work is licensed under a Creative Commons Attribution-NonCommercial-NoDerivatives 4.0 International License. To view a copy of this license, visit <http://creativecommons.org/licenses/by-nc-nd/4.0>.

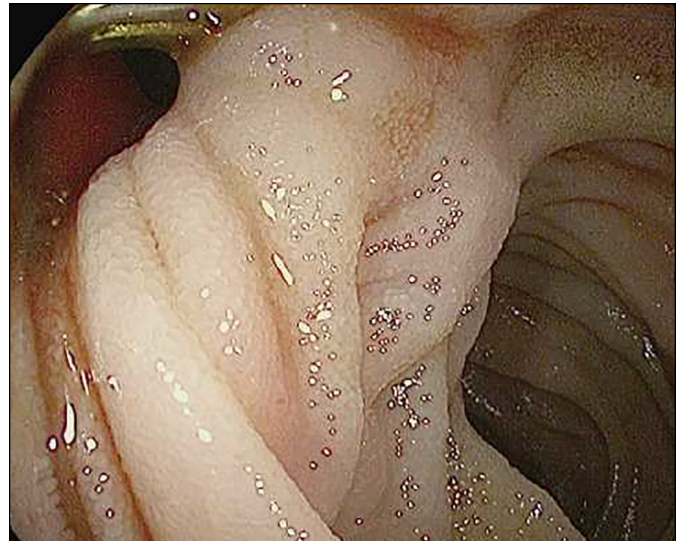


**Figure 1.** Push enteroscopy showing an actively bleeding diverticula in the proximal jejunum.

**Case 2:** A 67-year-old woman was admitted to our hospital for pre-syncope, abdominal pain, and melena. She had been taking high doses of aspirin for several weeks prior to this admission. A few days prior to admission, she developed



**Figure 2.** Clip at base of bleeding jejunal diverticulum.

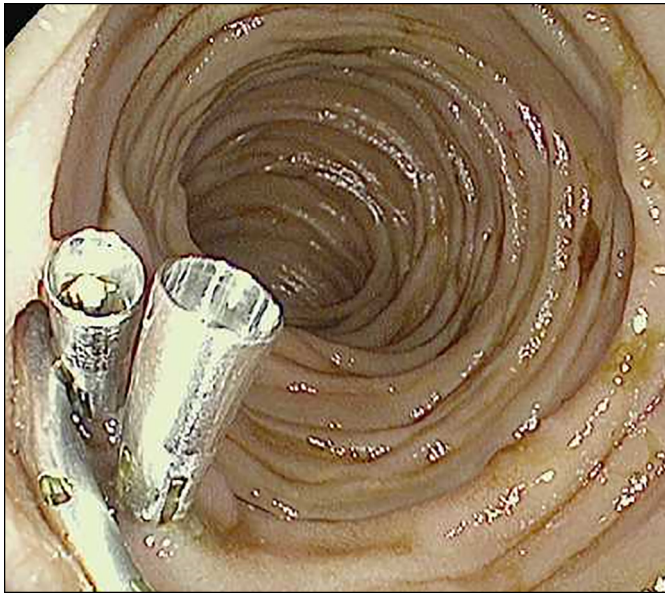


**Figure 3.** Active bleeding within duodenal diverticulum.

epigastric pain and then presented with melena for further evaluation. On arrival, she was tachycardic with a normal blood pressure and hemoglobin 10.0 g/dL. A proton pump inhibitor infusion was initiated. On hospital day 2, she passed maroon stool and her hemoglobin dropped to 6.6 g/dL. EGD showed a normal esophagus, one non-bleeding superficial gastric ulcer without stigmata on the greater curvature of the stomach, and fresh red blood throughout all segments of her duodenum. Further inspection revealed an actively bleeding diverticulum in the fourth portion of the duodenum (Figure 3). Two hemostatic clips were placed, but hemostasis was not achieved with this maneuver. Planned angiography was delayed by a contrast allergy that necessitated a steroid preparation. When performed, active bleeding was not evident and embolization was not pursued.

She remained clinically stable until hospital day 4, when she passed hematochezia and became hemodynamically unstable. Small bowel enteroscopy identified several distal duodenal diverticula. One of these was actively oozing around the previously placed clips. Three additional hemostatic clips were placed (Figure 4). The area was also injected with 4 mL 1:10,000 solution of epinephrine. These maneuvers achieved temporary hemostasis, and the area was tattooed.

The patient was stable until hospital day 7, when she again developed hematochezia. Red blood cell scintigraphy was negative, but her hemoglobin dropped even with transfusion. On hospital day 8, she underwent laparotomy with resection of 40 cm of small bowel directed by the tattoo. Pathology showed normal small bowel mucosa with diverticulosis. She had an uneventful postoperative course and was discharged on hospital day 14.



**Figure 4.** Additional clips placed across the oozing diverticulum.

## DISCUSSION

Non-Meckel's small bowel diverticulosis is uncommon and is usually discovered incidentally during endoscopic or radiographic evaluation.<sup>1</sup> The incidence of duodenal diverticulosis ranges from 6–22%, and the majority (75%) are found within 2 cm of the ampulla.<sup>2</sup> Diverticulosis is found less frequently in the jejunum and ileum, occurring in 0.3–1.3% of patients, though these lower rates are likely to reflect the fact that these segments of small bowel are less frequently visualized during routine endoscopic and radiographic evaluation.<sup>1,3–6</sup> Of small bowel diverticula that occur distal to the duodenum, 80% are in the jejunum, 15% in the ileum, and 5% involve both the jejunum and ileum.<sup>2,7,8</sup> Of patients who have jejunoileal diverticula, 35% of them have concomitant colonic diverticulosis.<sup>5</sup>

Approximately 90% of duodenal diverticula are asymptomatic. There is some evidence to suggest that periampullary diverticula can increase the risk of cholangitis.<sup>9</sup> By contrast, up to 60% of non-Meckel's jejunoileal diverticula may cause symptoms including small intestinal bacterial overgrowth, obstruction secondary to volvulus or enterolith impaction, diverticulitis, and abdominal pain.<sup>7,10,11</sup> Hemorrhage, as was seen in our patients, is described in 3–8% of patients with non-Meckel's jejunoileal diverticulosis.<sup>12,13</sup>

Only 60 cases of jejunoileal diverticular bleeding were reported prior to 1992. With widespread adoption of video capsule and deep enteroscopy, more cases have been noted since 1992. In a retrospective study from 8 Taiwanese centers spanning 2004–2010, non-Meckel's small bowel diverticular bleeding was seen in 8% of patients who underwent double-

balloon enteroscopy to evaluate obscure bleeding.<sup>14</sup> Initial hemostasis was achieved with endoscopic therapy in 86% of patients, but, as was seen in our second patient, re-bleeding was common (recurring in 20% of patients).

We recommend endoscopic therapy as the initial approach if the bleeding diverticulum can be accessed with the available endoscopic equipment. If hemostasis cannot be achieved with one or two endoscopic sessions, we recommend pursuing alternate modalities. Angiography with embolization targeted to the vessels supplying the culprit segment of small bowel is an option in patients with normal renal function. Although surgical resection of the culprit area is definitive and our patient did well with this intervention, it is invasive and potentially morbid.

## DISCLOSURES

Author contributions: G. Mansouraty wrote the manuscript, reviewed the literature, and is the article guarantor. D. Wild critically revised the manuscript.

Financial disclosure: None to report.

Informed consent was obtained for this case report.

Received April 26, 2016; Accepted August 8, 2016

## REFERENCES

- De Peuter B, Box I, Vanheste R, Dymarkowski S. Small-bowel diverticulosis: Imaging findings and review of three cases. *Gastroenterol Res Pract*. 2009;2009:1–3.
- Feldman M, Friedman LS, Brandt LJ. Diverticulae of the pharynx, esophagus, stomach, and small intestine. In: *Sleisenger and Fordtran's Gastrointestinal and Liver Disease*, 10th ed. 2016, Philadelphia, PA: Saunders/Elsevier; 2016: 397–406.
- Baskin RH Jr., Mayo CW. Jejunal diverticulosis: A clinical study of 87 cases. *Surg Clin North Am*. 1952;4:1185–96.
- Carey EJ, Fleischer DE. Investigation of the small bowel in gastrointestinal bleeding: Enteroscopy and capsule endoscopy. *Gastroenterol Clin North Am*. 2005;34(4):719–34.
- Forcione DG, Alam HB, Kalva SP, Misraji J. Case records of the Massachusetts General Hospital. Case 9-2009: An 81-year-old man with massive rectal bleeding. *N Engl J Med*. 2009;360(12):1239–48.
- Hazzan D, Reissman P, Meshulam J, Golijanin D, Shiloni E. Small-bowel diverticulosis: A potential source of recurrent gastrointestinal bleeding. Report of a case and review of the literature. *Scand J Gastroenterol*. 1998;33(12):1321–3.
- Afridi SA, Fichtenbaum CJ, Taubin H. Review of duodenal diverticula. *Am J Gastroenterol*. 1991;86(8):935–8.
- Yang CW, Chen YY, Yen HH, Soon MS. Successful double balloon enteroscopy treatment for bleeding jejunal diverticulum: A case report and review of the literature. *J Laparoendosc Adv Surg Tech A*. 2009;19(5):637–40.
- Karayianakis AJ, Bolanaki H, Courcousakis N, et al. Common bile duct obstruction secondary to a periampullary diverticulum. *Case Rep Gastroenterol*. 2012;6(2):523–9.
- Akhrass R, Yaffe MB, Fischer C, Ponsky J, Shuck JM. Small-bowel diverticulosis: Perceptions and reality. *J Am Coll Surg*. 1997;184(4):383–8.
- Ferreira-Aparicio FE, Gutiérrez-Vega R, Gálvez-Molina Y, Ontiveros-Navares P, Athie-Gutiérrez C, Montalvo-Javé EE. Diverticular disease of the small bowel. *Case Rep Gastroenterol*. 2012;6(3):668–76.

12. de Bree E, Grammatikakis J, Christodoulakis J, Tsiftsis D. The clinical significance of acquired jejunoileal diverticula. *Am J Gastroenterol*. 1998;93(12):2523-8.
13. Yen HH, Chen YY, Yang CW, Soon MS. Diagnosis and management of jejunoileal diverticular hemorrhage: A decade of experience. *J Dig Dis*. 2012;13(6):316-20.
14. Chen YY, Chiu CT, Hsu CM, et al. Enteroscopic diagnosis and management of small bowel diverticular hemorrhage: A multicenter report from the Taiwan Association for the Study of Small Intestinal Diseases. *Gastroenterol Res Pract*. 2015;2015:1-4.