

OPEN ACCESS

Full open access to this and thousands of other papers at <http://www.la-press.com>.

A Case of Left Main Coronary Artery Disease in an Octogenarian Treated Surgically and Complicated by Myocardial Infarction: Decisions, Techniques, Rescue and Final Outcome

Antoine Kossaify¹ and Gilles Grollier²

¹USEK-NDS University Hospital, Department of Cardiology, St. Charbel Street, Byblos, Jbeil, Lebanon.

²UH-Caen University Hospital, Department of Cardiology, Cote de Nacre, Caen, France.

Corresponding author email: antoinekossaify@yahoo.com

Abstract: We report on an octogenarian patient presenting with an acute coronary syndrome due to significant left main coronary artery disease and severe ostial stenosis of the left anterior descending artery disease. Emergent bypass graft performed with “beating heart” consisted of left internal mammary graft to the mid left anterior descending artery with an “over-stent” anastomosis. The immediate post-operative phase was simple, however the patient presented on post-operative day 8 with extensive anterior myocardial infarction and cardiogenic shock. Emergent coronary angiogram showed subocclusive anastomotic stenosis. Percutaneous coronary intervention was performed on left main, proximal left anterior descending, and proximal circumflex arteries. Subsequently, the patient restored a satisfactory hemodynamic condition. A focus on the importance of decision for management of left main disease especially in octogenarian is presented, along with a review of the pertinent literature.

Keywords: acute coronary syndrome, left main disease, cardiogenic shock, rescue, octogenarian, over-stent-anastomosis

Clinical Medicine Insights: Case Reports 2013;6 61–65

doi: [10.4137/CCRep.S11542](https://doi.org/10.4137/CCRep.S11542)

This article is available from <http://www.la-press.com>.

© the author(s), publisher and licensee Libertas Academica Ltd.

This is an open access article published under the Creative Commons CC-BY-NC 3.0 license.

Introduction

Severe left main coronary artery (LMCA) disease is a critical condition and it requires prompt management when it manifests in the setting of acute coronary syndrome (ACS). Interventional management with percutaneous coronary intervention (PCI) or coronary artery bypass graft (CABG) is mandatory in this setting. Both approaches (PCI and CABG) are feasible and many factors intervene in the decisional algorithm, mainly the immediate risks and the long-term major adverse cardiac events, these risks and events are considerable both in the elderly and when the procedure of revascularization is performed urgently. We present a case of ACS in an octogenarian male patient related to LMCA disease along with severe ostial left anterior descending (LAD) artery stenosis, emergent CABG consisted of a single graft of left internal mammary artery on LAD, the procedure was complicated by graft closure with subsequent acute anterior myocardial infarction and cardiogenic shock. PCI was delayed 18 hours because of an unstable hemodynamic condition; nevertheless it was successful and allowed to rescue the patient.

Case Presentation

An 84-year-old patient presented with unstable angina. His physical examination was unremarkable, surface electrocardiogram showed sinus rhythm, left bundle branch block, and non specific ST/T changes difficult to analyze due to the branch block. The patient had an aortic valve bioprosthesis implanted 5 years ago, he also had PCI realized 3 years ago and consisting of 2 long contiguous stents (drug eluted stents) in proximal and mid LAD artery, and another stent in proximal circumflex artery. He was treated with Clopidogrel and Aspirin. Of note, the patient had a relatively preserved systolic function with an ejection fraction estimated at 65% and a creatinine clearance of 51 mL/min, as well as a preserved functional capacity.

Coronary angiogram showed a significant LMCA disease with a diffuse narrowing estimated at 70%, a severe subocclusive ostial (>95%) LAD stenosis proximal to the stent (TIMI-1 flow), mild LAD intrastent narrowing and moderate (65%–75%) proximal circumflex artery disease with intrastent narrowing but patent stent. In addition, there was a moderate lesion on mid right coronary and severe stenosis on distal right coronary artery (Fig. 1). The coronary

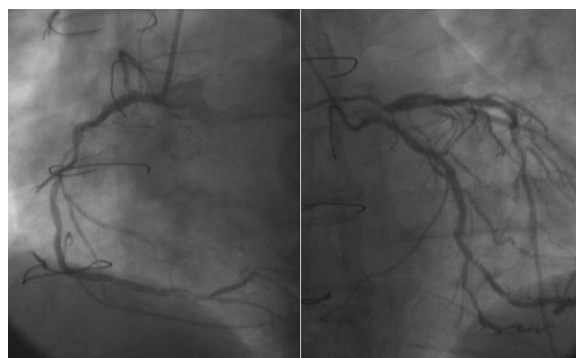


Figure 1. Coronary angiogram showing LMCA disease with severe ostial LAD stenosis and moderate proximal circumflex disease.

distribution showed a left dominance, there was minimal tortuosity, mild diffuse calcification, and no intraluminal thrombus visible.

A decision to perform emergent CABG was made. A single graft with “beating heart” was performed consisting of left internal mammary graft to mid left anterior descending artery with an “over-stent” anastomosis. It was also decided that a PCI be performed on the left circumflex afterward. Performing an extracorporeal circulation for a complete revascularization was estimated at high risk. Additionally the operator estimated that anastomosis on the distal LAD beyond the distal stent would be of little benefit and of high risk of restenosis given the small distal caliber of LAD. The immediate follow up was simple and without any incident. However, on post-operative day 8 the patient presented a syncope with abrupt and persistent poor hemodynamic status, history taking was difficult (subconscious), electrocardiogram was roughly unchanged compared to the last tracing, and cardiac biomarkers showed borderline values. Cardiac echogram showed severe left ventricular anterior hypokinesis, ejection fraction at 30%, and emergent coronary angiogram revealed a subocclusive stenosis of the left internal mammary at the anastomotic site (Fig. 2). The procedure was complicated by cardiorespiratory arrest requiring “on-table” resuscitation, with placement of a temporary pacer and artificial ventilation. At this stage, systolic blood pressure was at 50 mm Hg, serum creatinine at 1.9 mg/dL, and it was decided that a PCI be performed after stabilization of the hemodynamic condition.

Along with supportive measure and positive inotropic drugs, an intra aortic balloon was placed and it allowed a restoration of a satisfactory hemodynamic

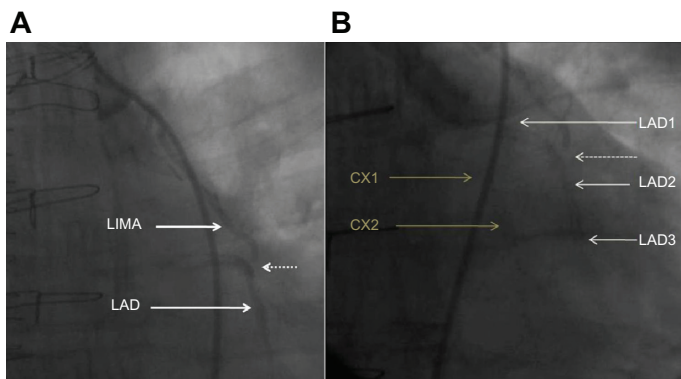


Figure 2. **A**) Subocclusive stenosis at the anastomotic site (showed with dotted arrow); LIMA, left internal mammary artery; LAD, left anterior descending artery. **B**) a “post-injection” view showing the frame of the 2 stents in the LAD (LAD1: pre-anastomotic; LAD2: post-anastomotic; LAD3: distal part of the stent) and the stent in the Circumflex (Cx1, Cx2), with an obvious “over-stent” subocclusive stenotic anastomosis (dotted arrow).

condition with blood pressure at 90/60 mm Hg, and an acceptable diuresis of 35–40 cc/hour. PCI was delayed due to the critical hemodynamic status, nevertheless it was successfully performed 18 hours later. It consisted of LMCA, proximal LAD, and proximal circumflex angioplasty/stenting (Fig. 3) using T-stenting technique (Everolimus drug eluting stents) with end kissing balloon angioplasty. Over the next 48 hours, the patient’s hemodynamic condition progressively improved and stabilized, positive inotropic drugs were progressively withdrawn, intra aortic balloon was removed, and the patient

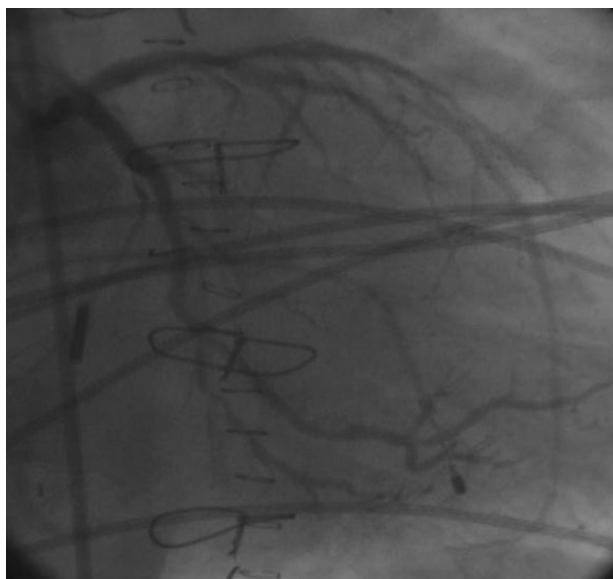

Figure 3. PCI of LMCA, proximal LAD and proximal circumflex.

restored a normal consciousness with normal sinus rhythm and spontaneous respiration. CPK (Creatine phosphokinase) peaked at 2200 IU/L on day 2, cardiac echogram showed severe mid-septal and septo-apical hypokinesia with ejection fraction estimated at 40% (Teicholtz), BNP (brain natriuretic peptide) at day 7 was at 1810 pg/mL. The patient condition continued to improve and he was discharged for a cardiac rehabilitation program with dual antiplatelet therapy (Ticagrelor and Aspirin).

Discussion

The first issue to discuss in this case is whether the decision of CABG compared to PCI was justified, next we will discuss the surgical technique. The patient risks can be evaluated taking into account the clinical and the angiographical data. In this patient, TIMI score¹ (ACS) was estimated at 4, yielding a 19.9% events rate with medical therapy within 14 days (all-cause mortality, new or recurrent myocardial infarction, or severe recurrent ischemia requiring urgent revascularization). Syntax score and clinical Syntax score evaluate the risk of PCI, including major adverse cardiac events rates at 1- and 5-year follow-up (all-cause mortality, cardiac death, myocardial infarction and target vessel revascularization).² In addition, Syntax and clinical Syntax scores are used to evaluate risks of PCI of unprotected LMCA in patients receiving drug-eluting stents.^{3,4}

In this patient, the Syntax-score was estimated at 30, yielding a 23%–32% rate of major cardiac events. Additionally, Clinical Syntax-score was estimated in the highest tertile. The Syntax score is purely anatomical and is notably significant in this patient with left main disease and with a bifurcation lesion type Medina (1,1,1). Other risk score for PCI is the Mayo Clinic risk score,⁵ it yields the risk of procedural death and major adverse cardiac events, and it is based on 7 variables (age, myocardial infarction < 24 hours, preprocedural hemodynamic shock, serum creatinine level, left ventricular ejection fraction, congestive heart failure, and peripheral artery disease). Surgical risk assessment with EuroSCORE II⁶ in this patient yields a 10.03% perioperative mortality risk. At day 8 and after the occurrence of the complication, the patient’s condition changed and EuroSCORE II yielded a 73.89% perioperative mortality risk due mainly to the low ejection fraction, lower creatinine



clearance, recent or ongoing myocardial infarction, critical pre-operative state, and recent cardiac surgery.

Recent literature showed a comparable outcome between PCI and CABG in patients with LMCA disease, though target vessel revascularization is lower in the CABG group; Chieffo et al⁷ reported that treatment of unprotected LMCA disease with PCI showed similar long-term mortality as compared to CABG, however, PCI (even with drug-eluting stents) was associated with higher rates of repeated revascularization. Park et al⁸ found, after 5 years of follow up, an advantage of elective PCI in the composite end point (death, myocardial infarction, stroke) and concluded that PCI of unprotected LMCA with drug-eluting stents is an acceptable alternative to CABG especially in non-diabetic patients and this conclusion was also supported by other studies.^{9,10} Similarly, Dahdouh et al¹¹ showed that PCI is a possible alternative in octogenarian population with a mean EuroSCORE of 21.1 ± 16.7 and mean Syntax score of 28.6 ± 8.7 .

In this patient, the LAD artery was previously stented with two long contiguous stents starting almost 3 mm after the ostium till to the distal 1/3. We hypothesize that ostial stenosis of LAD was probably enhanced by inappropriate positioning of the proximal stent that did not cover the ostium. Surgical anastomosis was theoretically feasible but with little benefit in the distal segment of the LAD in a “stent-free zone.” Moreover, we estimate that performing a graft on the very proximal segment of LAD, also in the “stent-free zone” is ideal in this case and would have resulted in a better outcome. Performing an “over-stent” coronary anastomosis is not a recognized technique, and, to the best of our knowledge, it is not reported in the literature. The history of this patient is a living proof that this technique is disappointing. Accordingly, we estimate that the early complication of CABG should be regarded as a “usual” consequence of an “unusual” procedural technique rather than a simple unfortunate complication. In the future, and with the potential success and common use of the totally biodegradable stents, performing anastomosis over the “stent-trace” could be a promising and feasible technique. Another promising approach is hybrid revascularization;¹² the natural history of

this patient was a “hybrid-like” revascularization performed in two different sessions and after failure of the graft.

In the light of these risk scores along with data from recent literature, knowing the patient anatomy and from a retrospective point of view, we estimate that CABG is a good choice provided that an adequate technique is implemented. Also we hypothesize that PCI in this non diabetic patient could have been a good choice initially especially with the surgical technical difficulties. In fact, the clinical history of this patient represents a spontaneous “cross-over-like” between CABG and PCI. In order to decide the best approach between medical, PCI, or CABG, the attending team should take into consideration the guideline recommendations, the individualized patient settings, and available operative technique for a better outcome and less risk.

Conclusion

PCI of LMCA disease should be regarded as a possible alternative to CABG—even in an octogenarian—when the surgical risk is estimated significant, and/or when the technique is expected difficult. Performing an “over-stent” anastomosis is hazardous and is not a recognized technique. With the recent advent of the totally biodegradable stents, anastomosis “over-stent-trace” could be a promising technique.

Acknowledgment

The authors would like to thank Oren Shlechts for editorial assistance.

Author Contributions

Conceived and designed the experiments: AK, GG. Analyzed the data: AK, GG. Wrote the first draft of the manuscript: AK, GG. Contributed to the writing of the manuscript: AK, GG. Agree with manuscript results and conclusions: AK, GG. Jointly developed the structure and arguments for the paper: AK, GG. Made critical revisions and approved final version: AK, GG. All authors reviewed and approved of the final manuscript.

Funding

Author(s) disclose no funding sources.



Competing Interests

Author(s) disclose no potential conflicts of interest.

Disclosures and Ethics

As a requirement of publication the authors have provided signed confirmation of their compliance with ethical and legal obligations including but not limited to compliance with ICMJE authorship and competing interests guidelines, that the article is neither under consideration for publication nor published elsewhere, of their compliance with legal and ethical guidelines concerning human and animal research participants (if applicable), and that permission has been obtained for reproduction of any copyrighted material. This article was subject to blind, independent, expert peer review. The reviewers reported no competing interests.

References

1. Antman EM, Cohen M, Bernink PJ, et al. The TIMI risk score for unstable angina/non-ST elevation MI: A method for prognostication and therapeutic decision making. *JAMA*. 2000;284(7):835–42.
2. Girasis C, Garg S, Räber L, et al. SYNTAX score and Clinical SYNTAX score as predictors of very long-term clinical outcomes in patients undergoing percutaneous coronary interventions: a substudy of SIRolimus-eluting stent compared with pacliTAXel-eluting stent for coronary revascularization (SIRTAX) trial. *Eur Heart J*. 2011;32(24):3115–27.
3. Jou YL, Lu TM, Chen YH, et al. Comparison of the predictive value of EuroSCORE, SYNTAX score, and clinical SYNTAX score for outcomes of patients undergoing percutaneous coronary intervention for unprotected left main coronary artery disease. *Catheter Cardiovasc Interv*. 2012;80(2):222–30.
4. Garg S, Sarno G, Garcia-Garcia HM, et al. A new tool for the risk stratification of patients with complex coronary artery disease: the Clinical SYNTAX Score. *Circ Cardiovasc Interv*. 2010;3(4):317–26.
5. Singh M, Rihal CS, Lennon RJ, Spertus J, Rumsfeld JS, Holmes DR Jr. Bedside estimation of risk from percutaneous coronary intervention: the new Mayo Clinic risk scores. *Mayo Clin Proc*. 2007;82(6):701–8.
6. Noyez L, Kievit PC, van Swieten HA, de Boer MJ. Cardiac operative risk evaluation: The EuroSCORE II, does it make a real difference? *Neth Heart J*. 2012;20(12):494–8.
7. Chieffo A, Magni V, Latib A, et al. 5-year outcomes following percutaneous coronary intervention with drug-eluting stent implantation versus coronary artery bypass graft for unprotected left main coronary artery lesions the Milan experience. *JACC Cardiovasc Interv*. 2010;3(6):595–601.
8. Park DW, Kim YH, Yun SC, et al. Long-term outcomes after stenting versus coronary artery bypass grafting for unprotected left main coronary artery disease: 10-year results of bare-metal stents and 5-year results of drug-eluting stents from the ASAN-MAIN (ASAN Medical Center-Left MAIN Revascularization) Registry. *J Am Coll Cardiol*. 2010;56(17):1366–75.
9. Luo Y, Yu X, Chen F, et al. Impact of diabetes mellitus on patients with unprotected left main coronary artery lesion disease treated with either percutaneous coronary intervention or coronary-artery bypass grafting. *Coron Artery Dis*. 2012;23(5):322–9.
10. Lee MS, Yang T, Dhoot J, Liao H. Meta-analysis of clinical studies comparing coronary artery bypass grafting with percutaneous coronary intervention and drug-eluting stents in patients with unprotected left main coronary artery narrowings. *Am J Cardiol*. 2010;105(8):1070–5.
11. Dahdouh Z, Roule V, Sabatier R, et al. Left main coronary stenting in a non surgical octogenarian population: a possible approach. *Cardiovasc Revasc Med*. 2012;13(2):119–24.
12. Harjai KJ, Samy S, Pennypacker B, et al. Developing a new hybrid revascularization program: a road map for hospital managers and physician leaders. *J Interv Cardiol*. 2012;25(6):557–64.