

# Myxopapillary ependymoma masquerading as subcutaneous sacrococcygeal non-healing ulcer: case report

Shaesta Naseem Zaidi, Hisham AlKhalidi, Ammar Cherkees Al-Rikabi

From the Department of Pathology, King Khalid University Hospital, Riyadh, Saudi Arabia

Correspondence: Shaesta Naseem Zaidi · Department of Pathology, King Khalid University Hospital, PO Box 2925, Riyadh 11461, Saudi Arabia · T: 0096614671658 F: 0096614672462 · snz24@yahoo.com

Ann Saudi Med 2014; 34(3): 262-264

DOI: 10.5144/0256-4947.2014.262

Ependymomas outside the confines of the cranium and spinal cord are rare. The occurrence of these tumors in an extradural, sacrococcygeal, or subcutaneous location may prove challenging, particularly in the absence of any obvious central nervous system connection. The origin of these tumors from subcutaneous sacrococcygeal ependymal rests is postulated on the basis of earlier reports. We describe 1 such rare extradural case of myxopapillary ependymoma in a 30-year-old female, which presented as a non-healing ulcer in the left gluteal area. It was initially diagnosed and was being treated as an infected epidermoid cyst. Clinical and histopathological features are described, and a brief review of published reports is presented.

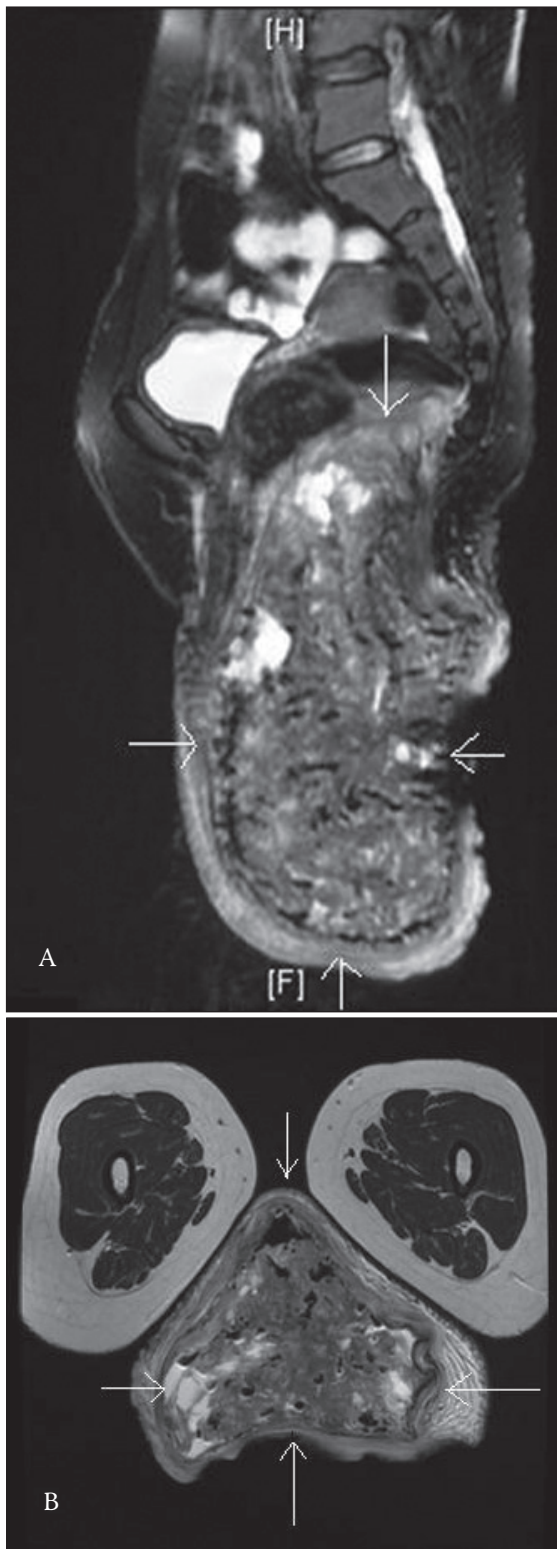**M**yxopapillary ependymoma (ME) is a distinctive variant of ependymoma that was first described as a separate pathological entity by Kernohan JW in 1932.<sup>1</sup> It is a low-grade intradural tumor of ependymal origin that typically occurs in the conus medullaris and filum terminale of the spinal cord. It is considered grade I of IV (WHO) at these sites. In rare instances, ME may occur as a primary lesion in the extraspinal soft tissues. About 50 cases of ependymoma in extraspinal locations have been reported in published reports.<sup>2</sup> We report a case of primary subcutaneous sacrococcygeal ME that presented as non-healing gluteal ulcer.

## CASE

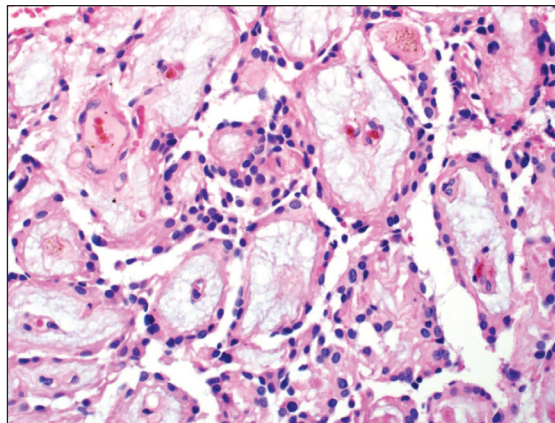
A 30-year-old single female started to complain 2 years back about a small non-painful mass at the left gluteal area with no discharge. It became bigger in size with time till it reached the size of 10×10 cm mass and started causing blackness of the skin. Gradually, it became painful with discharging pus. No history of neurologic involvement was reported. The patient went to a local hospital where excision biopsy of the mass was performed. Microscopy showed granulation tissue, neutrophilic exudates, and nests of reactive squamous cells

and keratinous debris. The diagnosis of ruptured epidermoid cyst was rendered. The pus was cultured, which showed *Escherichia coli* overgrowth, and the patient was prescribed Tazocin. When the patient had no improvement in her condition after 2 weeks, magnetic resonance imaging (MRI) was performed, which revealed a well-defined multiloculated cystic mass lesion arising from the precoccygeal retrorectal space and extending to the perineum (**Figures 1a and b**). Based on the location, multicystic nature of the lesion, and the huge size, the provisional radiological diagnosis of sacrococcygeal teratoma with malignant transformation and superadded infection was made. The patient was referred to our hospital for the surgery. Intraoperatively, the mass was seen near the tip of the coccyx but not arising from it. The en bloc resection of the left gluteal mass with all the margins was done, and the tip of the coccyx was excised.

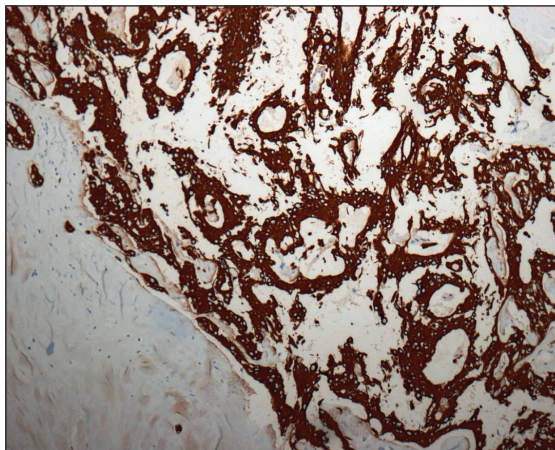
Gross pathologic analysis of the resected lesion demonstrated a lobulated mass of pale tissue measuring 14×13×8 cm partially covered by skin and measuring 13×8.5 cm. Serial sectioning revealed heterogeneous tan to yellowish cut surface and hemorrhagic areas. Microscopic pathologic analysis of the tumor showed the typical histological appearance of an ME. The cells were epithelioid with only minimal nuclear variation



**Figure 1.** Sagittal and axial MR images showing an irregular, lobulated, multicystic soft tissue mass near the coccyx extending to the perineum.



**Figure 2.** Pictomicrograph showing a typical pattern composed of multiple papillary projections covered by cuboidal or short columnar ependymal cells. The ependymal cells are separated from the blood vessels by a zone of basophilic myxomatous material (Hematoxylin and eosin stain,  $\times 200$ ).



**Figure 3.** GFAP positivity in the neoplastic cells ( $\times 100$ ).

and mitotic activity. In terms of architecture, the tumor had microcystic areas with cuboidal cells arranged around pools of basophilic myxoid material. The tumor cells were also arranged radially around fibrovascular cores with intervening myxoid material between the tumor cells and blood vessels (Figure 2). Large areas of necrosis and secondary inflammation were also present due to skin ulceration.

The neoplastic cells were diffusely reactive for glial fibrillary acidic protein (GFAP) (Figure 3), S-100 protein, and vimentin. They were negative for synaptophysin, CAM 5.2, epithelial membrane antigen, carcinoembryonic antigen, and CD34.

The diagnosis of extra axial ME was rendered on the basis of the classical histomorphology and immunohistochemical co-expression of GFAP and S-100 protein.

## DISCUSSION

Ependymomas are the most common intramedullary spinal cord tumors in adults. The 2 most common ependymoma variants are cellular and MEs.<sup>3</sup> Cellular ependymomas can arise anywhere but usually occur in the cervical cord, whereas MEs occur almost exclusively in the conus medullaris and filum terminale. MEs are believed to arise from the ependymal glia of the filum terminale and are typically intradural. Extradural ME are extremely rare, probably arising from extramedullary ependymal rests representing remnants of the coccygeal medullary vestige. This vestige is an ependyma-lined cleft and is a derivative of the caudal neural tube persisting beneath the skin of the post anal pit.<sup>4</sup>

ME demonstrates a slight male predilection and manifests earlier than do other spinal ependymomas, with a mean patient age of 36.4 years at presentation.<sup>3</sup> Subcutaneous sacrococcygeal ME grows slowly, and, therefore, are often large at the time of presentation.<sup>5</sup> The tumor usually presents as an asymptomatic mass at the base of the spine in young individuals and may, therefore, be mistaken for a pilonidal cyst.<sup>6</sup> The MRI features of extradural ME are nonspecific and may be mistaken for a solid teratoma<sup>5</sup> as in our case.

There have been approximately 75 reported cases of extraspinal ependymomas in published reports, with the subcutaneous ME variety accounting for about 50 cases.<sup>7</sup> Helwig and Stern<sup>8</sup> described the gross pathologic appearance of 32 cases of primary subcutaneous sacrococcygeal ME. The mean size of these tumors was 4 cm, ranging from 1.7 to 12 cm. The tumors were generally ovoid, well circumscribed or encapsulated, and firm or rubbery in texture. The cut surface usually appeared lobulated and gray-white. Other features occasionally noted included a moist appearance, hemorrhagic areas, yellow

foci, cysts, and mucoid area. On light microscopic examination, the tumor shows characteristic well-differentiated cuboidal to elongated tumor cells radially oriented around vascularized myxoid cores with a myxopapillary appearance. Usually there is no atypia and no/low mitotic activity. The tumors, either entirely or at least partially, had a papillary architecture on microscopy.

The differential diagnosis includes sacrococcygeal teratoma, neurogenic tumor, soft tissue sarcoma, and metastatic carcinoma. When the tumor involves sacrum and coccyx, tumors such as chordoma and chondrosarcoma must also be excluded. Immunopositivity of the tumor cells with GFAP helps in confirming the diagnosis of ME.

Intradural lumbosacral ependymomas can spread throughout the central nervous system but rarely metastasize beyond it,<sup>9</sup> whereas extradural ependymomas seldom disseminate within the central nervous system but pose a significant risk for systemic metastases.<sup>8,9</sup>

The treatment of choice is gross total resection.<sup>9</sup> Coccygectomy may be required if the tumor is attached to the bone. This treatment makes possible a cure without the need for adjuvant therapy. However, there is a local recurrence after 0.5 to 13.5 years in approximately 25% of patients after the initial surgery.<sup>10</sup>

On the basis of our case and a review of published reports, we concluded that the possibility of ME should be kept in mind as a form of tumor that may present as a mass in the gluteal area. It is usually mistaken for a pilonidal or epidermoid cyst or teratoma. It is advisable to consider an extradural subcutaneous ME as being a low-grade malignant tumor, and complete local excision should be performed in all cases. As the tumor may recur locally and tends to metastasize, such patients should be examined periodically.

## REFERENCES

1. Kernohan JW. Primary tumors of the spinal cord and intradural filum terminale - Cytology and cellular pathology of the nervous system. 1932;3:993-1025).
2. Ilhan I, Berberoglu S, Kutluay L, Maden HA. Subcutaneous sacrococcygeal myxopapillary ependymoma. *Med Pediatr Oncol.* 1998 Feb;30(2):81-4.
3. Shors SM, Jones TA, Jhaveri MD, Huckman MS. Best cases from the AFIP: myxopapillary ependymoma of the sacrum. *Radiographics.* 2006 Oct;26 Suppl 1:S111-6.
4. Koeller KK, Rosenblum RS, Morrison AL. Neoplasms of the spinal cord and filum terminale: radiologic-pathologic correlation. *Radiographics.* 2000 Nov-Dec;20(6):1721-49.
5. Chung JY, Lee SK, Yang KH, Song MK. Subcutaneous sacrococcygeal myxopapillary ependymoma. *AJNR Am J Neuroradiol.* 1999 Feb;20(2):344-6.
6. Agapitos E, Kavantzias N, Karaitianos J, Davaris P. Subcutaneous sacrococcygeal myxopapillary ependymoma. A case report. *Arch Anat Cytol Pathol.* 1995;43(3):157-9.
7. Ma YT, Ramachandra P, Spooner D. Case report: primary subcutaneous sacrococcygeal ependymoma: a case report and review of the literature. *Br J Radiol.* 2006 May;79(941):445-7.
8. Helwig EB, Stern JB. Subcutaneous sacrococcygeal myxopapillary ependymoma. A clinicopathologic study of 32 cases. *Am J Clin Pathol.* 1984 Feb;81(2):156-61.
9. Fassett DR, Schmidt MH. Lumbosacral ependymomas: a review of the management of intradural and extradural tumors. *Neurosurg Focus.* 2003 Nov 15;15(5):E13
10. Akpolat N, Bozlak N, Kazez A, Köseoğullari AA. Sacrococcygeal extraspinal ependymoma: a case report. *Turk J Pediatr.* 2003 Jul-Sep;45(3):276-9.