



REVIEW

# The Pathogenic Role of *Demodex* Mites in Rosacea: A Potential Therapeutic Target Already in Erythematotelangiectatic Rosacea?

Fabienne M. N. Forton

Received: September 3, 2020 / Published online: October 23, 2020  
© The Author(s) 2020

## ABSTRACT

Rosacea is a common facial dermatosis but its definition and classification are still unclear, especially in terms of its links with demodicosis. Triggers of rosacea (ultraviolet light, heat, spicy foods, alcohol, stress, microbes) are currently considered to induce a cascading innate and then adaptive immune response that gets out of control. Recent histological and biochemical studies support the concept that this inflammatory response is a continuum, already present from the onset of the disease, even when no clinical signs of inflammation are visible. The *Demodex* mite is beginning to be accepted as one of the triggers of this inflammatory cascade, and its proliferation as a marker of rosacea; moreover, the papulopustules of rosacea can be effectively treated with topical acaricidal agents. *Demodex* proliferation appears to be a continuum process in rosacea, and may not be clinically visible at the onset of the disease. Molecular studies suggest that *Demodex* may induce tolerogenic dendritic cells and collaborate with vascular endothelial growth factor (VEGF) to induce T cell exhaustion and favor its own proliferation. These interactions among VEGF, *Demodex*, and immunity need to be explored further and the nosology of rosacea

adapted accordingly. However, treating early rosacea, with only clinically visible vascular symptoms, with an acaricide may decrease early inflammation, limit potential flare-ups following laser treatment, and prevent the ultimate development of the papulopustules of rosacea. The effectiveness of this approach needs to be confirmed by prospective controlled clinical trials with long-term follow-up. Currently, the evidence suggests that patients with only vascular symptoms of rosacea should be carefully examined for the presence of follicular scales as signs of *Demodex* overgrowth or pityriasis folliculorum so that these patients, at least, can be treated early with an acaricidal cream.

**Keywords:** Benzyl benzoate; Demodicosis; Dendritic cell; Immunotolerance; Ivermectin; MGL; Rosacea; Standardized skin surface biopsy; Tn Ag; VEGF

---

F. M. N. Forton (✉)  
Rue Frans Binjé 8, 1030 Brussels, Belgium  
e-mail: fabienne@fforton.be

### Key Summary Points

Rosacea is an inflammatory continuum, with all characteristics being already present from the onset of the disease, even if not clinically visible.

*Demodex* proliferation also appears to be a continuum process in rosacea, and high *Demodex* density is beginning to be accepted as an important trigger of the inflammatory cascade and as a marker of rosacea: moreover, papulopustules of rosacea can be treated using acaricides.

Immunological studies are providing new hypotheses according to which *Demodex* may induce tolerogenic dendritic cells and collaborate with VEGF to induce T cell exhaustion favoring its own proliferation. This proliferation may not be clinically visible initially.

The interactions among VEGF, *Demodex*, and immunity need to be explored, and the nosology of rosacea definitions adapted accordingly.

The effectiveness of treating any patient who only has visible vascular symptoms with an acaricidal cream needs to be confirmed in prospective controlled clinical trials with long-term follow-up, but it is already important to detect patients with pityriasis folliculorum among those with only vascular symptoms of rosacea in order to treat at least these patients with an acaricidal cream.

## DIGITAL FEATURES

This article is published with digital features to facilitate understanding of the article. You can access the digital features on the article's associated Figshare page. To view digital features for

this article go to <https://doi.org/10.6084/m9.figshare.13042940>.

## INTRODUCTION

Rosacea and demodicosis are common conditions in dermatology practice. While demodicosis is clearly the result of infestation by the *Demodex* mite, the etiology of rosacea is unclear. However, there is increasing evidence to suggest that rosacea is an inflammatory continuum and that there is a key role for the *Demodex* mite in this inflammatory process. In this review, we will analyze these concepts further and discuss the possible implications for definitions and diagnosis, and also for treatment.

This article is based on previously conducted studies and does not contain any new studies with human participants or animals performed by the author.

## ROSACEA: DEFINITIONS

Rosacea is a common facial dermatosis with a prevalence of up to 10% if all forms are included [1–4]. Pure vascular rosacea is the most common form, about four times more frequent than rosacea with papulopustules [1]. Because the cause of rosacea is still unknown, rosacea is defined by the presence of non-specific clinical signs and symptoms [5, 6]. Successive expert opinion consensus documents have provided definitions and classifications of rosacea but these remain a source of debate [7–11]. In 2002, the National Rosacea Society (NRS) expert committee defined rosacea as a central face distribution of at least one of four primary features (flushing, persistent erythema, papules and pustules, and telangiectasia) and identified four subtypes: erythematotelangiectatic rosacea (ETR), papulopustular rosacea (PPR), phymatous rosacea, and ocular rosacea [12]. Two key clinical features were considered necessary for a diagnosis of the ETR subtype (flushing and persistent centrofacial erythema) [12]. In the 2018 update, the NRS adopted the suggestions of the global ROSacea Consensus (ROSCO) panel [13], abandoning the subtypes in favor of

phenotypes, and defining rosacea as the presence of at least one of two core features [phy-matous changes and persistent centrofacial erythema (Fig. 1a)] OR two of four major features (flushing, telangiectasia, papules/pustules, ocular manifestation) [6]. In the present review, the abbreviation ETR will be used for the phenotype “rosacea with only vascular symptoms” and PPR for “rosacea with papulopustules”.

## ROSACEA: AN INFLAMMATORY CONTINUUM

Rosacea is currently considered by most authors as a disease of the immune system, an inflammatory process including innate and then adaptive immune responses, which gets out of control resulting in vascular, inflammatory, and hypertrophic symptoms [2, 5, 14–22]. Genetic (46%) and environmental (54%) influences have recently been demonstrated in a study on twins [23], and many associated co-morbidities have been highlighted [24].

Histological and biochemical studies converge to suggest the continuum of this inflammatory process [25–38]. From the early stages of rosacea, all typical characteristics of the disease are present, although not all may be clinically visible [25]. These characteristics include dilation of blood and lymphatic vessels [26], solar elastosis [25, 27], and increased intradermal fibroblasts [28]. T cell infiltrates are also present from the early stages of rosacea, around intradermal vessels [25, 30], pilosebaceous follicles [25, 31, 32], and sebaceous glands [33]. These infiltrates are essentially composed of Th1 and Th17 type T helper cells (95%) [34–37] and T suppressor cells (5%) [35], but also of mastocytes [33], macrophages and plasmocytes [25], with a CD4<sup>+</sup> helper/CD8<sup>+</sup> cytotoxic ratio of 2.8, 31% CD4<sup>+</sup>CD25<sup>+</sup> regulatory cells, and 6% plasmacytoid dendritic cells [38]. This infiltrate, often associated with *Demodex* mites [34, 35, 39], invades the follicular wall and forms granulomas, which have been found in all rosacea subtypes [25, 40, 41]. Expression of the genes encoding the cathelicidin peptide LL-37, a key factor in the pathogenesis of rosacea, and other markers of inflammation are already

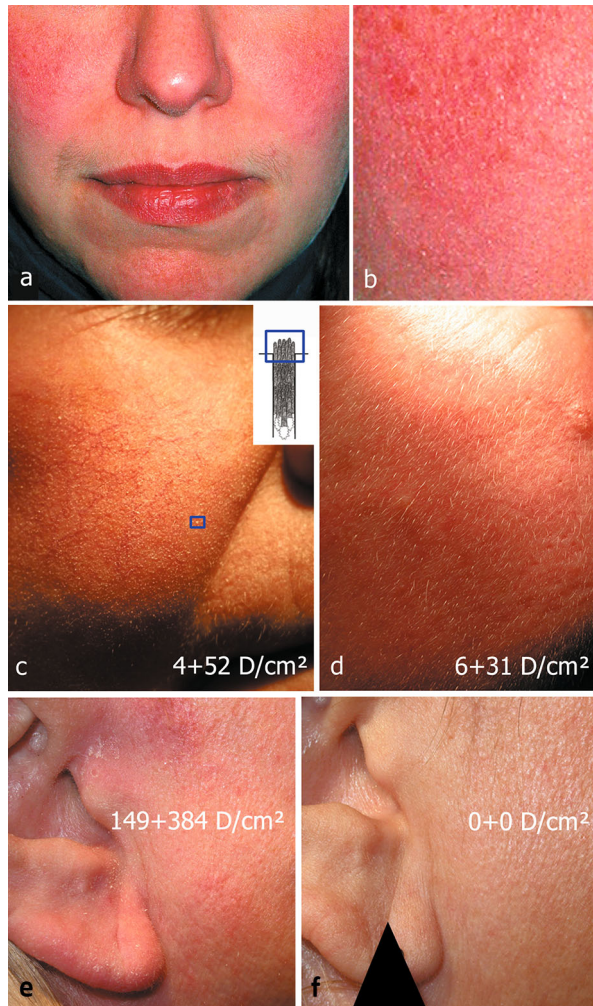increased in ETR and even more so in PPR [29], while dermal expression of vascular endothelial growth factor (VEGF) is similarly increased in ETR and PPR [26].

In PPR, this inflammatory reaction reflects a loss of the immunotolerant milieu seen in sebaceous gland-rich zones of healthy skin: dendritic cells become activated and T cells are increased in number and altered to inflammatory type [36].

## DEMODEX AND DEMODICOSIS

*Demodex folliculorum* and *Demodex brevis* are spindle-shaped transparent mites that live exclusively, at low densities, in human pilosebaceous follicles [42–46] as part of the normal adult human microbiota [42, 46–54]. Humans are born without *Demodex* mites on the skin [43, 54], and the mites are progressively acquired by direct contact with the skin of other humans [44, 55]. As a commensal, the *Demodex* mite likely controls the immune system of the host, through undefined mechanisms, to ensure its own survival [8, 10, 56–60].

The delicate host/*Demodex* equilibrium may be tipped in favor of mite proliferation by various factors, including immunosuppression [61–88], diabetes [89–92]), vasodilatory-related factors [8, 10, 25, 27, 31, 57, 93–97], and/or sebaceous hyperplasia [8, 10, 51, 98]. Initially, overproliferation of the mite is not clinically visible, giving rise to what could be called sub-clinical demodicosis, which can be observed in many skin conditions (including apparently healthy skin and any facial dermatosis), but is commonly encountered in ETR [97] (Fig. 1d). When this proliferation continues, the opisthosomes of the mites become visible to the naked eye, appearing as thin, discreet, regularly dispersed, whitish follicular scales at the base of the hair, often associated with diffuse erythema (which is a key feature of rosacea) [57, 99–102]. These clinically visible symptoms constitute the first stage of demodicosis—pityriasis folliculorum [8, 56, 57, 99, 101–103] (Fig. 1c), called by some primary demodicosis [7]. The symptoms are very discreet and, if the dermatologist is not familiar with the condition and trained to



**Fig. 1** Erythema of rosacea and pityriasis folliculorum. **a** Erythema of rosacea on white skin, according to the consensus of the National Rosacea Society (NRS): original photograph published by the NRS [6]. **b** However, as shown on a zoom on the right cheek, this photo clearly reveals the presence of follicular scales, suggesting a diagnosis of pityriasis folliculorum. **c** Demodicosis associated with vascular symptoms of rosacea: discreet thin whitish follicular scales at the base of the hair give a frosted appearance and a rough texture, suggesting a diagnosis of pityriasis folliculorum; this was confirmed by the diagnostic test. Each follicular scale corresponds to the most superficial part of numerous *Demodex* mites agglutinated on a single follicle (blue box). **d** Subclinical demodicosis with vascular symptoms of rosacea: the follicular scales were not detected on close clinical examination, even after cleaning the skin with ether and using tangential illumination, leading to the clinical diagnosis of erythematotelangiectatic rosacea. However, this patient had a high

*Demodex* density, suggesting a likely diagnosis of subclinical demodicosis. **e, f** Pityriasis folliculorum diagnosed as rosacea and treated with intense pulsed light (IPL): this 41-year-old woman complained of sensitive skin and redness of the whole face for 2 years. She consulted a dermatologist and was treated with isotretinoin for 8 months (30 mg/day for 6 months and 40 mg/day for 2 months) and then by IPL flash lamp (which emits simultaneous wavelengths between 530 and 1200 nm), with no resolution of her problems and even some aggravation. The dermatologist then sent the patient to our clinic for our advice. The patient had diffuse redness all over the face (not shown), more pronounced at the follicular orifices, with slight diffuse edema (visible on the lobule of the ear): the skin appeared irritated. On close examination, there was no vellus hair or follicular scales on the skin of the central face. After the skin was cleaned with ether, two standardized skin surface biopsies were consecutively performed on the right cheek and confirmed the absence of *Demodex* mite ( $0 + 0$  D/cm<sup>2</sup>). Nevertheless, on small areas not treated by IPL, i.e., the lobule of the ear and the preauricular zone of the cheek, we discovered follicular scales suggesting *Demodex* mites. **e** On the preauricular zone, the mite density was very high, confirming the diagnosis of pityriasis folliculorum. The patient was instructed to apply an acaricidal cream (benzyl benzoate 12% and crotamiton 10% in Cetomacrogol cream) all over the face (not on the eyelashes or the lips) once daily for 1 week, then twice daily. **f** Two months later, facial signs and symptoms had cleared and the *Demodex* density was normalized on the preauricular zone ( $0 + 0$  D/cm<sup>2</sup>). We concluded that the IPL may have killed the mites on the treated zones with release of their antigens and flare-up of the inflammation, or that the mites may still have persisted more deeply in the skin, in sufficient number to induce the inflammation. The standardized skin surface biopsy (SSSB1 + SSSB2) values are indicated on the figure. Part **a**, so also the zoom **b**, was reprinted from “Gallo RL et al. Standard classification and pathophysiology of rosacea: The 2017 update by the National Rosacea Society Expert Committee. *J Am Acad Dermatol.* 2018;78(1):148–55”, 2018, with permission from Elsevier. Parts **c** and **d** were reprinted from “Forton FMN, De Maertelaer V. Erythematotelangiectatic rosacea may be associated with a subclinical stage of demodicosis. A case control study. *Br J Dermatol.* 2019; 181: 818–25”, 2019, with permission from John Wiley and Sons

detect it, may go unnoticed, so that this entity is often underdiagnosed [56, 98, 102, 104]. To detect the follicular scales, the dermatologist must examine the skin from a distance of maximum 30 cm, with good tangential lighting; sometimes cleaning the skin with ether may be necessary to reveal the scales [97, 99, 101, 105]. Subjective complaints (sensation of burning, pruritus, dry skin, hypersensitive skin, irregular or rough skin) may also be present [7, 56, 57, 99, 101–103]. Nevertheless, despite the discreet symptoms (likely because of the mites' control over host immunity), *Demodex* densities in the skin of these patients are usually high [101–103], with values ranging from 7 to 61 D/cm<sup>2</sup> depending on the sampling method used and the population studied [56, 57, 106, 107], and reaching as much as 285 ± 12 D/cm<sup>2</sup> when the densities of two consecutive standardized skin surface biopsies (SSSBs) are summed [108, 109].

Over time, a more inflammatory stage of the disease may occur. Despite the local immunotolerance likely induced by the mite, the host immune system mounts a chronic, exaggerated, and not very effective response, resulting in the development of the papules and pustules of demodicosis [57, 104, 110], clinically represented by “rosacea-like demodicosis” and other variants (*Demodex* folliculitis/abscesses, demodectic prurigo, isolated inflammatory papule, follicular eczematids, demodectic post inflammatory pigmentation, and ocular demodicosis) [7, 8, 10, 56, 57, 72, 101–103, 111–122]. The exact prevalence of demodicosis is unknown, but is at least 1.5 times more frequent than PPR in dermatological consultations [56].

## DEMODEX PROLIFERATION IN ROSACEA: A CONTINUUM PROCESS?

Most authors still consider that proliferation of the *Demodex* mite in patients with rosacea is a secondary event, an epiphenomenon or an aggravating factor in which the initial inflammation promotes the proliferation of *Demodex*, which then exacerbates the disease [25, 123–127]. However, multiple observations

suggest that the *Demodex* mite may itself contribute to the early inflammatory process. Indeed, in histological studies, *Demodex* mites are found in 63% of cases with ETR, 85% to almost 100% of cases of PPR, and in 100% of hypertrophic forms of rosacea [31, 94]; they have also been identified in intradermal granulomas in 3–66% of patients with granulomatous rosacea [25, 128–131]. The mean facial density of the mite in patients with ETR is between the low density found in subjects with healthy skin and the very high density in those with demodicosis and PPR [95, 97, 132–135]. In an observational study, we observed an abnormally high *Demodex* density in about half of our patients with ETR (10/23 patients), with high variability in values showing that different patients had different degrees of *Demodex* proliferation [97]. As we took particular care not to include patients with discreet pityriasis folliculorum in our ETR group, we concluded that ETR may be associated with non-visible *Demodex* proliferation, possibly corresponding to a sub-clinical stage of demodicosis [97].

As PPR is more often observed after ETR than the inverse among patients with both PPR and ETR [136], and as the *Demodex* mite may be responsible for the papules and pustules of rosacea, this suggests that ETR is a condition that promotes mite proliferation [97], via a mechanism that is still unclear. One hypothesis is that vasodilation increases skin temperature [27, 31, 94], potentially promoting parasite reproduction, but the temperature, although it may be increased during flushes [137], does not appear to be higher in the skin of patients with ETR than in those without [138].

While it likely induces immunotolerance, *Demodex* is also able to stimulate the immune system's defense reaction [34, 43, 57, 58, 104, 110]. It stimulates Toll-like receptor 2 (TLR2) [58], resulting in an increased production of LL-37, with the subsequent angiogenesis and inflammation that are described in rosacea [15–18]. This implies the existence of a vicious circle including ETR, mite proliferation, and inflammation [10].

*Demodex* proliferation therefore seems to contribute to the continuum process in rosacea across all phenotypes.

## DEMODEX AND IMMUNOTOLERANCE: A ROLE FOR VEGF AND THOMSEN-NOUVEAU ANTIGEN (TN AG)?

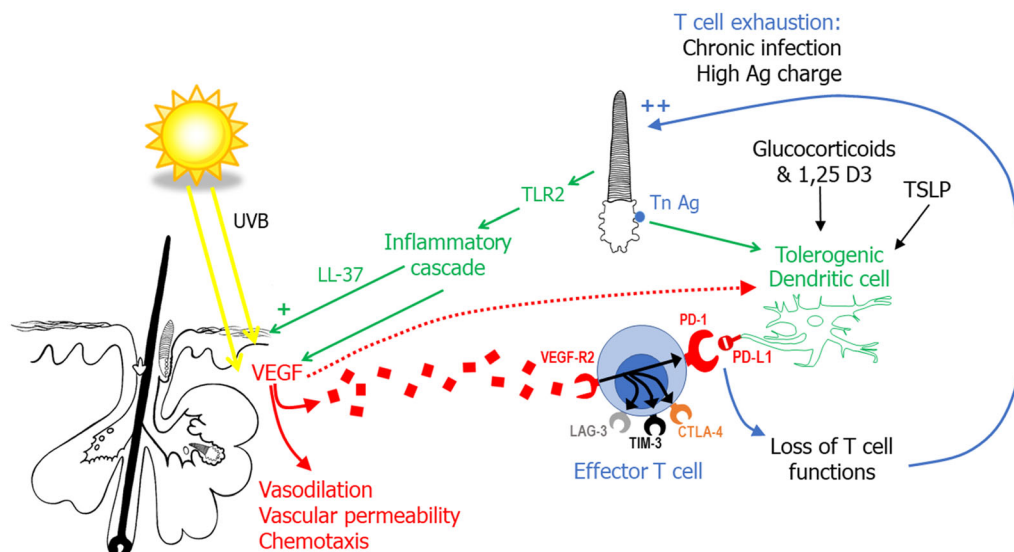
The apparent effect of ETR on *Demodex* proliferation [27, 31, 94, 97] may be explained by the immunosuppressive properties of VEGF, which were recently described in tumor pathology. VEGF inhibits maturation of dendritic cells, induces accumulation of immunosuppressive cells, such as regulatory T cells, and inhibits the migration of T lymphocytes to the tumor, thus favoring tumor cell escape from immune system surveillance [139, 140]. In rosacea, VEGF and its receptors, VEGF-R1 and VEGF-R2, are expressed not only by the epidermis, as in normal skin, but also by dermal infiltrating leukocytes (including lymphocytes, macrophages, and plasma cells) [141]. Moreover, accumulation of regulatory T cells has been observed [36, 38], as in demodicosis [142]. This suggests that, as in tumoral processes, VEGF may induce T cell exhaustion in rosacea and, through collaboration with tolerogenic dendritic cells, may favor the initial proliferation of the mite during the development of ETR (Fig. 2). The fact that *Demodex* densities can be normal in as many as half the patients with ETR [97] may be explained by a time lag between the immunomodulatory and pro-angiogenic effects of VEGF.

In addition to the direct action of VEGF on the maturation of dendritic cells [139], tolerogenic dendritic cells may be induced by several mechanisms. Initially, their production may be stimulated by high levels of thymic stromal lymphopoietin (TSLP) observed in sebaceous gland-rich zones of the healthy skin, where it induces an immunotolerant milieu for commensal microbes [36]: this cytokine exists in two forms, a long (inflammatory) and a short (tolerogenic) isoform [143] and is produced by keratinocytes in response to microbial products, physical injury, or inflammatory cytokines [144].

Tolerogenic dendritic cells may also be induced by vitamin D<sub>3</sub> and/or endogenous glucocorticoids. Indeed, in rosacea, TLR2

stimulates the enzyme responsible for the second hydroxylation of vitamin D<sub>3</sub> in keratinocytes, which initiates the inflammatory cascade [18] and promotes innate immunity [17]. But vitamin D<sub>3</sub> also inhibits adaptive immunity: exogenous treatment with vitamin D<sub>3</sub> promotes tolerogenic dendritic cells and increases expression of PD-L1 in dendritic cells, thus suppressing T cell proliferation [145]. The combination of dexamethasone and vitamin D<sub>3</sub> is an even more potent inducer of tolerogenic dendritic cells [145]. Furthermore, in ETR, abnormal glucocorticoid endogenous synthesis has been observed [146].

Tolerogenic dendritic cells may also be induced by the *Demodex* mite: because *Demodex* expresses the Tn Ag [147], it is possible that the mite could use this to induce immunotolerance for its own benefit (Fig. 3). Indeed, the Tn Ag is a precursor of the tumor Thomsen–Friedenreich (T) antigen [147]. These two antigens are tumor-associated glycan structures, and high expression levels are correlated with poor prognosis and an increased ability of the tumor to metastasize [147, 148]. Recently, it was shown that Tn Ag is recognized by the macrophage galactose-type lectin receptor (MGL) of the dendritic cell, which, on contact with it, becomes tolerogenic [148], inducing T cell exhaustion [149–152] (Fig. 3). After stimulation of its TLR2, producing a slight pro-inflammatory reaction, the dendritic cell usually also produces interleukin-10 (IL-10) as a natural feedback loop to prevent excessive inflammation. When its MGL receptor is also stimulated, this production of IL-10 is markedly increased, the two receptors working synergistically [151]. IL-10 is thought to play a pivotal role in blocking the metabolic switch to glycolysis (which is linked to immunogenic functions) and stimulating the expression of inhibitory receptors on dendritic cells (including PD-L1) and cytokines that induce transformation to tolerogenic dendritic cells [145] (Fig. 3). As *Demodex* mites express the Tn Ag [147], these immune reactions may also occur after contact of mite Tn Ag with dendritic cells.



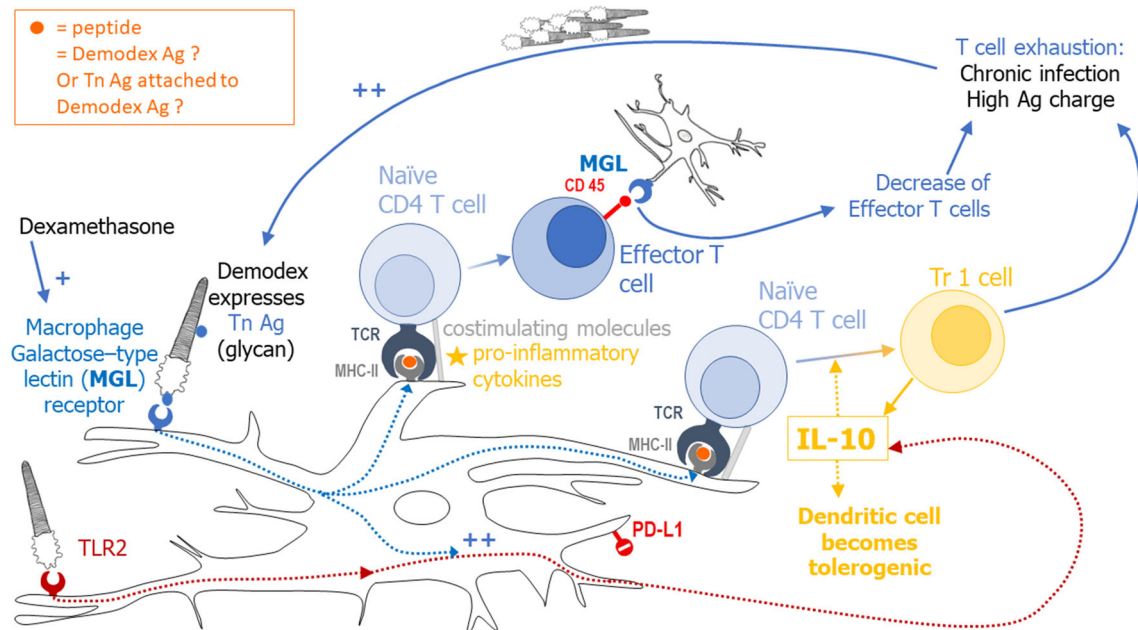
**Fig. 2** Schematic of hypothesis that vascular endothelial growth factor (VEGF) may promote T cell exhaustion and therefore *Demodex* proliferation, by analogy with what happens with tumors. This figure assembles information from tumor pathology, from studies on *Demodex* and rosacea, and from the hypothesis formulated in Fig. 3. In tumor pathology, it is known that tumors secrete VEGF, which favors their development through its pro-angiogenic properties, but also by favoring T cell exhaustion: when VEGF is bound by the VEGF receptor (VEGF-R2) present on CD8<sup>+</sup> cytotoxic T lymphocytes, inhibitory receptors, such as programmed cell death 1 (PD-1), cytotoxic T lymphocyte antigen (CTLA-4), T cell immunoglobulin and mucin 3 domain (TIM-3), or lymphocyte activation gene 3 protein (LAG-3), are expressed on the lymphocyte surface [140]. When these receptors bind to their ligands, expressed by the tumors, this causes loss of lymphocyte function, with accumulation of regulatory T cells, reflecting T cell exhaustion [140]. In the skin, VEGF is produced by keratinocytes and fibroblasts under ultraviolet (UV) B induction [237, 238] and is increased in the dermis in rosacea, both in erythematotelangiectatic rosacea (ETR) and papulopustular rosacea (PPR) [26]. VEGF may play

the same role in rosacea as in tumor pathology and collaborate with the tolerogenic dendritic cells to induce T cell exhaustion. The PD-1 receptor, induced on the effector T cell surface by its synapse with VEGF, binds to the programmed death ligand 1 (PD-L1), expressed on the surface of tolerogenic dendritic cells: this synapse then causes a loss of T cell function [145]. Tolerogenic dendritic cells may be induced by the mite (Fig. 3), thymic stromal lymphopoietin (TSLP) [36], vitamin D<sub>3</sub> (1,25 D<sub>3</sub>) and/or glucocorticoids [145, 149], and production is also favored by VEGF [139]. The *Demodex* mite activates a Toll-like receptor 2 (TLR2) pathway immune response [58], which induces increased production of the cathelicidin peptide, LL-37, and subsequent angiogenesis and inflammation [15, 18]. As LL-37 stimulates the activity of endothelial cells after UV exposure and may lead to increased sensitivity to UVB radiation [20, 21], theoretically, *Demodex* mites may also contribute to a higher sensitivity of the skin to UVB. This suggests a vicious circle that includes mite proliferation, TLR2, LL-37, sensitivity to UVB, and VEGF, providing a physiopathogenic link between ETR and PPR.

## ROSACEA: CHRONIC *DEMODOX* INFECTION WITH T CELL EXHAUSTION?

*Demodex* therefore likely induces tolerogenic dendritic cells via its Tn Ag, for its own survival (Fig. 3). It also induces a defensive, immunogenic immune reaction aimed at eliminating

the mite, but probably succeeds in diverting this for its own benefit, by using VEGF and induced tolerogenic dendritic cells to cause T cell exhaustion (Fig. 2), as has been reported in dogs [153]. As some of the accumulated T cells will have lost their normal function [36, 38], the inflammatory reaction is likely to be insufficient to kill the mites, leading to a chronic infection



**Fig. 3** How *Demodex* may manipulate the host immune system via its Tn Ag to induce dendritic cell immunotolerance. This schematic figure assembles information from immunological studies on dendritic cells and from immunohistological studies on *Demodex* and rosacea. Immunological studies have shown that when dendritic cells connect with the Thomsen-nouveau antigen (Tn Ag), through its macrophage galactose-type lectin receptor (MGL), the cells migrate towards the draining lymph node, where they initiate adaptive immunity [149]. The dendritic cells interact with naïve T cells to induce immunotolerance: a peptide Ag (small orange circle) with the major histocompatibility complex (MHC) type II is presented to the T cell receptor (TCR) of the naïve T cell, together with co-stimulation molecules (gray bar). If the dendritic cell also secretes pro-inflammatory cytokines (yellow star), the Ag presentation transforms the naïve T cell into an effector T cell expressing CD45. This interacts again with the MGL receptor of the dendritic cell [150], inducing loss of the functions of the effector T cell (decreasing proliferation, reducing production of inflammatory cytokines, and increasing apoptosis) [151]. If, instead of pro-inflammatory cytokines, there is interleukin

with persistence of a high antigenic load. This hypothesis places the dendritic cell, together with the mite, at the heart of the pathophysiology of rosacea and, because of the existence of different types of dendritic cells (polymorphism of dendritic cell genes), may explain the

(IL-10), contact with the naïve T cell results in its transformation into a Tr1 lymphocyte (with immunosuppressive functions), which in turn produces more IL-10 [148, 152]. The production of IL-10 by the dendritic cell after stimulation of its TLR2 is strongly increased when the MGL receptor is also stimulated [151]. IL-10 is thought to induce tolerogenic transformation of the dendritic cell and to stimulate the expression of inhibitory receptors (including programmed death-ligand 1 (PD-L1)) [145]. As *Demodex* mites express the Tn Ag [147], these immune reactions may also occur after contact of mite Tn Ag with dendritic cells. The peptide Ag (small orange circle) presented by the dendritic cells to the naïve T cell may be another *Demodex* Ag (exocuticle [239], proteases [167], its endosymbiont *Corynebacterium kroppenstedtii* [240], etc.) or the Tn Ag attached to a peptide *Demodex* Ag. The *Demodex* mite has also been shown to stimulate TLR2 [58], expression of which is increased in rosacea [18]. Dexamethasone treatment upregulated MGL expression on dendritic cells [149], and, in ETR, abnormal endogenous glucocorticoid synthesis has been observed [146]

differences in individual susceptibilities to *Demodex* antigens, and thus some of the genetic influence, as in inflammatory bowel disease [154].



## DIAGNOSTIC CONFUSION

The potential role of the *Demodex* mite in the development of rosacea and the multiple similarities between demodicosis and rosacea lead to considerable diagnostic confusion. More work needs to be done to reach agreement on the diagnosis and relationship among demodicosis, ETR, and PPR, potentially leading to a consensus that they are all part of the same entity (Figs. 4 and 5) [8, 10, 155].

### Pityriasis Folliculorum and ETR

When pityriasis folliculorum is associated with flushes, erythema, and/or telangiectasia, these obvious vascular symptoms may overshadow the discreet follicular scales of pityriasis folliculorum which are more difficult to identify (Figs. 1c, 5), thus potentially leading to a misdiagnosis of ETR based on the presence of persistent erythema. This diagnostic confusion may explain the unusually high *Demodex* densities observed in some studies of patients with ETR, similar to those observed in patients with PPR [29, 156]. Some patients with pityriasis folliculorum (with subclinical, subtle, or even obvious follicular scales) were probably misdiagnosed as ETR. Some authors may also have confused follicular scales with dry skin, with some even talking about two subtypes of ETR—scaly and not scaly ETR [157]—instead of the more likely diagnosis of pityriasis folliculorum. Others have suggested that this dry and rough aspect, with the possibility of fine follicular scales, is a characteristic of ETR [158]. This possible confusion highlights the importance of careful skin examination by a dermatologist experienced in the diagnosis of demodicosis.

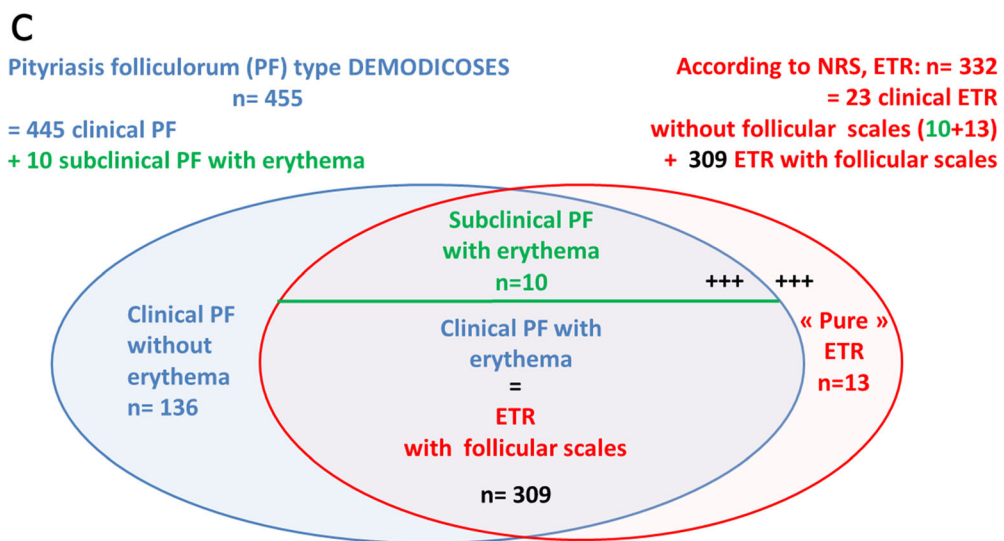
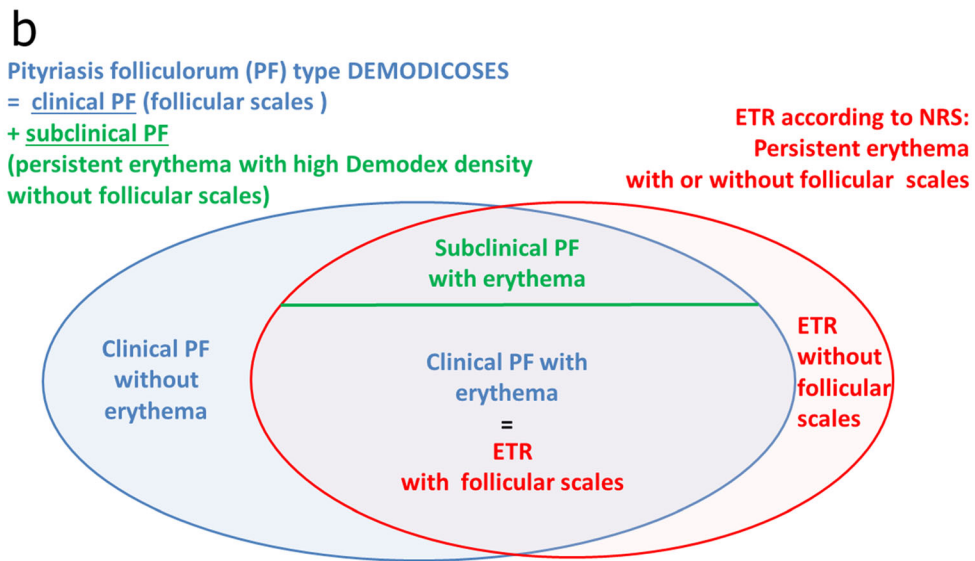
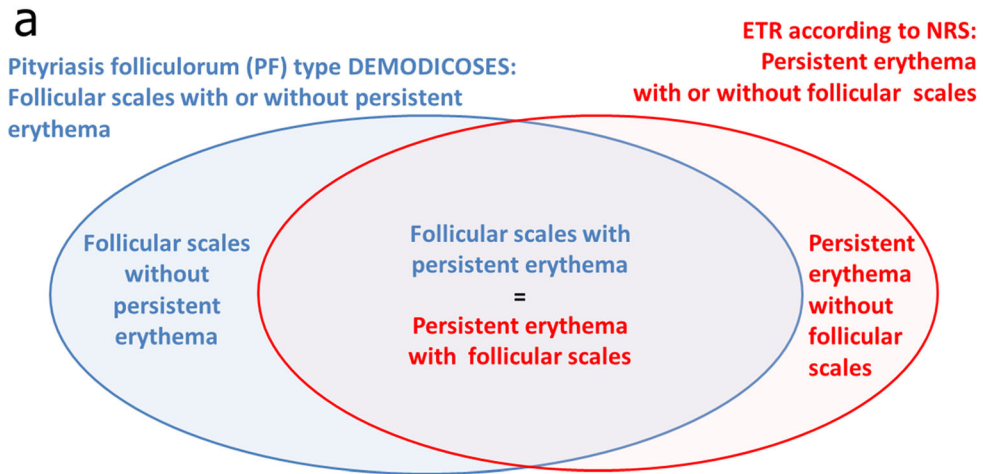
The ROSCO consensus specifies that demodicosis must be excluded before diagnosing rosacea, but without specifying how this should be done [13]. Interestingly, on the photo selected by the NRS to illustrate rosacea with only persistent erythema [6], there is evidence of the presence of follicular scales, suggesting that, according to the NRS, patients with ETR may have follicular scales, and thus pityriasis folliculorum (Figs. 1a, b, Fig. 4,

Table 1). Moreover, as a secondary ocular manifestation of rosacea, the NRS included collarette accumulation at the base of the lashes [6], likely corresponding to the cylindrical dandruff/follicular scales described in ocular demodicosis [118].

### Rosacea-Like Demodicosis and PPR

If *Demodex* mites induce the immune response that leads to the papules and pustules of PPR [8, 10, 29, 31, 34, 35, 56–58, 99, 108, 110, 111, 128, 132–134, 159–170], then rosacea-like demodicosis and PPR are probably two phenotypes of the same disease [10]. Indeed, the descriptions of demodicosis and rosacea seem to indicate two different approaches to the same condition (Table 1): their definitions cannot be compared because they are based on different criteria (etiological for demodicosis [101, 102] and clinical for rosacea [5, 6]); their symptoms are similar [10, 31] with no single criterion being specific for either and most patients presenting a mixture of characteristics that can be attributed to both of the entities [10]; they may occur successively in the same patient [10]; their histological characteristics are similar [31]; their *Demodex* densities are similar [10]; and both respond very well to acaricidal treatment, in terms of reduced *Demodex* densities and improved clinical symptoms [159, 160, 171, 172]. It is therefore increasingly difficult to defend the view that, in these two similar diseases, the exaggerated proliferation of parasites has a different role, causal in one and epiphenomenal in the other.

The *Demodex* mite is beginning to be accepted as one of the triggers that stimulates TLR2 at the start of the inflammatory cascade in rosacea [5, 14, 93, 123, 173], and as a marker of rosacea [174]: a clinical diagnosis of PPR may be confirmed by a diagnostic test based on the high *Demodex* density present in these patients, using two SSSBs taken from the same site. A superficial [SSSB1] *Demodex* density greater than 5 D/cm<sup>2</sup> OR a deep [SSSB2] *Demodex* density greater than 10 D/cm<sup>2</sup> enabled confirmation of a diagnosis of PPR (or demodicosis) with a sensitivity of 98.7% and a specificity of 95.5% [108].



◀ **Fig. 4** Overlap of the clinical entities pityriasis folliculorum (PF) and erythematotelangiectatic rosacea (ETR). **a** Schematic conceptualization of the overlap between PF and ETR. Most cases of “ETR according to the National Rosacea Society (NRS) definition” have follicular scales. Patients with the pure vascular form of rosacea (without increased *Demodex* density/follicular scales) or pure demodicosis (without persistent centrofacial erythema) are encountered less frequently. “PF with persistent erythema” and “ETR with follicular scales” are likely the same entity, with two possible modes of entry: (1) ETR, likely through VEGF, favors mite overproliferation [8, 10, 25, 27, 31, 57, 93–97], which in turn results in increased erythema as a result of inflammation; and (2) other factors favoring mite proliferation give rise initially to PF without erythema, but persistent erythema then develops as a result of the inflammation caused by the mites. **b** Some patients have persistent erythema without visible follicular scales, but nevertheless have high *Demodex* densities (Dd): they are considered to have subclinical demodicosis/subclinical pityriasis folliculorum, and so are included into the demodicosis group. **c** As a practical example of the schema in **b**, we provide the data from the 445 patients clinically diagnosed with pityriasis folliculorum and 23 patients clinically diagnosed with ETR from our recent studies [97, 99, 108]. According to the NRS definition, 332 of these 468 patients would have been diagnosed as ETR, of whom 309 (93%) had follicular scales. Clinically, among these 332 patients, we diagnosed only 23 patients as having ETR (without follicular scales) and 309 as having pityriasis folliculorum; only 13 had “pure” ETR, without *Demodex* proliferation detected. Patients with persistent erythema and high *Demodex* density (i.e., subclinical PF with erythema or clinical PF with erythema/ETR with follicular scales) were the most numerous ( $319/468 = 68\%$ ). In real life, the proportion of patients with ETR without follicular scales is nevertheless certainly higher (“+++”) because in our studies these patients were only included when we had time to perform the SSSB, whereas all patients with follicular scales were included [97, 99, 108]

## CURRENT TREATMENTS FOR VASCULAR SYMPTOMS OF ROSACEA: ACARICIDAL EFFECTS?

### Light Therapies

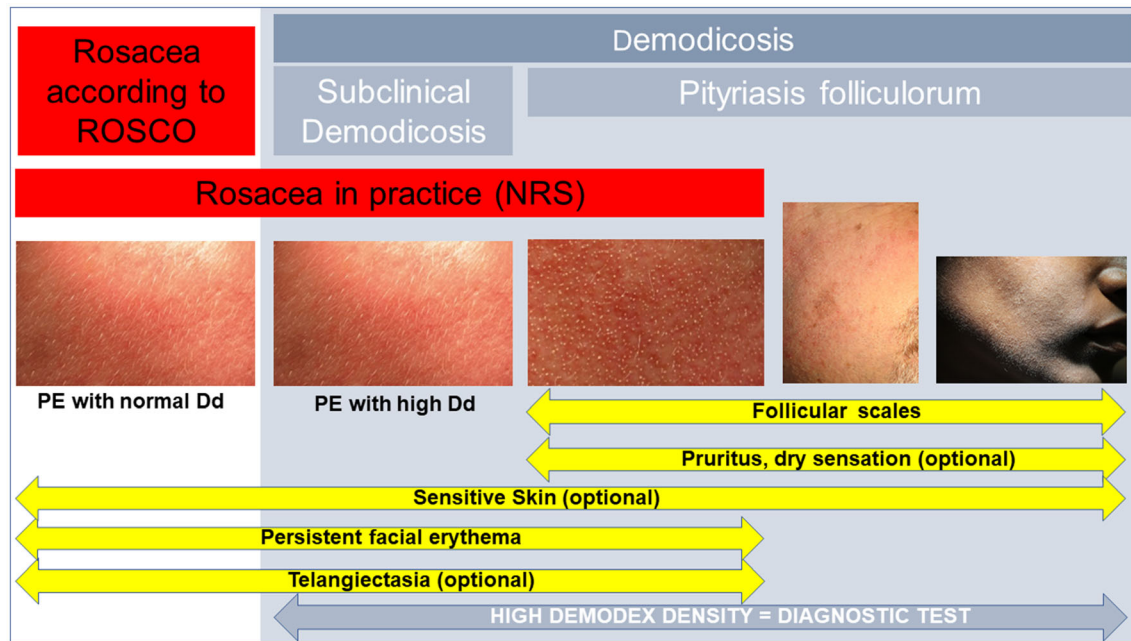
Light-based treatments with (long) pulsed dye laser (PDL), neodymium-doped yttrium

aluminum garnet (Nd:YAG) laser, and intense pulsed light (IPL) target oxyhemoglobin in the vascular system [155], but may also have acaricidal actions in rosacea. PDL, which had earlier been reported to have limited value for treatment of papulopustules [175], was recently shown to decrease their number [176]; this action, as well as its effect on erythema, tended to be more marked when ivermectin was given topically at the same time [176]. Nd:YAG laser also acts on papulopustules but is more effective in ETR than in PPR [177]. These actions on the papulopustules may result from a potential acaricidal effect as a result of increasing skin temperature [178] and, for the Nd:YAG laser, by destruction of the follicular unit [177]. One study suggested that these therapies may therefore be used not only in ETR but also in demodicosis [178], although these findings need to be confirmed. Coagulation necrosis of the *Demodex* mites has been observed after IPL treatment; nevertheless, the mites recolonized the skin 1 month after the second treatment [179]. IPL reduced the risk of recurrence of PPR after oral acaricidal treatment [180, 181], which also supports a facilitating role of the vascular background on the proliferation of mites.

Paradoxically, if these light-based therapies are applied from the outset of treatment, they may cause an exacerbation of rosacea, probably related to the mass death of many *Demodex* mites, although not all, because some are still observed after treatment [182] (Fig. 1e, f). Patients should therefore be treated first with an acaricidal treatment, and then possibly by laser or IPL treatment [182].

### Vasoconstrictors

Topical vasoconstrictors, such as  $\alpha$ -blockers (brimonidine, oxymetazoline) [183, 184], are used to decrease vasodilation of the dermal capillaries for a limited time, and act mainly on erythema but not on telangiectasia [2]. They are mainly recommended after light therapy, when this is not completely successful [185]. To our knowledge, these treatments have no activity against the *Demodex* mite.



**Fig. 5** Rosacea with only vascular symptoms and pityriasis folliculorum: overlaps and ambiguities in diagnostic criteria. According to the ROSacea COnsensus (ROSCO) panel, demodicosis must be excluded before making a diagnosis of rosacea [13], but it was not specified how this should be done; however, it can be assumed that the *Demodex* density must be normal. The latest National Rosacea Society (NRS) consensus seems not to take follicular scales into consideration to include or exclude a diagnosis of rosacea: the consequence is that patients with pityriasis folliculorum (and subclinical demodicosis) with vascular symptoms may therefore be (mis)diagnosed as

having rosacea with only vascular symptoms (ETR). However, pityriasis folliculorum is not always associated with ETR (the two photos on the right, on white skin and black skin). Of note, the photograph illustrating “Persistent erythema (PE) with normal *Demodex* density (Dd)” is the same as that of subclinical demodicosis “PE with high Dd” to stress that the clinical appearance/phenotypes of these conditions are identical. The patient with pityriasis folliculorum on black skin has provided written consent for publication

## ACARICIDAL TREATMENTS

### Case Reports

Multiple molecules have been reported to reduce the number or density of *Demodex* mites and improve or cure symptoms of demodicosis and rosacea in case studies.

Topical treatments have included sulfur or selenium (di)sulfide [75, 81, 101, 102, 105, 114, 115, 186–188], lindane (currently prohibited) [73, 74], yellow mercury oxide [189], malathion [72], metronidazole [190, 191], permethrin [71, 73, 192], pilocarpine [193, 194], benzyl benzoate [195], and combinations of some of these treatments

(also with crotamiton) [103, 196–199]. Oral treatments have included ivermectin (alone [200] or associated with topically administered crotamiton [201] or permethrin [202]) and metronidazole (alone [121, 203] or associated with topically administered metronidazole [197] or crotamiton [204]).

Some case reports in which these treatments were used also observed a clinical effect on lesions rich in *Demodex* but did not check that *Demodex* levels decreased after treatment [66–68, 70, 77, 120, 205–207].

Other case studies have reported no clinical effects of some of these treatments in demodicosis, e.g., permethrin [68, 203], crotamiton [70], topically administered [68, 70, 203] and

**Table 1** Comparison between pityriasis folliculorum and erythematotelangiectatic rosacea (ETR), and between rosacea-like demodicosis and typical papulopustular rosacea (PPR)

Pityriasis folliculorum		ETR according to NRS definition		References
Definition	Etiological	Clinical		[6, 101, 102, 105]
Cause	<i>Demodex</i> proliferation	Inflammatory reaction?		[6, 101, 102, 105]
<i>Demodex</i> density	Similar			[29, 109, 156]
Histology	Similar			[31]
Signs and symptoms	Similar, mixed forms are the most frequent			[6, 97], Fig. 4c
Main characteristic	Follicular scales	Persistent centrofacial erythema associated with periodic intensification by trigger factors		[6, 101, 102, 105]
Persistent erythema	Frequent	Always		[6], Fig. 4c
Follicular scales	Nearly always	Frequent		[99], Fig. 4c
Facial location	All	Central part		[6, 99, 101, 102, 105, 114]
Treatment	Acaricide	Light treatment, vasoconstrictors		
Rosacea-like demodicosis		PPR according to NRS definition		References
Definition	Etiological	Clinical		[6, 102, 105]
Cause	<i>Demodex</i> proliferation	Inflammatory reaction? <i>Demodex</i> proliferation?		[6, 102, 105]
<i>Demodex</i> density	Similar, very high			[10]
Histology	Similar			[31]
Signs and symptoms	Similar, mixed forms are the most frequent			[10, 113]
Follicular scales	Similar			[99]
Skin	More dry	More greasy		[102, 105]
Facial location	Central and lateral parts	Central part		[6, 102, 105]

Table 1 continued

	Rosacea-like demodicosis	PPR according to NRS definition	References
Persistent erythema	More unilateral	More bilateral	[71, 120, 201, 204, 207, 208]
Flushes/erythema	Frequent	Always	[6, 102, 105]
Papules and pustules	Less intense	More intense	[6, 102, 105]
Pruritus	More superficial and smaller	Deeper and larger	[102, 105, 113]
Evolution over time	Usually considered more frequent in demodicosis		[70, 72, 74, 79, 241, 242, 99]
Treatment	The 2 forms may occur successively in the same patient		[10]
	Often after pityriasis folliculorum	More often after ETR than the reverse	[8, 57, 136]
	Acaricide	Anti-inflammatory, acaricide	

orally administered [204, 208] metronidazole, and orally administered ivermectin [121].

### Experimental and Clinical Studies

Some authors have studied the survival time of the *Demodex* mite in vitro [209–213]. Tea tree oil and its isolated active component were shown to have considerable acaricidal activity [117, 210–212]; although they have mainly been used in *Demodex* blepharitis [117, 214, 215], they therefore also seem to be a promising treatment to kill the mites in the facial skin [216]. A relatively crude in vitro experiment using different concentrations of metronidazole showed that *Demodex* mites survived at a concentration of 1 mg/ml, a level that cannot be obtained in vivo [213]: the authors therefore suggested that metronidazole may act not directly in vivo but via one of its metabolites [217]. In a randomized clinical study comparing six topical treatments, we found that metronidazole had no acaricidal activity as measured using *Demodex* densities [218]. In a single-blind randomized study comparing an oral metronidazole-based treatment with a treatment based on oral ornidazole administration (a metronidazole analogue with a longer half-life), ornidazole was more effective than metronidazole (in terms of *Demodex* counts and clinical symptoms) and associated with fewer relapses [180].

In a randomized study, oral metronidazole treatment increased the acaricidal action seen with orally administered ivermectin [219], although the acaricidal effects of orally administered ivermectin have never been confirmed, especially over the long term, likely because the treatment itself is very short (2 weeks).

An acaricidal effect of permethrin cream applied twice daily was reported in two controlled studies [220, 221], and this treatment was proposed as a valuable option in a recent review [222].

Our randomized clinical study comparing six topical treatments reported that benzyl benzoate had marked acaricidal action and cro-tamiton moderate action [218]. We recently demonstrated the short- and long-term actions

of benzyl benzoate (with crotamiton) on *Demodex* density and on clinical symptoms in a real-life study [159, 160]. In our practice, we successfully used benzyl benzoate (with crotamiton) cream for more than 20 years; however, the development of ivermectin has provided an effective alternative [172, 223, 224] with better tolerance and this is now our treatment of choice. Indeed, ivermectin was approved by the US Food and Drug Administration and the European Medicines Agency in 2014–2015 as a topical anti-inflammatory treatment for PPR as a 1% once daily application [225]. Ivermectin quickly became established, together with azelaic acid, as a first-line treatment for PPR in mild rosacea [2, 183, 184, 223, 226–229], and combined with orally administered doxycycline in moderate to severe rosacea [173, 230, 231]. However, its efficacy may, at least in part, be explained by its other important property: acaricidal effects against the *Demodex* mite [172, 173, 225, 228, 230, 232–236]. Indeed, two other acaricidal treatments which have no known anti-inflammatory properties also improve clinical symptoms of rosacea: permethrin (5% applied twice daily) improved the vascular component of rosacea (erythema [221], telangiectasia [220]), and benzyl benzoate was shown to be an effective treatment for PPR [159, 160]. These observations provide indirect support for the role of the mite in PPR, as already suggested by numerous other studies [8, 10, 29, 31, 34, 35, 56–58, 99, 108, 110, 111, 128, 132–134, 161–170].

### Acaricidal Treatment for ETR?

Topical acaricidal treatment is certainly the most appropriate treatment for patients with pityriasis folliculorum with vascular symptoms/ETR with follicular scales: this therapy kills the mites and decreases subsequent inflammation and associated persistent erythema. In our experience, topical acaricidal treatment leads to disappearance of follicular scales [159, 160] as well as subjective complaints, such as burning sensation and hypersensitive skin. If only mild erythema is present, it may completely, or

almost completely, resolve after eradication of the mites, so that supplementary treatment (e.g., light therapy) may not be needed. More severe erythema generally just decreases a little in intensity, but the acaricidal treatment is nevertheless useful because subsequent light treatment may be better tolerated, without the potential for flare-ups [182].

Acaricidal treatment may also prevent the immunotolerance induced by the mite, and its subsequent overproliferation and ultimately the development of the papulopustules of rosacea, although further study is needed to confirm this hypothesis.

Because the distinction between ETR and pityriasis folliculorum is often not made, and even experienced dermatologists may miss subclinical demodicosis in about 40–50% of cases, a pragmatic approach may be to start treatment of all patients diagnosed with “ETR” with an acaricide (because many of them will have undiagnosed pityriasis folliculorum) for 2–4 months. A more scientific approach would be to measure the *Demodex* density in all patients with suspected ETR and start treatment with an acaricide only when the *Demodex* density is high and until the *Demodex* density normalizes (followed by a maintenance therapy). This can be managed easily in the clinic using two consecutive SSSBs as discussed earlier [108].

If future experimental studies confirm that VEGF collaborates with the mite to induce immunosuppression in rosacea, thus favoring *Demodex* proliferation, acaricidal treatment would then be clearly indicated in any patient with vascular symptoms of rosacea, and may contribute to prevent further evolution of ETR.

## CONCLUSION

The interactions among VEGF, *Demodex*, and the immune system need further exploration and the nosology of rosacea would then need to be adapted accordingly. The effectiveness of treating any patient with ETR first with an acaricidal cream needs to be assessed in prospective controlled clinical trials with long-term follow-up. Currently, learning to distinguish patients with pityriasis folliculorum from those with

isolated ETR is crucial so that they can be managed appropriately with an acaricidal cream.

## ACKNOWLEDGEMENTS

**Funding.** No funding was received for the study or publication of this article.

**Authorship.** All named authors meet the International Committee of Medical Journal Editors (ICMJE) criteria for authorship for this article, take responsibility for the integrity of the work as a whole, and have given their approval for this version to be published.

**Medical Writing and Editorial Assistance.** I thank Professor Sandra J. van Vliet (PhD, Department of Molecular Cell Biology and Immunology, Amsterdam UMC, PO Box 7057, 1007 MB Amsterdam, the Netherlands) for help with preparing Fig. 3, and Dr. K Pickett for editorial assistance.

**Disclosures.** Dr. Fabienne Forton occasionally works as a consultant for Galderma and has occasionally received payment for this work.

**Compliance with Ethics Guidelines.** This article is based on previously conducted studies and does not contain any new studies with human participants or animals performed by the author.

**Data Availability.** Data sharing is not applicable to this article as no datasets were generated or analyzed during the current study.

**Open Access.** This article is licensed under a Creative Commons Attribution-Non-Commercial 4.0 International License, which permits any non-commercial use, sharing, adaptation, distribution and reproduction in any medium or format, as long as you give appropriate credit to the original author(s) and the source, provide a link to the Creative Commons licence, and indicate if changes were made. The images or other third party material

in this article are included in the article's Creative Commons licence, unless indicated otherwise in a credit line to the material. If material is not included in the article's Creative Commons licence and your intended use is not permitted by statutory regulation or exceeds the permitted use, you will need to obtain permission directly from the copyright holder. To view a copy of this licence, visit <http://creativecommons.org/licenses/by-nc/4.0/>.

## REFERENCES

1. Tan J, Schöfer H, Araviiskaia E, et al. Prevalence of rosacea in the general population of Germany and Russia—the RISE study. *J Eur Acad Dermatol Venereol.* 2016;30:428–34.
2. Cribier B. Rosacée: nouveautés pour une meilleure prise en charge. *Ann Dermatol Venereol.* 2017;144: 508–17.
3. Berg M, Lidén S. An epidemiological study of rosacea. *Acta Derm Venereol.* 1989;69:419–23.
4. Gether L, Overgaard LK, Egeberg A, Thyssen JP. Incidence and prevalence of rosacea: a systematic review and meta-analysis. *Br J Dermatol.* 2018;179: 282–9.
5. Buddenkotte J, Steinhoff M. Recent advances in understanding and managing rosacea. *F1000Res.* 2018;7:F1000 Faculty Rev-1885.
6. Gallo RL, Granstein RD, Kang S, et al. Standard classification and pathophysiology of rosacea: the 2017 update by the National Rosacea Society Expert Committee. *J Am Acad Dermatol.* 2018;78:148–55.
7. Chen W, Plewig G. Human demodicosis: revisit and a proposed classification. *Br J Dermatol.* 2014;170: 1219–25.
8. Forton FM, Germaux M-AE, Thibaut SC, et al. Demodicosis: descriptive classification and status of Rosacea, in response to prior classification proposed. *J Eur Acad Dermatol Venereol.* 2015;29: 829–32.
9. Powell FC. Rosacea. In: Griffiths C, Barker J, Bleiker TO, Chalmers R, Creamer D, editors. *Rook's textbook of dermatology.* 9th ed. 2016. Chichester: Wiley; p. 1–20.
10. Forton FMN, De Maertelaer V. Papulopustular rosacea and rosacea-like demodicosis: two



- phenotypes of the same disease? *J Eur Acad Dermatol Venereol.* 2018;32:1011–6.
11. Saleem MD. Revisiting rosacea criteria. *Dermatol Clin.* 2018;36:161–5.
  12. Wilkin J, Dahl M, Detmar M, et al. Standard classification of rosacea: report of the National Rosacea Society Expert Committee on the Classification and Staging of Rosacea. *J Am Acad Dermatol.* 2002;46:584–7.
  13. Tan J, Almeida LMC, Bewley A, et al. Updating the diagnosis, classification and assessment of rosacea: recommendations from the global ROSacea COnsensus (ROSCO) panel. *Br J Dermatol.* 2017;176:431–8.
  14. Gerber PA, Buhren BA, Steinhoff M, Homey B. Rosacea: the cytokine and chemokine network. *J Investig Dermatol Symp Proc.* 2011;15:40–7.
  15. Yamasaki K, Di Nardo A, Bardan A, et al. Increased serine protease activity and cathelicidin promotes skin inflammation in rosacea. *Nat Med.* 2007;13:975–80.
  16. Yamasaki K, Gallo RL. The molecular pathology of rosacea. *J Dermatol Sci.* 2009;55:77–81.
  17. Yamasaki K, Gallo RL. Rosacea as a disease of cathelicidins and skin innate immunity. *J Investig Dermatol Symp Proc.* 2011;15:12–5.
  18. Yamasaki K, Kanada K, Macleod DT, et al. TLR2 expression is increased in rosacea and stimulates enhanced serine protease production by keratinocytes. *J Investig Dermatol.* 2011;131:688–97.
  19. Park K, Elias PM, Oda Y, et al. Regulation of cathelicidin antimicrobial peptide expression by an endoplasmic reticulum (ER) stress signaling, vitamin D receptor-independent pathway. *J Biol Chem.* 2011;286:34121–30.
  20. Kulkarni NN, Takahashi T, Sanford JA, et al. Innate immune dysfunction in rosacea promotes photosensitivity and vascular adhesion molecule expression. *J Invest Dermatol.* 2020;140(645–655):e6.
  21. Salzer S, Kresse S, Hirai Y, et al. Cathelicidin peptide LL-37 increases UVB-triggered inflammasome activation: possible implications for rosacea. *J Dermatol Sci.* 2014;76:173–9.
  22. Muto Y, Wang Z, Vanderberghe M, Two A, Gallo RL, Di Nardo A. Mast cells are key mediators of cathelicidin-initiated skin inflammation in rosacea. *J Investig Dermatol.* 2014;134:2728–36.
  23. Aldrich N, Gerstenblith M, Fu P, et al. Genetic vs environmental factors that correlate with rosacea: a cohort-based survey of twins. *JAMA Dermatol.* 2015;151:1213.
  24. Holmes AD, Spöndlin J, Chien AL, Baldwin H, Chang ALS. Evidence-based update on rosacea comorbidities and their common physiologic pathways. *J Am Acad Dermatol.* 2018;78:156–66.
  25. Aroni K, Tsagrani E, Lazaris AC, Patsouris E, Agapitos E. Rosacea: a clinicopathological approach. *Dermatology.* 2004;209:177–82.
  26. Goma AHA, Yaar M, Eyada MMK, Bhawan J. Lymphangiogenesis and angiogenesis in non-phy-matous rosacea. *J Cutan Pathol.* 2007;34:748–53.
  27. Cribier B. Pathophysiology of rosacea: redness, telangiectasia, and rosacea. *Ann Dermatol Venereol.* 2011;138:S184–91.
  28. Schwab VD, Sulk M, Seeliger S, et al. Neurovascular and neuroimmune aspects in the pathophysiology of rosacea. *J Investig Dermatol Symp Proc.* 2011;15:53–62.
  29. Casas C, Paul C, Lahfa M, et al. Quantification of *Demodex folliculorum* by PCR in rosacea and its relationship to skin innate immune activation. *Exp Dermatol.* 2012;21:906–10.
  30. Marks R, Harcourt-Webster JN. Histopathology of rosacea. *Arch Dermatol.* 1969;100:683–91.
  31. Cribier B. Rosacea under the microscope: characteristic histological findings. *J Eur Acad Dermatol Venereol.* 2013;27:1336–43.
  32. Powell FC. The histopathology of rosacea: ‘where’s the beef?’ *Dermatology.* 2004;209:173–4.
  33. Lee SH, Lee SB, Heo JH, et al. Sebaceous glands participate in the inflammation of rosacea. *J Eur Acad Dermatol Venereol.* 2020;34:e144–6.
  34. Georgala S, Katoulis A, Kylafis G, Koumantaki-Mathioudaki E, Georgala C, Aroni K. Increased density of *Demodex folliculorum* and evidence of delayed hypersensitivity reaction in subjects with papulopustular rosacea. *J Eur Acad Dermatol Venereol.* 2001;15:441–4.
  35. Ruffi T, Büchner SA. T-cell subsets in acne rosacea lesions and the possible role of *Demodex folliculorum*. *Dermatology.* 1984;169:1–5.
  36. Dajnoki Z, Béke G, Kapitány A, et al. Sebaceous gland-rich skin is characterized by TSLP expression and distinct immune surveillance which is disturbed in rosacea. *J Investig Dermatol.* 2017;137:1114–25.

37. Buhl T, Sulk M, Nowak P, et al. Molecular and morphological characterization of inflammatory infiltrate in rosacea reveals activation of Th1/Th17 pathways. *J Investig Dermatol.* 2015;135:2198–208.
38. Brown TT, Choi E-YK, Thomas DG, Hristov AC, Chan MP. Comparative analysis of rosacea and cutaneous lupus erythematosus: histopathologic features, T-cell subsets, and plasmacytoid dendritic cells. *J Am Acad Dermatol.* 2014;71:100–7.
39. Roihu T, Kariniemi A-L. Demodex mites in acne rosacea. *J Cutan Pathol.* 1998;25:550–2.
40. Helm KF, Menz J, Gibson LE, Dicken CH. A clinical and histopathologic study of granulomatous rosacea. *J Am Acad Dermatol.* 1991;25:1038–43.
41. Basta-Juzbasić A, Marinović T, Dobrić I, Bolanca-Bumber S, Sencar J. The possible role of skin surface lipid in rosacea with epitheloid granulomas. *Acta Med Croatica.* 1992;46:119–23.
42. Fuss F. La vie parasitaire du Demodex folliculorum hominis. *Ann Derm Syph (Paris).* 1933;4:1053–62.
43. Hellerich U, Metzelder M. Incidence of scalp involvement by *Demodex folliculorum* Simon ectoparasites in a pathologic-anatomic and forensic medicine autopsy sample. *Arch Kriminol.* 1994;194:111–8.
44. Ruffi T, Mumcuoglu Y. The hair follicle mites Demodex folliculorum and Demodex brevis: biology and medical importance. *Dermatology.* 1981;162:1–11.
45. Riechers R, Kopf AW. Cutaneous infestation with *Demodex folliculorum* in man. *J Invest Dermatol.* 1969;52:103–6.
46. Nutting WB. Hair follicle mites (Acari: Demodicidae) of man. *Int J Dermatol.* 1976;15:79–98.
47. Thoenes MS, Fergus DJ, Urban J, Trautwein M, Dunn RR. Ubiquity and diversity of human-associated Demodex mites. *PLoS One.* 2014;9:e106265.
48. Desch C, Nutting WB. *Demodex folliculorum* (Simon) and *D. brevis* akbulatova of man: redescription and reevaluation. *J Parasitol.* 1972;58:169–77.
49. Norm MS. *Demodex folliculorum*. Incidence, regional distribution, pathogenicity. *Dan Med Bull.* 1971;18:14–7.
50. Du Bois C. Recherche du Demodex folliculorum hominis dans la peau saine. *Ann Dermatol Syph.* 1910;1:188–90.
51. Zhao Y, Guo N, Xun M, Xu J, Wang M, Wang D. Sociodemographic characteristics and risk factor analysis of Demodex infestation (Acari: Demodicidae). *J Zhejiang Univ Sci B.* 2011;12:998–1007.
52. Nutting WB, Green AC. Pathogenesis associated with hair follicle mites (*Demodex* spp.) in Australian Aborigines. *Br J Dermatol.* 1976;94:307–12.
53. Nutting WB, Beerman H. Demodicosis and symbiophobia: status, terminology, and treatments. *Int J Dermatol.* 1983;22:13–7.
54. Gmeiner F. Demodex folliculorum des Menschen und der Tiere. *Arch Derm Syphilol.* 1908;92:25–96.
55. Palopoli MF, Fergus DJ, Minot S, et al. Global divergence of the human follicle mite *Demodex folliculorum*: persistent associations between host ancestry and mite lineages. *Proc Natl Acad Sci USA.* 2015;112:15958–63.
56. Forton F, Germaux M-A, Brasseur T, et al. Demodicosis and rosacea: epidemiology and significance in daily dermatologic practice. *J Am Acad Dermatol.* 2005;52:74–87.
57. Forton FMN. Papulopustular rosacea, skin immunity and Demodex: pityriasis folliculorum as a missing link. *J Eur Acad Dermatol Venereol.* 2012;26:19–28.
58. Lacey N, Russell-Hallinan A, Zouboulis CC, Powell FC. Demodex mites modulate sebocyte immune reaction: possible role in the pathogenesis of rosacea. *Br J Dermatol.* 2018;179:420–30.
59. Akilov O, Mumcuoglu K. Immune response in demodicosis. *J Eur Acad Dermatol Venereol.* 2004;18:440–4.
60. Foley R, Kelly P, Gatault S, Powell F. Demodex: a skin resident in man and his best friend. *J Eur Acad Dermatol Venereol.* 2020. <https://doi.org/10.1111/jdv.16461>.
61. Seyhan M, Karıncaoglu Y, Bayram N, Aycan O, Kuku I. Density of *Demodex folliculorum* in haematological malignancies. *J Int Med Res.* 2004;32:411–5.
62. Karıncaoglu Y, Esrefoglu Seyhan M, Bayram N, Aycan O, Taskapan H. Incidence of *Demodex folliculorum* in patients with end stage chronic renal failure. *Ren Fail.* 2005;27:495–9.
63. Sanchez-Viera M, Hernanz JM, Sampelayo T, Gurbindo MD, Lecona M, Soto-Melo J. Granulomatous rosacea in a child infected with the human immunodeficiency virus. *J Am Acad Dermatol.* 1992;27:1010–1.
64. Sahn EE, Sheridan DM. Demodicosis in a child with leukemia. *J Am Acad Dermatol.* 1992;27:799–801.

65. Barrio J, Lecona M, Hernanz JM, et al. Rosacea-like demodicosis in an HIV-positive child. *Dermatology (Basel)*. 1996;192:143–5.
66. Benessahraoui M, Paratte F, Plouvier E, Humbert P, Aubin F. Demodicidosis in a child with xantholeukaemia associated with type 1 neurofibromatosis. *Eur J Dermatol*. 2003;13:311–2.
67. Morrás PG, Santos SP, Imedio IL, Echeverría ML, Hermosa JMH. Rosacea-like demodicidosis in an immunocompromised child. *Pediatr Dermatol*. 2003;20:28–30.
68. Herron MD, O'reilly MA, Vanderhooft SL. Refractory Demodex folliculitis in five children with acute lymphoblastic leukemia. *Pediatr Dermatol*. 2005;22:407–11.
69. Damian D, Rogers M. Demodex infestation in a child with leukaemia: treatment with ivermectin and permethrin. *Int J Dermatol*. 2003;42:724–6.
70. Bañuls J, Ramon D, Aniz E, Jorda E, Torres V. Papular pruritic eruption with human immunodeficiency virus infection. *Int J Dermatol*. 1991;30:801–3.
71. Jansen T, Kastner U, Kreuter A, Altmeyer P. Rosacea-like demodicidosis associated with acquired immunodeficiency syndrome. *Br J Dermatol*. 2001;144:139–42.
72. de Jaureguiberry JP, Carsuzaa F, Pierre C, Arnoux D, Jaubert D. Demodex folliculitis: a cause of pruritus in human immunodeficiency virus infection. *Ann Med Interne (Paris)*. 1993;144:63–4.
73. Dominey A, Rosen T, Tschen J. Papulonodular demodicidosis associated with acquired immunodeficiency syndrome. *J Am Acad Dermatol*. 1989;20:197–201.
74. Ashack RJ, Frost ML, Norins AL. Papular pruritic eruption of Demodex folliculitis in patients with acquired immunodeficiency syndrome. *J Am Acad Dermatol*. 1989;21:306–7.
75. Nakagawa T, Sasaki M, Fujita K, Nishimoto M, Takaiwa T. Demodex folliculitis on the trunk of a patient with mycosis fungoides. *Clin Exp Dermatol*. 1996;21:148–50.
76. Redondo Mateo J, Soto Guzmán O, Fernández Rubio E, Domínguez FF. Demodex-attributed rosacea-like lesions in AIDS. *Acta Derm Venereol*. 1993;73:437.
77. Aquilina C, Viraben R, Sire S. Ivermectin-responsive Demodex infestation during human immunodeficiency virus infection. *Dermatology*. 2002;205:394–7.
78. Patrizi A, Trestini D, D'Antuono A, Colangeli V. Demodicidosis in a child infected with acquired immunodeficiency virus. *Eur J Pediatr Dermatol*. 1999;9:25–8.
79. Duvic M. Staphylococcal infections and the pruritus of AIDS-related complex. *Arch Dermatol*. 1987;123:1599.
80. Girault C, Borsa-Lebas F, Lecomte F, Humbert G. Papulonodular eruption. Demodicidosis in acquired immunodeficiency syndrome. *Presse Med*. 1991;20:177.
81. Sarro RA, Hong JJ, Elgart ML. An unusual demodicidosis manifestation in a patient with AIDS. *J Am Acad Dermatol*. 1998;38:120–1.
82. Antille C, Saurat J-H, Lübke J. Induction of rosaceaiform dermatitis during treatment of facial inflammatory dermatoses with tacrolimus ointment. *Arch Dermatol*. 2004;140:457–60.
83. Lübke J, Stucky L, Saurat J-H. Rosaceaiform dermatitis with follicular Demodex after treatment of facial atopic dermatitis with 1% pimecrolimus cream. *Dermatology*. 2003;207:205–7.
84. Kaya OA, Akkucuk S, Ilhan G, Guneri CO, Mumcuoglu K. The importance of Demodex mites (Acari: Demodicidae) in patients with sickle cell anemia. *J Med Entomol*. 2019;56:599–602.
85. Kaya S, Selimoglu MA, Kaya OA, Ozgen U. Prevalence of *Demodex folliculorum* and *Demodex brevis* in childhood malnutrition and malignancy: *Demodex* in malnutrition and malignancy. *Pediatr Int*. 2013;55:85–9.
86. Gerber PA, Kukova G, Buhren BA, Homey B. Density of *Demodex folliculorum* in patients receiving epidermal growth factor receptor inhibitors. *Dermatology*. 2011;222:144–7.
87. Molho-Pessach V, Meltser A, Kamshov A, Ramot Y, Zlotogorski A. *STAT1* gain-of-function and chronic demodicosis. *Pediatr Dermatol*. 2020;37:153–5.
88. Sáez-de-Ocariz M, Suárez-Gutiérrez M, Migaud M, et al. Rosacea as a striking feature in family members with a *STAT1* gain-of-function mutation. *J Eur Acad Dermatol Venereol*. 2020;34(6):e265–7.
89. Akdeniz S, Bahceci M, Tuzcu A, Harman M, Alp S, Bahceci S. Is Demodex folliculorum larger in diabetic patients? *J Eur Acad Dermatol Venereol*. 2002;16:539–41.
90. Clifford CW, Fulk GW. Association of diabetes, lash loss, and *Staphylococcus aureus* with infestation of eyelids by *Demodex folliculorum* (Acari: Demodicidae). *J Med Entomol*. 1990;27:467–70.

91. Gökçe C, Aycan-Kaya Ö, Yula E, et al. The effect of blood glucose regulation on the presence of opportunistic *Demodex folliculorum* mites in patients with type 2 diabetes mellitus. *J Int Med Res*. 2013;41:1752–8.
92. Keskin Kurt R, Aycan Kaya O, Karateke A, et al. Increased density of *Demodex folliculorum* mites in pregnancies with gestational diabetes. *Med Princ Pract*. 2014;23:369–72.
93. Two AM, Wu W, Gallo RL, Hata TR. Rosacea: part I. Introduction, categorization, histology, pathogenesis, and risk factors. *J Am Acad Dermatol*. 2015;72:749–58.
94. Perrigouard C, Peltre B, Cribier B. A histological and immunohistological study of vascular and inflammatory changes in rosacea. *Ann Dermatol Venereol*. 2013;140:21–9.
95. Turgut Erdemir A, Gurel MS, Koku Aksu AE, Falay T, Inan Yuksel E, Sarikaya E. Demodex mites in acne rosacea: reflectance confocal microscopic study. *Australas J Dermatol*. 2017;58:e26–30.
96. Katz AM. Rosacea: epidemiology and pathogenesis. *J Cutan Med Surg*. 1998;2(Suppl 4):5–10.
97. Forton F, De Maertelaer V. Erythematotelangiectatic rosacea may be associated with a subclinical stage of demodicosis: a case–control study. *Br J Dermatol*. 2019;181:818–25.
98. Zhao Y, Peng Y, Wang X, et al. Facial dermatosis associated with Demodex: a case-control study. *J Zhejiang Univ Sci B*. 2011;12:1008–15.
99. Forton FMN, De Maertelaer V. Rosacea and demodicosis: little-known diagnostic signs and symptoms. *Acta Derm Venereol*. 2019b;99:47–52.
100. Crosti C, Menni S, Sala F, Piccinno R. Demodectic infestation of the pilosebaceous follicle. *J Cutan Pathol*. 1983;10:257–61.
101. Ayres S. Pityriasis folliculorum (Demodex). *Arch Derm Syphilol*. 1930;21:19–24.
102. Ayres S. demodectic eruptions (demodicidosis) in the human: 30 years' experience with 2 commonly unrecognized entities: pityriasis folliculorum (Demodex) and acne rosacea (Demodex type). *Arch Dermatol*. 1961;83:816.
103. Dominey A, Tschen J, Rosen T, Batres E, Stern JK. Pityriasis folliculorum revisited. *J Am Acad Dermatol*. 1989;21:81–4.
104. Hsu C-K, Hsu MM-L, Lee JY-Y. Demodicosis: a clinicopathological study. *J Am Acad Dermatol*. 2009;60:453–62.
105. Ayres S. Rosacea and rosacea-like demodicidosis. *Int J Dermatol*. 1987;26:198–9.
106. Turgut Erdemir A, Gurel MS, Koku Aksu AE, et al. Reflectance confocal microscopy vs. standardized skin surface biopsy for measuring the density of Demodex mites. *Skin Res Technol*. 2014;20:435–9.
107. Yun CH, Yun JH, Baek JO, Roh JY, Lee JR. Demodex mite density determinations by standardized skin surface biopsy and direct microscopic examination and their relations with clinical types and distribution patterns. *Ann Dermatol*. 2017;29:137.
108. Forton FMN, De Maertelaer V. Two consecutive standardized skin surface biopsies: an improved sampling method to evaluate Demodex density as a diagnostic tool for rosacea and demodicosis. *Acta Derm Venereol*. 2017;97:242–8.
109. Forton FMN. Elucidating the role of *Demodex folliculorum* in the pathogenesis of rosacea: exciting first steps.... *Br J Dermatol*. 2018;179:252–3.
110. Forton F. Demodex and perifollicular inflammation in man: review and report of 69 biopsies. *Ann Dermatol Venereol*. 1986;113:1047–58.
111. Forton F, De Maertelaer V. Rosacea-like demodicosis and papulopustular rosacea may be two phenotypes of the same disease, and pityriasis folliculorum may be their precursor: response to the comment of Tatu. *J Eur Acad Dermatol Venereol*. 2019c;33:e47–8.
112. Tatu AL, Clatici VG, Nwabudike LC. Rosacea-like demodicosis (but not primary demodicosis) and papulopustular rosacea may be two phenotypes of the same disease—a microbioma, therapeutic and diagnostic tools perspective. *J Eur Acad Dermatol Venereol*. 2019;33:e46–7.
113. Ayres S. Rosacea-like demodicidosis. *Calif Med*. 1963;98:328–30.
114. Ayres S, Mihan R. Rosacea-like demodicidosis involving the eyelids. A case report. *Arch Dermatol*. 1967;95:63–6.
115. Post CF, Juhlin E. Demodex folliculorum and blepharitis. *Arch Dermatol*. 1963;88:298–302.
116. Morgan RJ, Coston TO. Demodex blepharitis. *South Med J*. 1964;57:694–9.
117. Kim JH, Chun YS, Kim JC. Clinical and immunological responses in ocular demodecosis. *J Korean Med Sci*. 2011;26:1231–7.
118. Liu J, Sheha H, Tseng SCG. Pathogenic role of Demodex mites in blepharitis. *Curr Opin Allergy Clin Immunol*. 2010;10:505–10.

119. Purcell SM, Hayes TJ, Dixon SL. Pustular folliculitis associated with *Demodex folliculorum*. J Am Acad Dermatol. 1986;15:1159–62.
120. Eismann R, Bramsiede I, Danz B, Wohlrab J, Marsch WC, Fiedler E. Abscessing nodular demodicosis—therapy with ivermectin and permethrin. J Eur Acad Dermatol Venereol. 2010;24:79–81.
121. Schaller M, Sander CA, Plewig G. Demodex abscesses: clinical and therapeutic challenges. J Am Acad Dermatol. 2003;49:272–4.
122. Seifert HW. Demodex folliculorum causing solitary tuberculoid granuloma. Z Hautkr. 1978;53:540–2.
123. Woo Y, Lim J, Cho D, Park H. Rosacea: molecular mechanisms and management of a chronic cutaneous inflammatory condition. Int J Mol Sci. 2016;17:1562.
124. Thyssen JP. Are Demodex mites the best target for rosacea treatments? Br J Dermatol. 2019;181:652–3.
125. Baima B, Sticherling M. Demodicidosis revisited. Acta Derm Venereol. 2002;82:3–6.
126. Holmes AD. Potential role of microorganisms in the pathogenesis of rosacea. J Am Acad Dermatol. 2013;69:1025–32.
127. Vemuri RC, Gundamaraju R, Sekaran SD, Manikam R. Major pathophysiological correlations of rosacea: a complete clinical appraisal. Int J Med Sci. 2015;12:387–96.
128. Grosshans E, Kremer M, Maleville J, Wanner R. Du rôle des Demodex folliculorum dans l'histogénèse de la rosacée granulomateuse. Bull Soc Fr Dermatol Syphiligr. 1972;79:639–46.
129. Amichai B, Grunwald MH, Avinoach I, Halevy S. Granulomatous rosacea associated with *Demodex folliculorum*. Int J Dermatol. 1992;31:718–9.
130. Ecker RI, Winkelmann RK. Demodex granuloma. Arch Dermatol. 1979;115:343–4.
131. Kharfi M, Zarrouk H, Nikkels A, et al. Granulomatous rosacea and demodicidosis. Afr J Dermatol. 1991;4:39–43.
132. Forton F, Seys B. Density of *Demodex folliculorum* in rosacea: a case-control study using standardized skin-surface biopsy. Br J Dermatol. 1993;128:650–9.
133. Erbagci Z, Özgöztaşı O. The significance of *Demodex folliculorum* density in rosacea. Int J Dermatol. 1998;37:421–5.
134. Chang Y-S, Huang Y-C. Role of Demodex mite infestation in rosacea: a systematic review and meta-analysis. J Am Acad Dermatol. 2017;77:441–7.
135. Jarmuda S, McMahon F, Żaba R, et al. Correlation between serum reactivity to Demodex-associated Bacillus oleronius proteins, and altered sebum levels and Demodex populations in erythematotelangiectatic rosacea patients. J Med Microbiol. 2014;63:258–62.
136. Tan J, Blume-Peytavi U, Ortonne JP, et al. An observational cross-sectional survey of rosacea: clinical associations and progression between subtypes. Br J Dermatol. 2013;169:555–62.
137. Parodi A, Guarrera M, Rebora A. Flushing in rosacea: an experimental approach. Arch Dermatol Res. 1980;269:269–73.
138. Guzman-Sanchez DA, Ishiujji Y, Patel T, Fountain J, Chan YH, Yosipovitch G. Enhanced skin blood flow and sensitivity to noxious heat stimuli in papulopustular rosacea. J Am Acad Dermatol. 2007;57:800–5.
139. Voron T, Marcheteau E, Pernot S, et al. Control of the immune response by pro-angiogenic factors. Front Oncol. 2014;4:70.
140. Voron T, Tartour É, Taieb J, Terme M. Rôle du VEGF dans l'épuisement des lymphocytes T intratumoraux. Med Sci (Paris). 2015;31:473–5.
141. Smith JR, Lanier VB, Braziel RM, Falkenhagen KM, White C, Rosenbaum JT. Expression of vascular endothelial growth factor and its receptors in rosacea. Br J Ophthalmol. 2007;91:226–9.
142. Gazi U, Gureser AS, Oztekin A, et al. Skin-homing T-cell responses associated with Demodex infestation and rosacea. Parasite Immunol. 2019;41:e12658.
143. Fornasa G, Tsilingiri K, Caprioli F, et al. Dichotomy of short and long thymic stromal lymphopoietin isoforms in inflammatory disorders of the bowel and skin. J Allergy Clin Immunol. 2015;136:413–22.
144. Allakhverdi Z, Comeau MR, Jessup HK, et al. Thymic stromal lymphopoietin is released by human epithelial cells in response to microbes, trauma, or inflammation and potentially activates mast cells. J Exp Med. 2007;204:253–8.
145. Sim WJ, Ahl PJ, Connolly JE. Metabolism is central to tolerogenic dendritic cell function. Mediat Inflamm. 2016;2016:2636701.
146. Hong JS, Han S, Lee JS, et al. Abnormal glucocorticoid synthesis in the lesional skin of

- erythematotelangiectatic rosacea. *J Investig Dermatol.* 2019;139(2225–2228):e3.
147. Kanitakis J, Al-Rifai I, Faure M, Claudy A. Demodex mites of human skin express Tn but not T (Thomsen-Friedenreich) antigen immunoreactivity. *J Cutan Pathol.* 1997;24:454–5.
148. Zaal A, Li RJE, Lübbbers J, et al. Activation of the C-type lectin MGL by terminal GalNAc ligands reduces the glycolytic activity of human dendritic cells. *Front Immunol.* 2020;11:305.
149. van Vliet SJ, van Liempt E, Geijtenbeek TBH, van Kooyk Y. Differential regulation of C-type lectin expression on tolerogenic dendritic cell subsets. *Immunobiology.* 2006;211:577–85.
150. van Vliet SJ, Gringhuis SI, Geijtenbeek TBH, van Kooyk Y. Regulation of effector T cells by antigen-presenting cells via interaction of the C-type lectin MGL with CD45. *Nat Immunol.* 2006;7:1200–8.
151. van Vliet SJ, Bay S, Vuist IM, et al. MGL signaling augments TLR2-mediated responses for enhanced IL-10 and TNF- $\alpha$  secretion. *J Leukoc Biol.* 2013;94:315–23.
152. Li D, Romain G, Flamar A-L, et al. Targeting self- and foreign antigens to dendritic cells via DC-ASGPR generates IL-10-producing suppressive CD4+ T cells. *J Exp Med.* 2012;209:109–21.
153. Ferrer L, Ravera I, Silbermayr K. Immunology and pathogenesis of canine demodicosis. *Vet Dermatol.* 2014;25:427–e65.
154. Bates J, Diehl L. Dendritic cells in IBD pathogenesis: an area of therapeutic opportunity? *J Pathol.* 2014;232:112–20.
155. Marson JW, Baldwin HE. Rosacea: a wholistic review and update from pathogenesis to diagnosis and therapy. *Int J Dermatol.* 2019;59(6):e175–82.
156. Huang H-P, Hsu C-K, Lee JY-Y. Thumbnail-squeezing method: an effective method for assessing Demodex density in rosacea. *J Eur Acad Dermatol Venereol.* 2020;34:e343–5.
157. Sibenge S, Gawkrödger DJ. Rosacea: a study of clinical patterns, blood flow, and the role of *Demodex folliculorum*. *J Am Acad Dermatol.* 1992;26:590–3.
158. Saleem MD, Wilkin JK. Evaluating and optimizing the diagnosis of erythematotelangiectatic rosacea. *Dermatol Clin.* 2018;36:127–34.
159. Forton FMN, De Maertelaer V. Treatment of rosacea and demodicosis with benzyl benzoate: effects of different doses on Demodex density and clinical symptoms. *J Eur Acad Dermatol Venereol.* 2020;34:365–9.
160. Forton FMN, De Maertelaer V. Effectiveness of benzyl benzoate treatment on clinical symptoms and Demodex density over time in patients with rosacea and demodicosis: a real life retrospective follow-up study comparing low- and high-dose regimens. *J Dermatolog Treat.* 2020;1–28. <https://doi.org/10.1080/09546634.2020.1770168>.
161. Bonnar E, Eustace P, Powell FC. The Demodex mite population in rosacea. *J Am Acad Dermatol.* 1993;28:443–8.
162. Abd-El-Al AM, Bayoumy AM, Abou Salem EA. A study on Demodex folliculorum in rosacea. *J Egypt Soc Parasitol.* 1997;27:183–95.
163. el-Shazly AM, Ghaneum BM, Morsy TA, Aaty HE. The pathogenesis of Demodex folliculorum (hair follicular mites) in females with and without rosacea. *J Egypt Soc Parasitol.* 2001;31:867–75.
164. Zhao YE, Wu LP, Peng Y, Cheng H. Retrospective analysis of the association between Demodex infestation and rosacea. *Arch Dermatol.* 2010;146:896–902.
165. Falay Gur T, Erdemir AV, Gurel MS, Kocyigit A, Guler EM, Erdil D. The investigation of the relationships of Demodex density with inflammatory response and oxidative stress in rosacea. *Arch Dermatol Res.* 2018;310:759–67.
166. Sattler EC, Maier T, Hoffmann VS, Hegyi J, Ruzicka T, Berking C. Noninvasive in vivo detection and quantification of *Demodex* mites by confocal laser scanning microscopy: quantification of *Demodex* mites by CLSM. *Br J Dermatol.* 2012;167:1042–7.
167. Tsutsumi Y. Deposition of IgD, alpha-1-antitrypsin and alpha-1-antichymotrypsin on *Demodex folliculorum* and *D. brevis* infesting the pilosebaceous unit. *Pathol Int.* 2004;54:32–4.
168. Bonamigo R, Bakos L, Edelweiss M, Cartell A. Could matrix metalloproteinase-9 be a link between *Demodex folliculorum* and rosacea? *J Eur Acad Dermatol Venereol.* 2005;19:646–7.
169. Grosshans EM, Kremer M, Maleville J. *Demodex folliculorum* and the histogenesis of granulomatous rosacea. *Hautarzt.* 1974;25:166–77.
170. Aylesworth R, Vance JC. *Demodex folliculorum* and *Demodex brevis* in cutaneous biopsies. *J Am Acad Dermatol.* 1982;7:583–9.
171. Darji K, Burkemper NM. Pityriasis folliculorum: response to topical ivermectin. *J Drugs Dermatol.* 2017;16:1290–2.

172. Schaller M, Gonser L, Belge K, et al. Dual anti-inflammatory and anti-parasitic action of topical ivermectin 1% in papulopustular rosacea. *J Eur Acad Dermatol Venereol*. 2017;31:1907–11.
173. Steinhoff M, Vocanson M, Voegel JJ, Hacini-Rachinel F, Schäfer G. Topical ivermectin 10 mg/g and oral doxycycline 40 mg modified-release: current evidence on the complementary use of anti-inflammatory rosacea treatments. *Adv Ther*. 2016;33:1481–501.
174. Gallo RL, Granstein RD, Kang S, et al. Rosacea comorbidities and future research: the 2017 update by the National Rosacea Society Expert Committee. *J Am Acad Dermatol*. 2018;78:167–70.
175. Berg M, Edström DW. Flashlamp pulsed dye laser (FPDL) did not cure papulopustular rosacea. *Lasers Surg Med*. 2004;34:266–8.
176. Osman M, Shokeir HA, Hassan AM, Atef Khalifa M. Pulsed dye laser alone versus its combination with topical ivermectin 1% in treatment of Rosacea: a randomized comparative study. *J Dermatolog Treat*. 2020;1–7. <https://doi.org/10.1080/09546634.2020.1737636>.
177. Say EM, Okan G, Gökdemir G. Treatment outcomes of long-pulsed Nd:YAG laser for two different subtypes of rosacea. *J Clin Aesthet Dermatol*. 2015;8:16–20.
178. Ertaş R, Yaman O, Akkuş MR, et al. The rapid effect of pulsed dye laser on Demodex density of facial skin. *J Cosmet Laser Ther*. 2019;21:123–6.
179. Prieto VG, Sadick NS, Lloreta J, Nicholson J, Shea CR. Effects of intense pulsed light on sun-damaged human skin, routine, and ultrastructural analysis. *Lasers Surg Med*. 2002;30:82–5.
180. Luo Y, Sun Y-J, Zhang L, Luan X-L. Treatment of mites folliculitis with an ornidazole-based sequential therapy: a randomized trial. *Medicine*. 2016;95:e4173.
181. Luo Y, Luan X-L, Zhang J-H, Wu L-X, Zhou N. Improved telangiectasia and reduced recurrence rate of rosacea after treatment with 540 nm-wave-length intense pulsed light: a prospective randomized controlled trial with a 2-year follow-up. *Exp Ther Med*. 2020;19:3543–50.
182. Wang P, Zhang L, Shi L, Yuan C, Zhang G, Wang X. Latent Demodex infection contributes to intense pulsed light aggravated rosacea: cases serial. *J Cosmet Laser Ther*. 2019;21:163–5.
183. van Zuuren EJ. Rosacea. *N Engl J Med*. 2017;377:1754–64.
184. van Zuuren EJ, Fedorowicz Z, Tan J, et al. Interventions for rosacea based on the phenotype approach: an updated systematic review including GRADE assessments. *Br J Dermatol*. 2019;181:65–79.
185. Del Rosso JQ, Tanghetti E, Webster G, Stein Gold L, Thiboutot D, Gallo RL. Update on the management of rosacea from the American Acne & Rosacea Society (AARS). *J Clin Aesthet Dermatol*. 2019;12:17–24.
186. Ayres S, Anderson NP. Acne rosacea: response to local treatment for Demodex folliculorum. *JAMA*. 1933;100:645–7.
187. Hojyo Tomoka MT, Dominguez Soto L. Demodectidosis y dermatitis rosaceiforme. *Med Cutan Ibero Lat Am*. 1976;4:83–90.
188. Ayres S, Mihan R. Demodex granuloma. *Arch Dermatol*. 1979;115:1285–6.
189. Pietrini P, Favennec L, Brasseur P. Demodex folliculorum in parakeratosis of the scalp in a child. *Parasite*. 1995;2:94.
190. Patrizi A, Neri I, Chieregato C, Misciali M. Demodicidosis in immunocompetent young children: report of eight cases. *Dermatology (Basel)*. 1997;195:239–42.
191. Junk AK, Lukacs A, Kampik A. Topical administration of metronidazole gel as an effective therapy alternative in chronic Demodex blepharitis—a case report. *Klin Monbl Augenheilkd*. 1998;213:48–50.
192. Ivy SP, Mackall CL, Gore L, Gress RE, Hartley AH. Demodicidosis in childhood acute lymphoblastic leukemia; an opportunistic infection occurring with immunosuppression. *J Pediatr*. 1995;127:751–4.
193. Fulk GW, Murphy B, Robins MD. Pilocarpine gel for the treatment of demodicosis—a case series. *Optom Vis Sci*. 1996;73:742–5.
194. Celorio J, Fariza-Guttmann E, Morales V. Pilocarpine as a coadjuvant treatment of blepharoconjunctivitis caused by Demodex folliculorum. *Invest Ophthalmol Vis Sci*. 1988;30(suppl):40.
195. Harmelin Y, Delaunay P, Erfan N, Tsilika K, Zorzi K, Passeron T, Lacour JP, Bahadoran P. Interest of confocal laser scanning microscopy for the diagnosis and treatment monitoring of demodicosis. *J Eur Acad Dermatol Venerol*. 2014; 28(2):255–7.
196. Rufli T, Mumcuoglu Y, Cajacob A, Büchner S. *Demodex folliculorum*: aetiopathogenesis and therapy of rosacea and perioral dermatitis (author's transl). *Dermatologica*. 1981;162:12–26.

197. Hoekzema R, Hulsebosch HJ, Bos JD. Demodicidosis or rosacea: what did we treat? *Br J Dermatol*. 1995;133:294–9.
198. Varotti C, Ghetti P, Negosanti M, Passarini B. *Demodex folliculorum* ed acne rosacea. *G Ital Dermatol Venereol*. 1981;116:489–91.
199. De Dulanto F, Camacho-Martinez F. Demodicidosis gravis. *Ann Dermatol Venereol*. 1979;106:699–704.
200. Forstinger C, Kittler H, Binder M. Treatment of rosacea-like demodicidosis with oral ivermectin and topical permethrin cream. *J Am Acad Dermatol*. 1999;41:775–7.
201. Kito Y, Hashizume H, Tokura Y. Rosacea-like demodicidosis mimicking cutaneous lymphoma. *Acta Derm Venerol*. 2012;92:169–70.
202. García-Vargas A, Mayorga-Rodríguez JA, Sandoval-Tress C. Scalp demodicidosis mimicking favus in a 6-year-old boy. *J Am Acad Dermatol*. 2007;57:S19–21.
203. Aydogan K, Alver O, Tore O, Karadogan S. Facial abscess-like conglomerates associated with *Demodex* mites. *J Eur Acad Dermatol Venerol*. 2006;20(8):1002–4.
204. Shelley WB, Shelley ED, Burmeister V. Unilateral demodectic rosacea. *J Am Acad Dermatol*. 1989;20:915–7.
205. Bikowski JB, Del Rosso JQ. *Demodex* dermatitis: a retrospective analysis of clinical diagnosis and successful treatment with topical crotamiton. *J Clin Aesthet Dermatol*. 2009;2:20–5.
206. Brown M, Hernández-Martín A, Clement A, Colmenero I, Torrelo A. Severe *Demodex folliculorum*-associated oculocutaneous rosacea in a girl successfully treated with ivermectin. *JAMA Dermatol*. 2014;150:61.
207. Vashisht D, Singh J, Baveja S, Tiwari R, Bhatnagar A. Unilateral demodicidosis of face mimicking Hansen disease. *Dermatol Reports*. 2016;8:6891.
208. Pallotta S, Cianchini G, Martelloni E, et al. Unilateral demodicidosis. *Eur J Dermatol*. 1998;8:191–2.
209. Norn MS. *Demodex folliculorum*. Incidence and possible pathogenic role in the human eyelid. *Acta Ophthalmol Suppl*. 1970;108:7–85.
210. Gao Y-Y, Di Pascuale MA, Li W, et al. In vitro and in vivo killing of ocular *Demodex* by tea tree oil. *Br J Ophthalmol*. 2005;89:1468–73.
211. Kabat AG. In vitro demodicidal activity of commercial lid hygiene products. *Clin Ophthalmol*. 2019;13:1493–7.
212. Tighe S, Gao Y-Y, Tseng SCG. Terpinen-4-ol is the most active ingredient of tea tree oil to kill *Demodex* mites. *Trans Vis Sci Tech*. 2013;2:2.
213. Persi A, Rebora A. Metronidazole and *Demodex folliculorum*. *Acta Derm Venereol*. 1981;61:182–3.
214. Koo H, Kim TH, Kim KW, Wee SW, Chun YS, Kim JC. Ocular surface discomfort and *Demodex*: effect of tea tree oil eyelid scrub in *Demodex blepharitis*. *J Korean Med Sci*. 2012;27:1574–9.
215. Evren Kemer Ö, Karaca EE, Özek D. Efficacy of cyclic therapy with terpinen-4-ol in *Demodex blepharitis*: Is treatment possible by considering *Demodex*'s life cycle? *Eur J Ophthalmol*. 2020;1120672120919085.
216. Lam NSK, Long XX, Griffin RC, Chen M-K, Doery JC. Can the tea tree oil (Australian native plant: *Melaleuca alternifolia* Cheel) be an alternative treatment for human demodicosis on skin? *Parasitology*. 2018;145:1510–20.
217. Persi A, Rebora A. Metronidazole in the treatment of rosacea. *Arch Dermatol*. 1985;121:307–8.
218. Forton S, Marchal S. *Demodex folliculorum* and topical treatment: acaricidal action evaluated by standardized skin surface biopsy. *Br J Dermatol*. 1998;138:461–6.
219. Salem DAB, El-Shazly A, Nabih N, El-Bayoumy Y, Saleh S. Evaluation of the efficacy of oral ivermectin in comparison with ivermectin-metronidazole combined therapy in the treatment of ocular and skin lesions of *Demodex folliculorum*. *Int J Infect Dis*. 2013;17:e343–7.
220. Raoufinejad K, Mansouri P, Rajabi M, Naraghi Z, Jebraeili R. Efficacy and safety of permethrin 5% topical gel vs. placebo for rosacea: a double-blind randomized controlled clinical trial. *J Eur Acad Dermatol Venereol*. 2016;30:2105–17.
221. Koçak M, Yağlı S, Vahapoğlu G, Ekşioğlu M. Permethrin 5% cream versus metronidazole 0.75% gel for the treatment of papulopustular rosacea. A randomized double-blind placebo-controlled study. *Dermatology (Basel)*. 2002;205:265–70.
222. Jacob S, VanDaele MA, Brown JN. Treatment of *Demodex*-associated inflammatory skin conditions: a systematic review. *Dermatol Ther*. 2019;32:e13103.
223. Siddiqui K, Gold LS, Gill J. The efficacy, safety, and tolerability of ivermectin compared with current topical treatments for the inflammatory lesions of



- rosacea: a network meta-analysis. SpringerPlus. 2016;5:1151.
224. Stein Gold L, Kircik L, Fowler J, et al. Long-term safety of ivermectin 1% cream vs azelaic acid 15% gel in treating inflammatory lesions of rosacea: results of two 40-week controlled, investigator-blinded trials. *J Drugs Dermatol*. 2014;13:1380–6.
225. Ali ST, Alinia H, Feldman SR. The treatment of rosacea with topical ivermectin. *Drugs Today*. 2015;51:243.
226. Taieb A, Ortonne JP, Ruzicka T, et al. Superiority of ivermectin 1% cream over metronidazole 0.75% cream in treating inflammatory lesions of rosacea: a randomized, investigator-blinded trial. *Br J Dermatol*. 2015;172:1103–10.
227. Schaller M, Dirschka T, Kemény L, Briantais P, Jacovella J. Superior efficacy with ivermectin 1% cream compared to metronidazole 0.75% cream contributes to a better quality of life in patients with severe papulopustular rosacea: a subanalysis of the randomized, investigator-blinded ATTRACT study. *Dermatol Ther (Heidelb)*. 2016;6:427–36.
228. Schaller M, Schöfer H, Homey B, et al. Rosacea management: update on general measures and topical treatment options. *J Dtsch Dermatol Ges*. 2016;14(Suppl 6):17–27.
229. van Zuuren EJ, van der Linden MMD, Arents BWM. Rosacea treatment guideline for the Netherlands. *Br J Dermatol*. 2020;182:1504–6.
230. Trave I, Merlo G, Cozzani E, Parodi A. Real-life experience on effectiveness and tolerability of topical ivermectin in papulopustular rosacea and antiparasitic effect on *Demodex* mites. *Dermatol Ther*. 2019;32:e13093.
231. Schaller M, Kemény L, Havlickova B, et al. A randomized phase 3b/4 study to evaluate concomitant use of topical ivermectin 1% cream and doxycycline 40-mg modified-release capsules, versus topical ivermectin 1% cream and placebo in the treatment of severe rosacea. *J Am Acad Dermatol*. 2020;82:336–43.
232. Logger JGM, Peppelman M, van Erp PEJ, de Jong EMGJ, Nguyen KP, Driessen RJB. Value of reflectance confocal microscopy for the monitoring of rosacea during treatment with topical ivermectin. *J Dermatolog Treat*. 2020;1–9. <https://doi.org/10.1080/09546634.2020.1741501>.
233. Cardwell L, Alinia H, Moradi Tuchayi S, Feldman S. New developments in the treatment of rosacea—role of once-daily ivermectin cream. *Clin Cosmet Investig Dermatol*. 2016;9:71–7.
234. Abokwidir M, Fleischer AB. Additional evidence that rosacea pathogenesis may involve *Demodex*: new information from the topical efficacy of ivermectin and praziquantel. *Dermatol Online J*. 2015;21:13030/qt13v249f5.
235. Abokwidir M, Fleischer AB. An emerging treatment: topical ivermectin for papulopustular rosacea. *J Dermatolog Treat*. 2015;26:379–80.
236. Ruini C, Sattler E, Hartmann D, Reinholz M, Ruzicka T, von Braunmühl T. Monitoring structural changes in *Demodex* mites under topical ivermectin in rosacea by means of reflectance confocal microscopy: a case series. *J Eur Acad Dermatol Venereol*. 2017;31:e299–301.
237. Trompezinski S, Pernet I, Schmitt D, Viac J. UV radiation and prostaglandin E2 up-regulate vascular endothelial growth factor (VEGF) in cultured human fibroblasts. *Inflamm Res*. 2001;50:422–7.
238. Brauchle M, Funk JO, Kind P, Werner S. Ultraviolet B and H2O2 are potent inducers of vascular endothelial growth factor expression in cultured keratinocytes. *J Biol Chem*. 1996;271:21793–7.
239. Stromberg BE, Nutting WB. Adaptive features of the exoskeleton and pigment deposits in *Demodex* spp. (*Demodicidae*). *Acarologia*. 1973;14:605–11.
240. Clanner-Engelshofen BM, French LE, Reinholz M. *Corynebacterium kroppenstedtii* subsp. *demodicis* is the endobacterium of *Demodex folliculorum*. *J Eur Acad Dermatol Venereol*. 2020;34:1043–9.
241. Akilov OE, Butov YS, Mumcuoglu KY. A clinicopathological approach to the classification of human demodicosis. Ein klinisch-pathologischer Ansatz zur Klassifikation der humanen Demodikose. *J Deut Dermatol Gesell*. 2005;3:607–14.
242. Sędzikowska A, Oseka M, Grytner-Zięcina B. Ocular symptoms reported by patients infested with *Demodex* mites. *Acta Parasitol*. 2016;61:808–14.