

Predetermination of root canal lengths in molar teeth: A comparison between radiovisigraphy and two-dimensional and three-dimensional measurements using cone-beam computed tomography

Annil Dhingra, Charu Dayal, Amteshwar Singh, Neetika Bhardwaj

Department of Conservative Dentistry and Endodontics, D. J. College of Dental Sciences and Research, Modinagar, Ghaziabad, Uttar Pradesh, India

Abstract

Introduction: Obtaining a correct working length is critical to the success of endodontic therapy. The aim of this clinical study was to compare the effect of working length determination using radiovisigraphy (RVG) and two-dimensional (2D) and three-dimensional (3D) measurements using cone-beam computed tomography (CBCT). **Materials and Methods:** Thirty mandibular teeth were taken and three groups of 10 each were made. Teeth with previous endodontic treatments, metal restorations, resorptions, incomplete apex formations, and multiple visible foramina were excluded. The root canal length was determined using RVG, CBCT measurement method 2D, and CBCT measurement method 3D. The difference between CBCT measurements, RVG, and the actual canal length were compared to evaluate the accuracy of each method. **Results:** No significant statistically difference was seen with 3D measurements and actual measurements. Measurements with RVG were better than CBCT 2D. **Conclusion:** Under experimental conditions, CBCT 3D measurements are accurate than RVG and CBCT 2D in the determination of root canal length.

Key words: Cone-beam computed tomography, radiovisigraphy, root canal length, stereomicroscope

INTRODUCTION

One of the major problems in endodontic treatment is identifying and maintaining the biological length of the root canal system. Optimal healing condition with minimal contact between the obturation material and the apical tissue is achieved when root canal treatment terminates at the apical constriction. In this way, persistent inflammatory responses, tissue destruction, and foreign body reactions are kept at their lowest possible level.^[1] This fact is supported by prognostic studies that have shown the success of root canal treatment is influenced by the adequacy of working length during endodontic treatment.^[2]

Although it has been a major subject of debate for decades, the exact termination point for root canal

therapy is still considered a controversial topic.^[3] However, in clinical practice, the minor apical foramen, as a more consistent anatomic feature, can be regarded as being the narrowest portion of the canal system and thus the ideal landmark for the apical endpoint for root canal treatment. Different methods have been used for locating the position of the canal terminus and measuring the working length of root canals as a result. Radiographic method, traditionally the most popular and trusted way for length measurement in the

Address for correspondence:

Dr. Amteshwar Singh,
Department of Conservative Dentistry and Endodontics,
D. J. College of Dental Sciences and Research, Modinagar,
Ghaziabad, Uttar Pradesh, India.
E-mail: amteshwar55555@gmail.com

This is an open access article distributed under the terms of the Creative Commons Attribution-NonCommercial-ShareAlike 3.0 License, which allows others to remix, tweak, and build upon the work non-commercially, as long as the author is credited and the new creations are licensed under the identical terms.

For reprints contact: reprints@medknow.com

How to cite this article: Dhingra A, Dayal C, Singh A, Bhardwaj N. Predetermination of root canal lengths in molar teeth: A comparison between radiovisigraphy and two-dimensional and three-dimensional measurements using cone-beam computed tomography. Indian J Dent 2015;6:195-8.

Access this article online

Quick Response Code:



Website:

www.ijdentistry.com

DOI:

10.4103/0975-962X.170377

field of endodontics, has advantages such as the direct observation of the anatomy of the root canal system, the number and curvature of roots, the presence or absence of disease, and, in addition, acts as an initial guide for working length estimation. There are, however, a number of disadvantages that make this technique not quite suitable in every situation (e.g., the danger of overestimation of the root canal length even when it seems to be short of the radiographic apex because of normal anatomic variations in the apical region).^[4] Other shortcomings of radiography include technique sensitivity and subjectivity, the danger of ionizing radiation, and errors of superimposition caused by producing a two-dimensional (2D) representation from a three-dimensional (3D) object.^[5] Cone-beam computed tomography (CBCT) is a validated tool used to explore root canal morphology in 3D. Axial slices can show root canal angles and define the location of the major foramen, which is not identifiable with sufficient precision in periapical radiographs (PAS). Since the introduction of CBCT in dental medicine, this radiographic technique has also become an important method for diagnosis and treatment planning in endodontology.^[6] In addition to improving comprehension of tooth anatomy, CBCT has become an established method for diagnosing periapical pathologies, root fractures, and internal/external root resorptions.^[7]

A better understanding of the third dimension of dental roots could also help to increase the accuracy of endodontic working length measurements and performance of root canal measurements on preexisting CBCT scans is a potential new method for determining root canal length before initiating endodontic treatment. By taking advantage of all the visual information available in the field of view, clinicians can apply already existing CBCT data toward further interventions in the same region of the jaw, such as root canal treatments. The purpose of this clinical study was to validate this new measurement method by analyzing its reliability and precision through a comparison with the standard clinical measurement procedure that uses CBCT. Furthermore, tooth-related aspects, such as the age and gender of the included patients, the type of tooth evaluated, and curvatures of the roots, were analyzed to determine their effects on the precision of the measurements.

MATERIALS AND METHODS

Thirty mandibular teeth were taken and three groups of 10 each were made. Teeth with previous endodontic treatments, metal restorations, resorptions, incomplete apex formations, and multiple visible foramina were excluded. The root canal length was determined using:

1. Radiovisography (RVG)
 2. CBCT measurement method 2D
 3. CBCT measurement method 3D.
- Difference between CBCT measurements, RVG and the actual canal length were compared to evaluate the accuracy of each method
 - 3D image acquisition was performed using the CBCT CS 9300 (78 kV, 2 mA, Planmeca, Helsinki, Finland). The open source software CS 3D On Demand was used for the 3D multiplanar reconstruction and length measurements. All CBCT measurements were performed by a single experienced investigator [Figure 1]
 - Group 1: RVG [Figure 2]
 - Group 2: CBCT - 2D [Figure 3]
 - Group 3: CBCT - 3D [Figure 4].
 - Subsequently, access cavities were prepared Using Endo Acess and Endo Z, and patency of the root canals was verified with a size 08 K-file. Root canals were irrigated with 5.25% sodium hypochlorite. Coronal third was flared using a rotary file (ProTaper Shaping file SX, Dentsply Maillefer, Ballaigues, Switzerland) to gain a straight line access. The actual length of each root canal was measured by a different blinded examiner. A size 10 K-file was advanced within the root canal until it was visible [Figure 5] with a stereomicroscope (Leica WILD M3Z; Leica Microsystems GmbH, Wetzlar, Germany)
 - The rubber stop was adapted to predefined coronal reference, and the actual canal length was determined.

RESULTS

The mean and standard deviations of the differences between CBCT 3D, RVG and CBCT 2D were calculated. ANOVA test was done and comparison was done between the groups and within the group.



Figure 1: Sample size

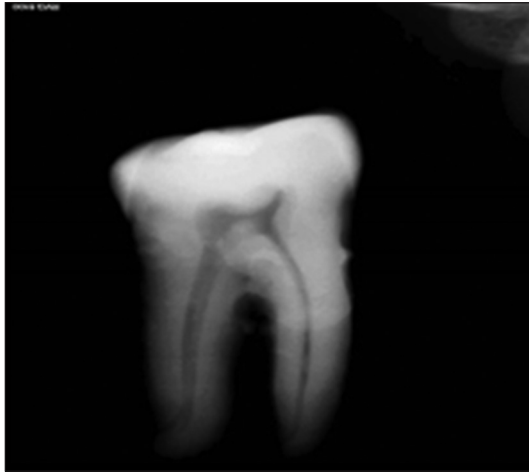

Figure 2: Working length determination in group 1 (RVG)

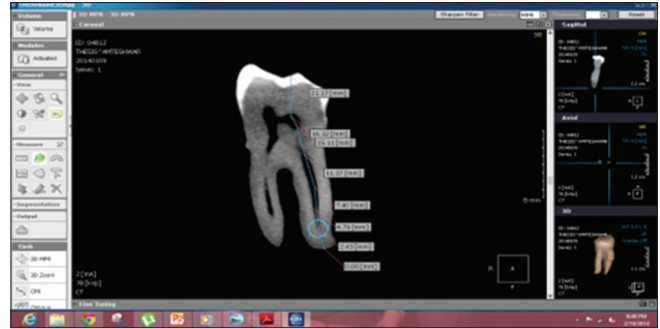


Figure 3: Working length determination in group 2 (CBCT 2D)

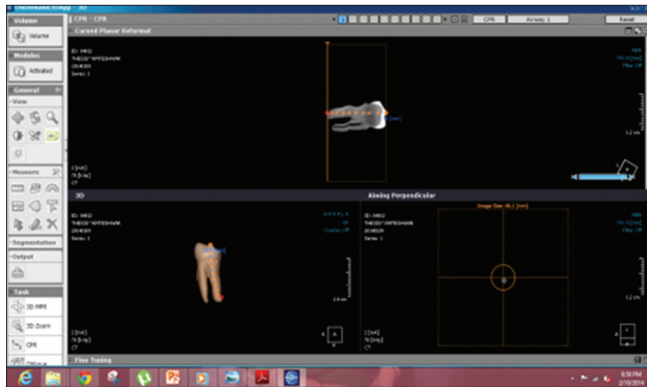


Figure 4: Working length determination in group 3 (CBCT 3 D)

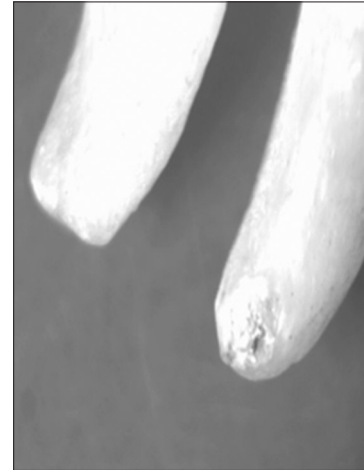

Figure 5: Stereomicroscopic image for determining actual working length

Tukey's honestly significant difference test was done and the results are shown in Tables 1 and 2.

DISCUSSION

The accuracy of root canal length measurements is essential for success after root canal treatment.^[8] Root canal length should be monitored continuously during endodontic treatment because straightening of the root canal can lead to an over instrumentation. Conventional measurement methods with tools such as an electronic apex locator and PAS have been well-documented in literature.^[8] Since the introduction of CBCT in dental medicine, this radiographic technique has also become an important method for diagnosis and treatment planning in endodontology. In addition to improving comprehension of tooth anatomy, CBCT has become an established method for diagnosing periapical pathologies, root fractures, and internal/external root resorptions.^[9]

Molar teeth can be especially challenging in this respect. Overlying dentine at the orifice should be removed

Table 1: ANOVA test

ANOVA					
Actual					
	Sum of squares	df	Mean square	F	Significant
Between groups	1.431	3	0.477	0.169	0.916
Within groups	101.428	36	2.817		
Total	102.859	39			

initially to facilitate complete and straight access to the root canal, decrease the initial curvature, and prevent working length reduction during instrumentation^[10] Radiographs could not always detect the apical foramen, and, thus, length measurements could be unreliable because of superimpositions.^[11-13] In contrast to radiographs, CBCT imaging can display both the mesiodistal and buccolingual shape of root canals and is able to show the apical foramen.^[14,15]

Hence in this study, a straight-line access was prepared, and the coronal third of the root canal was flared before the actual working length was measured. The primary objective of this study was to predetermine the root canal length using CBCT 3D, CBCT 2D, and RVG.

Table 2: Tukeys HSD test

Multiple comparisons						
Actual Tukey's HSD						
(I) s	(J) s	Mean	SE	Significant	95% CI	
number	number	difference			Lower bound	Upper bound
		(I-J)				
1	2	-0.200	0.751	0.993	-2.22	1.82
	3	-0.435	0.751	0.938	-2.46	1.59
	4	0.042	0.751	1.000	-1.98	2.06
2	1	0.200	0.751	0.993	-1.82	2.22
	3	-0.235	0.751	0.989	-2.26	1.79
	4	0.242	0.751	0.988	-1.78	2.26
3	1	0.435	0.751	0.938	-1.59	2.46
	2	0.235	0.751	0.989	-1.79	2.26
	4	0.477	0.751	0.920	-1.54	2.50
4	1	-0.042	0.751	1.000	-2.06	1.98
	2	-0.242	0.751	0.988	-2.26	1.78
	3	-0.477	0.751	0.920	-2.50	1.54

No significant statistically difference was seen with 3D measurements and actual measurements, measurements with RVG were better than CBCT 2D. 3D: Three-dimensional, CI: Confidence interval, SE: Standard error, HSD: Honestly significant difference, RVG: Radiovisiography, CBCT: Cone-beam computed tomography, 2D: Two-dimensional

Thirty mandibular molars were taken for the study. It was found that results with CBCT 3D were more accurate as compared to RVG and CBCT 2D. Standard error during the statistical analysis was 0.0476 in CBCT 3D while it was 0.5402 and 0.5738 in RVG and CBCT 2D, respectively. The mean discrepancy found in this study between the CBCT measurements and the actual working length was in accordance as registered by the mentioned authors (0.40 mm according to Janner *et al.* (2011) and 0.51 mm in the study published by Jeger *et al.* (2012). Measurements with CBCT 3D were better than RVG and CBCT 2D. This can be due to coronal references that are located buccally or lingually and root canals with multiple curvatures cannot be projected reliably in a single plane.

CONCLUSION

Under experimental conditions, CBCT 3D measurements are accurate than RVG and CBCT 2D in the determination of root canal length.

Financial support and sponsorship

Nil.

Conflicts of interest

There are no conflicts of interest.

REFERENCES

- Ricucci D, Langeland K. Apical limit of root canal instrumentation and obturation, part 2. A histological study. *Int Endod J* 1998;31:394-409.
- Sjogren U, Hagglund B, Sundqvist G, Wing K. Factors affecting the long-term results of endodontic treatment. *J Endod* 1990;16:498-504.
- Ng YL, Mann V, Rahbaran S, Lewsey J, Gulabivala K. Outcome of primary root canal treatment: Systematic review of the literature – Part 2. Influence of clinical factors. *Int Endod J* 2008;41:6-31.
- Kojima K, Inamoto K, Nagamatsu K, Hara A, Nakata K, Morita I, *et al.* Success rate of endodontic treatment of teeth with vital and nonvital pulps. A meta-analysis. *Oral Surg Oral Med Oral Pathol Oral Radiol Endod* 2004;97:95-9.
- Bergenholtz G, Spångberg L. Controversies in endodontics. *Crit Rev Oral Biol Med* 2004;15:99-114.
- Peters OA. Current challenges and concepts in the preparation of root canal systems: A review. *J Endod* 2004;30:559-67.
- Ponce EH, Vilar Fernández JA. The cemento-dentino-canal junction, the apical foramen, and the apical constriction: Evaluation by optical microscopy. *J Endod* 2003;29:214-9.
- ElAyouti A, Weiger R, Löst C. Frequency of overinstrumentation with an acceptable radiographic working length. *J Endod* 2001;27:49-52.
- Kazzi D, Horner K, Qualtrough AC, Martinez-Beneyto Y, Rushton VE. A comparative study of three periapical radiographic techniques for endodontic working length estimation. *Int Endod J* 2007;40:526-31.
- Radel RT, Goodell GG, McClanahan SB, Cohen ME. *In vitro* radiographic determination of distances from working length files to root ends comparing Kodak RVG 6000, Schick CDR, and Kodak insight film. *J Endod* 2006;32:566-8.
- Williams CB, Joyce AP, Roberts S. A comparison between *in vivo* radiographic working length determination and measurement after extraction. *J Endod* 2006;32:624-7.
- Pendlebury ME, Horner K, Eaton KA. Selection Criteria for Dental Radiography. 1st ed. London, UK: Faculty of General Dental Practitioners, Royal College of Surgeons of England; 2004. p. 6-17.
- ElAyouti A, Weiger R, Löst C. The ability of root ZX apex locator to reduce the frequency of overestimated radiographic working length. *J Endod* 2002;28:116-9.
- Michetti J, Maret D, Mallet JP, Diemer F. Validation of cone beam computed tomography as a tool to explore root canal anatomy. *J Endod* 2010;36:1187-90.
- Estrela C, Bueno MR, Sousa-Neto MD, Pécora JD. Method for determination of root curvature radius using cone-beam computed tomography images. *Braz Dent J* 2008;19:114-8.