

Available online at www.sciencedirect.com

ScienceDirect

journal homepage: www.elsevier.com/locate/radcr

Case Report

Isolated traumatic pectoralis minor tendon tear in a young adult diagnosed with MRI

Juan M. Colazo^{a,*}, Jimmy Saade^b, Sasan Partovi^d, James Andry^c, Nicholas Bhojwani^b

^a Vanderbilt University School of Medicine, Vanderbilt University Medical Center, Nashville, TN 37232, USA

^b HonorHealth, 10835 North 25th Avenue #240, Phoenix, AZ 85029, USA

^c Dignity Health, Orthopedics Department, University of Arizona, 500 West Thomas Road #850, Phoenix, AZ 85013, USA

^d Department of Radiology, University Hospitals Cleveland Medical Center, Case Western Reserve University, 11100 Euclid Avenue, Cleveland, OH 44106, USA

ARTICLE INFO

Article history:

Received 23 March 2018

Accepted 8 April 2018

Available online 1 June 2018

Keywords:

Pectoralis minor

Trauma

MVA

MRI

CT

ABSTRACT

This is a rare case of an isolated pectoralis minor partial-thickness tendon tear in a 24-year-old man who was involved in a major trauma. The purpose of this paper is to report the clinical signs, symptoms, cross-sectional imaging findings, and management of an isolated pectoralis minor tendon tear. Furthermore, this case represents a novel traumatic mechanism of injury, as opposed to the classic sports-related pectoralis minor tendon tear injury. The current limited body of literature on isolated pectoralis minor tendon tears is reviewed.

© 2018 The Authors. Published by Elsevier Inc. on behalf of University of Washington.

This is an open access article under the CC BY-NC-ND license.

(<http://creativecommons.org/licenses/by-nc-nd/4.0/>)

1. Introduction

Pectoralis major muscle tendon tears are frequently encountered [1–4]. Pectoralis minor muscle tendon tears are uncommon. If they do occur, they are usually in conjunction with a pectoralis major muscle tear [1]. However, isolated pectoralis minor tendon tears without a pectoralis major muscle tear are exceedingly rare. To our knowledge, only five cases of isolated pectoralis minor tendon tears are currently described in the English literature [Table 1], all of which were sports-related injuries. The medically accepted mechanism for a pectoralis major tear is forced abduction and external rotation. Pectoralis

minor tear mechanisms of injury are relatively unknown since very few cases have been described [5–8]. In these cases, conservative management is indicated [9,10].

The pectoralis minor is a fan-shaped muscle of the shoulder girdle. It originates from the external surfaces of the anterior portion of the third to fifth ribs and inserts onto the coracoid process of the scapula [11]. It is innervated by the medial and lateral pectoral nerves (C6–T1), which are branches of the brachial plexus. The pectoralis minor is located deep to the pectoralis major and together they form the anterior wall of the axilla. Thus, the contracted pectoralis minor muscle can be palpated in the axillary region. It is located in close proximity to the brachial plexus, the subclavian artery, and

* Corresponding author.

E-mail address: juan.m.colazo@vanderbilt.edu (J.M. Colazo).

<https://doi.org/10.1016/j.radcr.2018.04.015>

1930-0433/© 2018 The Authors. Published by Elsevier Inc. on behalf of University of Washington. This is an open access article under the CC BY-NC-ND license. (<http://creativecommons.org/licenses/by-nc-nd/4.0/>)

Table 1 – A review of the findings, imaging, and outcomes of all five literature-reported cases of an isolated pectoralis minor muscle tendon tear.

Authors/Year	Age	M/F	Mechanism of injury	R/L	Initial impression	Imaging findings	Treatment	Follow-up
Mehallo et al. (2004)	40 years	F	Female football player; during a tackling drill she was hit on the front of the right shoulder. The shoulder was pushed superiorly and posteriorly. The patient's arms were by her side at the time of impact	R	Grade 1 pectoralis major muscle strain	T2-weighted axial MRI showed edema and lack of definition of the right pectoralis minor muscle. Imaging of the right shoulder showed that the pectoralis major was intact including the humeral attachment	Cross-friction massage and shoulder stabilization exercises	Returned to play with full activities 2 weeks post injury
Kalra et al. (2010)	25 years	M	Professional ice hockey player; while avoiding a check he was contacted with the affected arm in slight abduction, external rotation and extension	R	An initial diagnosis of pectoralis major strain was made	T2-weighted proton-density fast spin echo oblique coronal MR images showed extensive edema in the pectoralis minor muscle and a complete isolated tendon tear with 2 cm of retraction. Pectoralis major was intact	Sling and physical therapy; 2 weeks—passive external rotation, passive abduction, and scapular retraction avoided; 3 weeks—abduction was initiated; 3.5 weeks—return to skating; 4 weeks—full return to play without pain/weakness	Pain-free pushups achieved 8 weeks from the injury date post injury. Patient played the remainder of the season without re-injury or shoulder complaints
Li et al. (2012)	17 years	M	High school football player (linebacker); injured during a game when making a tackle and leading with left arm and chest	L	N/A	Axial T1-weighted magnetic resonance image showing high T1 signal at the pectoralis minor myotendinous junction with muscle rupture and retraction. Sagittal T2-weighted magnetic resonance image showing significant edema within the pectoralis minor muscle and detachment of the tendon from the coracoid	Conservative treatment with physical therapy and NSAIDs	4 weeks—mild discomfort with activities requiring shoulder abduction and extension; 8 weeks—not lifting weights or participating in sports; 12 weeks—Pain completely resolved, released for athletic participation; 12 months—patient reported no residual pain with return for the following season
Zvijac et al. (2009)	Late 20s	M, M	Two male professional football players (NFL); during practice with blocking exercises. The arm position was in extension with the shoulder in flexion in both cases	L, L	N/A	Anteroposterior and cross-sectional MRI imaging showed isolated tear of the pectoralis minor muscle	Scapular retraction and protraction as well as shoulder depression exercises were recommended (scapular stabilizing exercises). Further conservative management included physical therapy, massage and neuromuscular training	Both athletes returned to playing after 3–4 weeks post injury

MRI = magnetic resonance imaging.

the subclavian vein which all run between the muscle and the bony ribcage. The arterial supply is coming from the pectoral branch of the thoracoacromial artery, the lateral thoracic artery, and the upper lateral cutaneous branches of the posterior intercostal arteries [11]. Regarding its function, the muscle pulls the scapula medially, forward, and downward. Thus, the pectoralis minor muscle is used in the shoulder movements of depression and abduction. Furthermore, it briefly aids in respiration, belonging to the respiratory musculature [11].

Although the anatomy, physiological function, and pathologic tearing of the pectoralis major muscle are well known [12–14], the mechanisms of an isolated pectoralis minor tear are largely unknown. We hereby report a case of an isolated pectoralis minor tendon tear in a 24-year-old man who was the victim of an automobile–pedestrian collision. The

clinical symptomatology, cross-sectional imaging findings, and treatment of an isolated pectoralis minor tendon tear are described. This paper highlights the possibility of a pectoralis minor tendon tear in a trauma setting and includes a review of the corresponding literature.

2. Case presentation

A 24-year-old male pedestrian presented as a trauma to the emergency department after being struck by an automobile. On admission, the patient had vital signs within normal limits and complained only of left shoulder pain. On physical examination, he exhibited left shoulder tenderness with an abrasion

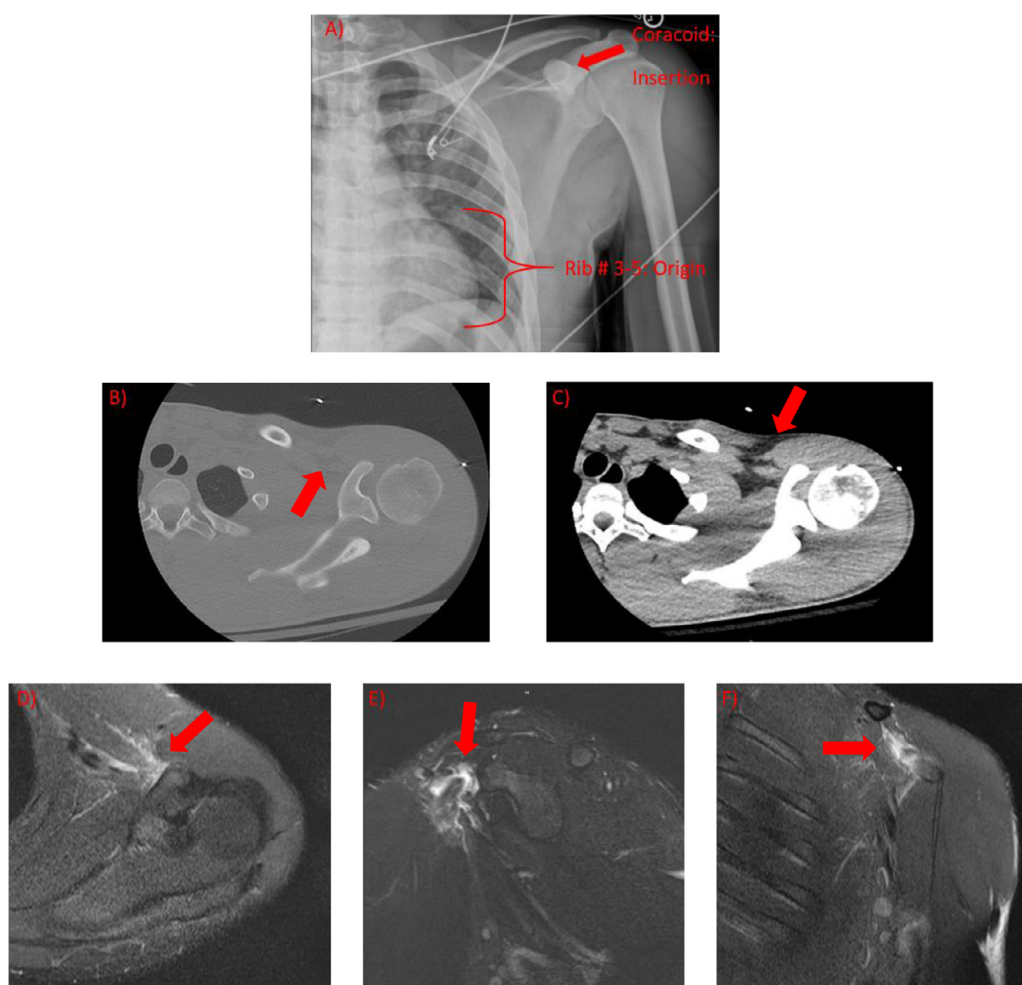


Fig. 1 – (A) Anteroposterior (AP) radiograph of the left upper extremity shows an intact coracoid process. The insertion (external surfaces of anterior portion of third to fifth rib) and the origin (coracoid process) of the pectoralis minor muscle are labeled. **(B)** Axial computerized tomography (CT) image (bone window) of the coracoid demonstrates no avulsion fracture. **(C)** Axial CT image of the coracoid (soft tissue window) clearly shows the pectoralis minor muscle and minimal surrounding fat stranding indicative of the tendon tear in retrospect. **(D)** Axial proton-density fat saturation magnetic resonance imaging (MRI) demonstrates edema and fluid signal (red arrow) of the pectoralis minor tendon attachment onto the coracoid process indicating a partial-thickness nonretracted tendon tear. **(E)** Sagittal T2 fat saturated MRI shows the insertion of the pectoralis minor tendon with significant muscle edema (red arrow). **(F)** Coronal proton-density fat saturation sequence MRI demonstrates pectoralis minor peritendinous fluid and edema (red arrow). (For interpretation of the references to color in this figure legend, the reader is referred to the web version of this article.)

observed over the lateral left shoulder. Shoulder motion was painful. Complete diagnostic imaging was performed with a pertinent finding of an isolated left pectoralis minor partial-thickness tendon insertion tear at the coracoid process (Fig. 1). An orthopedic consult was made. On musculoskeletal examination, there was global tenderness to palpation and reduced motion of the left shoulder. Our patient was recommended inpatient physical therapy and the use of a sling.

3. Imaging

As this was a blunt trauma injury, several imaging modalities were indicated including plain radiographs, computerized tomography (CT) scans, and magnetic resonance imaging (MRI) scans. An anteroposterior radiograph of the left upper extremity showed an intact coracoid process without evidence of acute fracture or malalignment (Fig. 1). Axial CT images of the left coracoid demonstrated minimal surrounding fat stranding, potentially suggestive of tendon injury. No other significant injuries were observed using CT. Primarily based on the symptomatology and secondarily based on the subtle left coracoid CT findings, the emergency medicine trauma team decided that MRI of the left shoulder was indicated. An axial proton-density fat saturation MRI demonstrated edema and fluid signal within the pectoralis minor tendon attachment onto the coracoid process. A sagittal T2 fat saturated MRI showed the insertion of the pectoralis minor tendon demonstrating significant muscle edema. A coronal proton-density fat saturation sequence MRI revealed pectoralis minor peritendinous fluid and edema. These MRI findings were consistent with a partial-thickness nonretracted pectoralis minor tendon tear off the coracoid process (Fig. 1).

4. Patient management and disease course

The trauma team concluded that no surgical treatment was necessary and that the pectoralis major muscle will compensate for the loss of function of the pectoralis minor muscle. Since the brachial plexus is located in vicinity to the tendon injury, irritation can explain at least partially the patient's pain. Physical therapy with short-term inpatient observation was recommended at a frequency of 5 days per week. The patient's left arm was placed temporarily in a sling and his left arm should be used as tolerated as per the orthopedic team.

5. Discussion

In this case, the mechanism of injury was a traumatic direct anterior force to the left shoulder during a motor-pedestrian collision. The five previously reported cases in the literature were sports-related injuries (Table 1). Similar to our case, all five previously reported cases also described coracoid process tenderness upon palpation. In the reported cases, significant pain was elicited with forced shoulder abduction, extension,

and external rotation of the afflicted arm [5–8, Table 1]. Our patient's physical examination was limitedly given the patient's significant pain.

The diagnosis of an isolated pectoralis minor tendon rupture should be made based on history, physical examination, and MRI. An important part of the history is the anatomic location of impact. Identical to our case, all five previously reported cases describe force that was applied along the anterior shoulder. Interestingly, in this case, like one other case in the literature [5], the patient had his arms at the side when the injury happened whereas in the four other reported cases, extension of the affected arm at the time of injury was observed [6–8]. Thus, a pectoralis minor tendon injury can be caused by a direct anterior force to the shoulder [5], forced external rotation of the arm in slight abduction [6], or with the arm in extension and shoulder in flexion [7]. On physical examination, tenderness to palpation over the coracoid process and reduced range of motion with pain/weakness is common [5–8]. In our case, and in accordance with the other five cases reported, MRI of the affected shoulder was crucial to confirm the diagnosis [5–8, Fig. 1].

Due to the similarity of this injury to a pectoralis major strain (or since pectoralis minor tears often occur in conjunction with pectoralis major strains), the female football player and professional ice hockey player from the literature [5,7, Table 1] were incorrectly diagnosed with pectoralis major strains before imaging results were collected and analyzed. Since a pectoralis major strain (or rupture) has different treatment implications, the correct diagnosis of an isolated pectoralis minor tear is important [5–8]. Patients with complete pectoralis major tears usually undergo surgery to regain optimal function [15], meanwhile conservative treatment management is recommended in isolated pectoralis minor tendon tears, as described in the five previously published cases. Conservative management was also suggested in our patient. Zvijac et al. originally suggested the idea of conservative treatment based on reports of patients with Poland syndrome (congenital absence of the pectoralis minor muscle is one variant) posing no functional limitations [16].

It is important to educate patients with pectoralis minor muscle tendon tears that shoulder strength may decrease slightly compared to pre-injury baseline, but that overall functional outcome is usually not compromised. Previous reports have shown a return to normal activity levels with no complaints during follow-up [5–8]. Physical therapy, nonsteroidal anti-inflammatory drugs, and avoidance of strenuous activity for several weeks are sufficient. The athletes in the five previously reported cases returned to sports activities after 2–12 weeks of conservative management including physical therapy, massage, neuromuscular training, and scapular stabilizing exercises [5–8]. The finalized recommendations in our patient were physical therapy 5 days per week, use of a sling, and movement of the left upper extremity, as tolerated.

6. Conclusion

Although rare, isolated pectoralis minor tendon tears should be considered in patients that complain about tenderness

regional to the coracoid process and that have recently sustained an anterior contact injury to the shoulder. The injury can be either trauma-related (as described, to our knowledge, for the first time in this case report) or sports-related (as described, to our knowledge, in five cases in the English literature). The definitive diagnosis is made with MRI. Patient management should consist of conservative measures including physical therapy with scapular stabilization exercises, avoidance of abduction and active adduction, as well as sling placement. The goal of conservative management in these patients is to return to their previous baseline activity levels.

7. Teaching point

To diagnose an isolated pectoralis minor tendon tear, physical examination will be evident for coracoid tenderness upon palpation. MRI will show edema at the tendon insertion site of the pectoralis minor muscle onto the coracoid process, along with an intact pectoralis major muscle. Along with sports-related injuries, it can also occur in trauma.

Authors' contributions

J.M.C. drafted the initial version of the manuscript. N.B. and S.P. edited the manuscript based on the initial draft. J.M.C. finalized the figures. J.M.C. and S.P. organized the final manuscript. N.B. provided patient information and raw images. J.S. and J.A. provided specialty-specific knowledge. J.M.C., J.S., S.P., J.A., and N.B. agreed to the final version of the manuscript.

Disclosures

None.

Conflict of interest

None.

Supplementary materials

Supplementary material associated with this article can be found, in the online version, at doi:[10.1016/j.radcr.2018.04.015](https://doi.org/10.1016/j.radcr.2018.04.015).

REFERENCES

- [1] Pochini Ade C, Ejnisman B, Andreoli CV, Monteiro GC, Silva AC, Cohen M, et al. Pectoralis major muscle rupture in athletes: a prospective study. *Am J Sports Med* 2010;38(1):92–8.
- [2] Gudmundsson B. A case of agenesis and a case of rupture of the pectoralis major muscle. *Acta Orthop Scand* 1973;44(2):213–18.
- [3] Schepsis AA, Grafe MW, Jones HP, Lemos MJ. Rupture of the pectoralis major muscle. Outcome after repair of acute and chronic injuries. *Am J Sports Med* 2000;28(1):9–15.
- [4] Zvijac JE, Schurhoff MR, Hechtman KS, et al. Pectoralis major tears: correlation of magnetic resonance imaging and treatment strategies. *Am J Sports Med* 2006;34(2) 289–289.
- [5] Mehallo CJ. Isolated tear of the pectoralis minor. *Clin J Sport Med* 2004;14(4):245–6.
- [6] Zvijac JE, Zikria B, Botto-van Bemden A. Isolated tears of pectoralis minor muscle in professional football players: a case series. *Am J Orthop* 2009;38(3):145–7.
- [7] Kalra K, Neri B. Isolated pectoralis minor tendon tear in a professional ice hockey player—radiographic findings and presentation. *Skeletal Radiol* 2010;39(12):1251–3.
- [8] Li X, Gorman MT, Dines JS, Limpsvasti O. Isolated tear of the pectoralis minor tendon in a high school football player. *Orthopedics* 2012;35(8):1272–5.
- [9] Fleury AM, Silva AC, Pochini A, Ejnisman B, Lira CA, Andrade Mdos S. Isokinetic muscle assessment after treatment of pectoralis major muscle rupture using surgical or non-surgical procedures. *Clinics (Sao Paulo)* 2011;66(2):313–20.
- [10] Pavlik A, Csepai D, Berkes I. Surgical treatment of pectoralis major rupture in athletes. *Knee Surg Sports Traumatol Arthrosc* 1998;6(2):129–33.
- [11] Moore KL, Dalley AF. *Clinically oriented anatomy*. 5th ed. Philadelphia: Lippincott Williams & Wilkins; 2005.
- [12] Bak K, Cameron EA, Henderson IJ. Rupture of the pectoralis major: a meta-analysis of 112 cases. *Knee Surg Sports Traumatol Arthrosc* 2000;8(2):113–19.
- [13] de Roguin B. Rupture of the pectoralis major muscle: diagnosis and treatment. Apropos of 3 cases [in French]. *Rev Chir Orthop Reparatrice Appar Mot* 1992;78(4):248–50.
- [14] McEntire JE, Hess WE, Coleman SS. Rupture of the pectoralis major muscle. A report of eleven injuries and review of fifty-six. *J Bone Joint Surg Am* 1972;54(5):1040–6.
- [15] Provencher MT, Handfield K, Boniquit NT, Reiff SN, Sekiya JK, Romeo AA. Injuries to the pectoralis major muscle; diagnosis and management. *Am J Sports Med* 2010;38(8):1693–705. <https://doi.org/10.1177/0363546509348051>.
- [16] Suzuki T, Takazawa H, Koshino T. Computed tomography of the pectoralis muscles in Poland's syndrome. *Hand* 1983;15(1):35–41.