

Available online at [www.sciencedirect.com](http://www.sciencedirect.com)

journal homepage: [www.elsevier.com/locate/radcr](http://www.elsevier.com/locate/radcr)

## Case Report

# Abnormal imaging presentations of extramedullary hematopoiesis in a 21-year old and 72-year old female<sup>☆,☆☆</sup>

Alexander Kaechele, DO\*, Aruj Chawla, DO, Matthew Osher, MD

Department of Radiology, Ascension Providence Hospital-MSU College of Human Medicine Southeast Michigan Campus, 16001 W. Nine Mile Road, Southfield, MI, 48075, USA

### ARTICLE INFO

#### Article history:

Received 16 April 2022

Revised 25 April 2022

Accepted 28 April 2022

#### Keywords:

Extramedullary hematopoiesis

Sickle cell anemia

Myelofibrosis

Chronic myelogenous leukemia

### ABSTRACT

Extramedullary hematopoiesis (EH) refers to hemopoiesis that occurs outside of the bone marrow and can be physiologic or pathologic in nature. Common sites of EH include the liver, spleen, and paravertebral soft tissues. Less commonly, EH can occur in the kidneys, pleura, paranasal sinuses, and various other organs. In this report, we describe two cases of EH with abnormal presentations on imaging. The first case discusses a 72-year-old female with a history of chronic myelogenous leukemia complicated by myelofibrosis. Outpatient computed tomography (CT) of the abdomen and pelvis obtained for symptoms of hematuria demonstrated infiltration of the pericelycal system by ill-defined soft tissue attenuating material. A well-circumscribed hypoattenuating splenic mass and enlarged retroperitoneal lymph nodes were also identified. CT-guided biopsy of an enlarged left para-aortic lymph node was ultimately performed which demonstrated abundant EH. The second case involves a 21-year-old female with a history of sickle cell anemia who originally presented to the emergency department with worsening chest and back pain. A CT of the abdomen was ultimately obtained which revealed multiple hypoattenuating splenic masses, a focal hypoattenuating liver lesion, mild hepatomegaly, and prominent retroperitoneal lymph nodes. Subsequent MRI revealed innumerable well-circumscribed intrahepatic lesions that were not readily apparent on the previous CT which demonstrated increased signal intensity on T1- and T2-weighted images. Ultrasound-guided biopsy of one of the splenic masses was ultimately performed, which revealed abundant EH.

© 2022 The Authors. Published by Elsevier Inc. on behalf of University of Washington.

This is an open access article under the CC BY-NC-ND license

(<http://creativecommons.org/licenses/by-nc-nd/4.0/>)

## Introduction

Extramedullary hematopoiesis (EH) refers to hemopoiesis that occurs outside of the bone marrow. Common locations include

<sup>☆</sup> Imaging of uncommon distributions of extramedullary hematopoiesis: a report of two cases.

<sup>☆☆</sup> Competing Interests: None.

\* Corresponding author.

E-mail address: [Alexander.Kaechele@ascension.org](mailto:Alexander.Kaechele@ascension.org) (A. Kaechele).

<https://doi.org/10.1016/j.radcr.2022.04.051>

1930-0433/© 2022 The Authors. Published by Elsevier Inc. on behalf of University of Washington. This is an open access article under the CC BY-NC-ND license (<http://creativecommons.org/licenses/by-nc-nd/4.0/>)

the liver, spleen, and paravertebral soft tissues [1]. However, cases of EH in various other organs have been reported, including the kidneys, paranasal sinuses, dura, gastrointestinal tract, and adrenal glands [9]. The exact mechanism of EH is not entirely understood although it is generally thought to be reactive to decreased or abnormal blood cell production in the bone marrow [9]. Diseases commonly associated with EH include myelofibrosis and leukemia. In addition, EH can often be seen in various hemoglobinopathies such as beta thalassemia and, less commonly, sickle cell anemia [9].

On imaging, common presentations of EH in the abdomen include diffuse hepatomegaly, diffuse splenomegaly, and prominent retroperitoneal lymph nodes [1]. Rarely, EH may present as mass-like lesions in the liver, spleen, and kidneys [1]. In this report, we discuss two cases of EH with abnormal patterns of organ involvement on imaging.

---

## Case report

### Case 1

A 21-year-old female with a history of sickle cell anemia presented to the emergency department with tachycardia, chest pain, and shortness of breath with ambulation which had started 1 day prior. An EKG obtained in the emergency department showed a heart rate of 97 beats per minute but was otherwise unremarkable. Labs obtained at that time demonstrated a decreased hemoglobin of 8.5 gm/dL, an elevated absolute reticulocyte count of greater than 720 K/mcl, an elevated total bilirubin of 9.8 mg/dL, and an elevated lactate dehydrogenase of 509 units/liter. Considering the patient's history of sickle cell anemia, the findings were consistent with an acute sickle cell flare. An elevated D-dimer of 1,038 ng/mL was present at that time, and a computed tomography (CT) angiogram of the chest was subsequently performed in order to rule out pulmonary embolism as a cause of the patient's symptoms. The CT angiogram of the chest did not reveal any evidence of pulmonary emboli but did demonstrate multiple hypoattenuating lesions throughout the spleen. CT of the abdomen and pelvis with contrast was subsequently obtained, which demonstrated mild diffuse hepatomegaly as well as a well-circumscribed hypoattenuating lesion within the left lobe of the liver measuring up to 1.9 cm. Multiple well-circumscribed hypoattenuating lesions, measuring up to 2.8 cm, were also identified throughout the spleen with no evidence of splenomegaly. Multiple prominent perisplenic lymph nodes were also present at the time of the exam (Fig. 1). Magnetic resonance imaging (MRI) of the abdomen with contrast obtained for further evaluation demonstrated innumerable hepatic lesions measuring up to 1.8 cm, the majority of which were not apparent on the previous CT. These lesions had increased signal intensity on both T1- and T2-weighted images and exhibited early arterial enhancement that persisted on delayed images. Multiple splenic lesions measuring up to 3.1

cm were present throughout the spleen with similar imaging characteristics (Fig. 2). Ultrasound-guided biopsy of one of the splenic lesions was ultimately performed. Preliminary ultrasound obtained prior to the procedure demonstrated a well-circumscribed hypoechoic mass measuring up to 2.5 cm without significant internal vascularity on color Doppler (Fig. 3). Histological analysis of the obtained tissue samples demonstrated abundant EH, multiple Gamna-Gandy bodies, and areas of fibrosis consistent with chronic infarcts. No findings suggestive of malignancy were identified. Of note, none of the previously described hepatic lesions could be identified on ultrasound at the time of the procedure or on a previous abdominal ultrasound obtained 10 days prior.

### Case 2

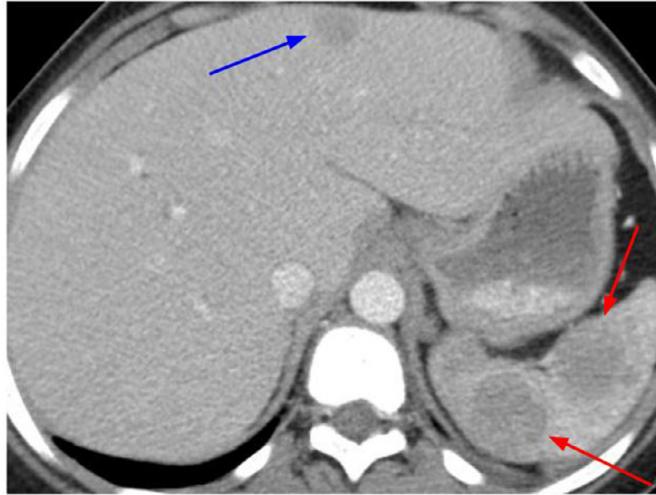
A 72-year-old female with a history of chronic myelogenous leukemia, complicated by chronic anemia, as well as a remote history of breast cancer presented to the radiology department on an outpatient basis with a chief complaint of hematuria and recurrent urinary tract infections. No recent labs had been recorded in the electronic health record at the time of the exam. A CT of the abdomen and pelvis without contrast demonstrated ill-defined soft tissue material surrounding the calyceal systems of both kidneys. Multiple well-defined soft tissue attenuating masses, measuring up to 2.8 cm and surrounding the calyceal system of the lower pole of the left kidney, were also identified (Fig. 4). An enlarged left para-aortic lymph node, measuring up to 1.4 cm in short axis, as well as innumerable non-enlarged retroperitoneal lymph nodes were also present (Fig. 5). Cystoscopy and left ureteroscopy were subsequently performed due to concern for underlying urothelial malignancy, but these demonstrated no evidence of urothelial neoplasm. A subsequent CT urogram showed that the renal lesions demonstrated mild contrast enhancement during nephrogenic phase that persisted on delayed phase images (Fig. 4). Multiple hypoattenuating splenic lesions, measuring up to 2.1 cm, were also identified with persistent contrast enhancement on delayed images (Fig. 6). Of note, these lesions were not discernable on the previous CT, likely due to the lack of intravenous contrast. The patient ultimately underwent CT-guided biopsy of an enlarged left para-aortic lymph node. Histological analysis of the obtained tissue samples demonstrated abundant EH without any evidence of underlying malignancy.

---

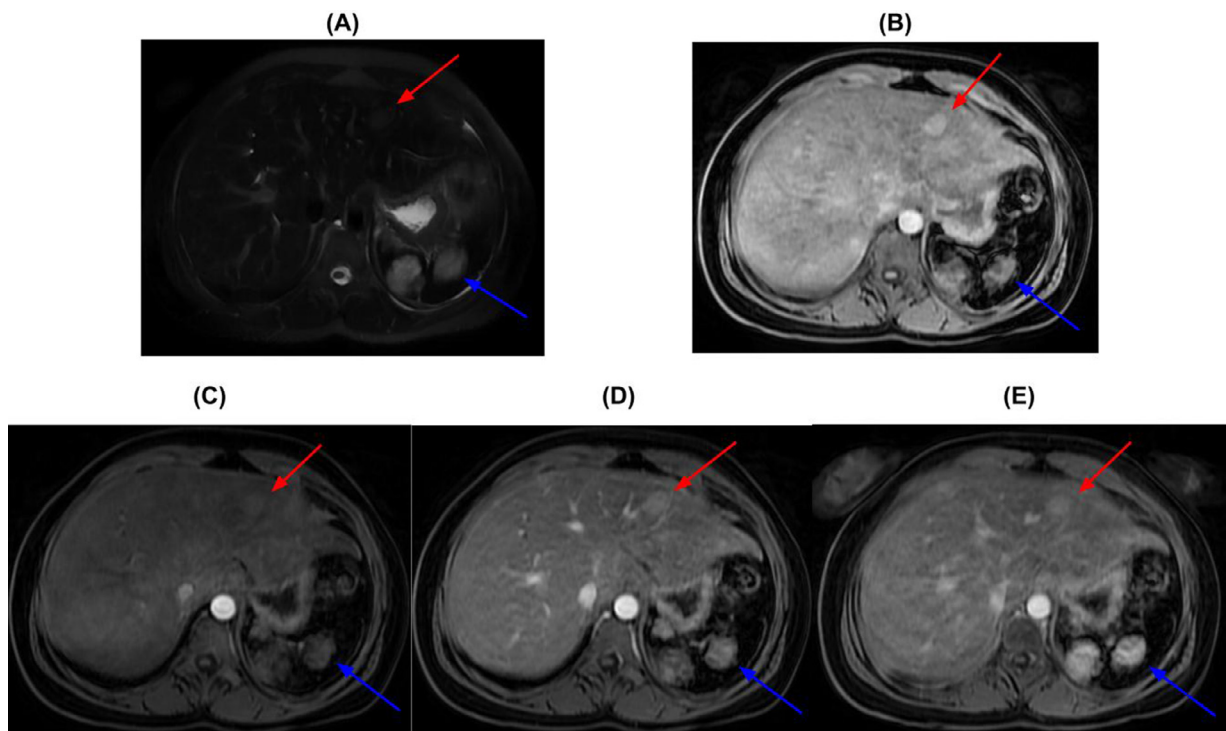
## Discussion

In the presented cases, we described two cases of EH with abnormal presentations on imaging.

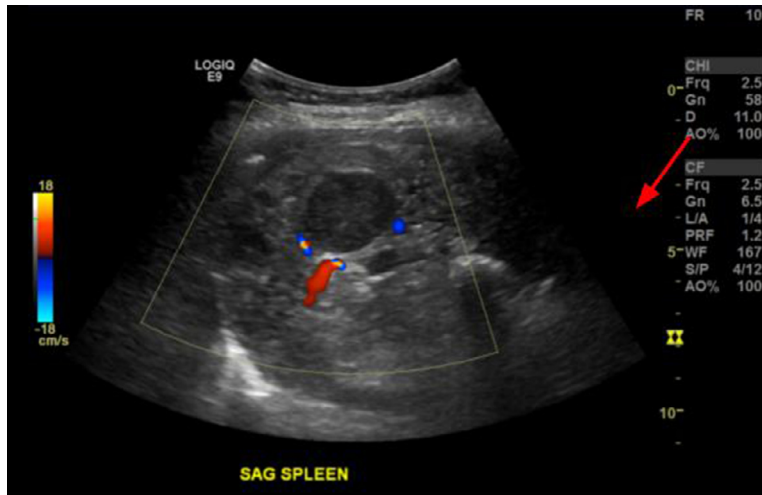
The first case involved a 21-year-old female with sickle cell anemia with multiple discrete splenic and hepatic masses, favored to represent areas of EH. Although cases of EH are commonly found in patients with various hemoglobinopathies, it



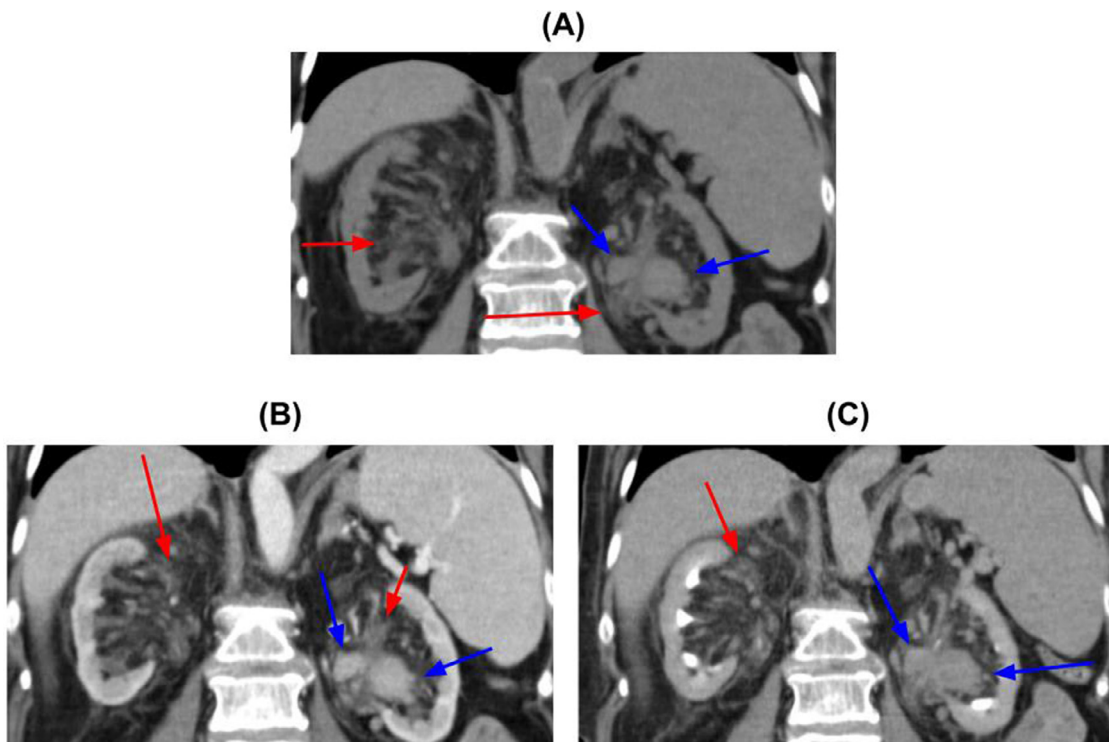
**Fig. 1** – A 21 year-old female with a history of sickle cell anemia. CT of the abdomen and pelvis obtained during portal venous phase after administration of 100 cc of intravenous Omnipaque 350 contrast (WW:350, WL:40). There are multiple well-circumscribed hypoattenuating lesions throughout the spleen measuring up to 2.8 cm with an average attenuation of 74.3 HU (red arrow). A hypoattenuating liver lesion is also present measuring up to 1.5 cm with an average attenuation of 84.1 HU (blue arrow). Mild hepatomegaly and multiple prominent perisplenic lymph nodes measuring up to 0.7 cm in short axis were also identified on this exam.



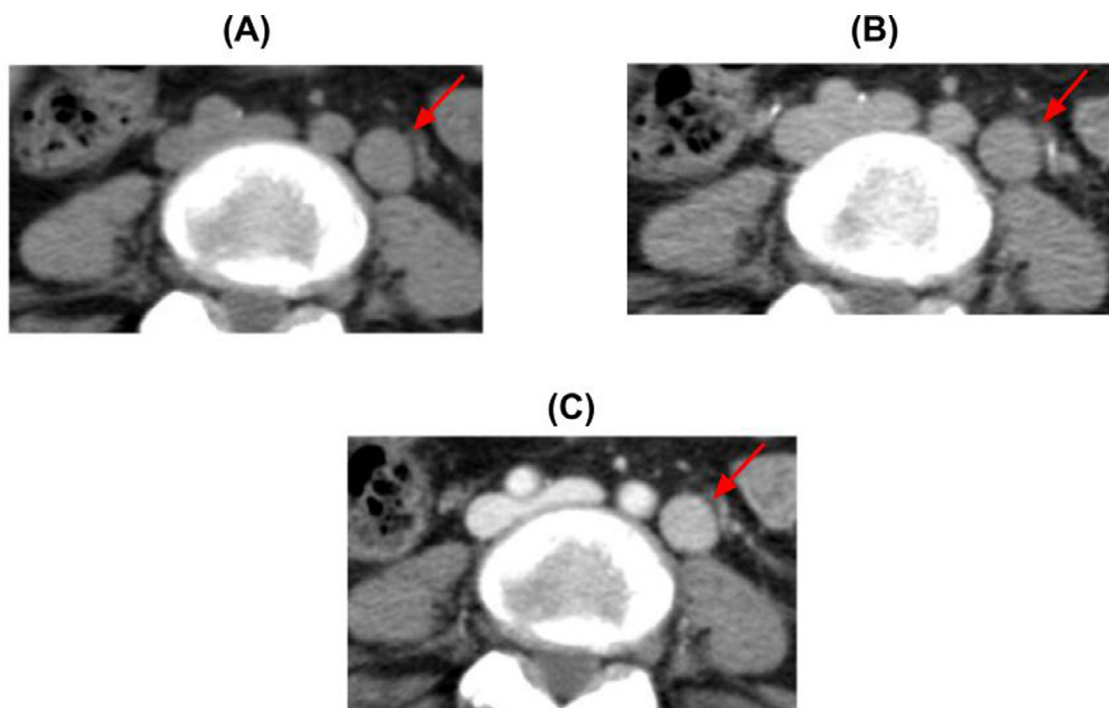
**Fig. 2** – A 21 year-old female with sickle cell anemia. MRI of the abdomen with and without administration of 14 cc of intravenous Clariscan contrast. (A) Axial T2 single shot fast-spin echo sequence with fat suppression (TR = 1041.24, TE = 118.72). (B) Axial LAVA-Flex sequence without contrast (TR = 6.968, TE = 3.368). (C) Axial LAVA-Flex sequence with contrast arterial phase (TR = 6.968, TE = 3.368). (D) Axial LAVA-Flex sequence with contrast portal venous phase (TR = 6.968, TE = 3.368). (E) Axial LAVA-Flex sequence with contrast delayed phase (TR = 6.968, TE = 3.368). Multiple well-circumscribed liver lesions measuring up to 1.8 cm are identified with increased signal intensity on T1 and T2 weighted images (red arrows). These lesions exhibit mild contrast enhancement on arterial phase which persists on delayed phase images. Multiple splenic lesions measuring up to 2.8 cm are also present with similar characteristics (blue arrows). Multiple prominent perisplenic lymph nodes measuring up to 0.7 cm were also redemonstrated on the exam.



**Fig. 3** – A 21 year-old female with a history of sickle cell anemia. Images obtained during ultrasound guided biopsy. A 2.5 cm well-circumscribed hypoechoic lesion is present within the spleen (red arrow). There is no significant vascularity detected within this lesion on color flow Doppler. Histological analysis of tissue samples obtained demonstrated abundant extramedullary hematopoiesis.



**Fig. 4** – A 72 year-old female with chronic myelogenous leukemia complicated by myelofibrosis. (A) CT without contrast enhancement (WW:350, WL:40). (B) CT obtained during nephrographic phase after administration of 75 cc of intravenous Omnipaque 350 contrast (WW:350, WL:40). (C) CT obtained during excretory phase after administration of intravenous contrast (WW:350, WL:40). There is ill-defined soft tissue attenuating material surrounding the calyceal system of both kidneys (red arrows). Multiple well-defined soft tissue attenuating masses measuring up to 2.8 cm surround the calyceal system of the lower pole of the left kidney (blue arrows). These masses have an average attenuation of 41.6 HU without contrast, 98.2 HU during nephrographic phase, and 63.8 HU during excretory phase. Bilateral cortical thinning is also present.

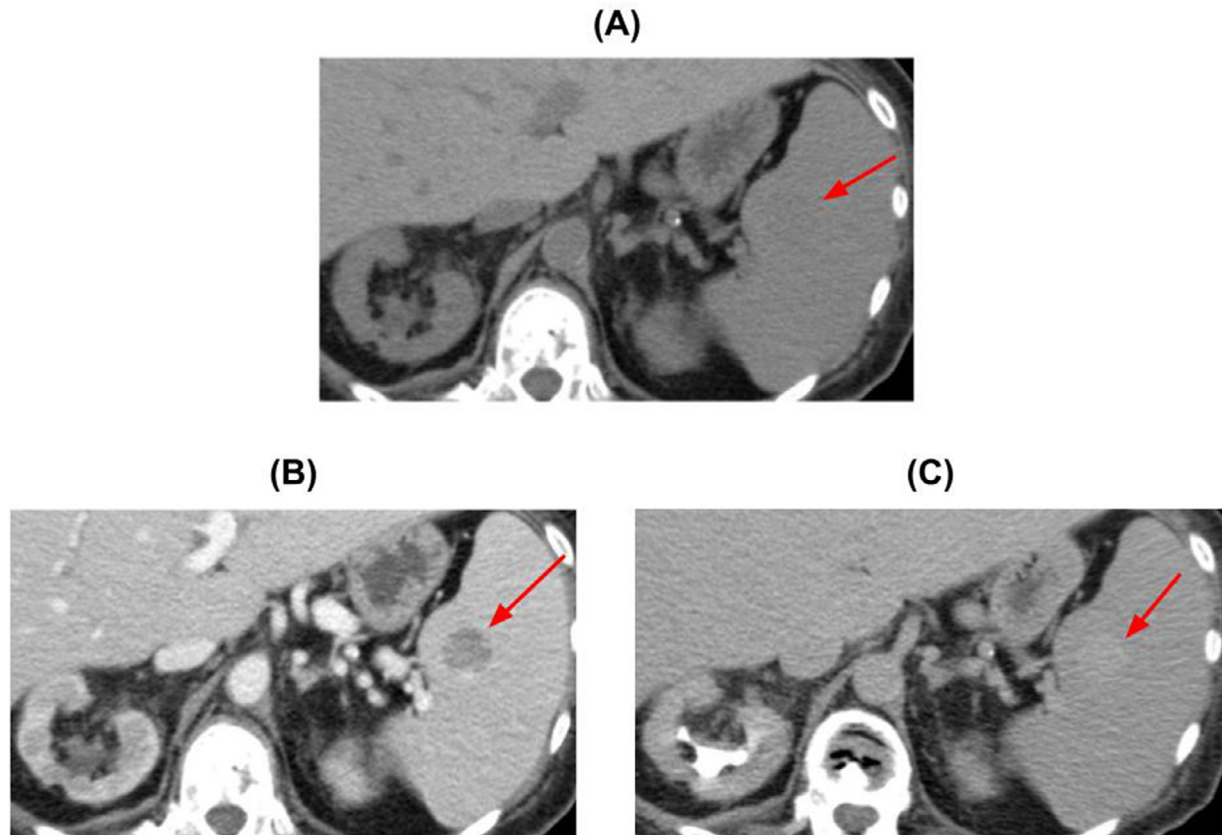


**Fig. 5** – A 72 year-old female with chronic myelogenous leukemia complicated by myelofibrosis. (A) CT without contrast enhancement (WW:350, WL:40). (B) CT obtained during nephrogenic phase after administration of 75 cc of intravenous Omnipaque 350 contrast (WW:350, WL:40). (C) CT obtained during excretory phase after administration of intravenous contrast (WW:350, WL:40). There is an enlarged left para-aortic lymph node identified measuring up to 1.7 cm in short axis (red arrow). This lymph node has an average attenuation of 47.6 HU on noncontrast images, 117.7 HU during nephrogenic phase, and 66.8 HU during excretory phase. Histological analysis of tissue samples obtained during CT-guided biopsy demonstrated abundant extramedullary hematopoiesis. Multiple additional prominent retroperitoneal lymph nodes measuring up to 0.7 cm were also identified on this exam.

is less common in sickle cell anemia when compared to other hemoglobinopathies such as beta thalassemia [4]. Splenic and hepatic involvement in EH that presents as a discrete mass rather than diffuse visceromegaly is even more uncommon [1]. In our literature search, we were able to find fewer than 15 cases describing the imaging appearance of focal intrahepatic EH and fewer than 15 cases that described the imaging appearance of focal intrasplenic EH. In addition, we were only able to find five cases describing the MRI appearance of intrahepatic mass-like EH [3,5,10–12]. In all of the previously published cases, the described hepatic lesions exhibited increased signal intensity on T2-weighted images in relation to the liver. The signal intensity of the described hepatic lesions on T1-weighted imaging was variable. Three of the four cases in which intravenous contrast was administered demonstrated lesions with some degree of contrast enhancement. Only one of the five case reports describes the appearance of intrahepatic mass-like EH in patients with sickle cell anemia on MRI [3]. Jelali, et al. found both mass-like intrahepatic and intrasplenic EH in a patient with sickle cell anemia. Both the intrahepatic and intrasplenic lesions described by Jelali, et al. demonstrated increased signal intensity on T1- and T2-weighted images in respect to the surrounding parenchyma, similar to the first case we reported on. In our case, we observed lesions that

had early arterial enhancement, whereas in the case reported by Jelali, et al., there was no contrast enhancement during the arterial phase for both splenic and hepatic lesions. However, persistent enhancement of splenic and hepatic lesions was observed on delayed phase images in both cases.

The second case we described is that of a 72-year-old female with chronic myelogenous leukemia complicated by myelofibrosis. Imaging demonstrated multiple splenic and pericalyceal masses, presumed to represent areas of EH. In our literature search, we found that fewer than 20 instances of renal EH have previously been reported, and the majority of cases involved both kidneys. We were able to find four cases that described the imaging appearance of pericalyceal mass-like EH [2,6–8]. In all of the previously described cases, the pericalyceal masses had soft tissue attenuation on CT, were relatively hypoenhancing to the renal parenchyma in the nephrogenic phase, and had increased contrast enhancement on delayed phase. Our case differs in that the identified pericalyceal masses were relatively hyperattenuating in relation to the renal parenchyma during the nephrogenic phase. This may be secondary to increased activity in the extramedullary tissue, as it has previously been described that increased activity in extramedullary hematopoietic tissue correlates with the degree of contrast enhancement in EH [1]. Of the four cases of



**Fig. 6 – A 72 year-old female with chronic myelogenous leukemia complicated by myelofibrosis. (A) CT without contrast enhancement (WW:350, WL:40). (B) CT obtained during nephrogenic phase after administration of 75 cc of intravenous Omnipaque 350 contrast (WW:350, WL:40). (C) CT obtained during excretory phase after administration of intravenous contrast (WW:350, WL:40). There is a 2.2 cm well-circumscribed soft tissue attenuating lesion within the spleen (red arrow). This lesion has an average attenuation of 42.2 HU on noncontrast images, 74.9 HU during nephrogenic phase, and 90.7 HU on excretory phase. Mild diffuse splenomegaly is also present.**

pericalyceal mass-like EH identified, three had been formally diagnosed with myelofibrosis at the time of imaging [2,7,6]. In our case, the patient had chronic myelogenous leukemia with myelofibrosis and suspected pericalyceal mass-like EH. Ricci et al. described pericalyceal mass-like extramedullary hematopoiesis in a patient with polycythemia vera, which is often complicated by myelofibrosis throughout the natural course of the disease [8]. This may suggest that findings of pericalyceal mass-like EH on imaging is relatively specific to patients with myelofibrosis. However, more cases will have to be documented and evaluated to confidently establish whether a correlation exists.

### Patient consent

The patients reported in this manuscript have provided consent for participation in research which includes permission to use data collected in future research projects, the presented case details, and the images used in this manuscript.

### REFERENCES

- [1] Georgiades CS, Neyman EG, Francis IR, Sneider MB, Fishman EK. Typical and atypical presentations of extramedullary hemopoiesis. *AJR Am J Roentgenol* 2002;179(5):1239–43. doi:10.2214/ajr.179.5.1791239.
- [2] Gryspeerdt S, Oyen R, Van Hoe L, Baert AL, Boogaerts M. Extramedullary hematopoiesis encasing the pelvicalyceal system: CT findings. *Ann Hematol* 1995;71(1):53–6. doi:10.1007/BF01696233.
- [3] Jelali MA, Luciani A, Kobeiter H, Zafrani S, Anglade MC, Zegai B, et al. MRI features of intrahepatic extramedullary haematopoiesis in sickle cell anaemia. *Cancer Imaging* 2006;6(1):182–5 Published 2006 Nov 28. doi:10.1102/1470-7330.2006.0030.
- [4] Kennedy DP, Hooker JD, Morris RW. Osseous Findings in Sickle Cell Disease. *Appl Radiol* 2020;49(2):30–4.
- [5] Kumar A, Aggarwal S, de Tilly LN. Case of the season. *Thalassemia major with extramedullary hematopoiesis in the liver. Semin Roentgenol* 1995;30(2):99–101.
- [6] Kwak HS, Lee JM. CT findings of extramedullary hematopoiesis in the thorax, liver and kidneys, in a patient

- with idiopathic myelofibrosis. *J Korean Med Sci* 2000;15(4):460–2. doi:[10.3346/jkms.2000.15.4.460](https://doi.org/10.3346/jkms.2000.15.4.460).
- [7] La Fianza A, Torretta L, Spinazzola A. Extramedullary hematopoiesis in chronic myelofibrosis encasing the pelvicaliceal system and perirenal spaces: CT findings. *Urol Int* 2005;75(3):281–4. doi:[10.1159/000087809](https://doi.org/10.1159/000087809).
- [8] Ricci D, Mandreoli M, Valentino M, Sabattini E, Santoro A. Extramedullary haematopoiesis in the kidney. *Clin Kidney J* 2012;5(2):143–5. doi:[10.1093/ckj/sfs015](https://doi.org/10.1093/ckj/sfs015).
- [9] Roberts AS, Shetty AS, Mellnick VM, Pickhardt PJ, Bhalla S, Menias CO. Extramedullary haematopoiesis: radiological imaging features. *Clin Radiol* 2016;71(9):807–14. doi:[10.1016/j.crad.2016.05.014](https://doi.org/10.1016/j.crad.2016.05.014).
- [10] Tamm EP, Rabushka LS, Fishman EK, Hruban RH, Diehl AM, Klein A. Intrahepatic, extramedullary hematopoiesis mimicking hemangioma on technetium-99m red blood cell SPECT examination. *Clin Imaging* 1995;19(2):88–91. doi:[10.1016/0899-7071\(94\)00037-d](https://doi.org/10.1016/0899-7071(94)00037-d).
- [11] Warshauer DM, Schiebler ML. Intrahepatic extramedullary hematopoiesis: MR, CT, and sonographic appearance. *J Comput Assist Tomogr* 1991;15(4):683–5.
- [12] Wong Y, Chen F, Tai KS, Yip LK, Tsang KW, Chan FL, et al. Imaging features of focal intrahepatic extramedullary haematopoiesis. *Br J Radiol* 1999;72(861):906–10. doi:[10.1259/bjr.72.861.10645201](https://doi.org/10.1259/bjr.72.861.10645201).