

Histoplasmosis with Deep CNS Involvement: Case Presentation with Discussion and Literature Review

Omid R. Hariri¹ Tanya Minasian¹ Syed A. Quadri¹ Anya Dyurgerova² Saman Farr² Dan E. Miulli¹
 Javed Siddiqi¹

¹Department of Neurosurgery, Arrowhead Regional Medical Center, Colton, California, United States

²Division of Neurosurgery, Department of Surgery, Western University of Health Sciences, Pomona, California, United States

Address for correspondence Omid R. Hariri, DO, MSc, Department of Neurosurgery, Arrowhead Regional Medical Center, 400 N. Pepper Avenue, Colton, CA 92324, United States (e-mail: ohaririucla@gmail.com).

J Neurol Surg Rep 2015;76:e167–e172.

Abstract

Central nervous system (CNS) histoplasmosis is rare and difficult to diagnose because it is often overlooked or mistaken for other pathologies due to its nonspecific symptoms. A 32-year-old Hispanic man with advanced acquired immunodeficiency virus presented with altered mental status and reported confusion for the past 3 months. He had a Glasgow Coma Scale of 12, repetitive nonfluent speech, and a disconjugate gaze with a right gaze preference. Lung computed tomography (CT) findings indicated a pulmonary histoplasmosis infection. Magnetic resonance imaging of the brain revealed a ring-enhancing lesion in the left caudate nucleus. A CT-guided left retroperitoneal node biopsy was performed and indicated a benign inflammatory process with organisms compatible with fungal yeast. Treatment with amphotericin B followed by itraconazole was initiated in spite of negative cerebrospinal fluid (CSF) cultures and proved effective in mitigating associated CNS lesions and resolving neurologic deficits. The patient was discharged 3 weeks later in stable condition. Six weeks later, his left basal ganglia mass decreased. Early recognition of symptoms and proper steps is key in improving outcomes of CNS histoplasmosis. Aggressive medical management is possible in the treatment of intracranial deep mass lesions, and disseminated histoplasmosis with CNS involvement can be appropriately diagnosed and treated, despite negative CSF and serology studies.

Keywords

- ▶ *Histoplasma capsulatum*
- ▶ disseminated histoplasmosis
- ▶ CNS infection
- ▶ fungal yeast
- ▶ CSF culture
- ▶ ring-enhancing lesion
- ▶ immunocompromised
- ▶ human immunodeficiency virus

Introduction

Histoplasmosis, an infection caused by the dimorphic fungus *Histoplasma capsulatum*, is considered one of the most common fungal respiratory infections in the world. It is endemic in the central and southeastern states of the United States, Latin America, Africa, and now parts of Asia with an estimated 40 million people in the United States infected.¹

H. capsulatum is a dimorphic fungus taking both mycelia and yeast forms. It feeds on nitrogen-rich soils, especially

those replete with bird and bat droppings. When inhabited soils like these are disturbed, spores, which are the reproducing body of the mycelia, can become airborne and inhaled. Once they are inhaled, infection begins. Due to the elevated temperature inside the lungs compared with room air, the spores grow as unicellular haploid yeast cells and are phagocytosed by macrophages. The fungus continues to live within the phagolysosomes of the macrophages where it increases the pH and potentially disturbs intracellular processes.^{2,3}

received
 December 9, 2014
 accepted
 April 6, 2015
 published online
 June 26, 2015

DOI <http://dx.doi.org/10.1055/s-0035-1554932>.
 ISSN 2193-6366.

© 2015 Georg Thieme Verlag KG
 Stuttgart · New York

License terms



Of the documented histoplasmosis infections in immunocompetent individuals, 50 to 90% are asymptomatic, and of the symptomatic infections, 80% require no therapy and are self-resolving.⁴ Conversely, some patients develop a progressive extrapulmonary infection, or rather a disseminated form of histoplasmosis where the infection spreads beyond its origin into other parts of the body. The symptomatic cases of infection are frequently found in immunocompromised patients, especially in individuals with acquired immunodeficiency virus (AIDS), those with ventriculoperitoneal shunts,⁵ recipients of transplants, or in patients taking corticosteroids and tumor necrosis factor- α antagonists.⁴

In particular, 3 to 5% of AIDS patients within endemic areas of North America develop disseminated histoplasmosis.⁶ A prospective study correlated that as an individual's CD4+ count decreases, the risk of acquiring histoplasmosis increases.⁷ Of these 3 to 5% infected immunocompromised patients, 90% have infections that advance into progressive disseminated histoplasmosis (PDH). Of all the patients with PDH, 10 to 20% develop central nervous system (CNS) involvement⁴ that affects the meninges, the spinal cord, and/or the brain.⁸ Patients with a CNS infection have a mortality rate of 20 to 40% and a relapse rate of 50%.⁹

Even though the incidence of CNS histoplasmosis in non-endemic areas is increasing, the diagnosis of isolated CNS histoplasmosis in these areas remains a challenge for clinicians for a number of reasons. CNS histoplasmosis is difficult to diagnose, especially in geographic areas that are not endemic, because it is often overlooked or mistaken for other pathologies due to its nonspecific symptom set. It may include all, some, or none of the following signs: acute and chronic meningitis, stroke due to infected emboli, diffuse encephalitis, ring-enhancing lesions, neurologic deficits, chronic recurrent hydrocephalus, elevated cerebrospinal fluid (CSF) protein, and an elevated CSF white blood cell count.^{4,10-12} Although these signs are indicative of localized CNS histoplasmosis, addition of systemic symptoms, such as a fever or weight loss,¹³ may indicate a disseminated disease.

Failure to diagnose CNS histoplasmosis quickly leads to a prolonged infection and lowers the chance of recovery. The following is a case presentation, discussion, and literature review on disseminated histoplasmosis with CNS involvement in an immunocompromised patient diagnosed outside of the endemic regions.

Case Study

A 32-year-old Hispanic man with advanced AIDS (CD4+ count: 31; 290,000 copies of human immunodeficiency virus RNA) presented with an altered mental status and reported confusion for the past 3 months. He had refused to continue highly active antiretroviral therapy 1 year prior. The patient complained of losing 30 pounds in 3 months and a persistent cough for 3 weeks. The patient's family disclosed that he had a recent fever and chills. The patient had also been admitted 3 weeks prior due to abdominal pain. He had a history of incarceration and deportation. He admitted to tobacco, alcohol, and polysubstance abuse (mainly methamphetamines),

but he denied any use in the past year. The patient was previously employed as a truck driver, and it cannot be ruled out that he may have visited and been exposed to endemic regions of histoplasmosis.

On physical examination, fever was confirmed with a temperature of 101.7°F. The patient was diaphoretic, cachectic, somnolent, and lethargic. Bilateral radial and dorsalis pedis pulses were +2/4. The patient's consciousness level was Glasgow Coma Scale 12 (Motor 6, Verbal 2, Eyes 4) with repetitive nonfluent speech. He had a disconjugate gaze with a right gaze preference and symmetrical movement of his extremities but with poor effort. No pronator drift was noted, and the patient's sensation was grossly intact. Deep tendon reflexes were +2/4 in all extremities. The patient's pupils were equal, round, and reactive to light, and his extraocular movements were intact without nystagmus. The patient's cranial nerves II–XII were grossly intact, and he showed no cerebellar deficits.

Laboratory results such as acid-fast bacilli smears, purified protein derivative, and QuantiFERON Gold were negative for tuberculosis. Blood cultures and CSF cultures showed no growth. CSF studies showed leukocytes (white blood cells) 1/ μ L, red blood cells 1,000/ μ L, lymphocytes 100/ μ L, glucose 48 ng/dL, and total protein 134 mg/dL.

Lung computed tomography (CT) findings indicated a pulmonary histoplasmosis infection. Furthermore, magnetic resonance imaging (MRI) of the brain revealed a ring-enhancing lesion in the left caudate nucleus (**Fig. 1A**). There were no true signs of meningitis on MRI. Given the extensive mass effect and cerebral edema, Decadron was started, as well as seizure prophylaxis with Keppra. A left retroperitoneal node biopsy was performed and indicated a benign inflammatory process with organisms compatible with fungal yeast, strongly suggesting histoplasmosis. Once a diagnosis of disseminated disease with CNS involvement was made, the patient was placed on amphotericin and itraconazole and taken off of Decadron, but Keppra was continued.

Throughout the hospital course, there was clear neurologic improvement, and the patient was discharged 3 weeks later in stable condition. On discharge, he was able to converse, ambulate without difficulty, and adequately perform activities of daily living with assistance. The patient was sent home with instructions to follow up and continue with lifelong antifungal treatment. Six weeks after the initial diagnosis, the patient's left basal ganglia mass significantly decreased from 30 \times 36.9 mm to 28.3 \times 23.3 mm (**Fig. 1B**). Cerebral edema also diminished.

Discussion

Due to its mode of transmission via spore inhalation, histoplasmosis most commonly manifests in the lungs, ranging from pneumonitis to severe acute respiratory distress syndrome. The yeast form is disseminated via macrophages as they travel throughout the body.¹⁴ Individuals with impaired cell-mediated immunity lack the ability to eliminate the intracellular pathogen, which

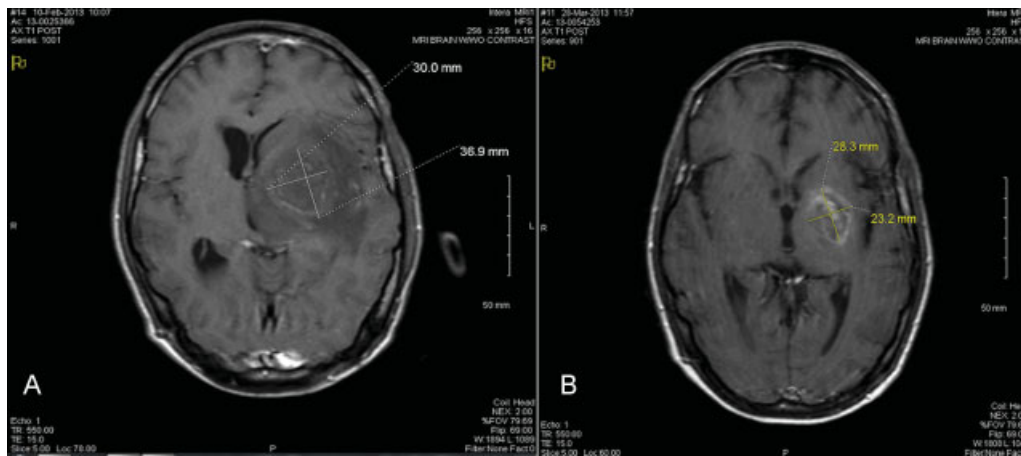


Fig. 1 (A) Pretreatment T1-weighted magnetic resonance imaging (MRI) with gadolinium. Axial image showing left basal ganglia mass of 30×36.9 mm. (B) T1-weighted MRI with gadolinium 6 weeks after treatment was initiated. Axial image showing decrease in left basal ganglia mass to 28.3×23.3 mm.

places them at greater risk for symptomatic histoplasmosis and disseminated disease.

The mechanism of the hematogenous dissemination of the infection to the meninges or brain is not well understood, and there have been very few studies done on this subject. A murine model indicates that *H. capsulatum* protein Yps3p interacts with microglial cells in the CNS, leading to activation of the nuclear factor- κ B via a signaling pathway involving a pathogen recognition receptor on microglial cells, toll-like receptor 2. This stimulates expression of a proinflammatory immune mediator, chemokine (C-C motif) ligand 2 in microglia.¹⁵

CNS histoplasmosis can present with or without pulmonary involvement; some isolated cases with absence of extraneural signs and symptoms have been reported.^{10–12} A study found that the most common symptoms of CNS involvement in PDH are acute or chronic meningitis, a lowered level of consciousness (28.8%), headache (24%), cranial nerve deficiency (19.2%), seizures (13.5%), and confusion.⁸ However, other symptoms are highly diverse among individual cases, and cerebral involvement is only clinically evident in 10 to 20% of patients.⁸

In rare cases, patients with CNS histoplasmosis may present with myelopathy (cervical and thoracic), hydrocephalus (chronic recurrent), or cachexia and hypercalcemia.^{11,12,16} Hydrocephalus is one of the significant complications of this condition that may possibly be identified even before meningitis is diagnosed.¹²

In immunocompetent individuals, *H. capsulatum* infection has been diagnosed in unusual stroke cases^{10,11,17–19} or mistaken for a brain tumor.²⁰ A case with a patient experiencing short-term memory loss and cognitive impairment was also reported.²¹ In our case the patient along with confusion and altered mental status had speech and gaze problems. All possible symptoms reported in the literature at the time of presentation were collated in ► **Table 1**.

Focal CNS infection is also possible but even rarer. An autopsy study showed that the rate of dissemination to the

CNS may be higher than diagnosed and may persist without symptoms, suggesting that focal CNS infection could either be primary infections or manifestations of latent infections.²² *H. capsulatum* can remain in the body undetected for years before it becomes symptomatic; furthermore, it can relapse with a delayed onset of symptoms. This hypothesis is supported by a case of a patient with advanced AIDS and previous disseminated histoplasmosis. The patient presented with a focal CNS infection 12 years after he had been diagnosed with and treated for disseminated histoplasmosis.²³ In another case, an immunocompetent woman in Arizona presented with slight cognitive deficits and seizures 2 years after she had undergone treatment for a gastrointestinal histoplasmosis infection. She was diagnosed with an intramedullary histoplasmosis spinal cord abscess secondary to a relapse of the previous gastrointestinal infection.²⁴

MRIs often show single or multiple ring-enhancing lesions in CNS histoplasmosis cases^{13,16,20,23–29} as presented here. However, ring-enhancing lesions can also be indicative of an abscess, a necrotic tumor,³⁰ subdural and epidural empyema,³¹ or toxoplasmosis.^{27,31} Histoplasmosis should be considered if symptoms correlate to that of the infection or if the patient has had exposure to an endemic area.

Multiple tests for diagnosis of *H. capsulatum* in the CNS are necessary due to the variability in symptoms and the number of false-negative tests. Culturing of the CSF or CNS parenchymal tissue is the gold standard for diagnosis of CNS histoplasmosis. Antigen detection in CSF culture has a sensitivity of 38% and a specificity of 98%.⁹ Additional tests for *H. capsulatum* polysaccharide antigen (HPA) in CSF, urine, or serum can be performed to aid in the diagnosis and monitor response to therapy. The sensitivity of these is 38 to 67%, 71%, and 38%, respectively.⁸ Antibody testing in CSF and serum has 80 to 89% and 92% sensitivity, respectively, although these tests are susceptible to cross-reactivity leading to false positives. Serologic testing is especially difficult with AIDS patients and often provides false negatives even with an active infection.⁸ In addition, positive CSF culture results are

Table 1 Symptoms, diagnostic techniques, and treatment reported/suggested in the literature^a

Symptoms/Possible Presentations Reported in the Literature	
Acute meningitis	
Chronic Meningitis	Undiagnosed up to 10 y because tests for other causes were negative has been reported. ³² It should always be included in the differential diagnoses of chronic meningitis in nonendemic areas even in the case of nonimmunocompromised individuals
Stroke	Recurrent strokes due to infected emboli ^{20,31,34}
Seizures	
Headache	
Focal parenchymal lesions of the brain or spinal cord	Ring-enhancing lesions in brain
Diffuse encephalitis	
Hydrocephalus	It is an important complications of CNS histoplasmosis that may be identified even before meningitis is diagnosed. ³² Chronic recurrent hydrocephalus can occur ³¹
Myelopathy	Cervical and thoracic myelopathy ³¹
Fever or weight loss	
Neurologic deficits	Repetitive nonfluent speech, disconjugate gaze with a right gaze preference ^{our case}
Memory loss	Short-term memory, difficulty recalling names, retaining information while reading and getting lost while driving ³³
Cognitive impairment	Word-finding problems and difficulty organizing, making decisions, and slowed processing speed ³³
Absence of extraneural signs and symptoms	Isolated cases of CNS histoplasmosis with absence of extraneural signs and symptoms have been reported ^{20,31,32}
Diagnostic and Imaging Techniques Reported in the Literature	
Elevated CSF WBC	
Elevated CSF protein	
Decreased CSF glucose	
Immunity level	Although very rare in immunocompetent patients, cases of histoplasmosis have been reported ^{15,18,20,31,34}
Culture	Culture of <i>H. capsulatum</i> from CSF, brain tissue, or other sites is the gold standard for diagnosis
Culture-negative cases	CSF culture could be negative. ^{19,our case} If culture is negative, then in those cases detection of <i>H. capsulatum</i> antigen in CSF, urine, or blood is helpful diagnostically
False-positive tests	It should be noted that antigen or serologic tests may also show false-positive results because of cross reactions due to infections by other fungi ³²
Low sensitivity	It is essential to do repeated cultures with a large volume of CSF because of the low sensitivity of the culture. It is recommended that tests for CNS histoplasmosis be repeated with large volumes of CSF even if negative results are obtained initially ^{32, our case}
Neuroendoscopic examination and biopsy	A biopsy of the floor of the third ventricle and the subarachnoid space, and the collection of ventricular CSF contributed to the correct diagnoses of histoplasmosis after CSF cultures and CSF antibody tests were negative ^{12,19}
CT-guided biopsy of a retroperitoneal lymph node	CT-guided biopsy of a retroperitoneal lymph node yielded the results with much less morbidity than a left-sided dominant hemisphere deep basal ganglia lesion biopsy would have [our case]
Treatment Reported/Suggested in the Literature	

Table 1 (Continued)

Liposomal amphotericin B	Initial course ^{20,21,31,32,our case}
Itraconazole	For 1 y after the initial course of liposomal amphotericin B ^{20,21,31,32, our case}
Fluconazole	20,21,31,32
Newer azoles	Newer azoles such as voriconazole have been shown to be effective in both immunocompromised and immunocompetent hosts ^{18,29}

Abbreviations: CNS, central nervous system; CSF, cerebrospinal fluid; CT, computed tomography; WBC, white blood cells.

^aIt should be kept in mind that patients presenting with these symptoms can be immunocompromised or immunocompetent belonging to endemic or nonendemic areas with or without any extraneural signs and symptoms.

similar to results seen in other fungal and tuberculous meningitis.¹ Therefore, other tests must be performed.

Multiple antigen and culture tests must be performed given the low sensitivities of each of the individual tests. A recent study found variability between spinal and ventricular CSF histoplasmosis antibody test results. Rangel-Castilla et al described a case of CNS histoplasmosis with basilar arachnoiditis where CSF cultures and CSF antibody tests were negative. To diagnose the patient, a neuroendoscopic examination of the ventricles and basal cisterns was done. A biopsy of the floor of the third ventricle and the subarachnoid space, and the collection of ventricular CSF contributed to the correct diagnoses of histoplasmosis.³² The antibodies were only identifiable in the ventricular CSF. It was hypothesized that the differences observed were a sequela of compartmentalization of the subarachnoid space caused by arachnoid membrane scarring as a result of an inflammatory process.³² Similarly, in another study, a diagnosis was made only after testing the patient's ventricular CSF 5 months after the infection started, making the recovery much more arduous.²⁶

Similarly, histoplasmosis remained undetected in the present case until a more aggressive diagnostic approach was performed. In our case a CT-guided biopsy of a retroperitoneal lymph node yielded the results with much less morbidity than a left-sided dominant hemisphere deep basal ganglia lesion biopsy would have. A correct diagnosis was procured despite the negative CSF cultures, urine, and blood tests, and it decreased the risk of possible complications accompanying a brain biopsy.

In most CNS histoplasmosis cases, one or a combination of any three antifungals, amphotericin B, fluconazole, and itraconazole, have been used. Although no prospective studies of an optimal treatment regimen for CNS histoplasmosis are available, numerous case reports have documented variable success of initial treatment with amphotericin B followed by a triazole (e.g., fluconazole, itraconazole, or voriconazole).^{10–12,29} Newer azoles such as voriconazole are currently being studied for efficacy in CNS histoplasmosis and may be shown to provide more consistent success in the future.³³

Liposomal amphotericin B is preferred over standard amphotericin B formulation for its greater CNS penetration and lower toxicity. The Infectious Diseases Society of America's 2007 Guidelines for Management of Histoplasmosis

recommend 5.0 mg/kg of liposomal amphotericin B for 4 to 6 weeks. This should be followed by itraconazole for at least 12 months until CSF findings and HPA are negative for immunocompetent patients.³⁴ In immunosuppressed patients, such as the present case, lifelong antifungal therapy may be needed to prevent relapse.

Conclusion

This case, along with numerous other published cases, illustrates that CNS histoplasmosis can present with a wide array of signs and symptoms with or without extraneural involvement even in nonendemic areas irrespective of the patient's immunologic status, making it more difficult for clinicians to diagnose. However clinical recovery from CNS histoplasmosis is possible with early recognition of symptoms and proper steps toward a correct diagnosis. An aggressive regime of more invasive testing may be required.

Treatment with amphotericin B followed by itraconazole proved effective in mitigating associated CNS lesions and resolving neurologic deficits. This case demonstrates that with aggressive medical management, treating intracranial deep mass lesions is possible, and that disseminated histoplasmosis with CNS involvement can be correctly diagnosed and treated, despite negative CSF and serology studies. The critical step in ensuring survival in patients with a CNS histoplasmosis infection is a quick diagnosis. Therefore, histoplasmosis should be considered in cases of chronic meningitis, focal brain lesions, recurrent hydrocephalus, and unexplained neurologic symptoms.

References

- 1 Kauffman CA. Histoplasmosis: a clinical and laboratory update. *Clin Microbiol Rev* 2007;20(1):115–132
- 2 Eissenberg LG, Goldman WE, Schlesinger PH. Histoplasma capsulatum modulates the acidification of phagolysosomes. *J Exp Med* 1993;177(6):1605–1611
- 3 Sebghati TS, Engle JT, Goldman WE. Intracellular parasitism by *Histoplasma capsulatum*: fungal virulence and calcium dependence. *Science* 2000;290(5495):1368–1372
- 4 Trofa D, Nosanchuk JD. Histoplasmosis of the central nervous system. *J Neuroparasitology* 2012;3:1–7

- 5 Veeravagu A, Ludwig C, Camara-Quintana JQ, Jiang B, Lad N, Shuer L. Fungal infection of a ventriculoperitoneal shunt: histoplasmosis diagnosis and treatment. *World Neurosurg* 2013;80(1-2):222. e5-222.e13
- 6 Goldman M, Zackin R, Fichtenbaum CJ, et al; AIDS Clinical Trials Group A5038 Study Group. Safety of discontinuation of maintenance therapy for disseminated histoplasmosis after immunologic response to antiretroviral therapy. *Clin Infect Dis* 2004;38(10):1485-1489
- 7 McKinsey DS, Spiegel RA, Hutwagner L, et al. Prospective study of histoplasmosis in patients infected with human immunodeficiency virus: incidence, risk factors, and pathophysiology. *Clin Infect Dis* 1997;24(6):1195-1203
- 8 Wheat LJ, Musial CE, Jenny-Avital E. Diagnosis and management of central nervous system histoplasmosis. *Clin Infect Dis* 2005;40(6):844-852
- 9 Black KE, Baden LR. Fungal infections of the CNS: treatment strategies for the immunocompromised patient. *CNS Drugs* 2007;21(4):293-318
- 10 Saccente M. Central nervous system histoplasmosis. *Curr Treat Options Neurol* 2008;10(3):161-167
- 11 Carod-Artal F, Venturini M, Gomes E, de Mello M. Chronic central nervous system histoplasmosis in an immunocompetent patient [in Spanish]. *Neurologia* 2008;23(4):263-268
- 12 Hamada M, Tsuji S. Central nervous system histoplasmosis [in Japanese]. *Brain Nerve* 2009;61(2):129-134
- 13 Vullo V, Mastroianni CM, Ferone U, et al. Central nervous system involvement as a relapse of disseminated histoplasmosis in an Italian AIDS patient. *J Infect* 1997;35(1):83-84
- 14 Guarner J, Brandt ME. Histopathologic diagnosis of fungal infections in the 21st century. *Clin Microbiol Rev* 2011;24(2):247-280
- 15 Aravalli RN, Hu S, Woods JP, Lokensgard JR. Histoplasma capsulatum yeast phase-specific protein Yps3p induces Toll-like receptor 2 signaling. *J Neuroinflammation* 2008;5:30
- 16 Khasawneh FA, Ahmed S, Halloush RA. Progressive disseminated histoplasmosis presenting with cachexia and hypercalcemia. *Int J Gen Med* 2013;6:79-83
- 17 Nguyen FN, Kar JK, Zakaria A, Schiess MC. Isolated central nervous system histoplasmosis presenting with ischemic pontine stroke and meningitis in an immune-competent patient. *JAMA Neurol* 2013;70(5):638-641
- 18 Ramireddy S, Wanger A, Ostrosky L. An instructive case of CNS histoplasmosis in an immunocompetent host. *Med Mycol Case Rep* 2012;1(1):69-71
- 19 Cleary JD, Pearson M, Oliver J, Chapman SW. Association between Histoplasma exposure and stroke. *J Stroke Cerebrovasc Dis* 2008;17(5):312-319
- 20 Paphitou NI, Barnett BJ. Solitary parietal lobe histoplasmosis mimicking a brain tumor. *Scand J Infect Dis* 2002;34(3):229-232
- 21 Loughan AR, Perna R, Hertz J. Cognitive impairment and memory loss associated with histoplasmosis: a case study. *Clin Neuropsychol* 2014;28(3):514-524
- 22 Shapiro JL, Lux JJ, Sproffkin BE. Histoplasmosis of the central nervous system. *Am J Pathol* 1955;31(2):319-335
- 23 Azizirad O, Clifford DB, Groger RK, Prelutsky D, Schmidt RE. Histoplasmosis: isolated central nervous system infection with Histoplasma capsulatum in a patient with AIDS. Case report and brief review of the literature. *Clin Neurol Neurosurg* 2007;109(2):176-181
- 24 Hott JS, Horn E, Sonntag VKH, Coons SW, Shetter A. Intramedullary histoplasmosis spinal cord abscess in a nonendemic region: case report and review of the literature. *J Spinal Disord Tech* 2003;16(2):212-215
- 25 John AM, Vasanthi N, Khurana A, et al. An unusual cause for rings in the brain. *Hong Kong Med J* 2012;18(4):346-347
- 26 Klein CJ, Dinapoli RP, Temesgen Z, Meyer FB. Central nervous system histoplasmosis mimicking a brain tumor: difficulties in diagnosis and treatment. *Mayo Clin Proc* 1999;74(8):803-807
- 27 Murata M, Furusyo N, Otaguro S, Nabeshima S, Ariyama I, Hayashi J. HIV infection with concomitant cerebral toxoplasmosis and disseminated histoplasmosis in a 45-year-old man. *J Infect Chemother* 2007;13(1):51-55
- 28 Parihar A, Tomar V, Ojha BK, Husain N, Gupta RK. Magnetic resonance imaging findings in a patient with isolated histoplasma brain abscess. *Arch Neurol* 2011;68(4):534-535
- 29 Saccente M, McDonnell RW, Baddour LM, Mathis MJ, Bradsher RW. Cerebral histoplasmosis in the azole era: report of four cases and review. *South Med J* 2003;96(4):410-416
- 30 Smith JS, Quiñones-Hinojosa A, Phillips JJ, Bollen AW, McDermott MW, Cha S. Limitations of diffusion-weighted imaging in distinguishing between a brain tumor and a central nervous system histoplasmosis. *J Neurooncol* 2006;79(2):217-218
- 31 Kastrup O, Wanke I, Maschke M. Neuroimaging of infections. *NeuroRx* 2005;2(2):324-332
- 32 Rangel-Castilla L, Hwang SW, White AC, Zhang YJ. Neuroendoscopic diagnosis of central nervous system histoplasmosis with basilar arachnoiditis. *World Neurosurg* 2012;77(2):E9-E13
- 33 Wheat LJ, Connolly P, Smedema M, et al. Activity of newer triazoles against Histoplasma capsulatum from patients with AIDS who failed fluconazole. *J Antimicrob Chemother* 2006;57(6):1235-1239
- 34 Wheat LJ, Freifeld AG, Kleiman MB, et al; Infectious Diseases Society of America. Clinical practice guidelines for the management of patients with histoplasmosis: 2007 update by the Infectious Diseases Society of America. *Clin Infect Dis* 2007;45(7):807-825