



The Transpetrosal-Ridge Approach: A Modification of the Combined Transpetrosal Approach

Eddie T.W. Tan

■ **BACKGROUND:** Petroclival tumors are formidable challenges for skull base surgeons. Obtaining adequate surgical access is a paramount consideration. Although the combined transpetrosal approach provides a wide surgical corridor, it is technically challenging and, to a degree, morbid. This article describes the transpetrosal-ridge approach, which is a modification of the combined transpetrosal approach with improvements with regards to ease of execution and reduced surgical morbidity.

■ **METHODS:** The key elements of the transpetrosal-ridge approach are outlined, followed by a detailed description of the steps. The head is placed in the lateral position. After skin incision and muscle elevation, a temporo-suboccipital craniotomy is performed. Middle fossa dura is elevated to the petrous ridge. A limited mastoidectomy is performed with preservation of the semicircular canals. The remaining petrous ridge is then resected and the posterior fossa dura is opened, with the opening extending through the trigeminal dural ring.

■ **RESULTS:** Steps of the combined transpetrosal approach that do not contribute to the final surgical corridor are omitted. Extensive mastoid and petrous apex resection is avoided. Posterior fossa dural opening extending through the trigeminal dural ring is a critical step, as it detaches the superior petrosal sinus and sigmoid sinus from the petrous bone. With the retraction of the temporal lobe and the cerebellum and sigmoid sinus, a wide surgical corridor is obtained.

■ **CONCLUSIONS:** The transpetrosal-ridge approach is a modification of the combined transpetrosal approach with optimization of the operative steps while continuing to provide a wide surgical corridor to the petroclival region.

INTRODUCTION

Tumors of the petroclival region, where the petrous temporal bone meets the clival part of the occipital bone along the petroclival fissure,¹ remain formidable for skull base surgeons.² These tumors can compress the brainstem, displace cranial nerves, and engulf arteries and veins, making surgical resection technically difficult and hazardous. Even benign tumors, such as meningiomas, can be associated with significant operative risks when located in the petroclival region; in the modern era, surgical mortality of petroclival meningiomas of up to 13.5% has been reported.³

For these tumors, obtaining adequate surgical access is a paramount consideration. Accordingly, as skull base surgery has evolved and matured, numerous skull base approaches have become established in gaining access to the petroclival region, particularly the retrosigmoid approach⁴ and the transpetrosal approaches (anterior, posterior, and combined).⁵⁻⁷ In recent years, endonasal surgeons have begun to access these tumors through the expanded endoscopic endonasal route.⁸

Hakuba et al.⁹ first described the combined transpetrosal approach in 1988. It provides the surgeon with a wide corridor for visualization, dissection, and tumor resection. Over the years, this approach has been developed, used, and modified by numerous other surgeons.¹⁰⁻²² The key elements of the approach are 1) temporo-suboccipital craniotomy, 2) mastoidectomy, 3) petrous apex resection, and 4) middle and posterior fossa dural opening with sectioning of the superior petrosal sinus and tentorium up to the tentorial incisura. Either the craniotomy or the mastoidectomy can be performed first, with some surgeons favoring the former^{9-11,14,18-20} and others the latter.^{12,13,15-17,21,22} Resection of part^{9,13} or all¹² of the semicircular canals further improves surgical exposure at the expense of hearing loss. In addition to the potential hearing loss, other approach-related morbidities include temporal lobe edema from retraction, venous congestion from venous thrombosis or sacrifice, and cerebrospinal fluid leak.

Key words

- Combined transpetrosal approach
- Skull base surgery

Abbreviations and Acronyms

- AE:** Arcuate eminence
PSC: Posterior semicircular canal
SSC: Superior semicircular canal

Department of Neurosurgery, National Neuroscience Institute, Singapore

To whom correspondence should be addressed: Eddie T.W. Tan, M.B.B.S., B.Med.Sc.
[E-mail: eddie.tan.t.w@icloud.com]

Citation: *World Neurosurg.* X (2019) 2:100009.
<https://doi.org/10.1016/j.wnsx.2019.100009>

Journal homepage: www.journals.elsevier.com/world-neurosurgery-x

Available online: www.sciencedirect.com

2590-1397/© 2019 The Author(s). Published by Elsevier Inc. This is an open access article under the CC BY-NC-ND license (<http://creativecommons.org/licenses/by-nc-nd/4.0/>).

Worldwide, tolerance for surgical morbidity is ever diminishing. Skull base surgeons face increasing pressure to reduce the morbidity of their approaches while providing adequate access for tumor resection. With novel approaches to the petroclival region such as the expanded endoscopic endonasal approach⁸ and the application of the keyhole concept^{23,24} as well as competition from radiosurgery²⁵ and targeted medical therapy,²⁶ there is a strong impetus for continued modifications to improve existing techniques such as the combined transpetrosal approach. This is particularly important because surgery will likely remain an important tool in the armamentarium of the skull base surgeons for the foreseeable future, even for benign tumors; although fractionated radiotherapy may be able to curtail their growth, those compressing the brainstem will still require surgical resection.

The combined transpetrosal approach provides a wide surgical corridor to petroclival tumors at the cost of technical difficulty and surgical morbidity. This article describes the transpetrosal-ridge approach, a modification of the combined transpetrosal approach with improvements with regards to ease of execution and reduced surgical morbidity. The label “transpetrosal-ridge approach” is used as its maneuvers are directed toward the final aim of resecting the entire petrous ridge before dural opening.

OVERVIEW

The key elements of the transpetrosal-ridge approach, in sequence, are as follows: 1) temporo-suboccipital craniotomy, 2) subtemporal elevation of middle fossa dura to the petrous ridge, 3) limited mastoidectomy with preservation of the semicircular canals, 4) completion of petrous ridge resection, and 5) posterior fossa dural opening extending through the trigeminal dural ring.

Similar to the technique of Kunihiro et al.,¹⁸ the craniotomy is performed before the mastoidectomy so that elevation of the posterior fossa dura enables “safe and swift” mastoid bone resection. In the transpetrosal-ridge approach, a complete mastoidectomy is deemed unnecessary as the anterolateral part of the bone resected in a standard mastoidectomy does not contribute to the final approach (Figure 1). Instead, only a small amount (~7 mm) of the medial mastoid surface facing the posterior fossa dura is resected, with progressive elevation of posterior fossa dura toward the posterior semicircular canal (PSC). After skeletonization of the PSC and superior semicircular canal (SSC), attention is turned to the remaining petrous ridge, where, again, only a small amount (~7 mm) of bone along the petrous ridge is resected.

Dural opening is similar to that described by Hafez et al.,²⁷ with the only difference being the emphasis in the transpetrosal-ridge approach on the opening of the trigeminal dural ring. A L-shaped dural opening is carried out, with one limb just anterior to the sigmoid sinus (posterior to the endolymphatic sac) and the other just caudal to the superior petrosal sinus. The latter limb extends into the trigeminal dural ring, opening it completely. After retraction of the temporal lobe and the cerebellum and sigmoid sinus, the final exposure provides a panoramic view of the petroclival region and a wide corridor for surgical dissection and tumor resection.

TECHNIQUE

Head Position and Skin Incision

Lumbar drainage should be used to aid dural sac relaxation, particularly for the subsequent step of subtemporal elevation of

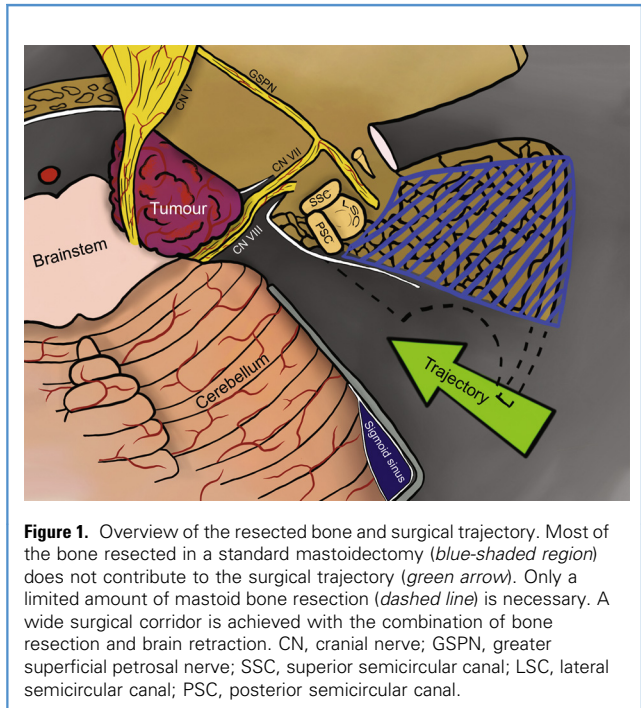


Figure 1. Overview of the resected bone and surgical trajectory. Most of the bone resected in a standard mastoidectomy (blue-shaded region) does not contribute to the surgical trajectory (green arrow). Only a limited amount of mastoid bone resection (dashed line) is necessary. A wide surgical corridor is achieved with the combination of bone resection and brain retraction. CN, cranial nerve; GSPN, greater superficial petrosal nerve; SSC, superior semicircular canal; LSC, lateral semicircular canal; PSC, posterior semicircular canal.

the middle fossa dura. The head is placed in the horizontal position, with the body either in the supine position with a roll under the torso or in the lateral position. The skin incision begins approximately 1 cm anterior to the tragus, goes cranially until the superior temporal line, turns posteriorly, then turns caudally approximately 6 cm posterior to the external auditory canal, and ends at the level of the mastoid tip (Figure 2A). The skin flap is elevated off the temporalis muscle, pericranium, and suboccipital muscles. A pericranial or temporalis fascia flap may be harvested to aid subsequent dural closure. The temporalis muscle is elevated and retracted anteriorly. The suboccipital muscles are elevated and retracted caudally (Figure 2B).

Temporo-suboccipital Craniotomy

Neuronavigation can be useful for outlining the transverse and sigmoid sinuses. In the absence of neuronavigation, standard landmarks are used.¹ Particular care is taken to not place a burr hole directly on a sinus and to not cut across a sinus with the craniotome until the sinus has been elevated off the overlying bone. Multiple burr holes are placed: just cranial to the zygomatic root, on both sides of the transverse sinus medially and laterally, and medial to the caudal part of the sigmoid sinus (Figure 2B). An optional parietal burr hole may be placed if adherent dura is encountered. Care should be taken in the process of joining the burr holes across the transverse sinus. Here, the author prefers to thin the bone with a high-speed drill and then cut across with the Kerrison punch after separating the sinus from the overlying bone. The rest of the bone cuts may be carried out with a craniotome. Once the craniotomy has been completed, the bone flap is lifted off, exposing part of the supratentorial dura, posterior fossa dura, and the transverse sinus (Figure 2C). The squamous temporal bone is drilled flat to the

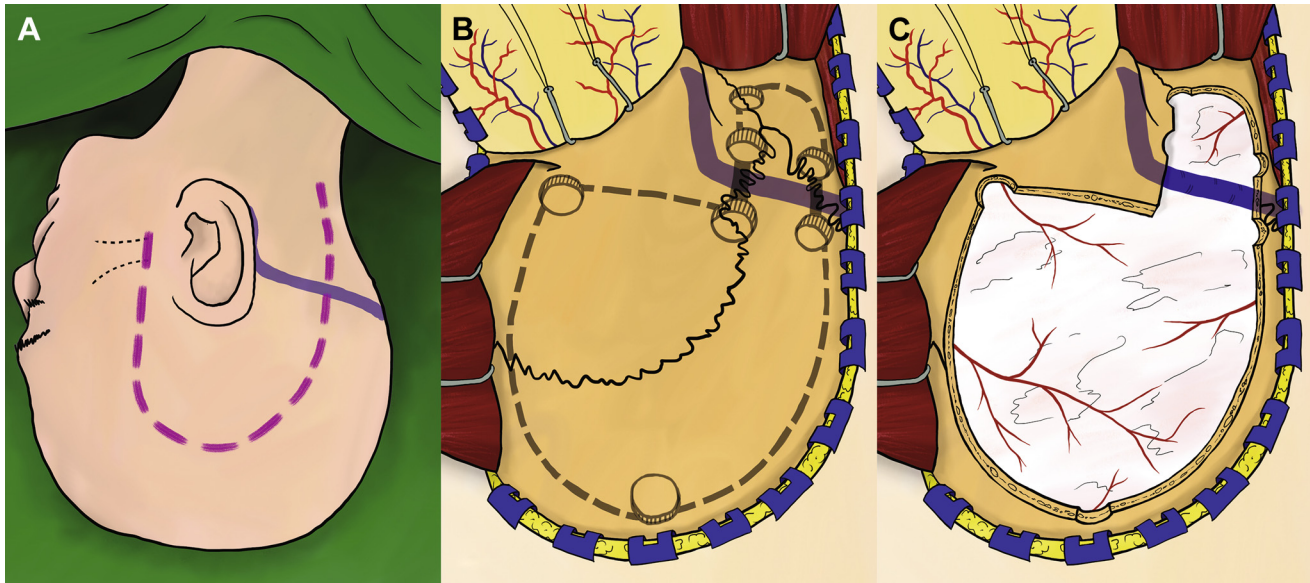


Figure 2. Skin incision, burr holes, and craniotomy. (A) Skin incision. (B) Burr holes and craniotomy. (C) Exposure after the craniotomy. A craniotome can be used along the *dashed lines* (B). When connecting the burr holes across the transverse sinus (*solid lines* in B), it is preferable to thin the bone with a high-speed drill and then cut across with the Kerrison punch after separating the sinus from the overlying bone.

middle fossa floor to improve visualization and to reduce the need for excessive temporal lobe retraction subsequently.

Subtemporal Elevation of Middle Fossa Dura

The middle fossa dura is elevated progressively toward the petrous ridge. The middle meningeal artery is coagulated and divided. Care should be taken to not injure the greater superficial petrosal nerve and the geniculate ganglion. Dura propria overlying the trigeminal nerve is incised sharply, and dural elevation is carried out progressively using a combination of blunt and sharp dissection. Adherent dura should be incised rather than forcefully elevated. Once the petrous ridge has been reached, dural elevation is turned posteriorly along the petrous ridge toward the arcuate eminence (AE). The AE is usually identifiable as a bony prominence just adjacent to the petrous ridge. Once identified, it is marked with a surgical marker (Figure 3) and will serve as a guide to the location of the PSC in the following step.

Limited Mastoidectomy

Attention is now turned to the mastoid bone and posterior fossa. One alternates between elevation of the sigmoid sinus and pre-sigmoid dura off the mastoid and resection of the mastoid bone, removing approximately 7 mm (slightly bigger than the width of a 5-mm round burr) of the medial mastoid bone facing the sigmoid sinus and pre-sigmoid dura progressively toward the PSC. With the sigmoid sinus and pre-sigmoid dura elevated, mastoid resection can be performed rapidly using a combination of cutting burrs and rongeurs (Figure 4). As the drilling nears the marked AE, it is slowed and additional care is taken to identify the solid cortical bone of the PSC amidst the sponge-like mastoid air cells. At the same time, one looks out for the endolymphatic duct during dural elevation. The endolymphatic duct is a constant

anatomical feature that appears as a fold of dura entering the bone just deep to the most superficial part of the PSC. Using these 3 features—AE, solid cortical bone of the PSC, and endolymphatic duct—the PSC can be identified consistently.

Once identified, the donut shape of its cortical bone is skeletonized. Care must be taken to not injure the facial nerve, which can course just anterior-caudal to the PSC. If in doubt, one should err on the side of caution and leave more bone behind.

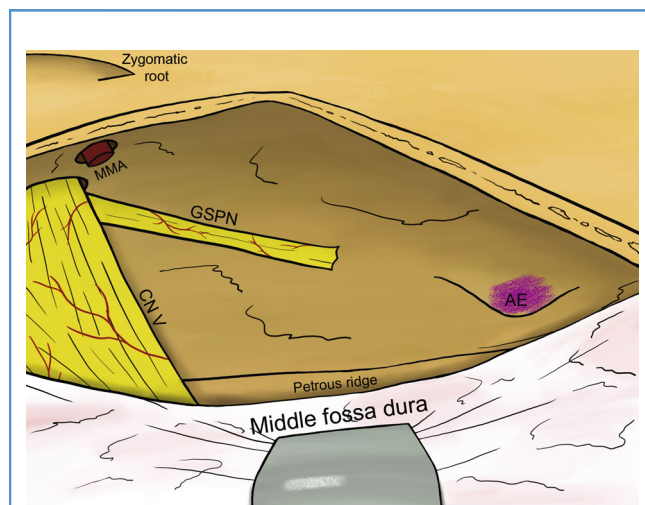


Figure 3. View of the middle fossa floor after elevation of middle fossa dura to the petrous ridge, and identification and marking of the arcuate eminence. MMA, middle meningeal artery; GSPN, greater superficial petrosal nerve; CN, cranial nerve; AE, arcuate eminence.

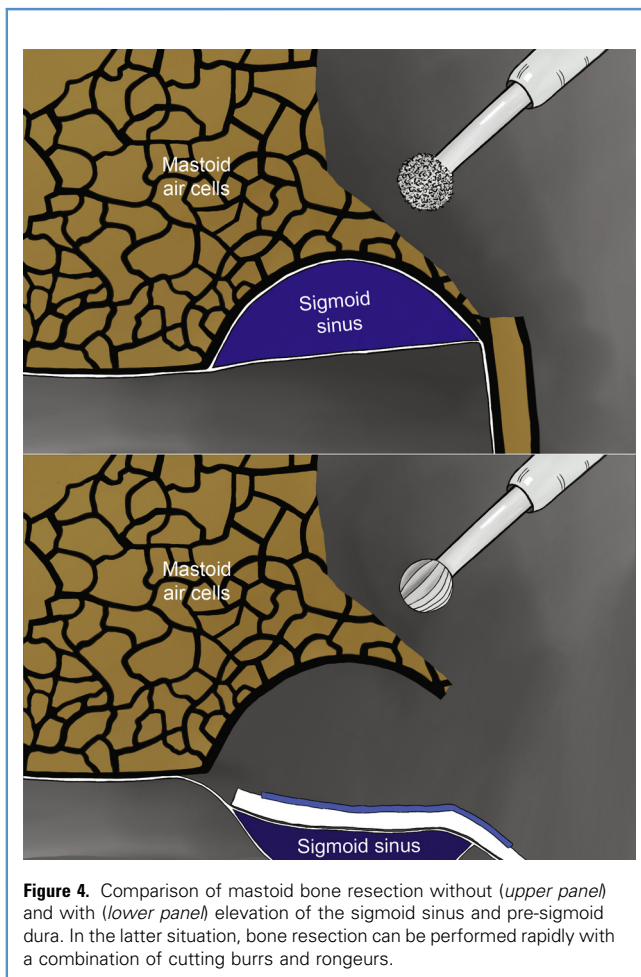


Figure 4. Comparison of mastoid bone resection without (*upper panel*) and with (*lower panel*) elevation of the sigmoid sinus and pre-sigmoid dura. In the latter situation, bone resection can be performed rapidly with a combination of cutting burrs and rongeurs.

Inadvertent breach of the PSC can be managed with the application of bone wax to the opening. Next, the SSC can be identified and skeletonized, guided by the location of the AE, solid cortical bone of the SSC, and location of the PSC. Once the PSC and SSC have been skeletonized, the limited mastoidectomy is complete (**Figure 5**).

Completion of Petrous Ridge Resection

Attention is now turned to the remainder of the petrous ridge in the region of the petrous apex. Approximately 7 mm (slightly bigger than the width of a 5-mm round burr) of the remaining petrous ridge from the SSC to the trigeminal nerve is drilled off (**Figure 6**). Before drilling, the superior petrosal sinus is elevated off the petrous ridge to protect it from injury. By staying along the petrous ridge, there is almost no risk of injury to the petrous internal carotid artery and the cochlea.

Dural Opening

First, the posterior fossa dura is opened along the anterior border of the sigmoid sinus, avoiding the endolymphatic sac. Next, the cranial end of the opening is extended anteriorly, coursing just caudal to the superior petrosal sinus. Care is taken to not injure the superior petrosal vein, which drains into the superior petrosal

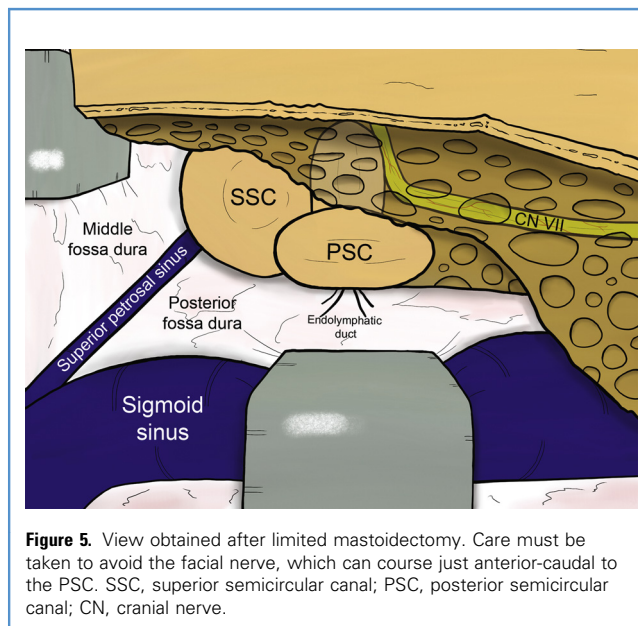


Figure 5. View obtained after limited mastoidectomy. Care must be taken to avoid the facial nerve, which can course just anterior-caudal to the PSC. SSC, superior semicircular canal; PSC, posterior semicircular canal; CN, cranial nerve.

sinus. The dural opening is carried all the way to and through the trigeminal dural ring, opening it completely (**Figure 6**). At this point, the approach is complete. Dural leaves are retracted with stay sutures. With retraction of the temporal lobe (protected by the middle fossa dura) and the cerebellum and sigmoid sinus, one obtains a panoramic view of the petroclival region and a wide surgical corridor (**Figure 7**).

Closure

Achieving primary dural closure is unlikely due to a degree of dural contraction from bipolar coagulation and desiccation. Dura may be closed with either a pericranial or temporalis fascia flap harvested during the opening. Alternatively, autologous fascial grafts (e.g., fascia lata) or commercial dural substitutes may be used. Autologous fat grafts are used to pack the extradural surgical cavity. Surgical sealants may be helpful in reducing the risk of cerebrospinal fluid leak. External bony defects may be reconstructed with bone cement or titanium plates. Subcutaneous tissues and skin are closed in layers.

DISCUSSION

The complexity and morbidity associated with complicated skull base approaches prevent their widespread use; complexity limits their usage to only highly trained and experienced surgeons, whereas morbidity turns away potential surgeons who are keen to learn them. Overall, this leads to an underuse of valuable approaches for skull base lesions. One must bear in mind the fact that the vast majority of skull base surgeons are not on par with highly skilled and experienced surgeons at high-volume centers. The availability of less technically difficult approaches will encourage young surgeons to take up skull base surgery, leading to greater benefit to patients.

The aim of the transpetrosal-ridge approach is to provide a simplified yet powerful workhorse approach for lesions of the petroclival region. The steps of the transpetrosal-ridge approach

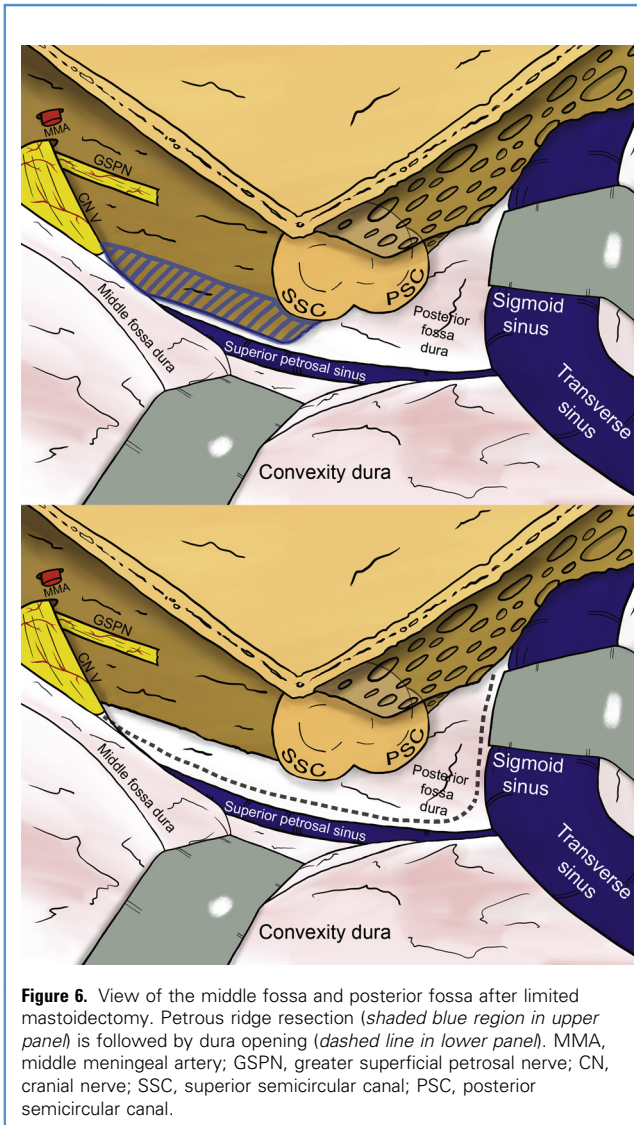


Figure 6. View of the middle fossa and posterior fossa after limited mastoidectomy. Petrous ridge resection (shaded blue region in upper panel) is followed by dura opening (dashed line in lower panel). MMA, middle meningeal artery; GSPN, greater superficial petrosal nerve; CN, cranial nerve; SSC, superior semicircular canal; PSC, posterior semicircular canal.

are deeply thought through and optimized for safety and expeditiousness. Maneuvers that do not contribute to the final surgical exposure are omitted, reducing operating time and potential associated morbidity. The sequence of maneuvers is highly logical in how the one step benefits the next. By performing the craniotomy first, dura can be elevated off the middle fossa floor and the AE can be identified. In addition, the sigmoid sinus and pre-sigmoid dura can be elevated off the mastoid, greatly facilitating the limited mastoidectomy. The AE identification assists in the identification of the PSC, which in turn, assists in the identification of the SSC. Finally, with the SSC identified, the remaining petrous ridge can be resected easily.

From a technical standpoint, the transpetrosal-ridge approach differs from previously reported combined transpetrosal approaches mainly with regards to the amount of bone resection (during the mastoidectomy and petrous apex resection) and dural opening. In the limited mastoidectomy described here, one avoids the complicated and time-consuming steps of the

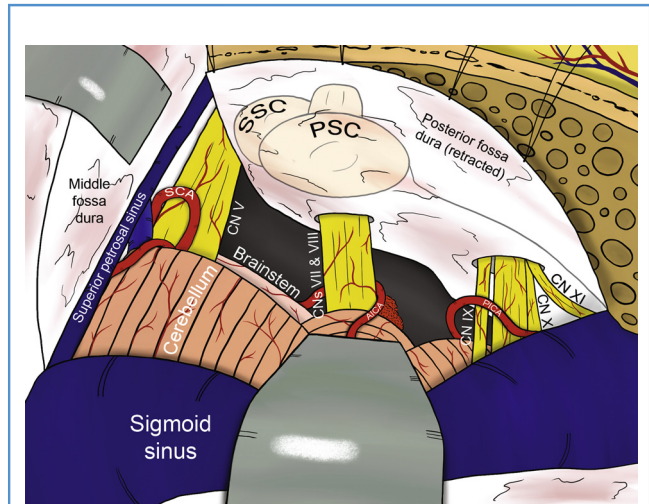


Figure 7. Final view with retraction of the temporal lobe and the cerebellum and sigmoid sinus. SSC, superior semicircular canal; PSC, posterior semicircular canal; SCA, superior cerebellar artery; CN, cranial nerve; AICA, anterior inferior cerebellar artery; PICA, posterior inferior cerebellar artery.

standard mastoidectomy, including skeletonization of the fallopian canal. Instead, the medial, dura-facing part of the mastoid is resected progressively toward the PSC, which is identified using 3 anatomical features—AE, solid cortical bone of the PSC, and endolymphatic duct. Once the PSC has been skeletonized, one can proceed to skeletonize the SSC guided by the location of the AE, solid cortical bone of the SSC, and location of the PSC. Likely with a similar concept in mind, Shibao et al.¹⁹ described a limited mastoid resection termed “partial posterior petrosectomy,” where the Trautmann triangle is drilled out while avoiding the tympanic cavity and semicircular canals using neuronavigation and anatomical landmarks, i.e., AE and external auditory canal. In the author’s opinion, using the anatomical features described here is more accurate and reliable in determining location of the PSC and SSC.

The limited petrous apex resection is in contrast to the more extensive anterior petrosectomies commonly performed in the combined transpetrosal approach.^{9,11,14,16,17,21,22} In the transpetrosal-ridge approach, the function of the limited petrous ridge resection along the petrous apex is to allow the subsequent dural opening (with opening of the trigeminal dural ring), which improves the surgical exposure. The petrous apex is not used as a surgical corridor per se, as the angulation required to peer from the middle fossa through the petrous apex into the posterior fossa requires excessive temporal lobe retraction, which increases the risk of temporal lobe complications. It is preferable to reach the petroclival region from a posterolateral to anteromedial trajectory, between the semicircular canals laterally and the cerebellum and sigmoid sinus medially (Figure 1). Kunihiro et al.¹⁸ had also reported a limited petrous ridge resection; however, their aim was to gain additional surgical corridor along the axis of the petrous ridge, rather than to allow subsequent dural opening.

With the exception of Hafez et al.’s²⁷ modification of the dural opening in the combined transpetrosal approach reported by

Cho and Al-Mefty,¹⁴ the rest of the reported combined transpetrosal approaches^{9-13,15-22} require opening of the middle fossa dura and sectioning of the superior petrosal sinus and tentorium. Sectioning of the superior petrosal sinus and tentorium has a number of disadvantages. A number of important structures, namely superior petrosal vein, vein of Labbé, and trochlear nerve, may be placed at risk during the maneuver. In some patients, there may be venous lakes in the tentorium, which can cause troublesome bleeding. In the transpetrosal-ridge approach, only the posterior fossa dura is opened. The dural opening anterior to the sigmoid sinus and below the superior petrosal sinus extending through the trigeminal dural ring is a critical step, which detaches the superior petrosal sinus and the sigmoid sinus from the petrous bone, and allows them to be retracted together with the temporal lobe and the cerebellum. As an additional benefit, the intact middle fossa dura protects the temporal lobe during retraction.

When comparing skull base approaches, one can consider their differing degrees of bone resection, brain retraction, and technical difficulty. For the posterolateral approaches to the petroclival region, the retrosigmoid approach resides on one extreme with minimal bone resection, maximal brain retraction, and minimal technical difficulty. On the other extreme is the transcochlear approach with maximal bone resection, minimal brain retraction, and maximal technical difficulty. The transpetrosal-ridge approach sits in the sweet spot in the middle; it uses a degree of both bone resection and brain retraction, and although it can be performed at a medium level of difficulty, it provides a wide surgical exposure.

In addition to the exposure, there are numerous other advantages of the transpetrosal-ridge approach over the combined transpetrosal approach, some of which have been mentioned but are worth repeating here. The limited mastoid drilling is carried out rapidly due to the prior elevation of sigmoid sinus and pre-sigmoid dura. Resection of the anterolateral mastoid does not contribute to the final surgical corridor and is avoided. The semicircular canals, cochlea, and endolymphatic duct and sac are preserved and opening into the mastoid antrum is avoided. This maximizes the likelihood of hearing preservation. Drilling is carried out away from the facial nerve and the internal carotid artery, minimizing risk of damage. The major venous structures encountered (superior petrosal vein, superior petrosal sinus, transverse sinus, and sigmoid sinus) are preserved. The vein of Labbé is not exposed and, hence, not placed at risk. Temporal lobe retraction is done with the protection of the middle fossa dura.

Either the limited mastoidectomy or the limited petrous apex resection alone provides a very limited exposure; rather, it is the

synergy between the two techniques that allows for the specific dural opening, which detaches the superior petrosal sinus and the sigmoid sinus from the petrous bone, and allows them to be retracted together with the temporal lobe and the cerebellum. Compared with the retrosigmoid approach, the transpetrosal-ridge approach provides the surgeon with a greater exposure of the anterolateral part of the brainstem. In the retrosigmoid approach, this part of the brainstem is a critically important blind spot, which hinders dissection of the tumor off the brainstem. Furthermore, the transpetrosal-ridge approach is advantageous as it complements cerebellar retraction with bony resection, as compared with the retrosigmoid approach, which almost wholly relies on cerebellar retraction. This is particularly important in young patients and in patients with a tight posterior fossa from tumor mass effect or cerebellar edema, in whom cerebellar retraction may be difficult and risky.

There are certainly disadvantages and limitations to this approach. Even though the transpetrosal-ridge approach is a simplification of the combined transpetrosal approach, it is still a technically demanding procedure. Hence, it cannot be over-emphasized that a deep knowledge of the anatomy of the region as well as familiarity and experience with standard skull base techniques remain invaluable to surgeons who operate in this region. Without the sectioning of the tentorium, lesions with middle fossa extension beyond Meckel's cave and the tentorium cannot be attacked. This is the main difference in exposure between the original combined transpetrosal approach and the transpetrosal-ridge approach described here. For such lesions, the approach can be extended by sectioning the middle fossa floor dura, superior petrosal sinus, and the tentorium. One will also encounter difficulty reaching midline clival lesions using this approach; in these cases, the surgeon should consider the endoscopic endonasal approach or the transcochlear approach. Finally, it should be emphasized that the surgical strategy must be tailored to the individual patient's clinical condition, anatomical peculiarities, and tumor characteristics. Depending on the individual case, a more limited, a more extensive, a staged, or a different approach may be the superior choice.

CONCLUSIONS

The transpetrosal-ridge approach is a modification of the combined transpetrosal approach with optimization of the operative steps while continuing to provide a wide surgical corridor to the petroclival region. Improvements of existing techniques can be valuable in increasing their use and in encouraging young surgeons to take up skull base surgery.

REFERENCES

1. Rhoton AL Jr. The temporal bone and trans-temporal approaches. *Neurosurgery*. 2000;47: S211-S265.
2. McElveen JT, Dorfman BE, Fukushima T. Petro-clival tumors: a synthesis. *Otolaryngol Clin North Am*. 2001;34:1219-1230.
3. Tahara A, de Santana PA, Calfat Maldaun MV, et al. Petroclival meningiomas: surgical management and common complications. *J Clin Neurosci*. 2009;16:655-659.
4. Samii M, Tatagiba M, Carvalho GA. Resection of large petroclival meningiomas by the simple retrosigmoid route. *J Clin Neurosci*. 1999;6:27-30.
5. Miller CG, van Loveren HR, Keller JT, Pensak M, El-Kalliny M, Tew JM. Transpetrosal approach: surgical anatomy and technique. *Neurosurgery*. 1993;33:461-469.
6. Bambakidis NC, Gonzalez LF, Amin-Hanjani S, et al. Combined skull base approaches to the posterior fossa: technical note. *Neurosurg Focus*. 2005;19:E8.
7. Tummala RP, Coscarella E, Morcos JJ. Transpetrosal approaches to the posterior fossa. *Neurosurg Focus*. 2005;19:E6.

8. Beer-Furlan A, Abi-Hachem R, Jamshidi AO, Carrau RL, Prevedello DM. Endoscopic trans-sphenoidal surgery for petroclival and clival meningiomas. *J Neurosurg Sci.* 2016;60:495-502.
9. Hakuba A, Nishimura S, Jang BJ. A combined retroauricular and preauricular transpetrosal-transientorial approach to clivus meningiomas. *Surg Neurol.* 1988;30:108-116.
10. Al-Mefty O, Ayoubi S, Smith RR. The petrosal approach: indications, technique, and results. *Acta Neurochir Suppl (Wein).* 1991;53:166-170.
11. Pensak ML, Van Loveren H, Tew JM, Keith RW. Transpetrosal access to meningiomas juxtaposing the temporal bone. *Laryngoscope.* 1994;104:814-820.
12. Blevins NH, Jackler RK, Kaplan MJ, Gutin PH. Combined transpetrosal-subtemporal craniotomy for clival tumors with extension into the posterior fossa. *Laryngoscope.* 1995;105:975-982.
13. Chanda A, Nanda A. Partial labyrinthectomy petrous apicectomy approach to the petroclival region: an anatomic and technical study. *Neurosurgery.* 2002;51:147-160.
14. Cho CW, Al-Mefty O. Combined petrosal approach to petroclival meningiomas. *Neurosurgery.* 2002;51:708-718.
15. Oghalai JS, Jackler RK. Anatomy of the combined retrolabyrinthine-middle fossa craniotomy. *Neurosurg Focus.* 2003;14:E8.
16. Terasaka S, Asaoka K, Kobayashi H, Sugiyama T, Yamaguchi S. Dural opening/removal for combined petrosal approach: technical note. *Skull Base.* 2011;21:123-128.
17. Kusumi M, Fukushima T, Mehta AI, et al. Tentorial detachment technique in the combined petrosal approach for petroclival meningiomas. *J Neurosurg.* 2012;116:566-573.
18. Kunihiro N, Goto T, Ishibashi K, Ohata K. Surgical outcomes of the minimum anterior and posterior combined transpetrosal approach for resection of retrochiasmatic craniopharyngiomas with complicated conditions. *J Neurosurg.* 2014;120:1-11.
19. Shibao S, Borghei-Razavi H, Orii M, Yoshida K. Anterior transpetrosal approach combined with partial posterior petrosectomy for petroclival meningiomas with posterior extension. *World Neurosurg.* 2015;84:574-579.
20. Haq IBI, Susilo RI, Goto T, Ohata K. Dural incision in the petrosal approach with preservation of the superior petrosal vein. *J Neurosurg.* 2016;124:1074-1078.
21. Troude LJ, Carissimi MJ, Lavieille JP, Roche PH. How I do it: the combined petrosectomy. *Acta Neurochir (Wien).* 2016;158:711-715.
22. Janjua MB, Caruso JP, Greenfield JP, Souweidane MM, Schwartz TH. The combined transpetrosal approach: anatomic study and literature review. *J Clin Neurosci.* 2017;41:36-40.
23. Taniguchi M, Pernecky A. Subtemporal keyhole approach to the suprasellar and petroclival region: microanatomic considerations and clinical application. *Neurosurgery.* 1997;41:592-601.
24. Zhu W, Mao Y, Zhou LF, Zhang R, Chen L. Combined subtemporal and retrosigmoid keyhole approach for extensive petroclival meningiomas surgery: report of experience with 7 cases. *Minim Invasive Neurosurg.* 2008;51:95-99.
25. Maurer AJ, Safavi-Abbasi S, Cheema AA, Glenn CA, Sughrue ME. Management of petroclival meningiomas: a review of the development of current therapy. *J Neurol Surg B Skull Base.* 2014;75:358-367.
26. Gupta S, Bi WL, Dunn IF. Medical management of meningioma in the era of precision medicine. *Neurosurg Focus.* 2018;44:E3.
27. Hafez A, Nader R, Al-Mefty O. Preservation of the superior petrosal sinus during the petrosal approach. *J Neurosurg.* 2011;114:1294-1298.

Conflict of interest statement: The author declares that the article content was composed in the absence of any commercial or financial relationships that could be construed as a potential conflict of interest.

Received 13 October 2018; accepted 2 January 2019

Citation: World Neurosurg. X (2019) 2:100009.

<https://doi.org/10.1016/j.wnsx.2019.100009>

Journal homepage: www.journals.elsevier.com/world-neurosurgery-x

Available online: www.sciencedirect.com

2590-1397/© 2019 The Author(s). Published by Elsevier Inc.

This is an open access article under the CC BY-NC-ND license (<http://creativecommons.org/licenses/by-nc-nd/4.0/>).