

Quantitative assessment of tumor-associated tissue eosinophilia and nuclear organizing region activity to validate the significance of the pattern of invasion in oral squamous cell carcinoma: A retrospective study

Hidangmayum Denish Sharma¹, Jyothi Mahadesh², Wakambam Monalisa³, Pillai Arun Gopinathan⁴, B L Laxmidevi⁵, Nelson Sanjenbam⁶

¹Shine Dental Clinic, Sagolband Mabudhou Mantri Leikai, Imphal, Manipur, ²Departments of Oral Pathology and Microbiology and ⁶Oral and Maxillofacial Surgery, Dental College, Jawaharlal Nehru Institute of Medical Sciences, Imphal, Manipur, ⁴Departments of Oral and Maxillofacial Pathology, Sri Sankara Dental College, Varkala, Kerala, Departments of ²Oral Pathology and Microbiology and ⁵Oral and Maxillofacial Pathology, Sri Siddhartha Dental College and Hospital, Sri Siddhartha Academy of Higher Education, Tumakuru, Karnataka, India

Abstract

Introduction: Pattern of invasion (POI) in scoring system of oral squamous cell carcinoma (OSCC) can predict local recurrence and overall survival rate. Argyrophilic nucleolar organizer region (AgNOR) counts are considered to reflect the biosynthetic and nucleolar activity of a cell and thus serve as an indicator of the rapidity of the cell cycle thereby indicating the proliferative index of the tumor. It is implied that higher tumor associated tissue eosinophilia (TATE) showed lesser venous invasion, lymph node metastasis and clinical recurrence. The aim of the study was to assess and evaluate the following criteria's: POI-1 to POI-4 as defined by Bryne *et al.* in OSCC, proliferative index by AgNOR stain and TATE with carbol chromotrope stain in OSCC, validity of POI by correlating the AgNOR proliferative index and TATE.

Materials and Methods: Forty samples of formalin fixed paraffin embedded tissue blocks diagnosed of OSCC were taken for the study. Three sections were taken from a single block and then the tissues were stained differently with H & E Stain, AgNOR stain and Carbol chromotrope stain. First section stained with H & E was observed for POI and grading was done according to Bryne's criteria. The second and third sections were stained with AgNOR stain and Carbol chromotrope stain for proliferative index and TATE. One way analysis of variance was used to test the significance.

Results: Mean AgNORs count increases gradually from type 1 to type 4, depicting the increase in the nucleolar proliferative index of the cells and was statistically significant. In the case of the mean eosinophilic count, type 1 shows the highest mean eosinophilic count and the count shows drastic decrease till type 3 and from type 3 to type 4 the decrease is more gradual and was statistically significant.

Address for correspondence: Dr. Pillai Arun Gopinathan, Reader, Department of Oral and Maxillofacial Pathology, Sri Sankara Dental College, Varkala, Akathumuri, Thiruvananthapuram - 695 318, Kerala, India.

E-mail: arunop7817@gmail.com

Submitted: 24-Jan-2020, **Revised:** 11-Jun-2020, **Accepted:** 18-May-2021, **Published:** 31-Aug-2021

This is an open access journal, and articles are distributed under the terms of the Creative Commons Attribution-NonCommercial-ShareAlike 4.0 License, which allows others to remix, tweak, and build upon the work non-commercially, as long as appropriate credit is given and the new creations are licensed under the identical terms.

For reprints contact: WKHLRPMedknow_reprints@wolterskluwer.com

How to cite this article: Sharma HD, Mahadesh J, Monalisa W, Gopinathan PA, Laxmidevi BL, Sanjenbam N. Quantitative assessment of tumor-associated tissue eosinophilia and nuclear organizing region activity to validate the significance of the pattern of invasion in oral squamous cell carcinoma: A retrospective study. *J Oral Maxillofac Pathol* 2021;25:258-65.

Access this article online

Quick Response Code:



Website:

www.jomfp.in

DOI:

10.4103/0973-029X.325124

Conclusion: The study validated that POI is a good predictor for prognosis and also can be included in grading OSCC along with routine histopathological criteria.

Keywords: Argyrophilic nucleolar organizer region and tumor associated tissue eosinophilia, invasive tumor front, oral squamous cell carcinoma, pattern of invasion

INTRODUCTION

Oral squamous cell carcinoma (OSCC) currently holds the sixth position in the worldwide cancer statistics, with a 5 years survival rate, except when diagnosed in the early stage.^[1] Histopathologic classifications for OSCC were developed in an attempt to explain the discrepant biological behavior of tumors with apparently similar clinical characteristics. Many authors, at different times, proposed new histopathologic grading systems for squamous cell carcinoma (SCC) of the head and neck in an effort to predict tumor clinical behaviour.^[2]

Several types of growth pattern have been described in various types of carcinoma, such as in gastric and endometrioid adenocarcinoma or in head and neck, tongue and skin. Border and Matxloff were among the first to describe the different pattern of invasion (POI) in cervical cancer.^[3]

POI of tumor refers to the manner in which cancer infiltrates tissue at the tumor/host interface. It is intuitive that neoplasia infiltrating in a dispersed manner is more aggressive than those growing in a bulky pushing fashion. Bryne *et al.* give four types of POI. POI type 1 represents tumor invasion in a broad pushing manner. POI type 2 represents tumor invasion with broad pushing “fingers,” or separate large tumor islands, with a stellate appearance. POI type 3 represents invasive islands of tumor >15 cells per island. POI type 4 represents invasive tumor islands smaller than 15 cells per island. This includes single-cell invasion. POI type 4 also includes strands of tumor cells in a single-cell filing pattern, regardless of island size.^[4] POI is considered as an important parameter in the histological risk assessment grading system by Gensler *et al.* to classify patients into low, intermediate and high-risk groups.^[4] POI according to Doshi *et al.* indicates the prognosis of the tumor better than the border’s classification.^[5]

Invasive tumor front (ITF) has been defined as the most progressed area, three to six tumour cell layers or detached tumor cell group at the advancing edge of OSCC. Tumor cells at the invasive front of carcinomas have been found to differ substantially from the rest of tumor cells in a variety of human cancers. It is believed that the integral and prognostic information about the tumor’s invasive and

metastatic capacity can be deduced from the ITF, where the deepest and presumably most aggressive cell resides.^[6]

Argyrophilic nucleolar organizer regions (AgNORs) appears to be of diagnostic and prognostic significance in different types of human tumors. High tumor front scores and AgNOR content at the invasive OSCC front thus seem to reflect increased malignant potential. Proliferative activity, assessed by standardized AgNOR analysis most probably represents one of the biological features underlying the usefulness of evaluating the ITF.^[7,8]

The nucleolar organizer regions (NORs) are chromosomal loops of DNA involved in the ribosomal synthesis. Associated with NORs there are some nucleolar proteins, which are stained with silver methods (AgNOR proteins or AgNORs). Their size and number reflect nucleolar and cell proliferative activity of tumors.^[9]

Tumor associated tissue eosinophilia (TATE) is defined as “eosinophilic stromal infiltration of a tumor not associated with tumor necrosis or ulceration.” It was first described by Przewoski in carcinoma of the cervix.^[10] Since then the relationship between TATE and prognosis has been explored in a variety of sites and found to be generally favorable.^[11]

TATE has been postulated to be involved in the biological behavior of squamous cell carcinoma, especially in the head and neck.^[12] With regard to good prognosis, it has been seen that OSCC patients with TATE presented higher overall survival and less incidence of distant metastasis in head and neck tumors.^[13] A combined study of POI, TATE and AgNORs count of OSCC has never been explored before. Hence, it is taken up to assess, evaluate and validate the importance of POI in predicting the disease outcome by evaluating the biological behavior, aggressiveness and proliferative activity of OSCC.

The aim of the study was to:

1. Evaluate histopathologically POI 1 to POI 4 as defined by Bryne *et al.* in OSCC
2. Evaluate nucleolar proliferative index by AgNOR stain in OSCC
3. Evaluate TATE quantitatively by staining with carbol chromotrope in OSCC

- Evaluate the validity of POI by correlating the AgNOR proliferative index and TATE.

MATERIALS AND METHODS

The quantitative assessment was conducted on tissue sections which were obtained from the biopsy tissue specimens retrieved from the archives of the Department of Oral and Maxillofacial Pathology. Tissue specimens were also collected from other institutions after obtaining consent from respective Heads of the Department. The study group comprised of 40 paraffin blocks of 4 groups of POI as suggested by Bryne *et al.*^[4]

Forty cases were grouped as following:

- Type 1 POI-10 cases
- Type 2 POI-10 cases
- Type 3 POI-10 cases
- Type 4 POI-10 cases.

Inclusion criteria

- Histopathologically diagnosed cases of primary OSCC
- Patients who have undergone surgical therapy as the primary mode of treatment
- Only sections with sufficient depth of ITF were selected
- If a case is showing multiple POI, only the predominant pattern is considered as the main POI type
- Only nucleated and intensely red cytoplasmic granules were accepted as eosinophils.

Exclusion criteria

- Patients with known primary tumor other than oral cavity
- Patient who have undergone radiotherapy as a primary mode of treatment
- Histopathologically necrotic and ulcerative areas were excluded
- Multiple biopsy samples of the same patients were excluded
- Cases showing multiple POI with no predominant pattern were excluded
- Red blood cells and superimposed mononuclear and polymorphonuclear inflammatory cells were excluded while counting eosinophils
- AgNOR staining precipitates were excluded during counting the AgNOR dots.

Three sections were taken from a single block and were stained differently with H & E stain, Carbol chromotrope stain and AgNOR stain. The tissue was deparaffinized in several changes of xylene and descending alcohol concentrations. Rehydration was performed in several changes of ultrapure distilled water.

Quantitative assessment technique

First sections of a case was stained with H & E for observation of POI. The stained sections were observed under research microscope [Figures 1-4]. The POI were graded according to Bryne's criteria. The second section was stained with the AgNOR staining technique suggested by Linder. AgNOR stained sections were observed under research microscope using oil immersion, a maximum magnification of $\times 1000$. AgNORs counting was done at the ITF. The third section of the same case was stained with special stain Carbolchromotrope by using Lendrum's 2R chromotrope technique.^[14] after standardization.

Argyrophilic nucleolar organizer region counting

AgNORs were visualized as black brown discrete dots of variable size within the nuclei. Nuclei were randomly examined with a $\times 1000$ oil immersion objective [Figures 5-8]. The method was proposed by Giri *et al.*^[15] When two or more dots were so closely aggregated within a nucleus that the precise number within the aggregate could not be counted, the aggregate was counted as one AgNOR dot. Counting for the percentage of nuclei exhibiting AgNOR granules/nucleus/hundred cells was done for proliferative index-pAgNOR.

Eosinophils counting

Eosinophils were observed under research microscope at $\times 400$ magnification [Figures 9-12] Quantification of eosinophil was done by selecting randomly five high power fields. The total number of eosinophils were counted around the ITF.

According to the calculation of the hypothesis, AgNOR stain to be considered as the primary stain, as 100 cells per case is calculated for AgNORs. Carbol chromotrope is considered as the secondary stain as counting of TATE is done in five high power field at the ITF. Therefore AgNORs count will be considered as primary criteria and TATE count will be considered as secondary criteria in the study.

All evaluations were done by double-blinded manner to eliminate subjective bias. The values were tabulated and descriptive statistics such as Proportion mean and standard deviation were calculated. One way analysis of variance (ANOVA) test was used to test the significance between means of different types of cells.

RESULTS

In the study, the AGNORs showed a gradual increase in the mean count from type 1 to type 4 OSCC at the ITF. Type 1 pattern with the least mean AgNORs count of 1.25 and type 4 with highest mean AgNORs count of 2.14,

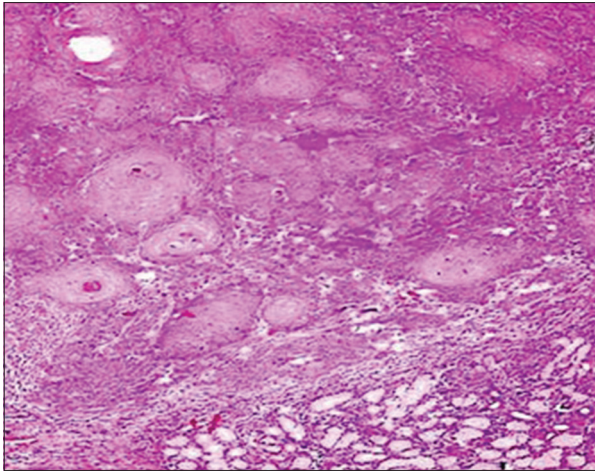


Figure 1: Photomicrograph of H & E stained, section under light microscope ($\times 100$) showing type 1 pattern of invasion

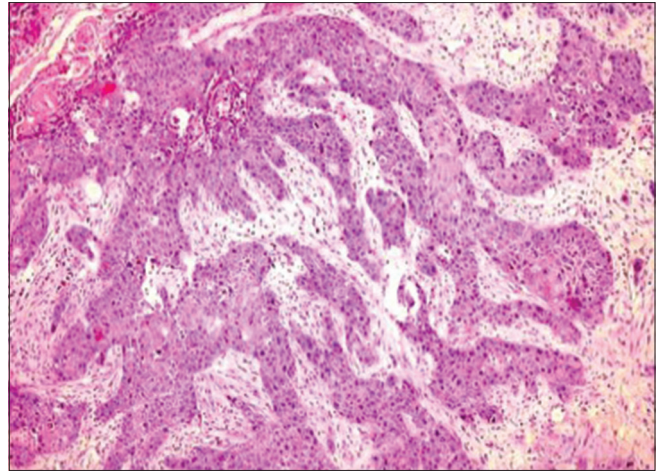


Figure 2: Photomicrograph of H & E stained, section under light microscope ($\times 100$) showing type 2 pattern of invasion

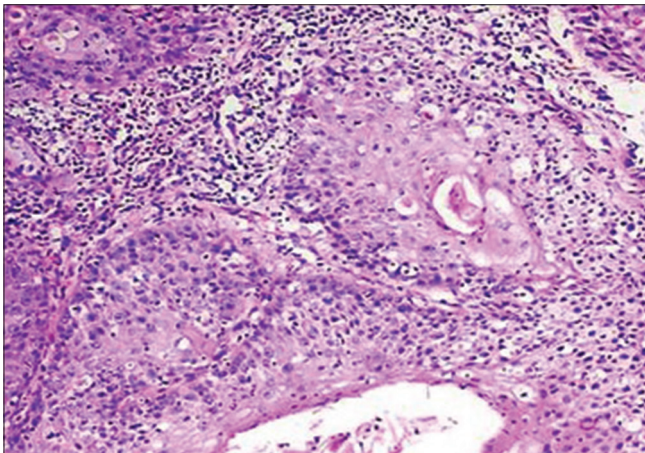


Figure 3: Photomicrograph of H & E stained, section under light microscope ($\times 200$) showing type 3 pattern of invasion

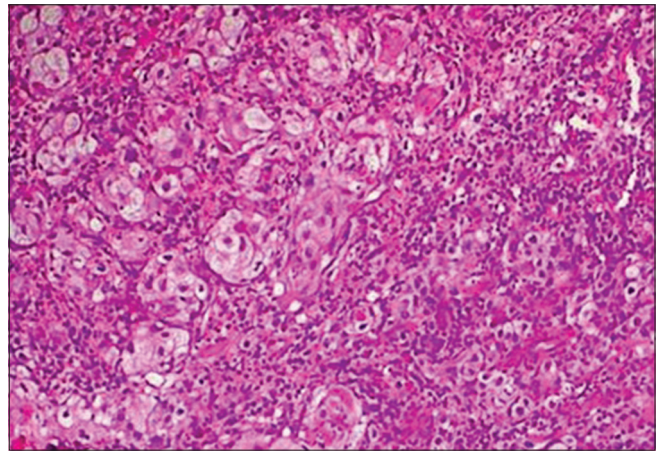


Figure 4: Photomicrograph of H & E stained, section under light microscope ($\times 200$) showing type 4 pattern of invasion

respectively [Graph 1]. Statistical analysis with One-way ANOVA between means of different types of cells was highly significant (P value: 0.00001).

Whereas in the TATE, showed a decrease in type 1 pattern with the highest mean eosinophils count of 18.02 and type 4 showed the least eosinophils count of 3.8 respectively [Graph 1]. Statistical analysis with One-way ANOVA between means of different types of cells were highly significant (P value: 0.00001).

DISCUSSION

Grading of OSCC is of great importance as it has direct correlation with the prognostic value. Broders (1927) initiated quantitative grading of oral cancer, and his classification had been in use for many years in oral squamous cell carcinoma, which was modified and altered by various pathologists like Anneroth (1987), Bryne (1989, 1992), Jacobson (1973), Fischer (1975) to name a few,

but nowadays WHO 2005 classification is followed worldwide.^[16,17]

Bryne *et al.* suggested four types of POI.^[4] In a study by Doshi *et al.*, comparison of different histological grading of oral cancer was done. They concluded that Bryne's grading of the invasive parts of OSCC was the only significant predictor of metastasis and could be taken as a valuable predictive factor in lymph node metastasis.^[5]

Lindenblatt *et al.* conducted a study on diagnosed and treated primary OSCC of head and neck region. They concluded that histological risk assessment proposed by Brandwein-Gensler *et al.* demonstrated the best results for survival prediction in OSCC over Bryne's POI at ITF.^[4]

The ITF has been defined as the most progressed, three to six tumour cell layers or detached tumour cell groups at the advancing edge of the OSCCs.^[6] The invasive edges of squamous cell carcinomas often display different molecular

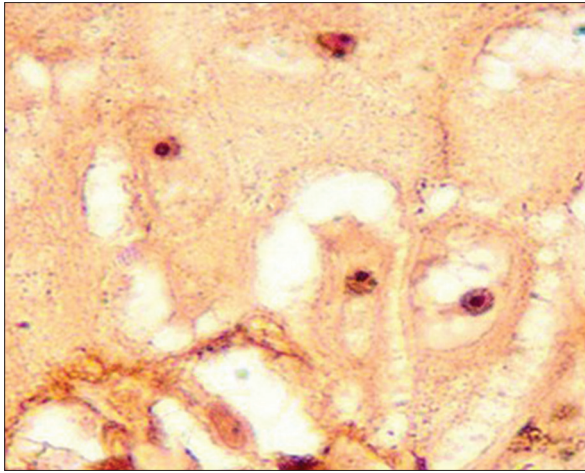


Figure 5: Photomicrograph of Argyrophilic nucleolar organizer region stained section under light microscope ($\times 1000$) using oil immersion showing type 1 pattern of invasion

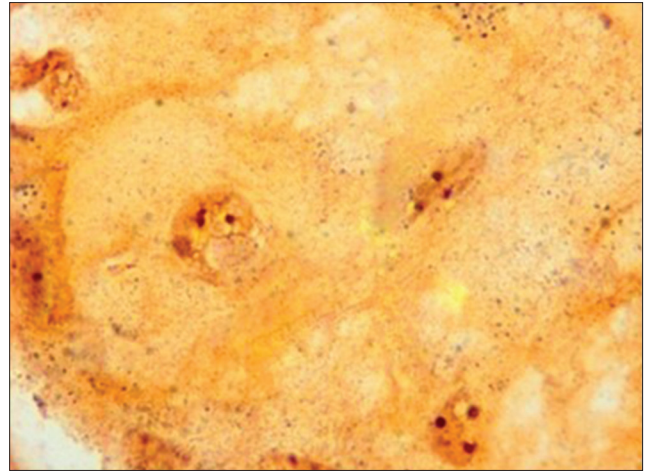


Figure 6: Photomicrograph of Argyrophilic nucleolar organizer region stained section under light microscope ($\times 1000$) using oil immersion showing type 2 pattern of invasion

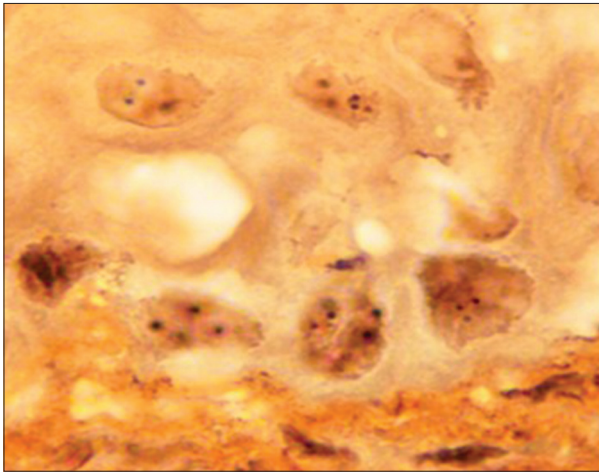


Figure 7: Photomicrograph of Argyrophilic nucleolar organizer region stained section under light microscope ($\times 1000$) using oil immersion showing type 3 pattern of invasion

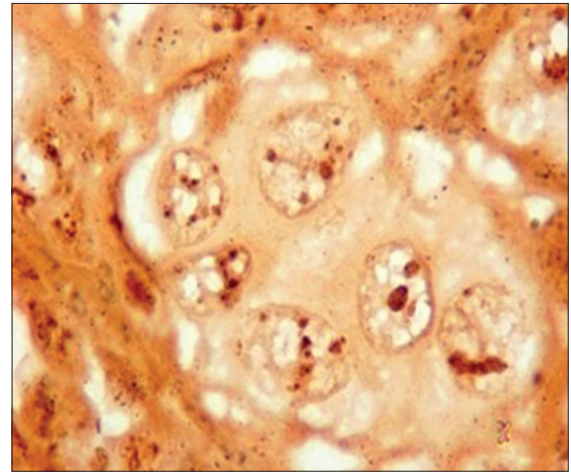


Figure 8: Photomicrograph of Argyrophilic nucleolar organizer region stained section under light microscope ($\times 400$) using oil immersion showing type 4 pattern of invasion

and morphological characteristics than more superficial parts of the same tumor.^[18]

Hence, the present study of ITF was considered to evaluate the importance of POI in predicting the disease outcome by evaluating the biological behavior, aggressiveness and proliferative activity of OSCC.

Proliferative activity of cell

AgNOR is loops of ribosomal DNA which are present in the nuclei. The NOR DNA possesses ribosomal DNA gene which are transcribed by RNA polymerase I and ultimately direct ribosomal formation and protein synthesis. As rRNA molecules are the main site of protein synthesis, the number of NORs in each nucleus reflects cellular activity.^[19,20]

Quantification of interphase AgNOR can actually represent a valuable tool for kinetics evaluation. Interphase

AgNOR accumulation in cell entering the mitotic cycle is associated with an increased request of ribosomal biogenesis. Protein synthesis is faster in rapidly dividing cells as compared to slowly proliferating ones. Therefore, an increase in nucleolar structure (AgNOR) is seen where rRNA synthesis takes place. So, AgNOR parameter has been suggested as a reliable marker for the evaluation of the rate of proliferation.^[21]

AgNOR is considered to reflect the biosynthesis and nucleolar activity of cell and thus, serve as a indicator for the rapidity of the cell cycle. AgNOR counts in squamous cell carcinoma of head and neck showed that a high value of mean AgNORs counts concure with poor prognosis.^[7]

Host response

Eosinophils are bone marrow-derived, tissue-dwelling

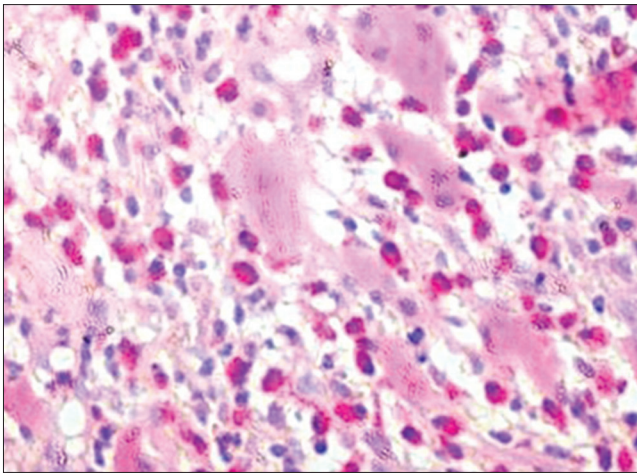


Figure 9: Photomicrograph of CarbolChromotrope stained section under light microscope (x400) showing type 1 pattern of invasion

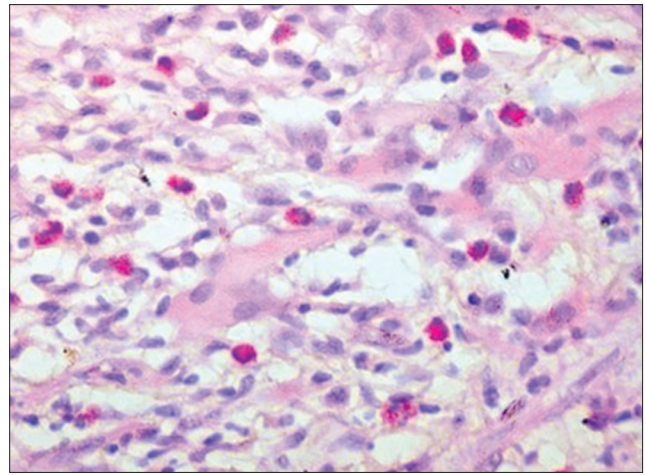


Figure 10: Photomicrograph of CarbolChromotrope stained section under light microscope (x400) showing type 2 pattern of invasion

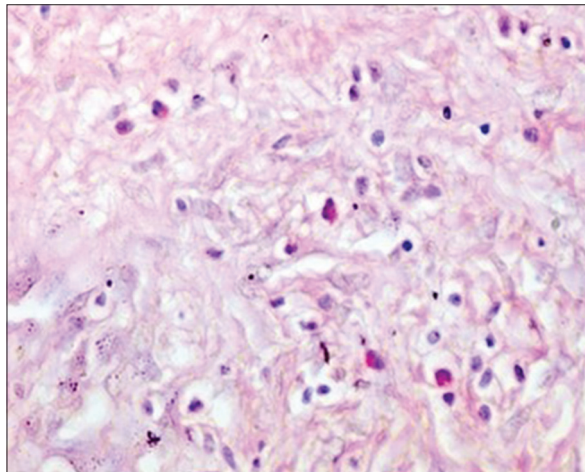


Figure 11: Photomicrograph of CarbolChromotrope stained section under light microscope (x400) showing type 3 pattern of invasion

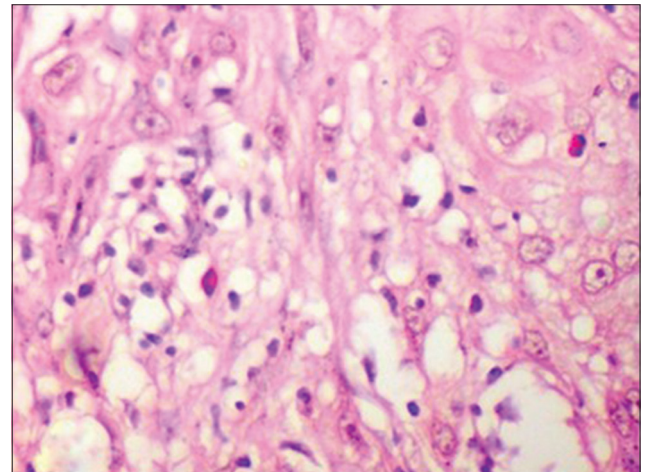


Figure 12: Photomicrograph of CarbolChromotrope stained section under light microscope (x400) showing type 3 pattern of invasion

granulocytes found transiently in the blood circulation enroute to the tissue inflammatory site. They are prominent cells in allergic inflammation, asthma and parasitic helminth infections. TATE has long been recognized as a pathological feature associated with a number of malignant tumour types including cancer of the mouth, esophagus, larynx, pharynx, breast, lung, intestine and gastrointestinal tract.^[22]

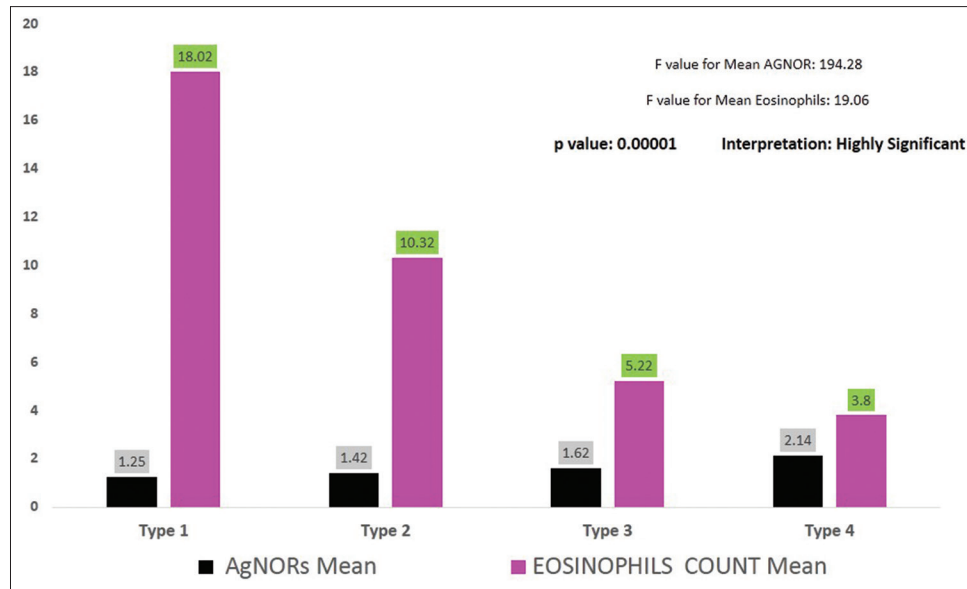
Sato *et al.* first highlighted the significance of tumor tissue eosinophilia compared to other tumor-associated inflammatory cell infiltration around the ITF of SCC of the maxillary sinus. Lowe *et al.* then proposed the term TATE.^[12]

Eosinophils are hypothesized to have direct tumoricidal activity associated with the release of cytotoxic proteins and also act indirectly by enhancing the permeability into tumour cells facilitating penetration of tumor-killing cytokines. Specific granules contain high amounts of cytotoxic basic

proteins, major basic protein, eosinophil cationic protein, eosinophil peroxidase and eosinophil-derived neurotoxin. These cationic proteins have been described to exert cytotoxic properties for tumor cell lines with variable efficiency.^[10,23]

A combined study of AgNORs and TATE count to validate POI at the ITF of OSCC has never been explored before. Hence, it is taken up to assess and to reiterate the importance of POI in predicting the disease outcome by evaluating the proliferative activity and TATE count of OSCC.

In our study, we used H & E to stain all our cases as a first step to evaluate the POI according to the Bryne's criteria. As H & E stain is the most popular routine stain used as gold standard in the field of histopathology by pathologists for medical diagnosis.



Graph 1: Comparison of mean of Argyrophilic nucleolar organizer region and mean of eosinophil count in all four types of squamous cell carcinoma at the tumour invasive front

AgNOR staining for all the cases was done and NOR was counted at the ITF for each case. As the mean AgNORs count indicates the proliferative index of the cell, our study shows a lower proliferative index in type 1 pattern with a mean AgNORs count of 1.25 ± 0.52 , respectively. The mean AgNORs count slightly increases to 1.42 ± 0.70 in type 2, type 3 also shows a slight increase in the proliferative index with a mean AgNORs of 1.62 ± 0.92 . Type 4 shows the highest mean AgNORs count of 2.14 ± 1.20 respectively.

As the mean AgNORs count is highest in type 4 pattern. It can be assumed that the ITF of type IV shows the highest proliferative index, indicating a poor prognosis for these types of cases. Whereas type 1 shows the least mean AgNORs count indicating its better prognosis compared to type 4 pattern. Therefore, the AgNORs count is directly proportional to the tumour grade.

During the course of the study we also noticed that the AgNORs dots were quite large in size in type 1 pattern, and in type 4 the dots were smaller in size and were more in numbers. This also indicates the increase in the proliferative index of the cell from type 1 to type 4 pattern. But measurement of size of AgNORs was not done as it was out of scope of our study. There is a scope for further research including this parameter.

The total numbers of eosinophils were counted around the tumour invasive front. Type 1 shows a highest mean eosinophils count of 18.02 ± 17.07 , type 2 shows a slight decrease in mean eosinophils count of 10.32 ± 9.95 . In

type 3 the mean eosinophils count decreases still more with 5.22 ± 5.21 . Type 4 shows the least numbers of mean eosinophils in the ITF with a mean eosinophils count of 3.8 ± 3.97 .

According to the result obtained from the eosinophils count, type 1 shows the highest mean eosinophilic count and the count shows drastic decrease till type 3 and from type 3 to type 4 the decrease is more gradual, depicting the possible drastic decrease in host immune response from type 1 to type 3 and a gradual decrease from type 3 to type 4. The reduction in the number of eosinophils/high-power field is seen, as the aggressiveness of the lesion increases. Drastic decrease from type 1 to type 3, indicates the drastic decrease in the host response to the tumor cells or that could be attributed to the tumor cells mastering the art of tumor escape mechanism.

A strategy that tumors use to escape from immune mediated response is by the expression of immunosuppressive factors. These factors may be expressed by the malignant cells themselves or by noncancerous cells present at the tumor site, such as immune, epithelial, or stromal cells. The most prominent of these factors is the transforming growth factor (TGF- β). Kadin *et al.* and Ohkawara *et al.* suggested that eosinophils are the major source of TGF- β . TGF- β is a cytokine that affects proliferation, activation and differentiation of cells of innate and adaptive immunity and thus inhibits the anti-tumor immune response.^[24-27]

Debta *et al.* reported that direct damage to mammalian tumor cells by eosinophil mediated peroxidase system has also been demonstrated, tumor necrosis factor-alpha,

secreted by eosinophil also plays an important role in OSCC, as it causes the death of tumor cells.^[28]

Therefore, we can state that POI type 1 which shows a decreased AgNORs and increased TATE count while POI type 4, which shows increased AgNORs and decreased TATE count renders the null hypothesis invalid. As a result of this, it can be inferred that null hypothesis is rejected, thus proving the research hypothesis.

Hence, the study validated that POI is a good predictor for prognosis and also can be included in grading OSCC along with routine histopathological criteria.

CONCLUSION

In the present study, it was found that Bryne's (POI) grading of the invasive parts of OSCC is a good predictor for prognosis. The present findings clearly indicate that both standardized AgNOR analysis and TATE count of the invasive front of OSCC provide outstanding information of the clinical course of the tumor. Thus, POI can also be taken into account along with the morphological and functional similarity of the tumor to parent cells and POI should be considered while reporting a case for better patient management.

Financial support and sponsorship

Nil.

Conflicts of interest

There are no conflicts of interest.

REFERENCES

- Rajput DV, Tupkari JV. Early detection of oral cancer: PAP and AgNOR staining in brush biopsies. *J Oral Maxillofac Pathol* 2010;14:52-8.
- Lindenblatt Rde C, Martinez GL, Silva LE, Faria PS, Camisasca DR, Lourenço Sde Q. Oral squamous cell carcinoma grading systems – Analysis of the best survival predictor. *J Oral Pathol Med* 2012;41:34-9.
- Horn LC, Fischer U, Raptis G, Bilek K, Hentschel B, Richter CE, *et al.* Pattern of invasion is of prognostic value in surgically treated cervical cancer patients. *Gynecol Oncol* 2006;103:906-11.
- Gensler MB, Teixeira MS, Lewis CM, Lee B, Rolnitzky L, Jille JJ, *et al.* Oral squamous cell carcinoma histological risk assessment, but not margin status, is strongly predictive of local disease-free and overall survival. *Am J Surg Pathol* 2005;29:167-78.
- Doshi N, Shah S, Patel K, Jhabuawala M. Histological grading of oral cancer: A comparison of different systems and their relation to lymph node metastasis. *Njmendia* 2011;2:136-42.
- Sharma M, Sah P, Sharma SS, Radhakrishnan R. Molecular changes in invasive front of oral cancer. *J Oral Maxillofac Pathol* 2013;17:240-7.
- Pillai KR, Sujathan K, Madhavan J, Abraham EK. Significance of silver-stained nucleolar organizer regions in early diagnosis and prognosis of oral squamous cell carcinoma: A multivariate analysis. *In Vivo* 2005;19:807-12.
- Piffkò J, Bãnkfalvi A, Ofner D, Bryne M, Rasch D, Joos U, *et al.* Prognostic value of histobiological factors (malignancy grading and AgNOR content) assessed at the invasive tumour front of oral squamous cell carcinomas. *Br J Cancer* 1997;75:1543-6.
- Barzilai A, Goldberg I, Yulash M, Pavlotsky F, Zuckerman A, Trau H, *et al.* Silver-stained nucleolar organizer regions (AgNORs) as a prognostic value in malignant melanoma. *Am J Dermatopathol* 1998;20:473-7.
- Jain M, Kasetty S, Sudheendra US, Tijare M, Khan S, Desai A. Assessment of tissue eosinophilia as a prognosticator in oral epithelial dysplasia and oral squamous cell carcinoma – An image analysis study. *Patholog Res Int* 2014;2014:507512.
- Thompson AC, Bradley PJ, Griffin NR. Tumour associated tissue eosinophilia and long term prognosis for carcinoma of the larynx. *Am J Surg* 1994;168:469-71.
- Ishibashi S, Ohashi Y, Suzuki T, Miyazaki S, Moriya T, Satomi S, *et al.* Tumour associated tissue eosinophilia in human esophageal squamous cell carcinoma. *Anticancer Res* 2006;269:1419-24.
- Martinelli-Klãy CP, Mendis BR, Lombardi T. Eosinophils and oral squamous cell carcinoma: A short review. *J Oncol* 2009;2009:310132.
- Song Y, Yin J, Chang H, Zhou Q, Peng H, Ji W, *et al.* Comparison of four staining methods for detecting eosinophils in nasal polyps. *Sci Rep* 2018;8:17718.
- Mehkri S, Iyengar AR, Nagesh KS, Bharati MB. Analysis of cell proliferation rate in oral leukoplakia and oral squamous cell carcinoma. *J Clin Exp Dent* 2010;2:173-7.
- Woolgar JA. Histopathological prognosticators in oral and oropharyngeal squamous cell carcinoma. *Oral Oncol* 2006;42:229-39.
- Pindborg JJ, Riechart PA, Smith CJ, Waal IV. *Histological Typing of Cancer and Precancer of the Oral Mucosa*. 2nd ed Germany: Springer; 1997;2:11-16.
- Kristensen GB, Abeler VM, Risberg B, Trop C, Bryne M. Tumor size, depth of invasion, and grading of the invasive tumor front are the main prognostic factors in early squamous cell cervical carcinoma. *Gynecol Oncol* 1999;74:245-51.
- Chiu KY, Loke SL, Wong KK. Improved silver technique for showing nucleolar organiser regions in paraffin wax sections. *J Clin Pathol* 1989;42:992-4.
- Kulkarni S, Mody RN, Jindal S, Sohi RS, Kaur B. Silver binding nucleolar organiser regions in oral submucous fibrosis, lichen planus, leukoplakia and squamous cell carcinoma. *J Cancer Res Exp Oncol* 2009;1:15-9.
- Moradzadeh Khiavi M, Vosoughhosseini S, Halimi M, Mahmoudi SM, Yarahmadi A. Nucleolar organizer regions in oral squamous cell carcinoma. *J Dent Res Dent Clin Dent Prospects* 2012;6:17-20.
- Davoine F, Sim A, Tang C, Fisher S, Ethier C, Puttagunta L, *et al.* Eosinophils in human oral squamous carcinoma; role of prostaglandin D2. *J Inflamm (Lond)* 2013;10:4.
- Legrand F, Driss V, Delbeke M, Loiseau S, Hermann E, Dombrowicz D, *et al.* Human eosinophils exert TNF- α and granzyme A-mediated tumoricidal activity toward colon carcinoma cells. *J Immunol* 2010;185:7443-51.
- Igney FH, Krammer PH. Immune escape of tumors: Apoptosis resistance and tumor counterattack. *J Leukoc Biol* 2002;71:907-20.
- Swann JB, Smyth MJ. Immune surveillance of tumors. *J Clin Invest* 2007;117:1137-46.
- Kadin M, Butmarc J, Elovic A, Wong D. Eosinophils are the major source of transforming growth factor- β 1 in nodular sclerosing Hodgkin's disease. *AJP* 1993;142:11-16.
- Ohkawara Y, Tamura G, Iwasaki T, Tanaka A, Kikuchi T, Shirato K. Activation and transforming growth factor-beta production in eosinophils by hyaluronan. *Am J Respir Cell Mol Biol* 2000;23:444-51.
- Debta P, Debta FM, Chaudhary M, Wadhwan V. Evaluation of prognostic significance of immunological cells (tissue eosinophil and mast cell) infiltration in oral squamous cell carcinoma. *J Cancer Sci Ther* 2011;3:201-4.