

L-carnitine alleviates sciatic nerve crush injury in rats: functional and electron microscopy assessments

Ümmü Zeynep Avsar¹, Umit Avsar², Ali Aydin³, Muhammed Yayla⁴, Berna Ozturkkaragoz⁵, Harun Un⁶, Murat Saritemur⁷, Tolga Mercantepe⁸

1 Department of Medical Education, Faculty of Medicine, Ataturk University, Yakutiye, Erzurum, Turkey

2 Department of Family Medicine, Faculty of Medicine, Ataturk University, Yakutiye, Erzurum, Turkey

3 Department of Orthopedics and Traumatology, Faculty of Medicine, Ataturk University, Yakutiye, Erzurum, Turkey

4 Department of Pharmacology, Faculty of Medicine, Ataturk University, Yakutiye, Erzurum, Turkey

5 Department of Pharmacology, Faculty of Pharmacy, Agri University, Agri, Turkey

6 Department of Biochemistry, Faculty of Pharmacy, Agri University, Agri, Turkey

7 Department of Emergency Medicine, Faculty of Medicine, Ataturk University, Yakutiye, Erzurum, Turkey

8 Department of Histology and Embryology, Faculty of Medicine, Ataturk University, Yakutiye, Erzurum, Turkey

Corresponding author:

Ümmü Zeynep Avsar, Department of Medical Education, Faculty of Medicine, Ataturk University, Erzurum 25240, Turkey, zeynep.avsar@atauni.edu.tr.

doi:10.4103/1673-5374.133163

http://www.nrronline.org/

Accepted: 2014-03-20

Abstract

Several studies have demonstrated that L-carnitine exhibits neuroprotective effects on injured sciatic nerve of rats with diabetes mellitus. It is hypothesized that L-carnitine exhibits neuroprotective effects on injured sciatic nerve of rats. Rat sciatic nerve was crush injured by a forceps and exhibited degenerative changes. After intragastric administration of 50 and 100 mg/kg L-carnitine for 30 days, axon area, myelin sheath area, axon diameter, myelin sheath diameter, and numerical density of the myelinated axons of injured sciatic nerve were similar to normal, and the function of injured sciatic nerve also improved significantly. These findings suggest that L-carnitine exhibits neuroprotective effects on sciatic nerve crush injury in rats.

Key Words: nerve regeneration; peripheral nerve injury; sciatic nerve; L-carnitine; neuroprotection; crush injury; electron microscopy; axon; myelin sheath; neural regeneration

Funding: This study was supported by a grant from Ataturk University Scientific Experimental Project Office to Project Number 2012/07.

Avsar ÜZ, Avsar U, Aydin A, Yayla M, Ozturkkaragoz B, Un H, Saritemur M, Mercantepe T. L-carnitine alleviates sciatic nerve crush injury in rats: functional and electron microscopy assessments. *Neural Regen Res.* 2014;9(10):1020-1024.

Introduction

Peripheral nerve injuries are a frequently encountered problem that severely affects a person's quality of living (Robinson, 2004). Peripheral nerve injuries most frequently originate from traumas (Abe and Cavalli, 2008). Regardless of the cause of the injury, the incomplete recovery in the nerve tissue or abnormal regeneration of the nerve frequently results in pain and loss of functionality (Mackinnon et al., 1985). Post-trauma changes in the nerve begin to appear both in distal and proximal regions of the axon, followed by inflammation and mitochondrial disorder, which occur due to cell damage (Navarro et al., 2007). If medical intervention is not provided, the injured nerve cell will begin to die and, ultimately, lose its function (Navarro et al., 2007). In order to prevent such losses, many agents are still both clinically and experimentally tried (Al-Majed et al., 2000; Boyd and Gordon, 2003; Chen et al., 2007; Eto et al., 2008).

Carnitine, a vitamin-like amine, contains a non-amino acid structure (Bahl and Bressler, 1987; Bieber, 1988). Carnitines, including L-carnitine and carnitine analogues (Zhou et al., 2007), have been shown to protect tissue and cells from ischemia and reperfusion damage (Vary and Neely,

1982). There are many studies investigating the neuroprotective effects of acetyl-L-carnitine. In particular, acetyl-L-carnitine was tried in cases of neuropathic pain, loss of nerve function, and many neurogenic disorders such as sciatic nerve damage, and therapeutic benefits were observed in these diseases (De Angelis et al., 1992; Hart et al., 2002; Chiechio et al., 2007; Rump et al., 2010; Karsidag et al., 2012). Another study showed that the amount of acetyl-L-carnitine decreased in the sciatic nerve of diabetes mellitus (Stevens et al., 1996). Furthermore, L-carnitine plays an important role in diabetes-induced neuropathy and retinopathy (Lowitt et al., 1993; Ido et al., 1994; Cotter et al., 1995; Hotta et al., 1996; Malone et al., 1996; Stevens et al., 1996). Studies on the neuroprotective and neuromodulatory effects of carnitines have revealed many benefits: a positive effect on cognitive functions like Alzheimer's disease (Pettegrew et al., 2000; Bianchetti et al., 2003); an antidepressant-like effect (Garzya et al., 1990; Cavallini et al., 2004); an analgesic and/or antinociceptive effect (Onofri et al., 1995; Galeotti et al., 2004); and a positive effect on neurodegenerative diseases like Parkinson's disease (Bodis-Wollner et al., 1991). However, fewer studies have been done on the neuroprotective effects of L-carnitine.

Table 1 Morphometric properties of the sciatic nerve

Group	Axon area (μm^2)	Myelin area (μm^2)	Numerical density of the myelinated axons (mm^2)	Axon diameter (μm)	Myelin diameter (μm)
Sham	12.58±0.27	93.04±0.505	2,848.9±21.7	3.42±0.15	2.43±0.14
NT	7.46±0.24 ^a	65.45±1.65 ^a	2,443.0±31.2 ^a	1.75±0.28 ^a	1.29±0.10 ^a
NT + CAR 50 mg/kg	12.07±0.39 ^b	92.05±0.33 ^b	2,739.7±27.1 ^b	3.28±0.10 ^{ab}	2.21±0.44 ^{ab}
NT + CAR 100 mg/kg	11.715±0.19 ^b	90.98±0.38 ^b	2,686.9±54.3 ^b	3.15±0.13 ^{ab}	2.16±0.07 ^{ab}

Results are expressed as mean ± SD with six rats per group. ^a*P* < 0.05, vs. sham group; ^b*P* < 0.05, vs. NT group. One-sample *t*-test was used to compare the difference in the numerical density of myelinated axons between groups. Changes in other parameters were statistically analyzed using one-way analysis of variance (ANOVA) with Tukey's multiple range test. NT: Nerve trauma; CAR: L-carnitine.

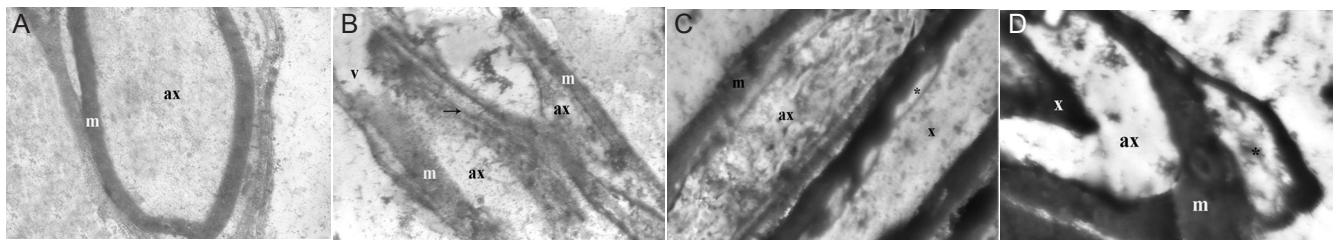


Figure 1 Electron microscopic view of the sciatic nerve.

(A) Sham group ($\times 10,000$). The axon (ax) and myelin sheath (m) are seen with normal structure. Mitochondria, neurotubulus, and neurofilaments were normally observed in the axon. (B) Nerve trauma (NT) group ($\times 20,000$). The axon (a) and myelin sheath are degenerated to a large extent in some of the myelinated nerve fibers. Vacuolization (V) occurs in axon cytoplasm. It is notable that the myelin sheath (m) is invaginated into the axon (ax) myelin nerve fibers, and that the myelin sheath lamellas are substantially separated from each other in some places (arrow). (C) NT + CAR 50 mg/kg group ($\times 20,000$). Little myelin sheath damage (asterisk) is seen in some of the myelinated nerve fibers and axon (a) and the myelin sheaths (M) have normal structure in most of the nerve fibers. Mitochondria (m), neurotubulus and neurofilaments (x) are shown. (D) NT + CAR 100 mg/kg group ($\times 20,000$). Little myelin sheath damage (asterisk), ranging in degree from low to medium, is seen in the myelin sheath in some of the myelinated nerve fibers. Vacuolization occurs in axon.

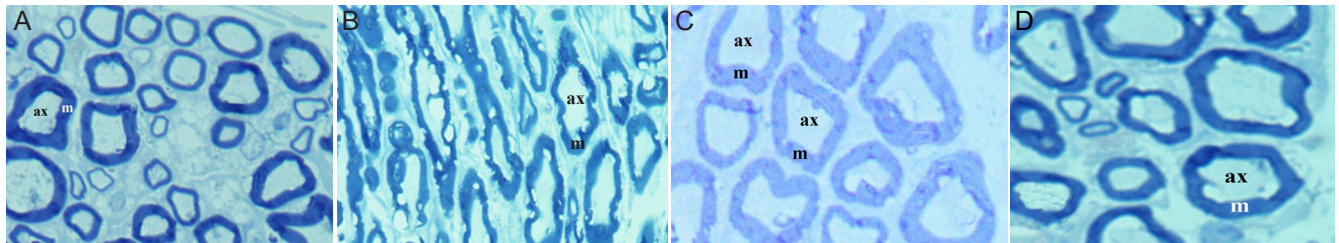


Figure 2 Electron microscopic view of the sciatic nerve ($\times 20,000$).

(A) Sham group. The myelinated nerve fibers have a visible myelin sheath, and these fibers have normal structure. (B) NT group. The axon (ax) and myelin sheath (m) structures are substantially degenerated in myelinated nerve fibers. (C) NT + CAR 50 mg/kg group. There are some degenerative changes in the axon and myelin sheath in some of the myelinated nerve fibers. (D) NT + CAR 100 mg/kg group. The sciatic nerve includes myelinated nerve fibers.

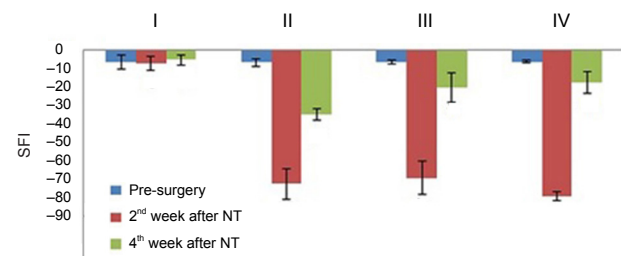


Figure 3 Functional evaluation of sciatic nerve function.

The results were expressed as mean ± SD for each group. The sciatic functional index (SFI) was significantly decreased for both the sham and CAR-treated groups at the 2nd week post-injury. However, the SFI values were significantly higher in the CAR-treated groups than in the nerve trauma (NT) group at the 4th week post-injury. SFI was statistically analyzed using one-way analysis of variance (ANOVA) with the Duncan's multiple range test. CAR: L-carnitine. I: Sham; II: NT; III: NT + CAR 50 mg/kg; IV: NT + CAR 100 mg/kg.

The aim of this study is to investigate the neuroprotective effects of L-carnitine on an experimental sciatic nerve crush injury model, employing reliable assessment parameters to indicate nerve regeneration, such as the average diameter of myelinated axons. Electron microscopy was used to examine axons and the area of the myelin sheath. Also, we used a walking tract analysis to evaluate functional improvement following peripheral nerve injuries.

Materials and Methods

Animals

Twenty-four adult female albino Wistar rats, weighing 240–250 g, were obtained from the Medicinal and Experimental Application and Research Center (ATADEM). They were given standard rat pellet feed and tap water *ad libitum*. All

animals were housed in stainless steel cages under standard laboratory conditions (light period 07.00 a.m. to 8.00 p.m., $21 \pm 2^\circ\text{C}$, and relative humidity 55%) throughout the experimental period. The animal care and experimental protocols were approved by the Experimental Animal Ethics Committee, Atatürk University, Erzurum, Turkey (23/02/2012-34).

Chemicals

L-carnitine tablets were obtained from the Tang Drug Store, Turkey and the L-carnitine was suspended in 1 mL 0.9% NaCl. Thiopental sodium (intraperitoneal (i.p.) injection, 20 or 50 mg/kg) was purchased from IE Ulagay A.S., Istanbul, Turkey.

Experimental design

The included rats were randomly and evenly divided into four groups: group 1 served as a sham; group 2 only comprised rats with sciatic nerve crush injury (NT); in the group 3, rats with sciatic nerve crush injury were treated with L-carnitine (NT + CAR 50 mg/kg (oral administration)); in the group 4, rats with sciatic nerve crush injury were treated with a higher dose of CAR (NT + CAR 100 mg/kg (intra-gastric administration)). Starting from the first day post-surgery, all rats in the sham and NT groups were treated with 1 mL 0.9% NaCl by oral administration once a day, and each rat in the NT + CAR 50 mg/kg and NT + CAR 100 mg/kg groups was treated with CAR (50 and 100 mg/kg respectively) in the same manner at the same time point for a period of 30 days.

Surgical procedures

All experiments were performed under a microscope by the same surgeon. After shaving and preparing the skin with 10% povidone iodine, the right thigh was operated. The sciatic nerve was exposed by opening the fascial plane between the gluteal and femoral musculature *via* a longitudinal incision. Under thiopental anesthesia, the right sciatic nerve of 18 rats was exposed at the mid-thigh level and crushed for 120 seconds with a pair of jeweler's forceps (Aneurysm clamp, the length of forceps: 12.5 cm, forces 0.6 N; Aesculap, Yaşargil standard aneurysm clamp, FE783, Tuttlingen, Germany). The wound was sutured in layers and then the rats were allowed to recover. At 2 and 4 weeks, all animals were evaluated for sciatic functional index (SFI) by walking tract analysis (WTA). Four weeks after the evaluation, in order to confirm the nerve recovery, all rats were euthanized by an overdose of thiopental anesthesia. A 10 mm sample of the right sciatic nerve segment centered to the lesion was removed, fixed, and prepared for light and electron microscopic examination.

Histological and quantitative analysis procedures

1 mm³ of sciatic nerve was dissected and fixed in a mixture of 2% paraformaldehyde + 3% glutaraldehyde (150 mL) in a 0.1 mol/L phosphate buffer overnight at 4°C, and the tissues were post-fixed in 1% phosphate-buffered osmium tetroxide for 1 hour, dehydrated in a graded alcohol series, and immersed in propylene oxide and a propylene oxide embedding-material mixture (Araldite-Electron Microscopy,

ScienceAraldit; CY 212 Kit, Cambridge, UK). The specimens were then embedded in embedding material and polymerized in an increasing degree of etuv from 45°C to 65°C for 3 days. Epon blocks were transversally cut with an ultramicrotome (Nova; LKB, Bromma, Sweden). The obtained semi-thin sections were stained with toluidine blue, and they were evaluated under a light microscope (Leica DM 4000B, Medisa Dis Ticaret Pazarlama Ltd Sti Clinical Microscopy, Cytovision and Digital Pathology, Istanbul, Turkey) for histopathological and stereological examination.

For stereologic examination, Stereo investigator (Micro-brightfield Inc, Williston, VT, USA) and a camera attachment were used. Sciatic nerve samples for each rat were examined at low magnification. The suitable grid size and unbiased counting frame size were estimated by a pilot study. The lined area was sampled systematically and randomly *via* a Fractionator probe, and myelinated axons were counted at high magnification. Finally, the mean numerical density of the myelinated axons was estimated by following formula: $N_v = \Sigma Q / \Sigma S \times A$. In the formula, N_v : numerical density; ΣQ : total markers counted; ΣS : number of sampling sides; A : counting frame area.

For electron microscopic analyses, 30–40 nm thin sections were obtained from determined regions of semi-thin sections. These thin sections were stained with 2% uranyl acetate and 0.4% lead citrate and then observed under a Jeol 100 SX transmission electron microscope (Jeol, Tokyo, Japan). Sections were photographed *via* a camera attachment (Kodak 4048).

Walking track analysis

A walking track analysis was performed in a white paper-covered corridor wide enough for a rat to walk through: 10 cm × 50 cm. Before the walking test, both soles of the rats' paws were immersed in ink; they then proceeded to walk along the corridor. Paired footprint parameters for footprint length (PL), the distance from the first to fifth toes (toe spread, TS), and the distance from the second to fourth toes (intermediary toe spread, IT) were recorded for the right normal control foots (NPL, NTS, NIT) and the corresponding left experimental foot (EPL, ETS, EIT) for each rat. The SFI was calculated according to the formula: $SFI = -38.3 [(EPL - NPL)/NPL] + 109.5 [(ETS - NTS)/NTS] + 13.3 [(EIT - NIT)/NIT] - 8.8$. A score of 0 indicates normal nerve function and a score of 100 represents complete dysfunction (Dijkstra et al., 2000).

Statistical analysis

The IBM SPSS Statistics 20 computer program package (Ataturk University contracted) was used for statistical calculations. The SFI was statistically analyzed using one-way analysis of variance (ANOVA) with the Duncan's multiple range test. All of the results were expressed as mean ± SD for each group. A histological evaluation was performed to evaluate the difference between groups: we used one-sample *t*-test to determine the numerical density of myelinated axons. The changes in the axon and myelin area were statistically analyzed using ANOVA with Tukey's multiple range test. Results were considered statistically significant at $P < 0.05$.

Results

Ultrastructure change of sciatic nerve

The axon and myelin sheath with normal structure were observed in the sciatic nerve fibers obtained from the sham group. Mitochondria, neurotubulus, and neurofilaments were normally observed in the axon (Figures 1A, 2A). The axon and myelin sheath were degenerated to the largest degree in the sciatic nerve fibers obtained from the NT group. Vacuolization occurred in the axonal cytoplasm. It was observed that the myelin sheath was invaginated into the axon and that the myelin sheath lamellas separated from each other in some places in myelinated nerve fibers (Figures 1B, 2B).

The axon and myelin sheath with normal structure were observed in the sciatic nerve fibres obtained from the NT + CAR 50 mg/kg group. Vacuolization occurred in the axonal cytoplasm and myelin sheath lamellas maintained their integrity (Figures 1C, 2C).

In the NT + CAR 100 mg/kg group, there were degenerative changes of the axon and myelin sheath in some of the myelinated nerve fibres. Myelin sheath damage ranged in degree, from low to medium, in the myelin sheath in some of the myelinated nerve fibres. The myelin sheath was substantially invaginated by myelinated nerve fibers (Figures 1D, 2D).

Compared to the the sham group, NT group demonstrated a significant decrease in the axon area and myelin sheath area ($P < 0.05$; Table 1). There were no significant differences in axon area and myelin sheath area between NT + CAR 50 mg/kg or NT + CAR 100 mg/kg group and sham group ($P > 0.05$), and no significant differences in axon area and myelin sheath area were observed between NT + CAR 50 mg/kg group and NT + CAR 100 mg/kg group ($P > 0.05$). The axon area, myelin sheath area, and the numerical density of the myelinated axons in the NT + CAR 50 mg/kg and NT + CAR 100 mg/kg groups were highly significantly greater than in the sham group, but significantly greater than in the NT group ($P < 0.05$; Table 1). Axon diameter and myelin sheath diameter were found to be significantly decreased in the NT group than in the sham group ($P < 0.05$; Table 1). There were no significant differences in axon diameter and myelin sheath diameter between NT + CAR 50 mg/kg group or NT + CAR 100 mg/kg group and sham group ($P > 0.05$; Table 1). The axon diameter and myelin sheath diameter in the NT + CAR 50 mg/kg and NT + CAR 100 mg/kg groups were highly significantly greater than in the sham group, but significantly greater than in the NT group ($P < 0.05$).

Functional evaluations of sciatic nerve healing

The SFI was significantly decreased in the sham and NT + CAR 50 mg/kg and NT + CAR 100 mg/kg groups at the 2nd week post-injury ($P < 0.05$; Figure 3). However, the SFI values were significantly higher in the NT + CAR 50 mg/kg and NT + CAR 100 mg/kg groups than in the NT group at the 4th week post-injury ($P < 0.05$; Figure 3).

Discussion

Recent *in vivo* and *in vitro* studies have demonstrated that L-carnitine is a powerful antioxidant (Gulcin, 2006). In regard to neuroprotective effects, L-carnitine has demonstrated

the ability to prevent oxidative damage, which is important against neurodegenerative diseases like Alzheimer's disease and Parkinson's disease (Beal, 2003; Hinerfeld et al., 2004; Abdul and Butterfield, 2007). In particular, Fernandez et al. (1989) examined the effects of L-carnitine on nerve regeneration in a sciatic nerve injury model and performed histopathological evaluation (Fernandez et al., 1989).

Collectively, we investigated the therapeutic effects of L-carnitine on sciatic nerve damage. In our study, we primarily compared the outcomes of sciatic nerve function recovery using the commonly used SFI test (Kanaya et al., 1992; Kalender et al., 2009; Pan et al., 2010). Results showed that the sciatic nerve function was considerably poorer in the NT group than in the sham group. This finding was consistent with previous studies (Kou et al., 2013; Tamaddonfard et al., 2013). In our study, a significant degree of recovery was observed after 4-week L-carnitine treatment by calculating post-injury SFI value, which suggests the positive effects of L-carnitine in the recovery of nerve functions.

There is evidence that in injured rat sciatic nerves, the axon and myelin sheaths were degenerated to a large extent, and myelin bulging and axonal vacuolization appeared (Kurtoglu et al., 2005; Yin et al., 2010; Tamaddonfard et al., 2013). Our histomorphometric findings are similar to abovementioned studies. That is to say, axon and myelin sheath degenerated in the nerve fiber and myelin sheath invaginated into the axon in the NT group. By contrast, axon and myelin sheath were seen with normal structure in the nerve fiber of the NT + CAR 50 mg/kg and NT + 100 mg/kg groups. These findings suggest that L-carnitine has a significant protective effect, particularly on axon and myelin sheath degeneration from the perspective of histopathology.

Taken together, results from this study demonstrated that L-carnitine significantly prevented nerve function loss after nerve injury, promoted nerve regeneration, and decreased "damage-induced degeneration" of the axon and myelin sheath as determined by electronmicroscopy and histopathology in the experimental sciatic nerve injury in rats.

Author contributions: Aydin A, Yayla M and Saritemur M designed this study and performed surgical procedures. Ozturkcaragoz B and Un H were responsible for drug administration and sciatic functional index analyses. Mercantepe T performed histological analyses. Avsar ÜZ and Yayla M were responsible for manuscript writing. Avsar U performed all statistical analyses. All authors approved the final version of this paper.

Conflicts of interest: None declared.

References

- Abdul HM, Butterfield DA (2007) Involvement of PI3K/PKG/ERK1/2 signaling pathways in cortical neurons to trigger protection by cotreatment of acetyl-L-carnitine and alpha-lipoic acid against HNE-mediated oxidative stress and neurotoxicity: implications for Alzheimer's disease. *Free Radic Biol Med* 42:371-384.
- Al-Majed AA, Neumann CM, Brushart TM, Gordon T (2000) Brief electrical stimulation promotes the speed and accuracy of motor axonal regeneration. *J Neurosci* 20:2602-2608.
- Beal MF (2003) Bioenergetic approaches for neuroprotection in Parkinson's disease. *Ann Neurol* 53 Suppl 3:S39-47.
- Bianchetti A, Rozzini R, Trabucchi M (2003) Effects of acetyl-L-carnitine in Alzheimer's disease patients unresponsive to acetylcholinesterase inhibitors. *Curr Med Res Opin* 19:350-353.

- Bodis-Wollner I, Chung E, Ghilardi MF, Glover A, Onofrij M, Pasik P, Samson Y (1991) Acetyl-levo-carnitine protects against MPTP-induced parkinsonism in primates. *J Neural Transm Park Dis Dement Sect 3*:63-72.
- Boyd JG, Gordon T (2003) Neurotrophic factors and their receptors in axonal regeneration and functional recovery after peripheral nerve injury. *Mol Neurobiol* 27:277-324.
- Cavallini G, Caracciolo S, Vitali G, Modenini F, Biagiotti G (2004) Carnitine versus androgen administration in the treatment of sexual dysfunction, depressed mood, and fatigue associated with male aging. *Urology* 63:641-646.
- Chen CJ, Ou YC, Liao SL, Chen WY, Chen SY, Wu CW, Wang CC, Wang WY, Huang YS, Hsu SH (2007) Transplantation of bone marrow stromal cells for peripheral nerve repair. *Exp Neurol* 204:443-453.
- Chiechio S, Copani A, Gereau RWt, Nicoletti F (2007) Acetyl-L-carnitine in neuropathic pain: experimental data. *CNS drugs* 21 Suppl 1:31-38.
- Cotter MA, Cameron NE, Keegan A, Dines KC (1995) Effects of acetyl- and propionyl-L-carnitine on peripheral nerve function and vascular supply in experimental diabetes. *Metabolism* 44:1209-1214.
- De Angelis C, Scarfo C, Falcinelli M, Reda E, Ramacci MT, Angelucci L (1992) Levocarnitine acetyl stimulates peripheral nerve regeneration and neuromuscular junction remodelling following sciatic nerve injury. *Int J Clin Pharmacol Res* 12:269-279.
- Dijkstra JR, Meek MF, Robinson PH, Gramsbergen A (2000) Methods to evaluate functional nerve recovery in adult rats: walking track analysis, video analysis and the withdrawal reflex. *J Neurosci Methods* 96:89-96.
- Eto M, Sumi H, Fujimura H, Yoshikawa H, Sakoda S (2008) Pioglitazone promotes peripheral nerve remyelination after crush injury through CD36 upregulation. *J Peripher Nerv Syst* 13:242-248.
- Fernandez E, Pallini R, Gangitano C, Del Fa A, Sangiacomo CO, Sbricoli A, Ricoy JR, Rossi GF (1989) Effects of L-carnitine, L-acetylcarnitine and gangliosides on the regeneration of the transected sciatic nerve in rats. *Neurol Res* 11:57-62.
- Galeotti N, Bartolini A, Calvani M, Nicolai R, Ghelardini C (2004) Acetyl-L-carnitine requires phospholipase C-IP3 pathway activation to induce antinociception. *Neuropharmacology* 47:286-294.
- Garzya G, Corallo D, Fiore A, Lecciso G, Petrelli G, Zotti C (1990) Evaluation of the effects of L-acetylcarnitine on senile patients suffering from depression. *Drugs Exp Clin Res* 16:101-106.
- Gulcin I (2006) Antioxidant and antiradical activities of L-carnitine. *Life Sci* 78:803-811.
- Hart AM, Wiberg M, Youle M, Terenghi G (2002) Systemic acetyl-L-carnitine eliminates sensory neuronal loss after peripheral axotomy: a new clinical approach in the management of peripheral nerve trauma. *Exp Brain Res* 145:182-189.
- Hinerfeld D, Traini MD, Weinberger RP, Cochran B, Doctrow SR, Harry J, Melov S (2004) Endogenous mitochondrial oxidative stress: neurodegeneration, proteomic analysis, specific respiratory chain defects, and efficacious antioxidant therapy in superoxide dismutase 2 null mice. *J Neurochem* 88:657-667.
- Hotta N, Koh N, Sakakibara F, Nakamura J, Hamada Y, Wakao T, Hara T, Mori K, Naruse K, Nakashima E, Sakamoto N (1996) Effect of propionyl-L-carnitine on motor nerve conduction, autonomic cardiac function, and nerve blood flow in rats with streptozotocin-induced diabetes: comparison with an aldose reductase inhibitor. *J Pharmacol Exp Ther* 276:49-55.
- Ido Y, McHowat J, Chang KC, Arrigoni-Martelli E, Orfalian Z, Kilo C, Corr PB, Williamson JR (1994) Neural dysfunction and metabolic imbalances in diabetic rats. Prevention by acetyl-L-carnitine. *Diabetes* 43:1469-1477.
- Kalender AM, Dogan A, Bakan V, Yildiz H, Gokalp MA, Kalender M (2009) Effect of Zofenopril on regeneration of sciatic nerve crush injury in a rat model. *J Brachial Plex Peripher Nerve Inj* 4:6.
- Kanaya F, Firrell J, Tsai TM, Breidenbach WC (1992) Functional results of vascularized versus nonvascularized nerve grafting. *Plast Reconstr Surg* 89:924-930.
- Karsidag S, Akcal A, Sahin S, Karsidag S, Kabukcuoglu F, Ugurlu K (2012) Neurophysiological and morphological responses to treatment with acetyl-L-carnitine in a sciatic nerve injury model: preliminary data. *J Hand Surg Eur Vol* 37:529-536.
- Kou Y, Wang Z, Wu Z, Zhang P, Zhang Y, Yin X, Wong X, Qiu G, Jiang B (2013) Epimedium extract promotes peripheral nerve regeneration in rats. *Evid Based Complement Alternat Med* 2013:954798.
- Kurtoglu Z, Ozturk AH, Bagdatoglu C, Polat G, Aktekin M, Uzman D, Camdeviren H, Bagdatoglu O, Sargon M (2005) Effects of trapidil after crush injury in peripheral nerve. *Acta Med Okayama* 59:37-44.
- Bieber LL (1988) Carnitine. *Annu Rev Biochem* 57:261-283.
- Lowitt S, Malone JJ, Salem A, Kozak WM, Orfalian Z (1993) Acetyl-L-carnitine corrects electroretinographic deficits in experimental diabetes. *Diabetes* 42:1115-1118.
- Mackinnon SE, Dellon AL, Hudson AR, Hunter DA (1985) Nerve regeneration through a pseudosynovial sheath in a primate model. *Plast Reconstr Surg* 75:833-841.
- Malone JJ, Lowitt S, Salem AF, Miranda C, Korthals JK, Carver J (1996) The effects of acetyl-L-carnitine and sorbinil on peripheral nerve structure, chemistry, and function in experimental diabetes. *Metabolism* 45:902-907.
- Navarro X, Vivo M, Valero-Cabre A (2007) Neural plasticity after peripheral nerve injury and regeneration. *Prog Neurobiol* 82:163-201.
- Onofrij M, Fulgente T, Melchionda D, Marchionni A, Tomasello F, Salpietro FM, Alafaci C, De Sanctis E, Pennisi G, Bella R, et al. (1995) L-acetylcarnitine as a new therapeutic approach for peripheral neuropathies with pain. *Int J Clin Pharmacol Res* 15:9-15.
- Pan HC, Yang DY, Ou YC, Ho SP, Cheng FC, Chen CJ (2010) Neuroprotective effect of atorvastatin in an experimental model of nerve crush injury. *Neurosurgery* 67:376-388; discussion 388-379.
- Pettegrew JW, Levine J, McClure RJ (2000) Acetyl-L-carnitine physical-chemical, metabolic, and therapeutic properties: relevance for its mode of action in Alzheimer's disease and geriatric depression. *Mol Psychiatry* 5:616-632.
- Robinson LR (2000) Traumatic injury to peripheral nerves. *Muscle Nerve* 23:863-873.
- Rump TJ, Abdul Muneer PM, Szlachetka AM, Lamb A, Haorei C, Ali-kunju S, Xiong H, Keblesh J, Liu J, Zimmerman MC, Jones J, Donohue TM, Jr., Persidsky Y, Haorah J (2010) Acetyl-L-carnitine protects neuronal function from alcohol-induced oxidative damage in the brain. *Free Radic Biol Med* 49:1494-1504.
- Stevens MJ, Lattimer SA, Feldman EL, Helton ED, Millington DS, Sima AA, Greene DA (1996) Acetyl-L-carnitine deficiency as a cause of altered nerve myo-inositol content, Na,K-ATPase activity, and motor conduction velocity in the streptozotocin-diabetic rat. *Metabolism* 45:865-872.
- Tamaddonfard E, Farshid AA, Maroufi S, Kazemi-Shojaei S, Erfanparast A, Asri-Rezaei S, Taati M, Dabbaghi M, Escort M (2014) Effects of safranal, a constituent of saffron, and vitamin E on nerve functions and histopathology following crush injury of sciatic nerve in rats. *Phytomedicine* 21:717-723.
- Vary TC, Neely JR (1982) A mechanism for reduced myocardial carnitine levels in diabetic animals. *Am J Physiol* 243:H154-158.
- Yin ZS, Zhang H, Bo W, Gao W (2010) Erythropoietin promotes functional recovery and enhances nerve regeneration after peripheral nerve injury in rats. *AJNR Am J Neuroradiol* 31:509-515.

Copyedited by Zhao YT, Pan W, Li CH, Song LP, Zhao M