

Recurrent non-traumatic idiopathic chylothorax: a diagnostic dilemma with therapeutic challenge

Rohit Vadala¹ , Dhruv Talwar² & Deepak Talwar¹

¹Metro Centre for Respiratory Diseases (MCRD), Metro Multispeciality Hospital, Noida, India.

²Department of Medicine, JNMC, Wardha, India.

Keywords

Chylothorax, filariasis, non-traumatic, recurrent.

Correspondence

Deepak Talwar, Director & Chair, Metro Centre for Respiratory Diseases (MCRD), Metro Multispeciality Hospital, Noida 201301, India. E-mail: dtlung@gmail.com

Received: 23 April 2020; Revised: 3 June 2020;

Accepted: 15 July 2020; Associate Editor: John

Wrightson.

Respirology Case Reports, 8 (7), 2020, e00637

doi: 10.1002/rcr2.637

Introduction

Chylothorax is an uncommon pleural effusion characterized by the presence of chyle in the pleural space. Malignancy, trauma, and infections such as tuberculosis and filariasis can result in chylothorax. The chyle is an odourless and white liquid; however, around 50% of chylothorax is not milky (serosanguineous) and 10% of chylothorax is idiopathic which can pose a diagnostic dilemma [1]. We propose to include pleural fluid triglycerides and cholesterol in systematic approach for all undiagnosed pleural effusion. The case highlights the diagnostic dilemma as well as therapeutic challenges.

Case Report

A 63-year-old man, resident of Jharkhand (India), ex-smoker with 10 cigarette pack-years, non-alcoholic, non-diabetic, hypertensive on medications since four years presented to our facility with gradually progressive breathlessness, modified Medical Research Council (mMRC) grade 1 to mMRC grade 2, along with recurrent right-sided pleuritic chest pain for two years. There was no history of associated persistent fever, loss of weight, or haemoptysis.

Abstract

Chylothorax is an uncommon pleural effusion characterized by the presence of chyle in the pleural space. Malignancy, trauma, and infections such as tuberculosis and filariasis can result in chylothorax. The chyle is an odourless and white liquid; however, around 50% of chylothorax is not milky (serosanguineous) and 10% of chylothorax is idiopathic which can pose a diagnostic dilemma. We propose a systematic approach which includes pleural fluid triglycerides and cholesterol for all undiagnosed pleural effusion. The case highlights the diagnostic dilemma as well as therapeutic challenges.

The patient had a past history right upper limb swelling which was evaluated and treated for filariasis 30 years ago. There was no history of any trauma and exact details of the treatment were not available with the patient. Our patient also had a past history of recurrent right-sided pleural effusion treated at elsewhere facility. He had right-sided pleural effusion six years ago which was aspirated and was exudative with lymphocytic predominance. Pleural fluid adenosine deaminase (ADA) was not done and the patient was treated with anti-tubercular treatment (ATT) for nine months. During the course of treatment, the patient had undergone several therapeutic thoracentesis from right side to relieve his dyspnoea. He completed his ATT and again three years back, the fluid re-accumulated on the right side and it was again aspirated with similar findings on pleural fluid analysis. The patient was treated with ATT again for one year with no symptomatic improvement.

The patient then presented to our facility with undiagnosed recurrent right-sided pleural effusion. The patient was haemodynamically stable and general examination showed no pallor, icterus, clubbing, or pedal oedema. Right upper limb swelling was noted which was non-pitting and considered asymmetry due to right handedness of the patient. Ultrasonography of the right upper limb did not show any evidence of deep vein thrombosis.

jugular venous pressure (JVP) was not raised and neck veins were not engorged. Cardiovascular system examination revealed normal findings. Respiratory system examination revealed decreased breath sounds over right infra-scapular and infra-axillary area with stony dullness. Electrocardiogram and two-dimensional (2D) echocardiography were normal. Figure 1 shows the chest X-ray and computed tomography (CT) of the patient.

Contrast-enhanced CT (CECT) thorax with CT pulmonary angiogram (CTPA) was done which revealed non-loculated right pleural effusion with no pleural thickening or irregularity and near-complete collapse of the right lower lobe. Rest of the lung parenchyma, mediastinum, and upper abdomen were normal. There was no evidence of pulmonary thromboembolism (PTE).

Diagnostic thoracentesis was performed which showed blood-tinged pleural fluid with pH of 7.5, protein of 4.5 g/dL, glucose of 149 mg/dL, lactate dehydrogenase (LDH) of 180 U/L, ADA of 21.8 IU/L (normal reference range: 0–30 U/L), total leukocyte count (TLC) of 1000/mm³ with mostly lymphocytes and few mesothelial cells, cholesterol of 20 mg/dL, and triglycerides of 870 mg/dL; pyogenic culture was sterile and GenXpert (Cepheid-Xpert[®] MTB/RIF-USA) was negative. Pleural fluid cytology did not show any evidence of malignant cells. Ziehl–Neelsen (ZN) staining of pleural fluid was negative. Pleural fluid remained turbid and blood tinged even after centrifugation and addition of ethyl ether suggesting probable chylothorax. Lipoprotein electrophoresis of the pleural fluid showed the presence of chylomicron confirming the diagnosis as chylothorax. Other laboratory tests including the full blood count and erythrocyte sedimentation rate (ESR) were normal. Blood film examination for microfilaria was done twice which was negative.

In view of chylothorax, a positron emission tomography-CT (PET-CT) was done which showed no abnormal hypermetabolic focus in the body. Lymphoscintigraphy was done to visualize lymphatic abnormality

which showed no abnormality or any leak. Furthermore, the patient underwent medical thoracoscopy and pleural surface was unremarkable and multiple pleural biopsies were taken. Pleural biopsy revealed non-specific chronic inflammation and it was negative for *Mycobacterium tuberculosis*. The patient was managed with intercostal drainage (ICD) tube and he was kept on a restricted fat diet consisting of medium-chain triglycerides along with high proteins.

Thoracic surgeon opinion was taken regarding pleuroperitoneal shunt for recurrent chylothorax. However, the patient was conservatively managed and the ICD tube drain reduced with dietary modification. ICD was removed when the drain was less than 100 mL and the patient was discharged in stable condition. The patient remains to be asymptomatic with no recurrence at 12 months follow-up after discharge from hospital.

Discussion

Chylothorax is a rare pleural effusion due to accumulation of chyle in the pleural cavity. The most common cause for chylothorax is malignancy followed by trauma. Infectious chylothorax secondary to tuberculosis or filariasis is not frequently seen and few case reports have been reported. Filariasis as a cause for chylothorax is very rare and is often faced with a diagnostic challenge and few cases have been reported. Early diagnosis and prompt management have been shown to improve patient outcomes and quality of life [2]. We present a rather unusual case of recurrent non-traumatic idiopathic chylothorax which posed a challenge in diagnosis and further management.

Chyle is a bacteriostatic milky body formed in the intestine that contains chylomicron, triglycerides, and lymphocytes. The effusion may be unilateral, mostly on right side in 50% of cases, left side in 33% while bilateral in 17% cases. It is dependent on the site of the leak. Chylothorax is an exudative effusion and almost 50% of them are blood stained and the rest half have a classic milky appearance

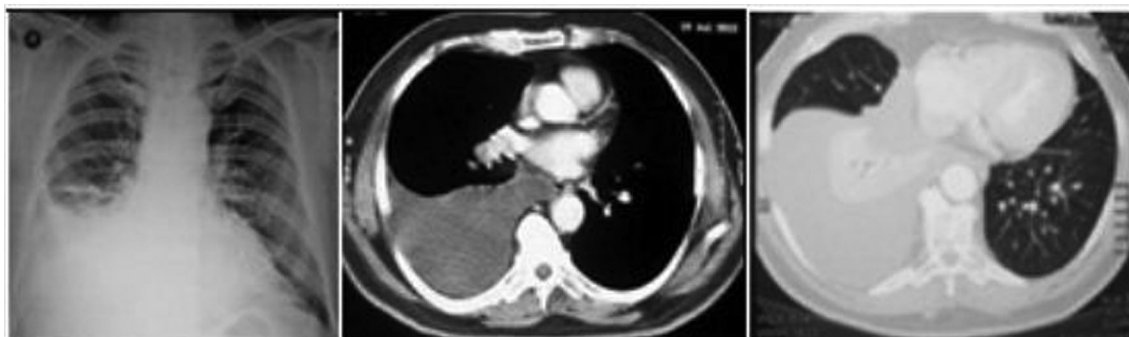

Figure 1. Chest X-ray and computed tomography (CT) of the patient showing right-sided pleural effusion with collapse of right lower lobe.

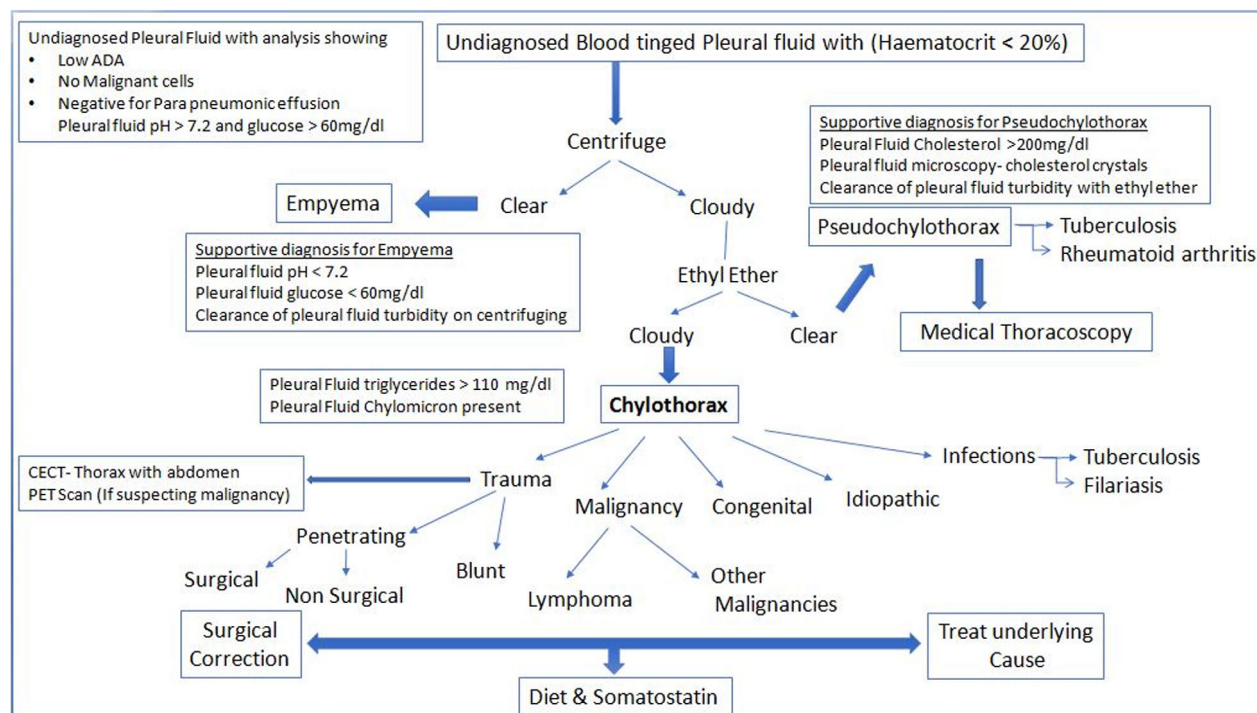


Figure 2. Proposed algorithmic approach to undiagnosed milky or turbid blood-tinged pleural effusion.

[3]. Our patient presented with recurrent right-sided pleural effusion with pleural fluid appearance of blood-tinged turbid fluid. The patient received ATT in the past based on the pleural fluid analysis showing exudative and lymphocyte predominance with no improvement on treatment. However, additional laboratory analysis of the pleural fluid was warranted to determine the exact diagnosis when he did not improve with therapy and he further presented to our facility with recurrent right-sided effusion (Fig. 2).

Chylothorax can be differentiated from empyema by centrifuging the pleural fluid which remains uniform while the supernatant is clear in empyema. Pseudochylothorax can be differentiated from chylothorax by addition of ethyl ether which results in clearing of milky appearance [4]. Pleural fluid with increased triglyceride levels more than 110 mg/dL is probably chylothorax and the presence of chylomicron on lipoprotein analysis confirmed the diagnosis of chylothorax [5].

The probable causes for non-traumatic chylothorax considered in our case were malignancy, infectious causes such as tuberculosis and filariasis, or idiopathic chylothorax [6]. However, radiological and laboratory investigation revealed no evidence of malignancy or tuberculosis. Filarial chylothorax was initially considered due to exclusion of malignancy and obvious past history of filariasis; however, lymphoscintigraphy did not show any

abnormality or chyle leak [7] and finally the diagnosis of idiopathic chylothorax was made.

Management of chylothorax is a big challenge especially in non-traumatic cases where there is no obvious source of chyle leakage. Most of the cases do respond to restricted fat diet consisting of medium-chain triglyceride along with complete drainage of the chyle via ICD. In patients who are not managed with dietary management, octreotide has been tried as a potential treatment option with great success. Octreotide has shown to reduce the splanchnic blood flow and the absorption of triglycerides thereby reducing chyle leak [8]. However, in some patients, who present with recurrent chylothorax, thoracic surgeons do consider pleuroperitoneal shunt in the treatment of chylothorax [9].

Our patient who presented with recurrent chylothorax did respond to conservative therapy and remained asymptomatic 12 months after discharge emphasizing the importance of systematic approach to evaluate such recurrent undiagnosed pleural effusion which should include pleural fluid triglycerides and cholesterol, even when it is non-white or milky.

Disclosure Statement

Appropriate written informed consent was obtained for publication of this case report and accompanying images.

References

1. Desai N, Chaddha U, Desai S, et al. 2012. Idiopathic chylothorax in a young man. *BMJ Case Rep.* 2012: bcr2012007318. <https://doi.org/10.1136/bcr-2012-007318>.
2. Bender B, Murthy V, and Chamberlain R. 2016. The changing management of chylothorax in the modern era. *Eur. J. Cardiothorac. Surg.* 49(1):18–24.
3. Maldonado F, Hawkins FJ, Daniels CE, et al. 2009. Pleural fluid characteristics of chylothorax. *Mayo Clin. Proc.* 84:129–133.
4. McGrath E, Blades Z, and Anderson P. 2010. Chylothorax: aetiology, diagnosis and therapeutic options. *Respir. Med.* 104:1–8.
5. Talwar A, and Lee H. 2008. A contemporary review of chylothorax. *Indian J. Chest Dis. Allied Sci.* 50:343–351.
6. Ananthan V, and Siva K. 2012. A rare case of acid-fast bacilli in chylothorax. *Lung India* 29(2):166–168.
7. Goh KL, Tan HW, Loh TG, et al. 1986. Chylothorax due to filariasis – a case report. *Singapore Med. J.* 27:173–176.
8. Kalomenidis I. 2006. Octreotide and chylothorax. *Curr. Opin. Pulm. Med.* 12:264–267.
9. Kitchen ND, Hocken DB, Greenhalgh RM, et al. 1991. Use of the Denver pleuroperitoneal shunt in the treatment of chylothorax secondary to filariasis. *Thorax* 46:144–145.