

Systemic and primary cutaneous anaplastic large cell lymphoma: Clinical features, morphological spectrum, and immunohistochemical profile

Kanwardeep Singh Kwatra, Preethi A. M. Paul, Nalini Calton, Joseph M. John¹, James D. Cotelingam²

Abstract

Background: T-cell lymphomas with anaplastic morphology typically comprise of anaplastic lymphoma kinase positive, anaplastic large cell lymphoma (ALK+ ALCL), ALK-negative ALCL (ALK- ALCL), and primary cutaneous ALCL (PC-ALCL). However, other entities such as diffuse large B-cell lymphoma, peripheral T-cell lymphoma, Hodgkin lymphoma, and undifferentiated carcinoma can also show similar anaplastic features. **Aims:** To study the clinical features and histological spectrum of ALCL and emphasize the role of immunohistochemistry (IHC) in their diagnosis and categorization. **Setting and Design:** Eight cases of ALCL diagnosed over a period of 4 years were selected for the study. **Materials and Methods:** Histopathological review and IHC was performed on all cases. Two ALK+ ALCL cases were tested by fluorescent *in situ* hybridization (FISH) for t(2;5)(p23;q35). **Results:** There were four cases of ALK+ ALCL and two each of ALK- ALCL and PC-ALCL. Histologically, all the subtypes showed pleomorphic and “hallmark” cells with strong CD30 expression and variable loss of T-cell antigens. One case of PC-ALCL was leukocyte common antigen (LCA) negative. Epithelial membrane antigen was positive in all the six systemic ALCL cases. Two cases tested for t(2;5)(p23;q35) by FISH were positive. **Conclusions:** Diagnosis of ALCL is based on recognizing the key morphological features, especially the presence of “hallmark” cells. IHC is essential for confirmation of diagnosis and excluding other malignancies with anaplastic morphology. The inclusion of CD30 in the initial IHC panel will help identify LCA negative cases and avoid misdiagnosis.

Key words: Anaplastic large cell lymphoma, anaplastic lymphoma kinase-1, CD30, epithelial membrane antigen, immunohistochemistry, non-Hodgkin lymphoma, T-cell

Introduction

Anaplastic large cell lymphomas (ALCLs) are a group of T-cell lymphomas composed of anaplastic large lymphoid cells which show diffuse CD30 positivity. It includes three entities, namely anaplastic lymphoma kinase positive, ALCL (ALK+ ALCL), ALK-negative ALCL (ALK- ALCL), and primary cutaneous ALCL (PC-ALCL).^[1-3] ALCL should be distinguished from other lymphomas with anaplastic features which may also show CD30 expression, like diffuse large B-cell lymphoma (DLBCL), classical Hodgkin lymphoma, and peripheral T-cell lymphoma not otherwise specified (PTCL-NOS). In this single institutional study of eight cases, we analyze the clinicopathological features and immunohistochemical (IHC) profile of ALCL with emphasis on diagnostic pitfalls.

Materials and Methods

All cases diagnosed as ALCL over a period of 4 years in our institution (2011–2014), were included in the study. Hematoxylin and eosin sections and IHC sections were reviewed. All cases were stained with CD45, CD30, ALK-1, CD20, PAX5, CD15, epithelial membrane antigen (EMA), Epstein-Barr virus (latent membrane protein-1) and Ki-67 using standard IHC protocols. Fluorescent *in situ* hybridization (FISH) for ALK translocation t(2;5)(p23;q35) was carried out using Vysis ALK dual color LSI break apart FISH probe.

Results

Of a total of 246 cases of non-Hodgkin lymphoma (NHL) diagnosed over a period of 4 years, eight cases (3.3%) were categorized as ALCL. Of these, four were ALK+ ALCL, and there were two cases each of ALK- ALCL and PC-ALCL.

The clinical features and histopathological findings are summarized in Table 1. The age range was 15–72 years with an equal sex distribution in all the subtypes. B-symptoms were present in four cases, three of which were ALK+ ALCL.

Extranodal involvement of the intestine was present in one case of ALK- ALCL. One case of PC-ALCL had multiple lesions on the thigh and gluteal region while the other had a solitary lesion on the face. Hepatomegaly was present in three cases, one ALK+ ALCL and two ALK- ALCL cases, while none had splenomegaly. Bone marrow (BM) involvement was present in one case of ALK+ ALCL. Serum lactate dehydrogenase levels were increased with a mean value of 407 U/L.

All the cases showed diffuse sheets of large anaplastic lymphoid cells with interspersed scattered “hallmark” cells. The latter showed large kidney-shaped vesicular nuclei, conspicuous nucleoli, and abundant cytoplasm [Figure 1]. One case of ALK+ ALCL resembled syncytial variant of nodular sclerosis Hodgkin lymphoma. Mitotic activity was uniformly high. A polymorphous inflammatory background was present in one case of ALK- ALCL and one case of PC-ALCL, which was ulcerated.

IHC findings are shown in Table 2. All cases were strongly and uniformly positive for CD30. The pattern of staining of ALK-1 in all the four ALK+ ALCL cases was nuclear and cytoplasmic [Figure 2]. One case of PC-ALCL was leukocyte common antigen (LCA) negative. Aberrant loss of CD3 was present in 5/8 cases, CD5 loss in 3/8, and both CD3 and CD5 loss in 2/8 cases. Both the cases of PC-ALCL were EMA negative while all the six cases of systemic ALCL were positive. The mean Ki-67 proliferative index was 74%. Two cases of ALK+, ALCL tested for t(2;5)(p23;q35) by FISH were positive. Complete staging and work up were possible in five of eight cases. Of these five cases, treatment was possible in three; 2 ALK+ ALCL (Case numbers 1 and 2) and 1 PC-ALCL (Case number 7). All were given six cycles of cyclophosphamide, adriamycin, vincristine, and prednisolone (CHOP) and were in clinical remission at their last follow-up of 3 years,

This is an open access article distributed under the terms of the Creative Commons Attribution-NonCommercial-ShareAlike 3.0 License, which allows others to remix, tweak, and build upon the work non-commercially, as long as the author is credited and the new creations are licensed under the identical terms.

For reprints contact: reprints@medknow.com

How to cite this article: Kwatra KS, Paul PA, Calton N, John JM, Cotelingam JD. Systemic and primary cutaneous anaplastic large cell lymphoma: Clinical features, morphological spectrum, and immunohistochemical profile. South Asian J Cancer 2017;6:129-31.

Access this article online

Quick Response Code:



Website: www.sajc.org

DOI: 10.4103/2278-330X.214575

Department of Pathology, Christian Medical College and Hospital, ¹Department of Clinical Hematology, Hemato-Oncology and Bone Marrow (Stem Cell) Transplant Unit, Christian Medical College and Hospital, Ludhiana, Punjab, India, ²Department of Pathology, Louisiana State University Health Sciences Center, Shreveport, LA 71103, USA
Correspondence to: Dr. Kanwardeep Singh Kwatra, E-mail: kwatraks@gmail.com

Table 1: Clinical profile and histopathological findings of patients with anaplastic large cell lymphoma

Case	Age/sex	Diagnosis	Involved sites	Histopathology	BM involvement	Stage
1	15/male	ALK+ ALCL	Generalized LN	Complete effacement, diffuse pattern Large pleomorphic cells with hallmark cells High mitotic activity with focal starry-sky appearance	No	IIB
2	36/female	ALK+ ALCL	Generalized LN	Complete effacement, nodular architecture with fibrous bands (nodular sclerosis-like) Large pleomorphic cells in sheets with hallmark cells High mitotic activity	No	IIIA
3	18/male	ALK+ ALCL	Mediastinal and cervical LN	Complete effacement, diffuse pattern Large pleomorphic cells with hallmark cells High mitotic activity	ND	ND
4	32/female	ALK+ ALCL	Cervical and axillary LN	Partial effacement, diffuse pattern Large pleomorphic cells, with hallmark cells High mitotic activity	Yes	IVB
5	68/male	ALK- ALCL	Small intestine, rectum, mesenteric LN	Wall thickened with multiple perforations, diffuse pattern Large pleomorphic cells with hallmark cells High mitotic activity	No	IIIA
6	45/female	ALK- ALCL	Hepato-duodenal LN	Partial effacement, diffuse pattern Large pleomorphic cells with hallmark cells High mitotic activity Few neutrophils, eosinophils and plasma cells	ND	ND
7	71/male	PC-ALCL	Multiple skin nodules over thigh and gluteal area, inguinal LN	Diffuse pattern, focal ulceration, no epidermotropism Large pleomorphic cells with hallmark cells High mitotic activity, necrosis	No	IIA
8	72/female	PC-ALCL	Solitary ulcerated skin nodule - face	Diffuse pattern, ulceration, no epidermotropism Large pleomorphic cells with hallmark cells Several lymphocytes, plasma cells, eosinophils, neutrophils and histiocytes Subcutaneous fat infiltrated	ND	ND

LN=Lymphadenopathy, ND=Not done, ALCL=Anaplastic large cell lymphoma, ALK=Anaplastic lymphoma kinase, PC=Primary cutaneous, BM=Bone marrow

1 year, and 2 years 9 months, respectively. Two patients; one ALK+ ALCL (Case number 4) and one ALK- ALCL (Case number 5), expired at diagnosis, and the remaining three were lost to follow-up.

Discussion

The rarity of ALCL was highlighted in our study which showed it to comprise 3.3% (8/246) of all NHL. A clinical evaluation of 1378 cases of NHL by International NHL Classification Project found ALCL to be comprising 2.4%.^[4]

The clinical profile of our patients was similar to that described in literature. ALK+ ALCL mostly occurs in the first three decades of life with the male:female ratio ranging from 1.5 and 6.5.^[1] This lymphoma is aggressive and frequently presents as Stage III-IV disease with systemic symptoms and extranodal involvement.

^[1] The frequency of BM involvement is 11%. Only one case of ALK+ ALCL in our series had BM involvement. ALK- ALCL occurs in older patients, peak age of incidence being in the sixth decade of life, with a lower male predominance when compared to ALK+ ALCL. Advanced-stage disease and B-symptoms are relatively less common.^[2,5] Primary cutaneous CD30-positive T-cell lymphoproliferative disorders include PC-ALCL and lymphomatoid papulosis (LyP). The median age at diagnosis for PC-ALCL is 60 years with a male:female ratio of 2-3:1.^[3,6] Common sites of involvement are the face, trunk, extremities, and buttocks. They commonly present with solitary nodules that may ulcerate. In 20% of cases, the lesions are multiple while in 10% cases there may be regional lymph node involvement.^[3,6]

Histologically, all types of ALCL are characterized by sheets of large pleomorphic cells with a variable proportion of "hallmark" cells showing typical horseshoe-shaped nuclei. In ALK+ ALCL, morphological patterns that have been recognized

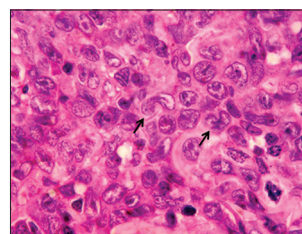


Figure 1: Anaplastic lymphoid cells and "hallmark" cells (arrows) (H and E, x800)

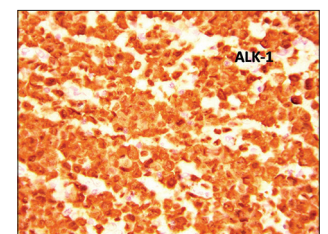


Figure 2: Anaplastic lymphoma kinase-1 positivity, both nuclear and cytoplasmic (IHC, x400)

are: (1) Common pattern (60%); (2) lymphohistiocytic pattern (10%); (3) small cell pattern (5-10%); (4) Hodgkin-like pattern (3%); and (5) composite pattern (15%).^[1,4] One case of ALK+ ALCL in our series showed nodular sclerosis Hodgkin-like pattern. The rest showed "common pattern." The histology of ALK- ALCL shows a similar morphologic spectrum.^[2,4] PC-ALCL shows nonepidermotropic infiltrates of anaplastic cells with a variable number of inflammatory cells in the background which are especially prominent in ulcerated lesions. To differentiate such cases from LyP features like lesions limited to an anatomical region and infiltration into subcutaneous tissue favor a diagnosis of PC-ALCL.^[7]

The defining feature of all types of ALCL is strong and diffuses CD30 staining in more than 75% of tumor cells. All eight cases in our series had a uniform and intense CD30 staining. Positivity for CD30 is not specific for ALCL and can be expressed by HRS cells and a subset of B- and T-cell lymphomas.^[4] However, the CD30 immunostain is generally less intense in CD30+ PTCL-NOS and DLBCL and is often seen only in a fraction of tumor cells. ALCL usually demonstrate an aberrant T phenotype, with frequent loss of T-cell markers.

Table 2: Immunohistochemical profile of anaplastic large cell lymphoma cases

Case	Diagnosis	LCA	CD30	CD3	CD5	ALK-1	CD20	PAX5	CD15	EMA	EBV	Ki-67 (%)
1	ALK+ ALCL	+	+	-	+	+	-	-	-	+	-	95
2	ALK+ ALCL	+	+	+	+	+	-	-	-	+	-	70
3	ALK+ ALCL	+ weak	+	-	-	+	-	-	-	+	-	80
4	ALK+ ALCL	+	+	-	+	+	-	-	-	+	-	50
5	ALK- ALCL	+	+	+	-	-	-	-	-	+	-	65
6	ALK- ALCL	+	+	+	+	-	-	-	-	+	-	90
7	PC-ALCL	-	+	-	-	-	-	-	-	-	-	90
8	PC-ALCL	+	+	-	+	-	-	-	-	-	-	50

ALCL=Anaplastic large cell lymphoma, ALK=Anaplastic lymphoma kinase, PC=Primary cutaneous, LCA=Leukocyte common antigen, EMA=Epithelial membrane antigen, EBV=Epstein-Barr virus, + =Positive, - = Negative

Null cell ALCL by IHC can usually be proven to be lymphoma of T-cell origin with clonal T-cell receptor rearrangements.^[4] In our series, aberrant T-cell antigen loss was a frequent finding. A diagnostic pitfall is negative or weak staining for LCA in some cases of ALCL.^[8] One case of PC-ALCL was LCA negative with loss of T-cell antigens and initially misdiagnosed as melanoma at another institute. Hence in suspected cases, CD30 should always be included in the initial IHC panel. In certain situations, like Case number 4 in our study, which was a treated case of carcinoma esophagus, metastatic carcinoma may enter the histological differential diagnosis. It is preferable to use cytokeratin immunostain than EMA for this purpose as ALCL can be EMA positive.^[4] EMA expression is more frequent in ALK+ than ALK- ALCL (83% vs. 43%).^[5]

In histologically suspected cases which are a CD30 positive, further evaluation with markers for T-cells (CD2, CD3, CD5), B-cells (CD20, PAX5), Hodgkin lymphoma (CD15, PAX5) and ALCL (ALK-1) is required. To distinguish PC-ALCL from systemic ALCL with secondary skin involvement, EMA can be helpful, which is usually negative in the former.^[7] Feature which differentiates ALK- ALCL from PTCL-NOS is weak and heterogeneous staining of CD30, consistent expression of T-cell markers and EMA negativity in the latter.^[5]

Systemic ALK+ ALCL show t(2;5)(p23;q35) in 84% cases. Variant translocations also occur, albeit with a much lower frequency.^[9] Translocation t(2;5) results in a nuclear and diffuse cytoplasmic staining for ALK-1 on IHC. All the four ALK+ ALCL cases in our series showed nuclear and diffuse cytoplasmic staining and two of these who were tested for t(2;5) by FISH were positive. Variant translocations can produce cytoplasmic, membranous or nuclear staining patterns.^[1]

CHOP chemotherapy regimen remains the standard of care in primary systemic ALCL. The addition of etoposide to the standard CHOP regimen is an important consideration for young patients with ALK+ ALCL.^[10] Immunologic strategies with anti-CD30 agent brentuximab vedotin and ALK inhibitor crizotinib have also been used. Solitary or localized PC-ALCL is best treated with radiation therapy or surgical excision.

Five year overall survival (OS) rates for ALK+ ALCL have ranged from 70% to 93% and that of ALK- ALCL from 15% to 49%.^[5] PC-ALCL has a very high OS of 90% at 10 years.^[3] Two patients of ALK+ ALCL and one of PC-ALCL who were given CHOP therapy showed good response to treatment and were in clinical remission at their last follow-up.

Conclusions

The clinical and histopathological findings of our study are commensurate with that recorded in literature. LCA negativity and aberrant T-cell antigen loss are potential diagnostic pitfalls. However, a diligent search for hallmark cells with the inclusion of CD30 and at least two T-cell markers in the initial IHC panel will clinch the diagnosis in most cases.

Financial support and sponsorship

Nil.

Conflicts of interest

There are no conflicts of interest.

References

- Delsol G, Falini B, Muller-Hermelink HK, Campo E, Jaffe ES, Gascoyne RD, et al. Anaplastic large cell lymphoma (ALCL), ALK-positive. In: Swerdlow SH, Campo E, Harris NL, Jaffe ES, Pileri SA, Stein H, et al., editors. WHO Classification of Tumours of Haemopoietic and Lymphoid Tissue. 4th ed. Lyon: International Agency for Research on Cancer (IARC); 2008. p. 312-6.
- Mason DY, Harris NL, Delsol G, Stein H, Campo E, Kinney MC, et al. Anaplastic large cell lymphoma, ALK-negative. In: Swerdlow SH, Campo E, Harris NL, Jaffe ES, Pileri SA, Stein H, et al., editors. WHO Classification of Tumours of Haemopoietic and Lymphoid Tissue. 4th ed. Lyon: International Agency for Research on Cancer (IARC); 2008. p. 317-9.
- Ralfkiaer E, Willemze R, Paulli M, Kadin ME. Primary cutaneous CD30-positive T-cell lymphoproliferative disorders. In: Swerdlow SH, Campo E, Harris NL, Jaffe ES, Pileri SA, Stein H, et al., editors. WHO Classification of Tumours of Haemopoietic and Lymphoid Tissue. 4th ed. Lyon: International Agency for Research on Cancer (IARC); 2008. p. 300-1.
- Inghirami G, Pileri SA; European T-Cell Lymphoma Study Group. Anaplastic large-cell lymphoma. *Semin Diagn Pathol* 2011;28:190-201.
- Savage KJ, Harris NL, Vose JM, Ullrich F, Jaffe ES, Connors JM, et al. ALK- anaplastic large-cell lymphoma is clinically and immunophenotypically different from both ALK+ALCL and peripheral T-cell lymphoma, not otherwise specified: Report from the International Peripheral T-Cell Lymphoma Project. *Blood* 2008;111:5496-504.
- Burg G, Kempf W, Cozzio A, Feit J, Willemze R, Jaffe ES, et al. WHO/EORTC classification of cutaneous lymphomas 2005: Histological and molecular aspects. *J Cutan Pathol* 2005;32:647-74.
- Calzado-Villarreal L, Polo-Rodríguez I, Ortiz-Romero PL. Primary cutaneous CD30+ lymphoproliferative disorders. *Actas Dermosifiliogr* 2010;101:119-28.
- Gustafson S, Medeiros LJ, Kalthor N, Bueso-Ramos CE. Anaplastic large cell lymphoma: Another entity in the differential diagnosis of small round blue cell tumors. *Ann Diagn Pathol* 2009;13:413-27.
- Amin HM, Lai R. Pathobiology of ALK+ anaplastic large-cell lymphoma. *Blood* 2007;110:2259-67.
- Schmitz N, Trümper L, Ziepert M, Nickelsen M, Ho AD, Metzner B, et al. Treatment and prognosis of mature T-cell and NK-cell lymphoma: An analysis of patients with T-cell lymphoma treated in studies of the German High-Grade Non-Hodgkin Lymphoma Study Group. *Blood* 2010;116:3418-25.