



CASE REPORT

Heterotopic pleomorphic adenoma in the postauricular area



Hsiu-An Hsu^a, Fang-Chih Kuo^b, Ye-Jen Hsia^{a,c*}

^a Department of Oral and Maxillofacial Surgery, Tri-Service General Hospital, Taipei, Taiwan

^b Oral and Maxillofacial Surgeon, Private Practice, Taipei, Taiwan

^c Department of Oral and Maxillofacial Surgery, Taipei Tzu Chi General Hospital, Taipei, Taiwan

Final revision received 4 May 2012; accepted 4 October 2012

Available online 14 December 2012

KEYWORDS

heterotopic salivary tissues;
neck mass;
pleomorphic adenoma

Abstract Heterotopic salivary gland tissue is salivary tissue located outside the sites generally known to accommodate major and minor salivary glands. Although heterotopic salivary tumors were reported in various regions of the head and neck, they are seldom found in the superio-posterior neck region and can be confused with other neck masses. Herein, we present a rare case of a heterotopic pleomorphic adenoma in the postauricular area and remind clinicians that heterotopic salivary tumors should be in the differential diagnosis of neck masses. © 2018 Association for Dental Sciences of the Republic of China. Publishing services by Elsevier B.V. This is an open access article under the CC BY-NC-ND license (<https://creativecommons.org/licenses/by-nc-nd/4.0/>).

Introduction

Heterotopic salivary gland tissue (HSGT) is salivary tissue located outside the sites generally known to accommodate major and minor salivary glands. Tumors arising from ectopic salivary tissues are rare. Although heterotopic salivary tumors were reported in various regions of the head and neck, they are seldom found in the superio-posterior

neck region. Herein, we present a rare case of a heterotopic pleomorphic adenoma in the postauricular area.

Case presentation

A 32-year-old healthy woman was referred for an evaluation of a painless, slowly growing mass behind her right ear, which she first noticed 3 years before. She denied a history of using cigarettes, alcohol, or betel nuts. A physical examination revealed a painless, firm, well-defined, 3 × 2-cm mass with intact overlying cervical skin in the postauricular region (Fig. 1). The patient's neck could move freely in every direction. No other head or neck abnormalities were noted.

* Corresponding author. Department of Oral and Maxillofacial Surgery, Tri-Service General Hospital, 2nd Floor, 325 Chenggong Road, Section 2, Neihu District, Taipei 114, Taiwan.

E-mail address: nh4hsu@yahoo.com.tw (Y.-J. Hsia).

1991-7902/© 2018 Association for Dental Sciences of the Republic of China. Publishing services by Elsevier B.V. This is an open access article under the CC BY-NC-ND license (<https://creativecommons.org/licenses/by-nc-nd/4.0/>).

<http://dx.doi.org/10.1016/j.jds.2012.10.004>

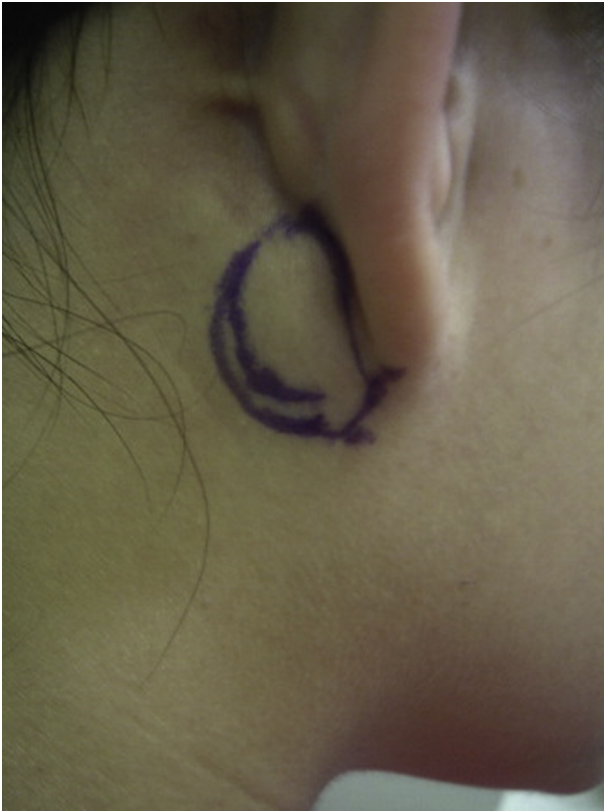

Figure 1 Painless mass measuring 3 × 2 cm with intact overlying cervical skin in the postauricular region.

The preoperative differential diagnosis included a heterotopic salivary gland tumor, neck lymphadenopathy, a cyst, and, less likely, a malignant tumor. An excisional biopsy was planned and was carried out under general anesthesia. Intraoperatively, the skin flap was elevated along the posterior border of the mass. The lesion was found to be solitary and deep in the investing layer of the deep cervical fascia without sinus tract formation. The mass was easily dissected from the surrounding fascia and was completely excised from the neck (Fig. 2). The specimen was a firm, well-encapsulated tumor, measuring

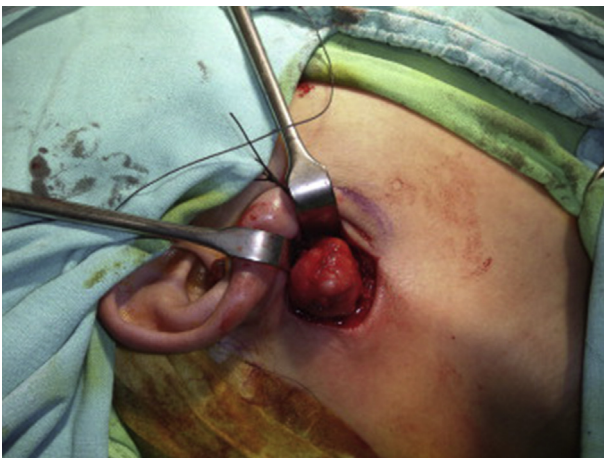

Figure 2 Encapsulated mass with a well-defined margin was identified and excised from the posterior neck.

2.5 × 2 × 2 cm. A microscopic analysis of the tumor revealed a combination of glandular epithelium and mesenchyme-like tissues without malignant change (Fig. 3). The diagnosis was a heterotopic pleomorphic adenoma in the postauricular area. The patient was followed-up for 1 year without recurrence.

Discussion

HSGTs are rare and should be distinguished from accessory salivary gland tissues. Accessory salivary glands are ectopic salivary gland tissues with a duct connecting them to the main salivary duct system, whereas heterotopic salivary glands have acini without a duct system.¹ An accessory parotid gland is not uncommon, and has an incidence rate of approximately 21–56% reported in adults.² In our case, the lesion was isolated from the parotid gland, and there was no duct system connecting the lesion to the parotid duct. Therefore, this lesion can be regarded as heterotopic to the salivary gland.

Theories of development of ectopic salivary tissues in the head and neck area were proposed in the literature, including entrapment of salivary tissues in lymph nodes, dislocation of a normal salivary gland, abnormal differentiation of local tissues, and abnormal migration of normal salivary tissue; among these, entrapment of salivary tissues in the developing cervical lymph nodes during embryogenesis is widely accepted.³ The entrapment theory can be explained by the presence of normal salivary tissue next to tumors occluded in cervical lymphatic tissues.⁴

Neoplasms originating from heterotopic sites are infrequent. The incidence, types, and diagnostic and therapeutic methods of tumors arising from normally positioned salivary gland tissue can be applied to tumors developed from HSGTs.⁵ Approximately 80% of HSGT tumors are benign.⁶ Fine-needle aspiration cytology (FNAC) is a simple, economic, and sensitive diagnostic tool, but it is problematic for a surgeon to decide whether performing an FNAC of a neck mass, especially one that is clinically benign looking, for a preoperative histopathological diagnosis is necessary. Tumor metastasis along the needle track after an FNAC procedure was reported in the literature. Although the

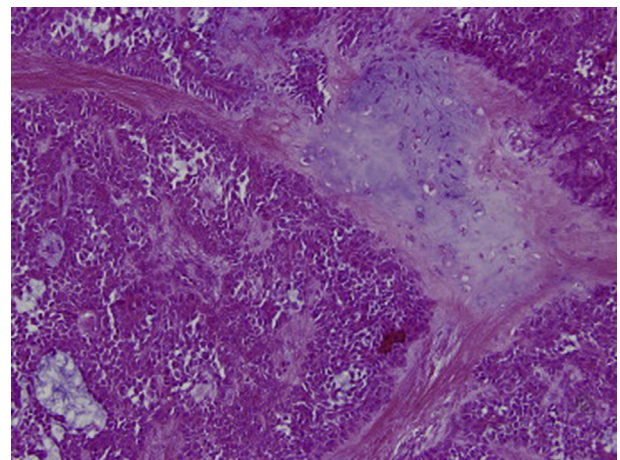


Figure 3 Hyperplasia of the glandular epithelium and mesenchyme-like tissues without malignant change (hematoxylin and eosin stain; magnification, 200×).

Table 1 Reports of heterotopic pleomorphic adenoma in the neck published in the English literature.

| Age/gender | Location of tumor | Authors | Year |
|------------|--|------------------------|------|
| 36/F | Below mandibular angle | Pesavento and Ferlito | 1976 |
| 50/F | Lower third of neck, lateral to SCM | Bothra et al | 1977 |
| 41/F | Below mandibular angle | Hulbert | 1978 |
| 40/M | Jugulodigastric area | Mair et al | 1978 |
| 61/M | Below mandibular angle | Singer et al | 1979 |
| 32/F | Jugulodigastric area | Zajtchuk et al | 1982 |
| 30/F | Submandibular area | Zajtchuk et al | 1982 |
| 35/F | Unknown | Zajtchuk et al | 1982 |
| 22/M | Upper neck, anterior border of SCM | Cotelingam and Gerberi | 1983 |
| 11/F | Below mandibular angle | Evans and Rubin | 1991 |
| 15/M | Below mandibular angle | Evans and Rubin | 1991 |
| 14/M | Upper neck, anterior border of SCM | Rodgers et al | 1991 |
| 9/F | Jugulodigastric area | Surana et al | 1993 |
| 12/F | Jugulodigastric area | Surana et al | 1993 |
| 50/M | Middle neck, anterior border of the trapezius muscle | Tay and Howitt | 1995 |
| 40/M | Right neck | Baldi et al | 2003 |
| 8/M | Upper neck, anterior border of SCM | Arunkumar et al | 2011 |

SCM = sternocleidomastoid muscle.

majority of reported cases were related to malignant lesions, seeding of a benign parotid tumor was also described.⁷ According to history taking and a physical examination, we believed that the neck mass in our case was most likely a benign lesion. Thus, an excisional biopsy was carried out for diagnosis and treatment, and to avoid the risk of tumor seeding via the FNAC procedure.

Although pleomorphic adenomas are the most common salivary gland tumor, Warthin's tumor is the most frequent heterotopic salivary gland neoplasm.⁸ Heterotopic salivary tumors are predominantly found in the anterior triangle of the upper neck.⁶ A review of the literature revealed a small number of heterotopic pleomorphic adenomas noted in the neck.^{4,9–20} Tumor locations of the presented cases were mainly in the upper neck and anterior to the sternomastoid muscle (Table 1). To the best of our knowledge, the present case is the first heterotopic pleomorphic adenoma found in the postauricular area.

Surgical excision of the lesion with close follow-up is the best way to treat benign HSGT tumors. With adequate surgery, the prognosis is excellent.⁸ We present this unusual postauricular pleomorphic adenoma to remind clinicians that a heterotopic salivary tumor should be included in the differential diagnosis of superior-posterior neck masses.

References

- Frommer J. The human accessory parotid gland: its incidence, nature, and significance. *Oral Surg Oral Med Oral Pathol* 1977; 43:671–6.
- Toh H, Kodama J, Fukuda J, Rittman B, Mackenzie I. Incidence and histology of human accessory parotid glands. *Anat Rec* 1993;236:586–90.
- Batsakis JG. Heterotopic and accessory salivary tissues. *Ann Otol Rhinol Laryngol* 1986;95:434–5.
- Singer MI, Applebaum EL, Loy KD. Heterotopic salivary tissue in the neck. *Laryngoscope* 1979;89:1772–8.
- Gudbrandsson FK, Liston SL, Maisel RA. Heterotopic salivary tissue in the neck. *Otolaryngol Head Neck Surg* 1982;90:279–82.
- Ferlito A, Bertino G, Rinaldo A, Mannarà GM, Devaney KO. A review of heterotopia and associated salivary gland neoplasms of the head and neck. *J Laryngol Otol* 1999;113:299–303.
- Supriya M, Denholm S, Palmer T. Seeding of tumor cells after fine needle aspiration cytology in benign parotid tumor: a case report and literature review. *Laryngoscope* 2008;118:263–5.
- Daniel E, McGuirt Sr WF. Neck masses secondary to heterotopic salivary gland tissue: a 25-year experience. *Am J Otol* 2005;26: 96–100.
- Pesavento G, Ferlito A. Benign mixed tumour of heterotopic salivary gland tissue in upper neck. Report of a case with a review of the literature on heterotopic salivary gland tissue. *J Laryngol Otol* 1976;90:577–84.
- Bothra AC, Agarwal RK, Dube MK, Bothra S, Dixit SM. Mixed salivary tumor in heterotopic salivary tissue at the base of the neck. *Int Surg* 1977;62:228–9.
- Hulbert JC. Ectopic mixed salivary tumour in the neck. *J Laryngol Otol* 1978;92:533–6.
- Mair IW, Elvertland HH, Knudsen OS. Heterotopic salivary pleomorphic adenoma. *J Otolaryngol* 1978;7:158–60.
- Zajtchuk JT, Patow CA, Hyams VJ. Cervical heterotopic salivary gland neoplasms: a diagnostic dilemma. *Otolaryngol Head Neck Surg* 1982;90:178–81.
- Cotelingam JD, Gerberi MP. Parotid heterotopia with pleomorphic adenoma. *Arch Otolaryngol* 1983;109:563–5.
- Evans MG, Rubin SZ. Pleomorphic adenoma arising in a salivary rest in childhood. *J Pediatr Surg* 1991;26:1314–5.
- Rodgers GK, Felder H, Yunis EJ. Pleomorphic adenoma of cervical heterotopic salivary gland tissue: case report and review of neoplasms arising in cervical heterotopic salivary gland tissue. *Otolaryngol Head Neck Surg* 1991;104:533–6.
- Surana R, Moloney R, Fitzgerald RJ. Tumours of heterotopic salivary tissue in the upper cervical region in children. *Surg Oncol* 1993;2:133–6.
- Tay HL, Howitt RJ. Heterotopic pleomorphic adenoma in the neck. *J Laryngol Otol* 1995;109:445–8.
- Baldi A, Persichetti P, Di Marino MP, Nicoletti G, Baldi F. Pleomorphic adenoma of cervical heterotopic salivary glands. *J Exp Clin Cancer Res* 2003;22:645–7.
- Arunkumar KV, Kumar S, Bansal V, Saxena S, Elhence P. Pleomorphic adenoma—unusual presentation of a salivary gland tumor in the neck of a child. *Quintessence Int* 2011;42:879–82.