

Tuberculous corneal ulcer with hypopyon: A case report

Neethu Latiff, Meena Lakshmipathy¹, M K Janani²,
Parthoprattim Dutta Majumder

This case report represents an unusual presentation of *Mycobacterium tuberculosis*-associated corneal ulcer with hypopyon. A 64-year-old man presented with a hypopyon corneal ulcer in the right eye. His corneal scrapings were negative, and the ulcer was not responding to empirical antimicrobial therapy. A real-time polymerase chain reaction from an aqueous aspirate of the right eye detected 422 copies of *M. tuberculosis*. Subsequent investigations revealed positive Mantoux and interferon-gamma release assay, supportive radiology. The patient was successfully treated with a course of antitubercular therapy and topical steroids. Hypopyon corneal ulcer, though a rare manifestation of ocular tuberculosis, should be considered in cases not responding to standard antimicrobial therapy.

Key words: Antituberculosis therapy, corneal ulcer, hypopyon, ocular tuberculosis, tuberculosis, uveitis

The clinical manifestations of ocular tuberculosis are diverse and protean. The diagnosis of ocular tuberculosis always remains challenging because of the difficulty in ocular sample collection considering the delicate structure of the eye. Due to the paucibacillary nature of the infection, live *Mycobacterium tuberculosis* is rarely isolated from tissue samples. Thus, hypotheses on immune-mediated inflammation and direct bacteria-mediated inflammation in the pathogenesis of intraocular tuberculosis have been advocated. Over the last few years polymerase chain reaction (PCR) has emerged out as a valuable tool for the diagnosis of infections from various tissue samples and has been able to fill this gap in the diagnosis of ocular tuberculosis partially.

Corneal involvement in tuberculosis is rare. Peripheral corneal ulceration, limbal nodule, and stromal keratitis have

been described in the literature. In the majority of the cases with corneal involvement even in an endemic country like India, possibility of *M. tuberculosis* infections comes last in the list of differential diagnoses. Similarly, in a patient presenting with hypopyon corneal ulcer, ocular tuberculosis is never considered, though there are several reports of ocular tuberculosis presenting as hypopyon uveitis. TB-causing immune stromal keratitis with hypopyon has been reported once in the past. We report a case of hypopyon corneal ulcer, where an association with *M. tuberculosis* infection was established with the help of real-time polymerase chain reaction (RT-PCR) and subsequent investigations revealed positive Mantoux test, interferon-gamma release assay (IGRA), and pulmonary involvement on radiography.

Case Report

A 64-year-old male presented to our outpatient clinic with a sudden increase in redness, pain, and watering in the right eye for the past 1 month. He was a known diabetic under antidiabetic treatment for the past 8 years. He had received a diagnosis of infective keratitis elsewhere and underwent a series of preliminary investigations, which also included microbiologically negative corneal scraping. His blood investigations were within normal limits, except for raised erythrocyte sedimentation rate (ESR). The ocular condition got worse in spite of being on intensive topical antimicrobial medications. On examination, best-corrected visual acuity (BCVA) in the right eye was 6/24 and 6/6 in the left eye. Slit-lamp examination of the right eye revealed mid-stromal infiltrate with overlying epithelial defect along with the adjacent superficial limbal vascularization. Examination revealed cells 1+, flare 1+ with trace hypopyon [Fig. 1a]. Slit-lamp and fundus examination of the left eye were unremarkable. View of fundus in right eye was hazy, but grossly it looked normal. A repeat corneal scraping was not helpful in isolating any microorganism. An anterior chamber paracentesis was done, and his aqueous aspirate was sent for microbiological evaluation and PCR was done for eubacterial, pan fungal genome, herpes group viruses, and *M. tuberculosis*. RT-PCR detected 422 copies/mL DNA of *M. tuberculosis*. Based on his PCR report, patient was thoroughly evaluated for systemic tuberculosis. Mantoux test was positive with induration of 15 mm and IGRA was also positive. High-resolution computerized tomography (HRCT) of chest was suggestive of granulomatous sequelae. His serum angiotensin enzyme and serum lysozyme were within the normal limit and serology for syphilis and human immunodeficiency viruses (HIV) were negative. We considered a provisional diagnosis of immune stromal keratouveitis secondary to ocular tuberculosis. The patient

Access this article online	
Quick Response Code:	Website: www.ijjo.in
	DOI: 10.4103/ijjo.IJO_1368_19

Departments of Uvea and ¹Cornea, Medical and Vision Research Foundations, Sankara Nethralaya, ²Sankara Nethralaya Referral Laboratory, Chennai, Tamil Nadu, India

Correspondence to: Dr. Parthoprattim Dutta Majumder, Department of Uvea, Sankara Nethralaya, 18, College Road, Nungambakkam, Chennai - 600 006, Tamil Nadu, India. E-mail: drparthoprattim@gmail.com

Received: 01-Aug-2019
Accepted: 27-Oct-2019

Revision: 26-Oct-2019
Published: 20-Apr-2020

This is an open access journal, and articles are distributed under the terms of the Creative Commons Attribution-NonCommercial-ShareAlike 4.0 License, which allows others to remix, tweak, and build upon the work non-commercially, as long as appropriate credit is given and the new creations are licensed under the identical terms.

For reprints contact: reprints@medknow.com

Cite this article as: Latiff N, Lakshmipathy M, Janani MK, Dutta Majumder P. Tuberculous corneal ulcer with hypopyon: A case report. Indian J Ophthalmol 2020;68:922-4.

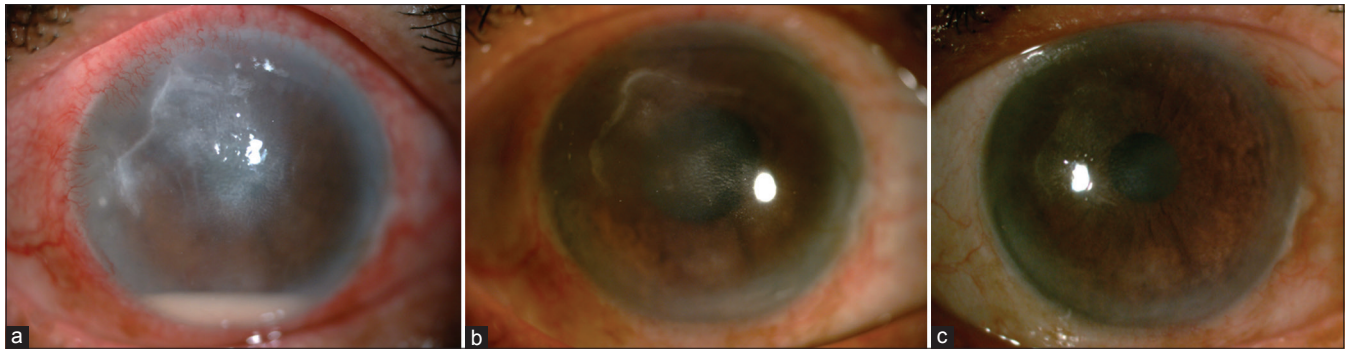


Figure 1: (a) Slit-lamp photograph of the right eye showing mid-stromal infiltrate, overlying epithelial defect along with adjacent superficial limbal vascularization and hypopyon. (b) Slit-lamp photograph of the right eye after 1 month. (c) Slit-lamp photograph of the right eye after cataract surgery

was advised to hike up the topical steroid and cycloplegics and was started on antitubercular treatment (ATT) in consultation with chest physician. The patient was closely monitored and there was a complete resolution of the corneal ulcer within a month of the initiation of the treatment [Fig. 1b]. The patient underwent phacoemulsification with the implantation of the intraocular lens in the right eye after 6 months of resolution of inflammation [Fig. 1c]. A repeat RT-PCR on aqueous aspirate, collected during cataract surgery, did not detect any copies of *M. tuberculosis* genome. His BCVA improved to 6/9 following surgery. He is in follow-up with us for last 1 year and after the treatment, till now, he did not have any recurrence of inflammation.

Discussion

The involvement of conjunctiva, cornea, and sclera are rare though but not uncommon in tuberculosis.^[1-3] Phlycten, interstitial keratitis, and conjunctival granulomas have been described as hypersensitivity diseases of cornea and conjunctiva.^[4,5] A hypersensitivity reaction to tubercular protein has been implicated primarily rather than direct involvement of *M. tuberculosis*. However, direct involvement by the bacilli is not uncommon and has been reported widely in the literature.^[1,6] Corneal involvement in ocular tuberculosis includes interstitial keratitis,^[7] disciform keratitis,^[8] and stromal keratitis.^[9] Similarly, the reports on hypopyon uveitis in association with tuberculous infection are increasing in number.^[3,10,11] The present case illustrates the protean corneal manifestations of tuberculous corneal ulcer. It was RT-PCR report that raised our suspicion toward tuberculous etiology in our case and was confirmed subsequently by positive Mantoux test, positive IGRA, pulmonary involvement in HRCT of chest.

Bilateral interstitial keratitis and granulomatous anterior uveitis were reported to be the initial manifestation in a 17-year-old girl. A presumptive diagnosis of ocular tuberculosis was achieved on the basis of raised ESR, positive Mantoux test and IGRA.^[7] The corneal edema responded to topical steroid and ATT. Delayed type of hypersensitivity reaction to the probable tubercular antigen in aqueous humor was implicated by the authors. Arora *et al.*^[8] described bilateral disciform keratitis as presenting manifestation of extrapulmonary tuberculosis in a 11-year-old girl. Subsequent investigations revealed tubercular Pott's spine, and treatment with topical steroid and ATT shows considerable resolution of corneal lesion.^[8] In another

separate case report, multiple disc-shaped stromal infiltrates with overlying corneal ulcers with non-granulomatous uveitis in both eyes and hypopyon were reported in an 11-year-old female by Singhal *et al.* The patient had raised ESR, positive Mantoux test, and radiographic evidence of pulmonary tuberculosis, and finally her ocular lesions responded to topical steroid and ATT. Similar to this case, our case initially did not respond to anti-infective treatment and initial microbiological investigations were negative. There are many reports of hypopyon uveitis associating ocular tuberculosis in the literature.^[3,10-12] RT-PCR was able to detect and quantify the presence of *M. tuberculosis* genome, which we believe was not reported previously.

To conclude, the possibility of ocular tuberculosis should be considered in the cases with corneal ulcer not responding to the standard antimicrobial therapy, and PCR can be added as a valuable tool in the diagnosis of such cases.

Declaration of patient consent

The authors certify that they have obtained all appropriate patient consent forms. In the form the patient(s) has/have given his/her/their consent for his/her/their images and other clinical information to be reported in the journal. The patients understand that their names and initials will not be published and due efforts will be made to conceal their identity, but anonymity cannot be guaranteed.

Financial support and sponsorship

Nil.

Conflicts of interest

There are no conflicts of interest.

Reference

1. Brar RK, Singh A, Deshpande AH, Gargade CB, Das S. Primary conjunctival tuberculosis presenting as dry eye: A rare case report and review of the literature. *Ocul Oncol Pathol* 2017;3:276-8.
2. Sarah B, Batoul MS, Ibtissam H, Ouafa H, Said A, Abdeljalil M. Corneal manifestations of tuberculosis: About 2 cases. *Am J Med Case Rep* 2016;4:160-4.
3. Dutta Majumder P. Presumed tuberculous sclerokeratitis presenting with hypopyon. *Ocul Immunol Inflamm* 2019;27:1121-3.
4. Miller SD. Hypersensitivity diseases of the cornea and conjunctiva with a detailed discussion of phlyctenular disease. *Ophthalmic Semin* 1977;2:119-65.

5. Lahiri K, Landge A, Gahlowt P, Bhattar A, Rai R. Phlyctenular conjunctivitis and tuberculosis. *Pediatr Infect Dis J* 2015;34:675.
 6. Solmaz N, Önder F, Demir N, AltuntaşAydın Ö. Primary conjunctival tuberculosis. *Turk J Ophthalmol* 2018;48:39-41.
 7. Kamal S, Kumar R, Kumar S, Goel R. Bilateral interstitial keratitis and granulomatous uveitis of tubercular origin. *Eye Contact Lens* 2014;40:e13-5.
 8. Arora R, Mehta S, Gupta D, Goyal J. Bilateral disciform keratitis as the presenting feature of extrapulmonary tuberculosis. *Br J Ophthalmol* 2010;94:809-10.
 9. Singhal D, Maharana PK, Sharma N, Titiyal JS. Immune stromal keratitis: A rare ocular presentation of tuberculosis. *BMJ Case Rep* 2018;2018:pil: bcr-2017-222571. doi: 10.1136/bcr-2017-222571.
 10. Velu J, Agarwal S, Gupta V, Sharma K, Sharma A, Gupta A. Hypopyon uveitis-a rare presentation of intraocular tuberculosis. *Ocul Immunol Inflamm* 2013;21:251-3.
 11. Rathinam SR, Rao NA. Tuberculous intraocular infection presenting with pigmented hypopyon: A clinicopathological case report. *Br J Ophthalmol* 2004;88:721-2.
 12. Shetty SB, Devulapally SH, Murali S, Walinjar JA, Biswas J. Tuberculous uveitis presenting as pigmented hypopyon – A case report. *Am J Ophthalmol Case Rep* 2017;7:1-3.
-