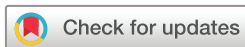

# Recurrent squamous cell carcinoma of the perianal skin: a case report



Ramon Staeger, Egle Ramelyte, Reinhard Dummer

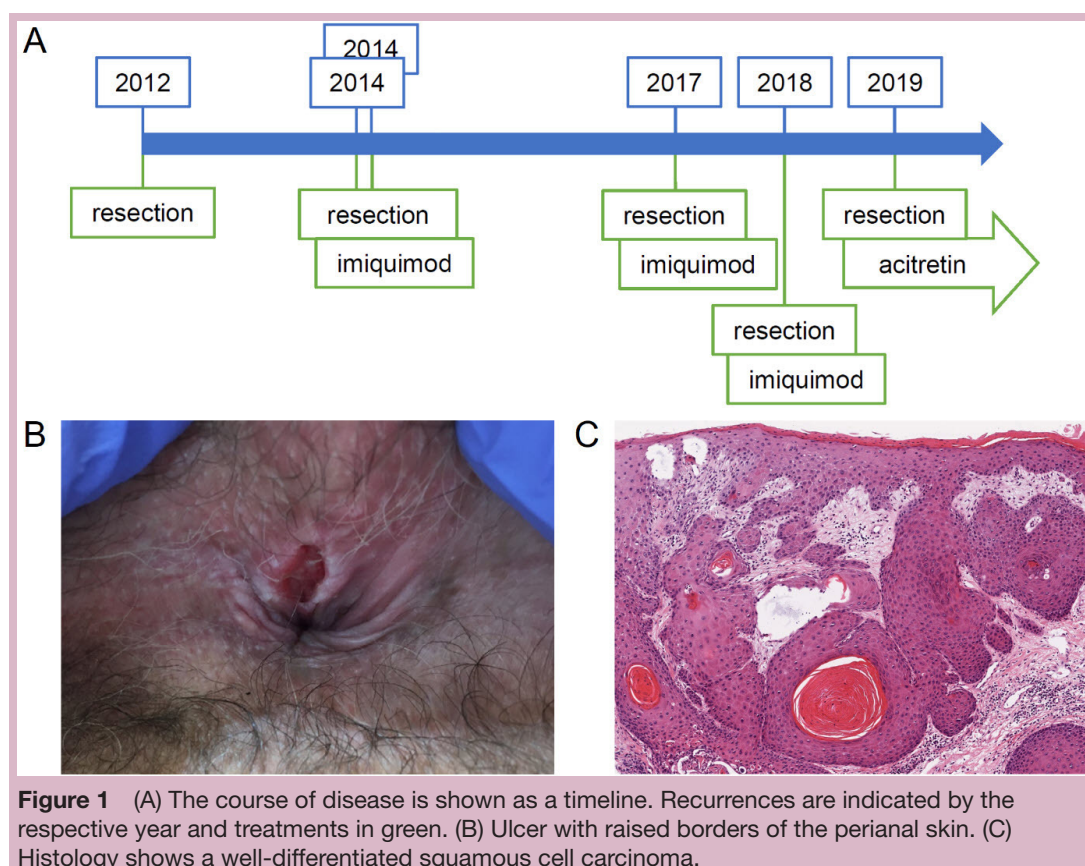
**To cite:** Staeger R, Ramelyte E, Dummer R. Recurrent squamous cell carcinoma of the perianal skin: a case report. *ESMO Open* 2020;5:e000786. doi:10.1136/esmoopen-2020-000786

Received 9 April 2020  
 Accepted 13 April 2020

We report the case of a 60-year-old patient with a recurrent squamous cell carcinoma (SCC) of the perianal skin. In 2012, an ulcerated perianal lesion was excised. The initial clinical diagnosis was an anal fissure, but histology showed a well-differentiated invasive SCC. Staging by pelvic MRI and proctoscopy did not show any pathology. HPV (human papillomavirus), PCR and STI (sexually transmitted infections) screening were negative. None of the known risk factors for perianal SCC applied: immunosuppression, high-risk types of HPV (16 and 18), men who have sex with men or smoking. The patient reported of chronic anal itch and scratching for many years. No evidence of lichen sclerosus were found clinically or histologically.

The patient was followed up by quarterly clinical examinations, regular proctoscopies

and pelvic MRI scans. In 2014, 2 years after the initial diagnosis, two local recurrences appeared in short succession ([figure 1](#)). Our multidisciplinary tumour board suggested either chemoradiation or local resection. After shared decision making with the patient, we opted for local resection, adjuvant therapy with topical imiquimod 5% and regular follow-ups. The patient had no signs of disease for 3 years. After 2017, he had three relapses, each approximately 1 year apart. We treated with local resection and imiquimod. After the last relapse, we initiated systemic acitretin (Neotigason), a second generation retinoid, which is often used as chemoprophylaxis for non-melanoma skin cancer.<sup>1 2</sup> At the moment, the patient has been disease free for 4 months.



© Author (s) (or their employer(s)) 2020. Re-use permitted under CC BY-NC. No commercial re-use. Published by BMJ on behalf of the European Society for Medical Oncology.

Department of Dermatology, University Hospital Zurich, Zurich, Switzerland

#### Correspondence to

Professor Reinhard Dummer; reinhard.dummer@usz.ch



SCC of the perianal skin are rare tumours. They belong to the entity of anal cancers, together with SCC of the anal canal. According to the European Society for Medical Oncology (ESMO) guidelines, perianal SCC may be treated by local resection, provided they are small (<2 cm) and well differentiated.<sup>1</sup> In contrast, standard of care for anal canal SCC is chemoradiation.

Chung *et al* have reported that 60% of anal SCC carry alterations in the phosphoinositol-3-kinase pathway (PI3K/AKT/mTOR). HPV-negative anal SCC were commonly mutated in *TP53* and *CDKN2A*.<sup>2</sup> A FoundationOne analysis of our patient's tumour revealed genetic alterations in *TP53* and *CDKN2A/B*, but not in the PI3K pathway, in line with the mutations observed in HPV-negative anal SCC. The tumour mutational burden was 1 Mut/Mb, thus much lower than in cutaneous SCC (cSCC).<sup>3</sup> This might be the result of minimal UV exposure of the perianal skin and lack of HPV-mediated mutagenesis in this case.

In conclusion, SCC of the perianal skin are rare and often misdiagnosed as anal fissure, eczema or haemorrhoids.<sup>4</sup> Chronic itch and scratching might play a pathogenic role due to mechanical stress and inflammation.<sup>5</sup> For most cases, surgery is first-line therapy, in contrast to the more aggressive approach in anal canal SCC. Perianal SCC probably belongs to the spectrum of different biological subtypes of cSCC and might share pathogenic mechanisms with cSCC of non-sun-exposed areas. Further research on genomic profiling of anal SCC may

define molecular subtypes and ultimately guide treatment decisions.

**Contributors** All authors have contributed to this work equally.

**Funding** The authors have not declared a specific grant for this research from any funding agency in the public, commercial or not-for-profit sectors.

**Competing interests** None declared.

**Patient consent for publication** Obtained.

**Provenance and peer review** Not commissioned; internally peer reviewed.

**Open access** This is an open access article distributed in accordance with the Creative Commons Attribution Non Commercial (CC BY-NC 4.0) license, which permits others to distribute, remix, adapt, build upon this work non-commercially, and license their derivative works on different terms, provided the original work is properly cited, any changes made are indicated, and the use is non-commercial. See: <http://creativecommons.org/licenses/by-nc/4.0/>.

#### ORCID iD

Reinhard Dummer <http://orcid.org/0000-0002-2279-6906>

#### REFERENCES

- 1 Glynne-Jones R, Nilsson PJ, Aschele C, *et al*. Anal cancer: ESMO-ESSO-ESTRO clinical practice guidelines for diagnosis, treatment and follow-up. *Radiother Oncol* 2014;111:330–9.
- 2 Chung JH, Sanford E, Johnson A, *et al*. Comprehensive genomic profiling of anal squamous cell carcinoma reveals distinct genomically defined classes. *Ann Oncol* 2016;27:1336–41.
- 3 South AP, Purdie KJ, Watt SA, *et al*. Notch1 mutations occur early during cutaneous squamous cell carcinogenesis. *J Invest Dermatol* 2014;134:2630–8.
- 4 Leonard D, Beddy D, Dozois EJ. Neoplasms of anal canal and perianal skin. *Clin Colon Rectal Surg* 2011;24:054–63.
- 5 Shacter E, Weitzman SA. Chronic inflammation and cancer. *Oncology* 2002;16:217–26.